

Elastic Stable Intramedullary Fixation Using Epibloc versus Crossed Kirschner Wires Fixation for Distal Forearm Fractures in Children: A Retrospective Analysis

Rocco De Vitis¹, Marco D'Orio¹, Marco Passiatore¹, Andrea Perna¹, Vitale Cilli², Giuseppe Taccardo¹

¹Department of Orthopaedics, Fondazione Policlinico Universitario A. Gemelli IRCCS, Rome Italy, ²Hand Surgery Unit, CHIREC Site Delta, Bruxelles, Belgium

Abstract

Background: Childrens' distal forearm fractures (DFFs) could be treated conservatively with closed reduction and immobilisation, but post-reduction displacements often occur. Displaced DFF should be surgically fixed, to avoid further displacement. Nevertheless, immobilisation after surgery is recommended. Epibloc system (ES), a system of stable elastic nail fixation, is widely used to stabilise adults extra-articular distal radius fractures, with advantages to not requiring post-surgical immobilisation. The present investigation represents a retrospective analysis of paediatric patients with DFF treated with ES applied with a minimal technical variation, to fix both ulna and radius fractures using a unique device. **Materials and Methods:** A retrospective analysis was performed on 44 children (age 6–11 years) who underwent closed reduction and internal fixation because of DFF (both ulna and radius). Group A (21 patients): ES fixation. Group B (23 patients): K-wires and short arm cast fixation. The primary outcome was the subsistence of reduction monitored through X-rays. The secondary outcome was the measurement of active range of motion (AROM) and the time of recovery. **Results:** No differences were observed comparing Group A and B in terms of the maintenance of reduction ($P > 0.05$). Seven days after the implant removal, patients in Group A reached significantly better results compared to patients in Group B in terms of AROM ($P < 0.05$). No differences were revealed in terms of complications between the two groups. **Conclusion:** ES applied with a minimal technical variation is safe and effective in treating distal ulna and radius fractures, with minimal requirement of post-surgical rehabilitation.

Keywords: Cast immobilisation, closed reduction and internal fixation, elastic stable intramedullary nailing, forearm fracture, forearm, paediatric

INTRODUCTION

Distal forearm fractures (DFFs) are very common in childhood.^[1] Displaced DFF could be treated conservatively with close reduction and cast immobilisation, but post-reduction displacement in the first 2 weeks is reported in 7%–34% and so require a stable fixation.^[1,2] Fracture must be fixed surgically, after the correct alignment was obtained, to prevent secondary displacement, mal-alignment and malunion.^[1] Post-surgical immobilisation is often recommended.^[1,3-5] Closed reduction and internal fixation (CRIF), using elastic stable intramedullary nailing (ESIN) or K-wire pinning followed by short arm-cast immobilisation, represents the most common surgical technique used for the treatment of

paediatric DFF.^[1,3-5] Some authors maintain that minimally invasive K-wire percutaneous fixations are safe and effective methods.^[1,4,6-9] In the authors' opinion, CRIF using epibloc system (ES)^[10-12] represents a reproducible and safe percutaneous fixation device.^[13]

The ES of percutaneous intramedullary fixation was developed in Italy and widely used to treat distal metaphyseal-epiphyseal radius fractures in the elderly.^[10-12]

Address for correspondence: Dr. Marco Passiatore, Fondazione Policlinico Universitario A. Gemelli IRCCS, Largo Agostino Gemelli 8, Roma 00168, Italy. E-mail: passiatore.m@gmail.com

Received: 12-12-2020 Revised: 24-06-2021 Accepted: 10-08-2021 Available Online: 23-06-2022

Access this article online

Quick Response Code:



Website:
www.afrijpaedsurg.org

DOI:
10.4103/ajps.AJPS_178_20

This is an open access journal, and articles are distributed under the terms of the Creative Commons Attribution-NonCommercial-ShareAlike 4.0 License, which allows others to remix, tweak, and build upon the work non-commercially, as long as appropriate credit is given and the new creations are licensed under the identical terms.

For reprints contact: WKHLRPMedknow_reprints@wolterskluwer.com

How to cite this article: De Vitis R, D'Orio M, Passiatore M, Perna A, Cilli V, Taccardo G. Elastic stable intramedullary fixation using epibloc versus crossed kirschner wires fixation for distal forearm fractures in children: A retrospective analysis. Afr J Paediatr Surg 2022;19:153-9.

It is a versatile technical device, according to the first description and application by Poggi, who designed ES in the last decade of the former century for metaphyseal fractures of tubular bones. ES has found its main application from the outset in fractures of the distal radius.^[11-13] Today is available in different versions and produced by different companies.

The ES for the distal radius fractures consist in elastic steel wires (35 cm in length, diameter 2–2.5 mm) accurately bent before the surgery, are inserted through the metaphyseal cortex.

The tip of the wires is flattened, to promote the bending into the intramedullary canal, without piercing the second the second cortex [Figure 1]. The wires are bended out of the skin, and finally they are locked with an external radiolucent plate and 2 screws, in order to obtain a ‘spring back effect’ on the fracture site [Figure 2].^[14] The described fixation system does not require additional cast immobilisation, and allows a rapid functional recovery.^[10-12,14] Based on our experience, we applied ES in children. ES is an ESIN technique and the wires are inserted sparing the growth plates.

The real advantage of avoiding post-surgical immobilisation is allowing and encouraging early mobilisation. The aim of the study is to analyse the efficacy of ES in a paediatric population with DFF and to compare clinical and radiological results with other CRIF techniques followed by cast immobilisation described in the literature.^[4,6,9]

MATERIALS AND METHODS

Study design

The present investigation represents a retrospective analysis on paediatric patients affected by displaced DFFs and surgically treated with CRIF at our institution from January 2015 to February 2019. This research study was conducted retrospectively from data obtained for clinical purposes. We consulted extensively with our Institutional Review Board who determined that our study did not need ethical approval. In our institute, CRIF represents the standard surgical treatment for paediatric DFF and ES is common used in distal displaced radius fracture. Both parents of all patients were clearly informed about the procedure and expressed a

written consensus before surgery. Advantages, dangers and complications eventually associated with surgery compared with conservative treatment (long arm cast immobilisation and radiographic assessment) were illustrated to all patients’ parents. This manuscript was reported following the STROBE guidelines.

Inclusion and exclusion criteria

All patients with age ranged between 6 and 11 years, with displaced distal extra-articular fracture of the radius and ulna (type 23-M/3.1 according to AO classification)^[15] and surgically treated with CRIF at our institute were potentially eligible for the study.

Exclusion criteria were:

1. Involvement of growth plates
2. Open fractures
3. Previous upper limb fractures
4. Radial head fractures
5. Galeazzi lesion
6. Pathologic fractures secondary to neoplasia or bone metabolic disease
7. Fractures of the proximal two-thirds forearm
8. Epilepsy
9. Attention-deficit hyperactivity disorder and/or mental retardation
10. Poor or incomplete radiographical and clinical follow-up.

As standard protocol, for each paediatric patient affected by DFFs and surgically treated were routinely recorded:

- Plain wrist radiographs (antero-posterior and lateral views) were obtained at the time of trauma and postoperatively
- Clinical evaluation and plain wrist radiographs 7 days after surgery (to detect any eventual fracture displacement) and 30 days after surgery (to confirm the fracture healing and program the wires removal)
- Clinical evaluation 7 and 30 days after wires removal. In these evaluations, wrist and forearm active range of motion (AROM) were evaluated and compared with the contralateral side. During the first visit after wires removal, the requirement of physiotherapy treatment was estimated case-by-case.

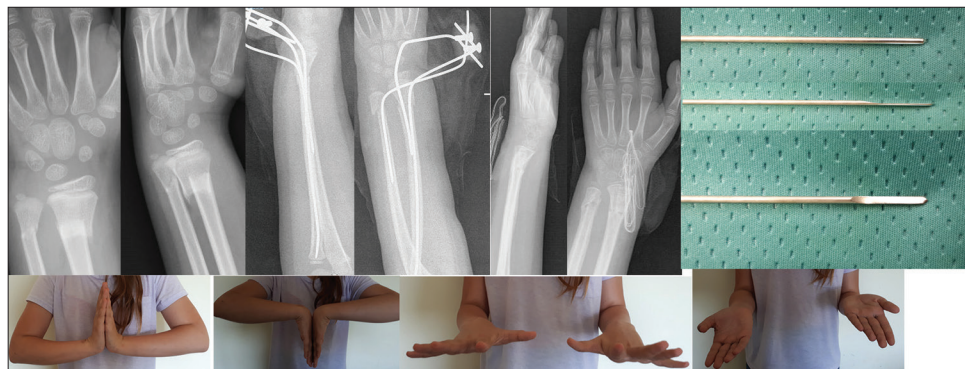

Figure 1: A 6-year-old girl. Radiographic images refer to pre-operative, immediately post-operative and 7 days post-wires removal. The flat tip allow to drive the wire into the medullary canal. The clinical images refer to 3 years post-operative follow-up

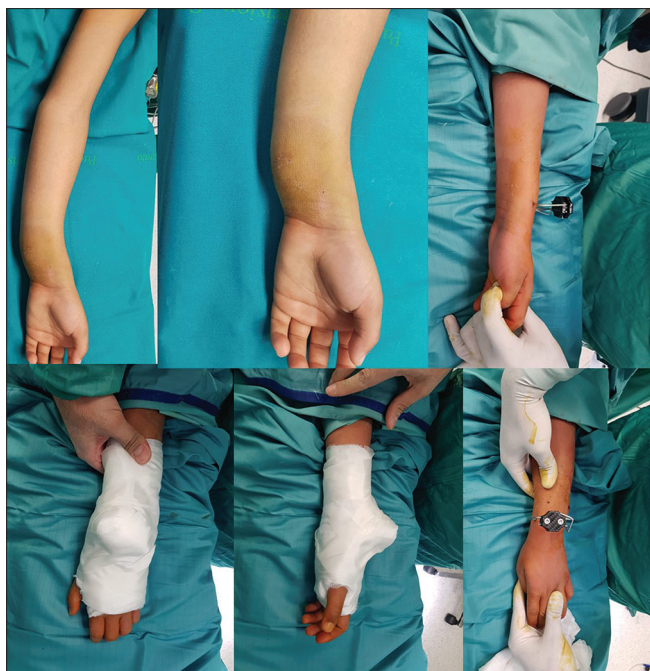

Figure 2: A 11-year-old boy. The wires are locked into an external radiolucent plate, and covered with a soft dressing

Patients assignment and groups setting

Forty-four patients met the inclusion criteria, therefore were included in the study. Patients were divided into two groups according to received treatment:

- Group A (21 patients): CRIF using ES
- Group B (23 patients): CRIF using cross K wires pinning and short arm cast.

CRIF represents the standard treatment for 23-M/3.1 fractures, therefore surgical treatment could be considered equivalent in both groups. The surgical procedure was selected after parents consulting amongst surgeons and parents.

Surgical techniques

The aim of CRIF is stable and trusted osteosynthesis. All patients were operated by two senior authors (R. D. V and G. T.). An accurate disinfection of the skin is recommended before performing surgery.^[16] A transient ischemia with pneumatic cuff was performed in all cases; a close reduction was obtained under the image intensifier. In case of difficult reduction, a small incision (5–10 mm) was made to lever out and reduce the distal fragments.^[4]

Epibloc system (Group A)

After anatomical reduction, two long, flattened tip [Figure 1], intramedullary elastic nails were inserted into the radius from distal to proximal, through the dorsal aspect of the distal fragment. The two radial entry points should be more distal if possible and proximal to the growth plate.

According to the original technique, ES is indicated for distal radius fractures alone.^[11] A minimal variation to the original technique was performed, to fix the fracture of the ulna. A third intramedullary nail was inserted from distal to proximal into the

ulna, in the same way as both previous ones. We used 2 mm calibre wires in all cases. All the nails were inserted by respecting the distal growth plates. Then the three nails were bent out of the skin to avoid decubitus and firmly connected to an external radiolucent plate, and a ‘spring back effect’ was obtained on the fracture site [Figure 2]. Patients do not need a further immobilisation. The primary stability of the obtained construct was tested with dynamic continuous sequence under the image intensifier. Finally, a soft bandage was made to protect ES [Figure 3].

Crossed K wire pinning (Group B)

Under fluoroscopic guide, after fracture reduction, at least two retrograde K-wires (calibre from 1.2 to 1.8 mm), were percutaneously inserted both in radius and ulna, proximal to the growth plates, to create an X-shaped construct [Figure 4].^[6,17,18] When the position of the wires under fluoroscopic guidance was satisfactory, the wires were cut and bent. Then, an immobilisation in a short arm cast was made.^[4]

As post-operative indication, the patients of both groups were educated to active and passive finger and wrist movement as permitted by the bandage or cast. In all patients, the implants were removed when the fracture was healed.

Variables

Fracture site angle displacements were determined on pre-operative radiographs. CRIF were performed with fluoroscopic guidance. The anatomical reduction was achieved and prompt post-operative plain radiographs were performed. Goniometric measurements were executed:

- Frontal angle of the distal fragments (on anterior posterior view)
- Sagittal angle of the distal fragments (on lateral view).

Due to children’s bone plasticity, a remodelling during growth will correct residual deformities, therefore a sagittal angle of $<30^\circ$ and frontal angle of $<10^\circ$ were accepted as good results.^[1,19] Radiographic images were evaluated by three observers (orthopaedic surgeons) and all measurements recorded were the mean among the three measurements observed. The wires removal was performed after mild sedation in all patients, as a 1-day surgery procedure. The movement of the treated wrist was strongly encouraged in all patients before hospital discharge. A treated wrist AROM evaluation (flexion-extension, pronation-supination) was obtained 7 days after the wires removal and compared with the contralateral wrist. AROM evaluation was performed in all following follow-up visits. AROM gap was calculated as percentage and compared with the contralateral wrist. Within paediatric patients, physiotherapy is a categorical indication when there was an AROM gap $>15\%$ in any type of movement compared with the contralateral wrist. If the AROM gap was $<15\%$, physiotherapy is only recommended and the parents were encouraged to stimulate child’s active and passive wrist motion.

Outcomes

The primary outcome was the preservation of fracture reduction. The secondary outcome was the recovery of the

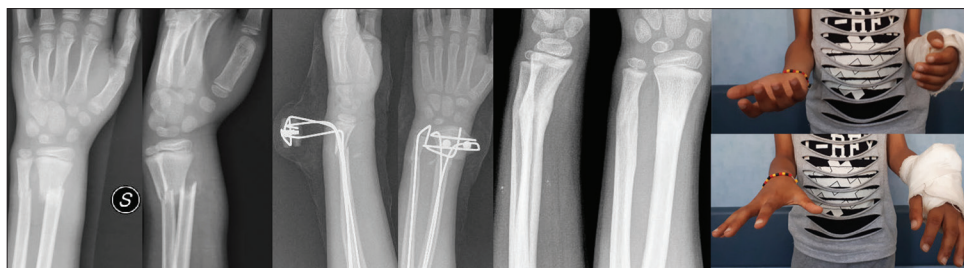


Figure 3: Same patient showed in Figure 2. Radiographs shows pre-operative, immediately post-operative and after 4 months post-operative follow-up, with a significant bon remodeling. Clinical images have been taken 7 days post-surgery: forearm can be pronated and supinated, with some limitations

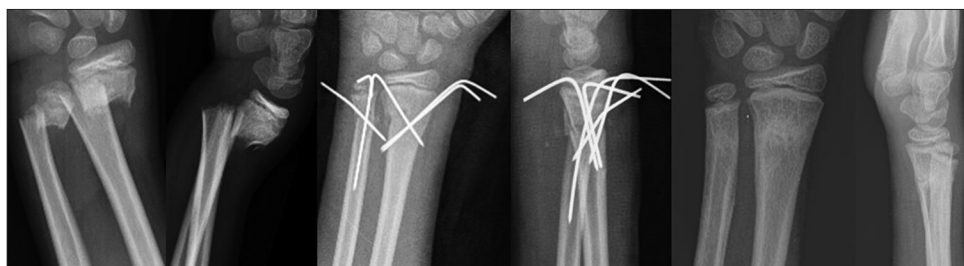


Figure 4: A 7-year-old girl treated with cross-pinning

AROM of the wrist, including pronation, supination, flexion and extension of the wrist, compared with the contralateral side, and the time requested to reach it. Need for additional physiotherapy and the presence of any side effects were also recorded. Complete AROM recovery was identified as a lag $\leq 5\%$ compared with the contralateral healthy wrist.

Statistical analysis

The Fisher exact test was used to compare for categorical variables, while the Wilcoxon test was performed for two dependent continuous variables. To compare two independent continuous variables the Mann–Whitney *U*-test was used. A value of $P < 0.05$ was identified as statistically significant. Data were reported as mean \pm standard deviation for continuous variables and as percentage and frequency for categorical variables. Statistical analysis was performed using the SPSS v. 19.0 software (SPSS Inc.; Chicago, IL, USA).

RESULTS

Participants

Forty-four patients (34 male, 10 female) affected by 23-M/3.1 fractures and operated with CRIF from January 2015–February 2019, were included in the study. All patients were treated within 120 h from the trauma (60.3 ± 26.5 in Group A, 68.4 ± 32.5 in Group B); 21 patients belonging to Group A (16 male, 5 female) and 23 to Group B (18 male, 5 female). The mean age in Group A was 8.4 ± 1.6 years while in Group B was 8.5 ± 1.7 years. Regional anaesthesia was performed in 16 patients (eight patients in Group A and eight patients in Group B). General anaesthesia was performed in the other enrolled patients. A further intra-focal reduction was necessary in seven patients (33.3%) in Group A and seven patients (30.4%) of Group B. The mean operation time was

15.8 ± 4.2 min in Group A and 16.1 ± 4.5 min in Group B. The mean follow-up was 18.4 ± 3.0 weeks in Group A, and 17.3 ± 2.4 weeks in Group B. Demographic and clinical features are resumed in Table 1.

Radiologic and clinical results

A satisfactory reduction was obtained in all patients and it was maintained until the last radiographic assessment in each case. All fractures healed 30 days after surgery. The mean time from surgery to implant removal was 35.8 ± 4.8 days in Group A and 36.8 ± 6.0 in Group B.

In Group A, the mean displacement at the post-operative X-ray was $2.4^\circ \pm 3.4^\circ$ on anterior-posterior view, $6.6^\circ \pm 4.5^\circ$ on the lateral view. Seven days after surgery, the mean displacement was $1.9^\circ \pm 3.3^\circ$ on anterior-posterior view, $7.1^\circ \pm 4.9^\circ$ on the lateral view, with no significant difference compared to the previous evaluation ($P > 0.05$) [Table 2].

In Group B, the mean displacement at the post-operative X-ray was on $2.2^\circ \pm 3.3^\circ$ anterior-posterior view, $6.9^\circ \pm 4.5^\circ$ on the lateral view. Seven days after surgery, the mean displacement was $2.8^\circ \pm 3.3^\circ$ on anterior-posterior view, $6.7^\circ \pm 4.7^\circ$ on the lateral view, with no significant difference compared to the previous measurement ($P > 0.05$) [Table 2].

AROM difference, 7 days after implants removal, was statistically significant for each movement between the two groups. The mean flexion in Group A was $95.2 \pm 5.1\%$ versus $85.8 \pm 10.3\%$ in Group B ($P = 0.004$). The mean extension in Group A was $93.3 \pm 6.6\%$ versus $83.2 \pm 11.2\%$ in Group B ($P = 0.003$). The mean pronation in Group A was $95.7 \pm 6.0\%$ versus $82.1.0 \pm 12.0\%$ in Group B ($P = 0.0002$). The mean supination in Group A was $94.8\% \pm 5.1$ versus $78.0\% \pm 11.6$ in Group B ($P < 0.00001$). Physiotherapy was strictly recommended for 17 patients in Group B while

only for two patients in Group A and the difference was statistically significant ($P < 0.0001$) according to the Fisher test. Thirty days after wires removal, all patients showed a complete functional recovery and no statistically significant differences were observed between both groups concerning AROM ($P > 0.05$) [Table 3].

No major complications were reported. No infections were recorded. In two patients in Group A and in six patients in Group B was observed skin suffering at the level of wires entry point, with no significant difference between Group A and B ($P = 0.24$). All skin suffering cases healed in few days without further treatment [Table 3].

DISCUSSION

In the last decade, the orthopaedic surgeons' strategy for the treatment of paediatric displaced DFF was changed, preferring surgical treatment more frequently compared to the past.^[1] Surgery should restore the anatomic bone alignment, and ensure a stable fixation, without provoking iatrogenic injuries of the growth plates. Nevertheless, in clinical practice, surgical treatment is useful to limit a further displacement during the healing period but does not exclude the post-operative immobilisation time.^[1,4,9] In fact, upper limb fractures, whether conservatively or surgically treated, need a cast immobilisation period for approximately 3 weeks, to promote appropriate healing of the fracture. This period can lead to elbow or wrist stiffness after cast removal and consequently to limitations in a child's daily activities.^[20-23] Despite this

risk, the use of physical therapy after removal of the cast is still on debate, because of strong evidence of autonomous complete functional recovery in children forearm fractures. In contrast, recent studies demonstrated that an upper limb immobilisation, longer than 2 weeks, can produce thinning of its corresponding region on the primary sensory-motor cortex, known as homunculus, and so following physical therapy was strictly recommended.^[20,24] Furthermore Colaris *et al.*, on 2013, reported that long cast immobilisation, in children with both bone forearm fractures, could result in higher limitation of pronation/supination because of severe interosseous membrane contracture and in those cases, physiotherapy was associated with a better functional outcome.^[23] Therefore we believe that immobilisation should be reduced to the minimum, so that early mobilisation could minimise cortical alterations, reduce the risk of joint stiffness, avoiding the need of physiotherapy and granting a faster return to all daily activities. Physical therapy in fact, even if required, increases psychological trauma related to the fractures, due to the poor adherence to therapy in this population. Several surgical procedures for paediatric displaced DFF have been presented, but any kind of fixation has limitations. Plate osteosynthesis provides often a more stable and satisfactory reduction but could hesitate in an anaesthetic skin scar, slower healing and risk of physeal plate injury.^[25,26] Furthermore the adoption of minimally invasive techniques often was desired from patients and their parents compared with open plate fixation. K-wire pinning represents a standard fixation technique broadly applied for DFFs; it allows a good primary biomechanical stability, but a casting immobilisation is recommended at least for 4 weeks after surgery, causing soft-tissue impairment.^[3,4,22-25] The necessity of immobilisation after an invasive surgical procedure, arised a discussion in the literature about the correct indication between surgical or conservative treatment.^[5,27]

As known in literature a delayed wrist mobilisation could result in the worst AROM recovery and a more pain during the movement of the treated wrist.^[21-23] These drawbacks can be prevented due to an elastic percutaneous fixation systems that could provide a strong mechanical stability without decreasing the periosteal blood supply or disturbing fracture hematoma and paediatric bone remodelling capacity.^[1,28] Furthermore, they also allow micro-movements at the fracture site, which promote the production of a bony callus, without need of an external orthosis.^[9,29-31] This kind of stabilisation, was compatible with the biomechanical properties of growing bone.^[32] ESIN in the treatment of paediatric forearm fractures was esteemed in literature, as a stable, efficient and safe technique, using different implant designs and materials, even if often related to post-operative cast immobilisation.^[32] Some authors proposed an ES-like surgical techniques for the surgical treatment of paediatric DFF, that granted an early functional recovery and reducing the immobilisation time. Varga *et al.* described a modified ESIN method with two pre-bent short thick elastic titanium nails inserted from distal to proximal in radius, associated with ulnar anterograde

Table 1: Demographic and clinical features of studied patient

| Demographics | Group A, n (%) | Group B, n (%) |
|--|----------------|----------------|
| Number of patient | 21 (47.7) | 23 (52.3) |
| Age (years) mean±SD | 8.4±1.6 | 8.5±1.7 |
| Gender (female/male) | 5/16 | 5/18 |
| Anaesthesia | | |
| Regional | 8 (38.1) | 8 (34.8) |
| General | 13 (61.9) | 15 (65.2) |
| Follow-up (weeks postsurgery), mean±SD | 18.4±3.0 | 17.3±2.4 |

SD: Standard deviation

Table 2: The main results about reduction maintenance in each group

| Maintenance of reduction | Degrees±SD (°) | | P |
|--------------------------|------------------------|----------------------|------|
| | Immediately after CRIF | 7 days after surgery | |
| Group A | | | |
| Frontal angle | 2.4±3.4 | 1.9±3.3 | 0.34 |
| Lateral angle | 6.6±4.5 | 7.1±4.9 | 0.42 |
| Group B | | | |
| Frontal angle | 2.2±3.3 | 2.8±3.3 | 0.68 |
| Lateral angle | 6.9±4.5 | 6.7±4.7 | 0.55 |

SD: Standard deviation, CRIF: Closed reduction and internal fixation

Table 3: The main results divider per groups

| Variables | Percentage compared to the contralateral \pm SD | | P |
|--|---|-----------------|----------|
| | Group A | Group B | |
| Healed patients (%) | 100 | 100 | |
| AROM measured 7 days after wire removal | | | |
| Flexion | 95.2 \pm 5.1 | 85.8 \pm 10.3 | 0.004 |
| Extension | 93.3 \pm 6.6 | 83.2 \pm 11.2 | 0.003 |
| Pronation | 95.7 \pm 6.0 | 82.2 \pm 12.0 | 0.0002 |
| Supination | 94.8 \pm 5.1 | 78.0 \pm 11.6 | <0.00001 |
| AROM measured 30 days after wire removal | | | |
| Flexion | 98.1 \pm 4.0 | 98.7 \pm 3.4 | 0.74 |
| Extension | 98.6 \pm 3.6 | 99.5 \pm 2.1 | 0.58 |
| Pronation | 97.6 \pm 4.3 | 98.3 \pm 3.9 | 0.73 |
| Supination | 99.0 \pm 3.0 | 98.3 \pm 3.9 | 0.67 |
| Number of patients who need for physiotherapy, n (%) | 2 (9.5) | 17 (73.9) | <0.0001 |
| Complications (skin suffering), n (%) | 2 (9.5) | 6 (26.1) | 0.24 |

SD: Standard deviation, AROM: Active range of motion

nailing in case of severe ulnar displacement. Varga moreover underlined the importance of a short immobilisation period, usually 1–2 weeks.^[3] In our opinion this technique had some limitations: first, the need of an immobilisation period, although reduced, to maintain stability and second due to elbow discomfort caused by the anterograde ulnar nailing, already described in the literature^[17,33] on the other hand, regarding Varga's propose, we consider that one nail at least should be long up to the radial head, to make a more stable synthesis, in order to avoid a further immobilisation. The application of ES in paediatric DFF is an innovation because maintains the mechanical benefits of intramedullary elastic nailing, adding stability, just joining the three wires together with an 'external binding' system to reach a stronger growth plate sparing construct.^[11]

This kind of 'external bridge' holds the distance between radius and ulna without compressing the radio-ulnar joint and provides three-dimensional stability to the radio-ulnar complex. Furthermore, the soft dressing allows complete and early mobilisation of wrist in flexion and extension, partially limiting prono-supination movement, to avoid torsion forces on both bones that could contribute to a further displacement. This is why mostly physiotherapy is not necessary.

In our series a satisfying fracture reduction was maintained at the last radiographic evaluation in all patients, suggesting that both used techniques are effective in restoring the anatomy of the distal forearm. Otherwise functional outcomes, compared with the contralateral healthy limb, in the short follow-up (7 days from implants removal) showed a significant difference ($P < 0.05$) between the two groups, with the ES group, having a better result, primarily in pronation and supination AROM. At 30 days from implants removal, no significant AROM differences were revealed, pointing out that both procedures are able to reach the same result, but with different timing. This gap was shown also by the greater need of physiotherapy for the Group B (73.9%) compared with

Group A (9.5%) and was related to earlier mobilisation granted from bandage unlike the cast. Our patients have never shown discomfort towards ES, but, especially during the immediate post-operative period (1st week) analgesic therapy could be needed to provide a pain-free mobilisation of the treated wrist. A clinical evaluation 7 days after surgery is helpful to understand if the patient observes the surgeon instructions on treated wrist movements.

This study was the first to present ES as the valid procedure in paediatric DFF treatment. Compared with a broadly accepted technique, in two homogeneous groups of patients, we found that they bring to similar results regard restoring anatomy, reduction maintaining and functional outcomes (in terms of AROM); though functional recovery seems to be faster when fracture is treated with ES.

However, our study has limitations. First, it included a fairly small number of patients, they were in different growth steps and the study had a retrospective design. Although our follow-up was wide enough to evaluate fracture healing and motion analysis, further studies with a higher level of evidence and a larger follow-up are required to confirm our results.

CONCLUSION

ES is an easy, secure, reproducible and minimally invasive alternative procedure for the treatment of extraarticular DFF in a paediatrics population. This technique ensures a better functional result compared to K-wire pinning in paediatric DFFs.

Compliance with ethical requirements

All procedures followed were in accordance with the ethical standards of the responsible committee on human experimentation (institutional and national) and with the Helsinki Declaration of 1975, as revised in 2008. Informed consent was obtained from all parents' patients for being included in the study. All the authors of this article do not have

any financial or personal relationships with other people, or organisations, that could inappropriately influence this article. There are no conflicts of interest.

Declaration of patient consent

The authors certify that they have obtained all appropriate patient consent forms. In the form, the patients have given their consent for their images and other clinical information to be reported in the journal. The patients understand that their names and initials will not be published and due efforts will be made to conceal their identity, but anonymity cannot be guaranteed.

Financial support and sponsorship

Nil.

Conflicts of interest

There are no conflicts of interest.

REFERENCES

- van Egmond PW, Schipper IB, van Luijt PA. Displaced distal forearm fractures in children with an indication for reduction under general anesthesia should be percutaneously fixated. *Eur J Orthop Surg Traumatol* 2012;22:201-7.
- Voto SJ, Weiner DS, Leighley B. Redisplacement after closed reduction of forearm fractures in children. *J Pediatr Orthop* 1990;10:79-84.
- Varga M, Józsa G, Fadyas B, Kassai T, Renner A. Short, double elastic nailing of severely displaced distal pediatric radial fractures: A new method for stable fixation. *Medicine (Baltimore)* 2017;96:e6532.
- Valisena S, Gonzalez JG, Voumard NM, Hamitaga F, Ciritis BD, Mendoza Sagaon M, *et al.* Treatment of paediatric unstable displaced distal radius fractures using Kapanji technique: A case series. *Eur J Orthop Surg Traumatol* 2019;29:413-20.
- Adrian M, Wachtlin D, Kronfeld K, Sommerfeldt D, Wessel LM. A comparison of intervention and conservative treatment for angulated fractures of the distal forearm in children (AFIC): Study protocol for a randomized controlled trial. *Trials* 2015;16:437.
- Özkan S, Westenberg RF, Helliwell LA, Mudgal CS. Distal radius fractures: Evaluation of closed reduction and percutaneous Kirschner wire pinning. *J Hand Microsurg* 2018;10:134-8.
- Kim JY, Tae SK. Percutaneous distal radius-ulna pinning of distal radius fractures to prevent settling. *J Hand Surg Am* 2014;39:1921-5.
- Yung SH, Lam CY, Choi KY, Ng KW, Maffulli N, Cheng JC. Percutaneous intramedullary Kirschner wiring for displaced diaphyseal forearm fractures in children. *J Bone Joint Surg Br* 1998;80:91-4.
- Yung PS, Lam CY, Ng BK, Lam TP, Cheng JC. Percutaneous transphyseal intramedullary Kirschner wire pinning: A safe and effective procedure for treatment of displaced diaphyseal forearm fracture in children. *J Pediatr Orthop* 2004;24:7-12.
- Solarino G, Vicenti G, Abate A, Carrozzo M, Picca G, Colella A, *et al.* Volar locking plate vs epibloc system for distal radius fractures in the elderly. *Injury* 2016;47 Suppl 4:S84-90.
- Catalano F, Poggi D, Massarella M, De Mas M, Vivaldi R, Vignali E. Revisione critica di 1247 fratture metaepifisarie dell'arto superiore trattate con il sistema Epibloc®: Studio multicentrico. *Riv Chir Mano* 2004;41:89-104.
- Altissimi M, Nienstedt F. Fratture del radio distale. In: *Trattato di Chir. Della Mano*. Roma: Verduci; 2007.
- Geraci A, Sanfilippo A, D'Arienzo M. The treatment of wrist fractures with Epibloc system. *Ortop Traumatol Rehabil* 2011;13:1-7.
- Passiatore M, De Vitis R, Perna A, D'Orio M, Cilli V, Taccardo G. Extraphyseal distal radius fracture in children: Is the cast always needed? A retrospective analysis comparing Epibloc system and K-wire pinning. *Eur J Orthop Surg Traumatol* 2020;30:1243-50.
- Joeris A, Lutz N, Blumenthal A, Slongo T, Audigé L. The AO pediatric comprehensive classification of long bone fractures (PCCF). *Acta Orthop* 2017;88:123-8.
- De Vitis R, Passiatore M, Perna A, Proietti L, Taccardo G. COVID-19 contagion and contamination through hands of trauma patients: What risks and what precautions? *J Hosp Infect* 2020;105:354-5.
- Catena N, Calevo MG, Fracassetti D, Moharamzadeh D, Origo C, De Pellegrin M. Risk of ulnar nerve injury during cross-pinning in supine and prone position for supracondylar humeral fractures in children: A recent literature review. *Eur J Orthop Surg Traumatol* 2019;29:1169-75.
- De Pellegrin M, Fracassetti D, Moharamzadeh D, Origo C, Catena N. Advantages and disadvantages of the prone position in the surgical treatment of supracondylar humerus fractures in children. A literature review. *Injury* 2018;49 Suppl 3:S37-42.
- Noonan KJ, Price CT. Forearm and distal radius fractures in children. *J Am Acad Orthop Surg* 1998;6:146-56.
- Arrebola LS, Yi LC, de Oliveira VG. The use of video games combined with conventional physical therapy in children with upper limb fractures: An exploratory study. *J Pediatr Rehabil Med* 2019;12:65-70.
- Zhang P, Jia B, Chen XK, Wang Y, Huang W, Wang TB. Effects of surgical and nonoperative treatment on wrist function of patients with distal radius fracture. *Chin J Traumatol* 2018;21:30-3.
- Gong HS, Lee JO, Huh JK, Oh JH, Kim SH, Baek GH. Comparison of depressive symptoms during the early recovery period in patients with a distal radius fracture treated by volar plating and cast immobilisation. *Injury* 2011;42:1266-70.
- Colaris JW, Allema JH, Reijman M, de Vries MR, Ulas Biter L, Bloem RM, *et al.* Which factors affect limitation of pronation/supination after forearm fractures in children? A prospective multicentre study. *Injury* 2014;45:696-700.
- Langer N, Hänggi J, Müller NA, Simmen HP, Jäncke L. Effects of limb immobilization on brain plasticity. *Neurology* 2012;78:182-8.
- Van der Reis WL, Otsuka NY, Moroz P, Mah J. Intramedullary nailing versus plate fixation for unstable forearm fractures in children. *J Pediatr Orthop* 1998;18:9-13.
- Lieber J, Sommerfeldt DW. Diametaphyseal forearm fracture in childhood. Pitfalls and recommendations for treatment. *Unfallchirurg* 2011;114:292-9.
- Madhuri V, Dutt V, Gahukamble AD, Tharyan P. Conservative interventions for treating diaphyseal fractures of the forearm bones in children. *Cochrane Database Syst Rev* 2013;(4):CD008775.
- Do TT, Strub WM, Foad SL, Mehlman CT, Crawford AH. Reduction versus remodeling in pediatric distal forearm fractures: A preliminary cost analysis. *J Pediatr Orthop B* 2003;12:109-15.
- Tamburrelli FC, Perna A, Proietti L, Zirio G, Santagada DA, Genitiempo M. The feasibility of long-segment fluoroscopy-guided percutaneous thoracic spine pedicle screw fixation, and the outcome at two-year follow-up. *Malays Orthop J* 2019;13:39-44.
- De Vitis R, Passiatore M, Perna A, Tulli A, Pagliei A, Taccardo G. Modified Matti-Russe technique using a "butterfly bone graft" for treatment of scaphoid non-union. *J Orthop* 2020;19:63-6.
- De Vitis R, Passiatore M, Cilli V, Maffei J, Milano G, Taccardo G. Intramedullary nailing for treatment of forearm non-union: Is it useful?-A case series. *J Orthop* 2020;20:97-104.
- Poutoglidou F, Metaxiotis D, Kazas C, Alvanos D, Mpeletsiotis A. Flexible intramedullary nailing in the treatment of forearm fractures in children and adolescents, a systematic review. *J Orthop* 2020;20:125-30.
- Salonen A, Salonen H, Pajulo O. A critical analysis of postoperative complications of antebrahum TEN-nailing in 35 children. *Scand J Surg* 2012;101:216-21.