

Direct His bundle pacing using retrograde mapping in complete heart block and L-transposition of the great arteries



Indrajeet Mahata, MD,* Scott L. Macicek, MD,* Daniel P. Morin, MD, MPH, FHRS*†

From the *Ochsner Medical Center, New Orleans, Louisiana, and †University of Queensland Ochsner Clinical School, New Orleans, Louisiana.

Introduction

Levo-transposition of the great arteries (L-TGA), also termed “congenitally corrected transposition of the great arteries,” is characterized by both atrioventricular (AV) and ventriculoarterial discordance. The subpulmonary ventricle is the morphologic left ventricle (LV) and the systemic ventricle is the morphologic right ventricle (RV). The word “corrected” is used because of the double discordance, which maintains the physiologic direction of blood flow.

The incidence of L-TGA ranges from 0.02 to 0.07 per 1000 live births, accounting for <1% of congenital heart abnormalities.¹

The effects of L-TGA can range from the patient being asymptomatic and enjoying normal life expectancy, to neonatal congestive heart failure (HF) in the setting of complete AV block and a dilated systemic RV. Progressive dysfunction of the morphologic RV as the systemic pump can lead to gradual decline in the clinical course, often eventually indicating device therapy for ventricular resynchronization. In addition, L-TGA is associated with various other congenital abnormalities, such as ventricular septal defect, left-sided TV abnormalities including Ebstein’s anomaly, and right-sided mitral valve abnormalities.² The associated variable anatomical location of the coronary sinus (CS) can make cardiac resynchronization therapy device implantation a challenge.³ In addition, the bundle of His may be found in various locations, and in some cases dual AV nodes (1 anterior, 1 posterior) and associated dual His bundles may be found.³

Here, we report a patient with L-TGA with complete heart block (CHB), progressive HF, RV dilation, and multiple failed CS leads, who was treated successfully with permanent His bundle pacing (HBP). We demonstrate that HBP is

KEY TEACHING POINTS

- Levo-transposition of the great arteries (L-TGA) is associated with variable anatomical location of the coronary sinus, making cardiac resynchronization therapy device implantation a challenge.
- Permanent His bundle pacing (HBP) is a feasible option in patients with L-TGA with complete heart block and hostile coronary sinus anatomy.
- In complete antegrade atrioventricular block, retrograde His activation may be useful for mapping the His bundle, facilitating successful HBP.

feasible in such patients, and also describe the successful use of retrograde His activation to map HBP catheter placement in the setting of complete AV block.

Case report

A 46-year-old man with L-TGA, permanent atrial fibrillation, CHB, and nonischemic cardiomyopathy was evaluated for worsening HF symptoms. He had NYHA class III symptoms of dyspnea on mild exertion. His medical regimen included typical guideline-directed medical therapy as well as constant milrinone infusion. The exam was notable for morbid obesity with a body mass index of 44.5 kg/m², crackles at the lung bases, and pedal edema. Echocardiography demonstrated a severely depressed systemic ventricle ejection fraction of 15%, with elevated left atrial pressure and pulmonary hypertension (calculated pulmonary artery systolic pressure of 50 mm Hg). The subpulmonary ventricle showed normal function. He had suffered frequent HF admissions, requiring inotropes and intra-aortic balloon pump support. He was not to be a candidate for advanced HF therapies including a ventricular assist device or transplant, primarily owing to his morbid obesity.

The patient’s predominant spontaneous heart rhythm was atrial fibrillation with slow aberrant conduction to the ventricle (Figure 1), and at other times there was CHB with ventricular pacing. Ten years prior to presentation to our center, a

KEYWORDS Complete heart block; Coronary sinus stenosis; Heart failure; His bundle pacing; L-TGA; Retrograde His mapping (Heart Rhythm Case Reports 2019;5:291–293)

Dr Morin received speaker honoraria/consulting fees from Biotronik, Boston Scientific, and Medtronic. The other authors have no conflicts of interest. **Address reprint requests and correspondence:** Dr Daniel P. Morin, Ochsner Medical Center, 1514 Jefferson Hwy, New Orleans, LA 70121. E-mail address: dmorin@ochsner.org.

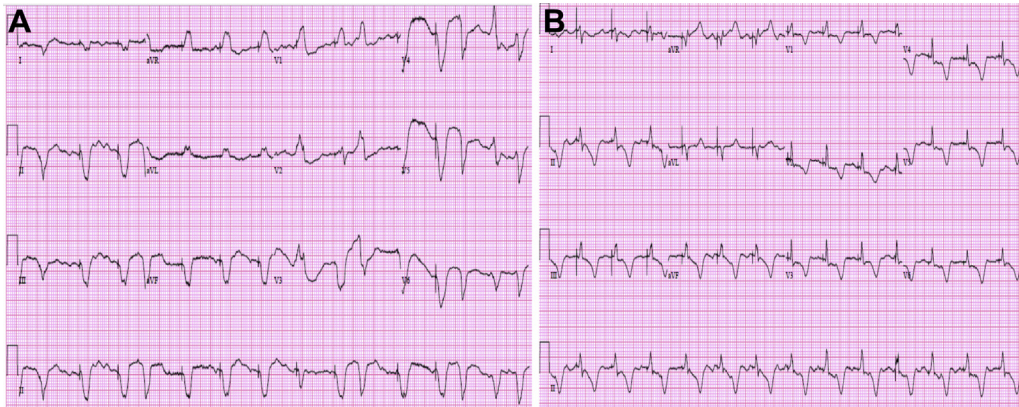


Figure 1 A: Preprocedure electrocardiogram, revealing atrial fibrillation with aberrant conduction, as well as demand right ventricular pacing with QRS duration 168 ms. B: Postoperative electrocardiogram, demonstrating His bundle pacing with a narrow QRS.

biventricular implantable cardioverter-defibrillator had been implanted in response to his HF and QRS duration >150 ms. The CS lead had dislodged, and LV capture was lost completely. In 2017, a second attempt was made to place a CS lead. CS access was difficult, even with the previously existing CS lead as a guide, owing to the distorted anatomy. As is commonly seen in L-TGA,⁴ there was an angulated takeoff followed by an apparent stenosis. This stenosis prevented deep cannulation of the CS. On follow-up visits, the second CS lead's threshold was higher than at implant and subsequently it did not capture in any pacing configuration. We decided to attempt HBP in order to effect ventricular resynchronization.

To facilitate localization the His bundle, we placed a quadripolar catheter via the right common femoral vein and positioned it in the typical His bundle location at the anteroseptal aspect of the right-sided AV valve. The patient presented in CHB with a ventricular escape rhythm. Fortunately, there were frequent ventricular premature contractions (VPCs), followed by retrograde His deflections (Figure 2). Using a nondeflectable peelaway catheter designed for HBP (model C315HIS, Medtronic, Minneapolis, MN), we advanced an active-fixation bipolar lead (Select Secure, model 3830, Medtronic) to the location of the bundle of His, as located by the quadripolar diagnostic catheter. High-density mapping of the area was performed, and following lead fixation we were able to capture the His bundle. We achieved selective His bundle capture, as seen in Figure 3. The capture threshold was 1.2 V at 1 ms. The device was programmed VVIR 70 and to pace "LV first" by 80 ms, which results in HBP followed by backup RV pacing that occurs during the ventricular absolute refractory period. His underlying rhythm post HBP continued to be CHB with intermittent slow AV conduction.

Since His bundle lead implantation, the patient has been successfully selectively His-paced, reports improved exertion tolerance, and has not required a hospital admission for over 6 months. Postoperative echocardiogram done 1 month after the procedure did not demonstrate any change in the systemic ventricle (RV). A repeat echocardiogram is pending. As the patient's systemic ventricular dysfunction

is longstanding, improvement in RV ejection fraction may be somewhat delayed. Of note, the patient's brain natriuretic peptide has improved from 1441 pg/mL to 299 pg/mL over the course of 1 month post HBP, offering some objective evidence of improvement.

Discussion

Although temporary direct HBP has been regularly performed in the electrophysiology laboratory for many years, permanent direct HBP in humans was first described by Deshmukh and colleagues⁵ in 2000. The absence of specialized tools for implantation initially dampened enthusiasm for this technique. However, the recent development of specifically designed sheaths and leads for mapping the HBP and delivering permanent HBP has led to a significant revival of interest.

The bundle of His extends from the compact AV node to the membranous interventricular septum and measures approximately 20 mm in length. Today, the most commonly used lead for HBP is the 69 cm Medtronic Select Secure 3830 lead.⁶ This is a non-stylet-driven, active-fixation lead. The lead can be delivered to the His bundle region using either the specially designed nondeflectable sheath or a deflectable sheath. The His signal is targeted, aiming for the local ventricular electrogram to be approximately twice the amplitude

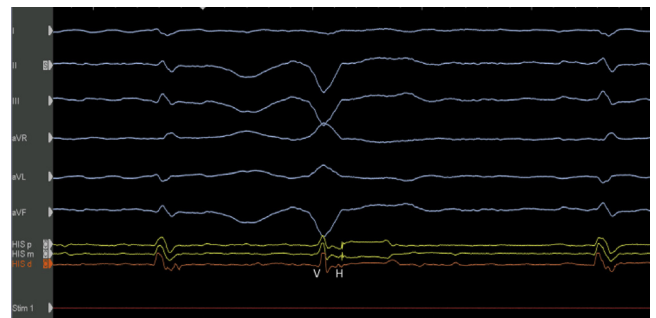


Figure 2 Intraoperative His bundle recording, demonstrating a ventricular escape beat with inapparent His followed by a ventricular premature contraction with a retrograde His deflection.

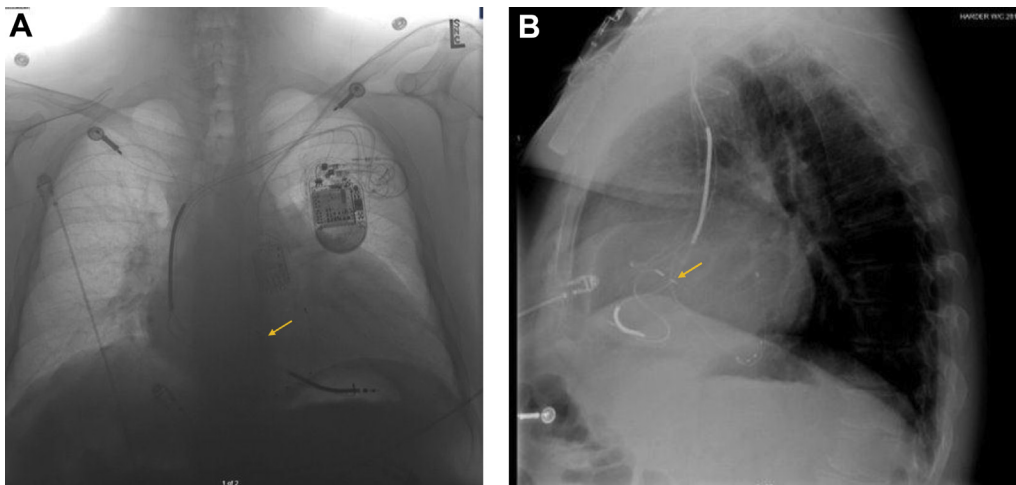


Figure 3 A: A negative image of the patient's chest radiograph, posteroanterior film demonstrating His bundle lead positioning (arrow). B: A lateral radiograph film, demonstrating the His bundle pacing lead (arrow).

of the atrial signal, and adequate His capture is confirmed by observing QRS narrowing on the surface electrocardiogram.

The natural history of patients with uncomplicated L-TGA is progressive RV failure and AV conduction loss over time, resulting in the need for device therapy. Various degrees of CS atresia, variably overt or inapparent, have been reported, which can render cardiac resynchronization therapy delivery challenging.⁷ HBP offers a more physiologic option in this population.

Anderson and colleagues⁸ described anatomic variations in L-TGA based on their examination of pathologic specimens. In these patients, the AV node is typically anteriorly displaced adjacent to the pulmonary valve annulus, with an extended length of His bundle that is concealed and not easily accessible.⁸ The subpulmonary and rightward morphologic LV retains its ribbon-like left bundle, while the systemic and leftward morphologic RV retains its discrete right bundle coursing along the moderator band. Interestingly, dual AV nodes and bundles of His have been noted in some patients with L-TGA. In patients with the usual perimembranous, subpulmonary ventricular septal defect, the bundle of His passes along the anterior and superior rim of the defect in a markedly different location than in hearts with normal anatomy.^{4,9} We recorded a retrograde His bundle potential first from a decapolar His recording catheter and then from the lead, with resultant successful selective His capture, significant QRS narrowing, and an excellent clinical response.

In cases with complex anatomy, HBP can be quite challenging. Here, in this first reported case of HBP in an L-TGA patient with CHB, we describe a technique of His localization using a quadripolar diagnostic catheter to map the retrograde His depolarization prior to lead fixation. Kean and colleagues⁹ have performed HBP in an L-TGA patient, but in their reported case no mapping was used to exactly localize the His. They paced in locations near the usual anatomical location of the His bundle, where they

captured the ventricle with a QRS complex identical to the junctional escape complex, with minimal local myocardial capture and fusion. Our more proactive management strategy was to localize the His bundle during retrograde His activation following VPCs.

Even in the case of CHB, during the patient's native ventricular escape rhythm (if stable), during VPCs, or during ventricular pacing, confirmation of the His bundle's location is possible. Although not required in our case, in cases of inapparent retrograde His deflections owing to brisk ipsilateral bundle branch conduction, ventricular extrastimulation could be useful by inducing entrance block in the ipsilateral bundle branch, with retrograde conduction via the contralateral (nonblocked) bundle branch. This technique may result in a later, more visible, retrograde His deflection.

References

- Šamánek M, Voříšková M. Congenital heart disease among 815,569 children born between 1980 and 1990 and their 15-year survival: a prospective Bohemia survival study. *Pediatr Cardiol* 1999;20:411–417.
- Graham TP, Bernard YD, Mellen BG, et al. Long-term outcome in congenitally corrected transposition of the great arteries: a multi-institutional study. *J Am Coll Cardiol* 2000;36:255–261.
- Baruteau A-E, Abrams DJ, Ho SY, Thambo J-B, McLeod CJ, Shah MJ. Cardiac conduction system in congenitally corrected transposition of the great arteries and its clinical relevance. *J Am Heart Assoc* 2017;6:e007759.
- Graham TP, Markham L, Parra DA, Bichell D. Congenitally corrected transposition of the great arteries: an update. *Curr Treat Options Cardiovasc Med* 2007;9:407–413.
- Deshmukh P, Casavant DA, Romanyshyn M, Anderson K. Permanent, direct His-bundle pacing: a novel approach to cardiac pacing in patients with normal His-Purkinje activation. *Circulation* 2000;101:869–877.
- Ali N, Keene D, Arnold A, Shun-Shin M, Whinnett ZI, Afzal Sohaib SM. His bundle pacing: a new frontier in the treatment of heart failure. *Arrhythmia Electrophysiol Rev* 2018;7:103–110.
- Juneja R, Rowland E, Ho SY. Atrial morphology in hearts with congenitally corrected transposition of the great arteries: implications for the interventionist. *J Cardiovasc Electrophysiol* 2002;13:158–163.
- Anderson RH, Becker AE, Arnold R, Wilkinson JL. The conducting tissues in congenitally corrected transposition. *Circulation* 1974;50:911–923.
- Kean AC, Kay WA, Patel JK, Miller JM, Dandamudi G. Permanent nonselective His bundle pacing in an adult with L-transposition of the great arteries and complete AV block. *Pacing Clin Electrophysiol* 2017;40:1313–1317.