

Rare Occurrence of Prosthetic Knee Septic Arthritis Due to *Streptococcus viridans* in the Background of a Dental Procedure

Tikal Kansara¹, Monica Pernia¹, Yoojin Kim¹, Mohammad Saeed¹

1. Internal Medicine, New York Medical College - Metropolitan Hospital Center, New York, USA

✉ **Corresponding author:** Tikal Kansara, tikal_kansara@yahoo.co.in

Disclosures can be found in Additional Information at the end of the article

Abstract

The American Academy of Oral Medicine, American Dental Association (ADA), in conjunction with the American Academy of Orthopedic Surgeons (AAOS) and the British Society for Antimicrobial Chemotherapy, advises against the universal use of antimicrobial prophylaxis prior to dental procedures for the prevention of prosthetic joint infection (PJI). Here, we discuss the case of a patient with PJI in the background of periodontal scaling, which was done a week prior to presentation to the hospital. The PJI occurred with *Streptococcus (S.) viridans*, a rare organism for PJI but a common oral commensal. As the number of prosthetic joint surgeries are increasing and more data become available, prophylactic antibiotics might be considered to prevent PJI, especially in high-risk patients.

Categories: Orthopedics, Dentistry, Infectious Disease

Keywords: streptococcus viridans, septic arthritis

Introduction

Septic arthritis remains a medical emergency despite advances in antimicrobial and surgical therapy. Although the rate of prosthetic joint infection (PJI) is low after total knee arthroplasty (TKA), with a reported rate of 0.3% - 1.7%, the number of patients with PJI is increasing due to the increase in TKA surgeries [1-3]. In adults, *Staphylococcus aureus* is the most common bacterial source of PJI, found in almost 40% - 60% of cases, followed by beta-hemolytic streptococci and Enterococci [4-5]. Viridans streptococci are rarely associated with PJI [4]. We discuss an unusual case of PJI due to the viridans group.

Case Presentation

A 64-year-old female presented with a three-day history of left knee pain and swelling along with high-grade fever (102.6 F) and chills. She had TKA performed eight years prior to her presentation, followed by a total of three revisions; the last revision was three weeks before the current hospital visit. She had periodontal scaling one week ago. Co-morbidities included hypertension (for five years), diet-controlled diabetes mellitus type 2 (for 10 years), chronic obstructive pulmonary disease, chronic hepatitis C, and opioid dependence. Her home medications included aspirin 81 mg, atorvastatin 10 mg, and methadone 35 mg orally daily.

On the initial presentation, the patient's temperature was 102.6 F, pulse was 122 beats per minute, respiratory rate was 20 per minute, and blood pressure was 125/85 mmHg. Physical examination was normal except for the left knee, which was diffusely erythematous, swollen, warm, and tender.

How to cite this article

Kansara T, Pernia M, Kim Y, et al. (October 24, 2019) Rare Occurrence of Prosthetic Knee Septic Arthritis Due to *Streptococcus viridans* in the Background of a Dental Procedure. *Cureus* 11(10): e5980. DOI 10.7759/cureus.5980

Received 10/10/2019

Review began 10/18/2019

Review ended 10/23/2019

Published 10/24/2019

© Copyright 2019

Kansara et al. This is an open access article distributed under the terms of the Creative Commons Attribution License CC-BY 3.0., which permits unrestricted use, distribution, and reproduction in any medium, provided the original author and source are credited.

Investigations

Her laboratory investigations showed a total leukocyte count of 11.44 cells per cubic millimeter with neutrophilia of 93.58%. C-reactive protein (CRP) was elevated at 15 milligrams per deciliter. Left knee X-ray was suggestive of soft tissue swelling with left knee prosthesis in a satisfactory position without evidence of fracture (Figure 1). Left knee joint arthrocentesis was grossly cloudy in appearance with a white blood cell (WBC) count of 52,800 cells per cubic millimeter, 93% neutrophils, and red blood cells (RBCs) of 177,000 cells per cubic millimeter. Crystal analysis showed calcium pyrophosphate deposition (CPPD). Blood cultures were negative for both aerobic and anaerobic organisms. Synovial fluid culture grew *Streptococcus (S.) viridans* sensitive to tetracycline, vancomycin, levofloxacin, and intermediate sensitivity to penicillin.

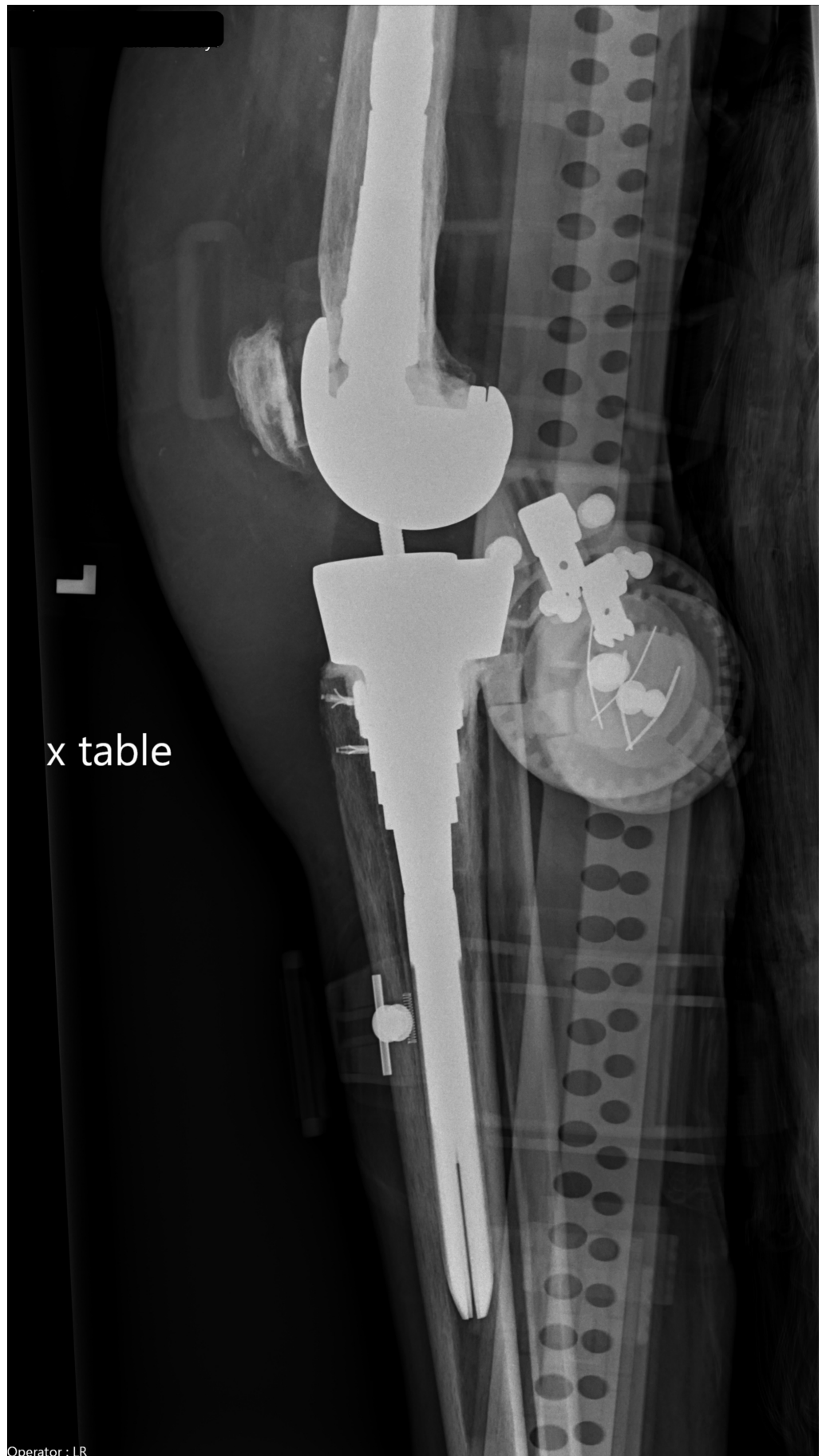


FIGURE 1: Dx left knee

Taking into consideration the patient's recent dental procedure and synovial fluid analysis showing WBCs and neutrophilia, a diagnosis of prosthetic joint infection was established. Risk factors for septic arthritis also included CPPD and diabetes mellitus. As the organism grew on the second day of culture and was sensitive to routine antibiotics, further testing like 16S rRNA sequencing was deferred.

Treatment

The patient was initially started on vancomycin (1 gm; adjusted with serial vancomycin levels) and piperacillin-tazobactam (3.375 gm) and then switched to fluoroquinolones (levofloxacin 750 mg) as per the synovial fluid culture report. She underwent irrigation and debridement of the left knee and exchange of polyethylene with the retention of the left knee prosthesis. The culture of necrotic and inflamed fibro-connective tissue obtained during irrigation and debridement was negative for any growth. She completed a total of six weeks of antibiotics.

Outcome and follow-up

The patient regularly follows up in the clinic without any further significant events.

Discussion

The common organisms in prosthetic joint infections are *Staphylococcus* and beta-hemolytic streptococci [6-9]. Viridans group streptococci are, however, a rare cause of septic arthritis. The *S. viridans* group is a heterogeneous group of organisms, which consists of 26 species [10-11]. The viridans group is part of normal commensal flora and has low virulence. The infection usually occurs on a previously injured focus [10-12]. A comprehensive review of records does not mention viridans group *Streptococcus* as one of the etiological agents for septic arthritis [11,13]. However, isolated cases are discussed, involving joints, mainly including the knee, sternoclavicular, acromioclavicular, sacroiliac, and spondylodiscitis [11-18]. Our patient had an infection of the prosthetic knee joint in the background of dental work-up.

Microscopic analysis and culture of synovial fluid are fundamental diagnostic tools for diagnosis. The cytology of synovial fluid usually shows white blood cells of 100,000 cells per cubic millimeter. However, in some cases, cell counts can be less than 25,000 cells per cubic millimeter; as in our case, which does not rule out the possibility of septic arthritis. In knee arthroplasty, a synovial fluid leukocyte count of more than 17000 had a 94% sensitivity and specificity of 88% for prosthetic joint infection [11,19]. The gold standard for diagnosis is the culture of aspirate fluid or prosthetic joint. Other tests to isolate organism is to isolate sterile samples like synovial fluid into BACTEC (Becton, Dickinson and Company, New Jersey, US) system or pediatric isolator tubes. The 16S rRNA gene sequence analysis is useful for sub-classification.

The choice of treatment is antibiotics. There is no one universal antibiotic regimen that has an advantage over the other based on one systematic review and meta-analysis of antibiotic treatment for joint infections [11,20]. The choice of antibiotic is based on culture and sensitivity. In general, *S. sanguinis* is sensitive to ceftriaxone, *S. mitis* to clindamycin, and *S. anginosus* to both ceftriaxone and clindamycin [1]. Our patient's sensitivity report showed *S. viridans* sensitive to tetracycline, vancomycin, and levofloxacin. The removal of purulent material can be achieved either surgically or through closed needle aspiration. Our patient underwent irrigation and debridement of the left knee and exchange of polyethylene with the retention of left knee prosthesis. Overall, the duration of antibiotics should depend on the acute condition, co-morbidities of the patient, and a multiple of allied factors, but, in general,

at least three weeks of antibiotics is recommended. Our case was unique from all other reported cases as the patient had multiple revisions of the prosthetic joint, which, in itself, acts as a nidus of infection and had a dental procedure a week ago. She did not receive any prophylactic antibiotics prior to the dental procedure. The organism *Streptococcus viridans* is native to the oral cavity, which was found in the joint fluid aspirate.

Conclusions

Although rare, streptococcus viridans is a causative organism for prosthetic joint infection. It occurs commonly in cases with recent procedures, especially of an oral cavity. Our patient had multiple revisions of the prosthetic joint and was diabetic. Even though not recommended, prophylactic antibiotics might be considered for patients with prosthetic joints undergoing a dental procedure, especially those with poor dental hygiene and in an immunocompromised condition. Studies with a large number of patients are required to evaluate, in detail, the cause of *S. viridans* PJI, standardize the line of management, prevent the infection, and define recommendations for prophylactic antibiotics.

Additional Information

Disclosures

Human subjects: Consent was obtained by all participants in this study. **Conflicts of interest:** In compliance with the ICMJE uniform disclosure form, all authors declare the following: **Payment/services info:** All authors have declared that no financial support was received from any organization for the submitted work. **Financial relationships:** All authors have declared that they have no financial relationships at present or within the previous three years with any organizations that might have an interest in the submitted work. **Other relationships:** All authors have declared that there are no other relationships or activities that could appear to have influenced the submitted work.

References

1. Mathur A, Chen AF: Streptococcus viridans periprosthetic joint infections. *Ann Joint.* 2017, 2:
2. Kurtz S, Ong K, Lau E, Mowat F, Halpern M: Projections of primary and revision hip and knee arthroplasty in the United States from 2005 to 2030. *J Bone Joint Surg Am.* 2007, 89:780-785.
3. Bjerke-Kroll BT, Christ AB, McLawhorn AS, Sculco PK, Jules-Elysée KM, Sculco TP: Periprosthetic joint infections treated with two-stage revision over 14 years: an evolving microbiology profile. *J Arthroplasty.* 2014, 29:877-882.
4. Papaioannides D, Boniatsi L, Korantzopoulos P, Sinapidis D, Giotis C: Acute septic arthritis due to *Streptococcus sanguis*. *Med Princ Pract.* 2005, 15:77-79.
5. Peters RHJ, Rasker JJ, Jacobs JWG, Prevo RL, Karthaus RP: Bacterial arthritis in a district hospital. *Clin Rheumatol.* 1992, 11:351-355.
6. Waqar S, Hussain T, Bawarish MA: Knee sepsis caused by *Streptococcus mitis* after dental hygiene therapy in a patient with total knee replacement: a case report. *Curr Orthop Pract.* 2008, 19:586-588. [10.1097/BCO.0b013e328313bba7](https://doi.org/10.1097/BCO.0b013e328313bba7)
7. Tattevin P, Crémieux A, Pottier P, Hutten D, Carbon C: Prosthetic joint infection: when can prosthesis salvage be considered?. *Clin Infect Dis.* 1999, 29:292-295. [10.1086/520202](https://doi.org/10.1086/520202)
8. Gillespie WJ: Prevention and management of infection after total joint replacement. *Clin Infect Dis.* 1997, 25:1310-1317. [10.1086/516134](https://doi.org/10.1086/516134)
9. Ip D, Yam S, Chen C: Implications of the changing pattern of bacterial infections following total joint replacements. *J Orthop Surg.* 2005, 13:125-130. [10.1177/230949900501300204](https://doi.org/10.1177/230949900501300204)
10. Facklam R: What happened to the streptococci: overview of taxonomic and nomenclature changes. *Clin Microbiol Rev.* 2002, 15:613-630.
11. Yombi JC, Belkhir L, Jonckheere S, Wilmes D, Cornu O, Vandercam B, Rodriguez-Villalobos H: *Streptococcus gordonii* septic arthritis: two cases and review of literature. *BMC Infect Dis.* 2012, 12:215. [10.1186/1471-2334-12-215](https://doi.org/10.1186/1471-2334-12-215)

12. Barbadillo C, Trujillo A, Cuende E, Mazzucchelli R, Mulero J: Septic arthritis due to streptococcus viridans. *Clin Exp Rheumatol*. 1990, 8:520-1.
13. Mathews CJ, Kingsley G, Field M, et al.: Management of septic arthritis: a systematic review . *Postgrad Med J*. 2008, 84:265-270. [10.1136/ard.2006.058909](https://doi.org/10.1136/ard.2006.058909)
14. Mata P, Molins A, de Oya M: Sternal arthritis caused by Streptococcus viridans in a heroin addict. *Med Clin (Barc)*. 1984, 83:16.
15. Blankstein A, Amsallem JL, Rubinstein E, Horoszowski H, Farin I: Septic arthritis of the acromioclavicular joint. *Arch Orthop Trauma Surg*. 1985, 103:417-418.
16. Fossaluzza V, Tosato F, Rossi P, Udina P: Bacterial endocarditis caused by Streptococcus viridans disclosed by sacroiliitis [Article in French]. *Rev Rhum Mal Osteoartic*. 1987, 54:79.
17. Weber M, Gubler J, Fahrer H, et al.: Spondylodiscitis caused by Viridans streptococci: three cases and a review of the literature. *Clin Rheumatology*. 1999, 18:417-421. [10.1007/s100670050130](https://doi.org/10.1007/s100670050130)
18. Balsam LB, Shepherd GMG, Ruoff KL, Wiznia AA: Streptococcus anginosus spondylodiskitis . *Clin Infect Dis*. 1997, 24:93-94.
19. Coutlakis PJ, Roberts WN, Wise CM: Another look at synovial fluid leukocytosis and infection . *JCR J Clin Rheumatol*. 2002, 8:67-71.
20. Stengel D, Bauwens K, Sehouli J, Ekkernkamp A, Porzsolt F: Systematic review and meta-analysis of antibiotic therapy for bone and joint infections. *Lancet Infect Dis*. 2001, 1:175-188.