




# The use of image analysis software increases the accuracy of the periacetabular osteotomy fragment placement

Alison J. Dittmer Flemig <sup>1\*</sup>, Anthony Essilfie<sup>2</sup>, Brandon Schneider<sup>2</sup>, Stacy Robustelli<sup>2</sup> and Ernest L. Sink<sup>3</sup>

<sup>1</sup>Department of Orthopedic Surgery, Gillette Children's Specialty Healthcare, 200 University Avenue East, St. Paul, MN 55101, USA, <sup>2</sup>Hospital for Special Surgery, 535 East 70th Street, New York, NY 10021, USA and <sup>3</sup>Department of Hip Preservation, Hospital for Special Surgery, 535 East 70th Street, NY, NY 10021, USA.

\*Correspondence to: A. J. Dittmer Flemig. E-mail: [AlisonDittmer@Gillettechildrens.com](mailto:AlisonDittmer@Gillettechildrens.com)

## ABSTRACT

The purpose of this study was to report on the use of image analysis technology to enhance accuracy of intra-operative imaging and evaluation of periacetabular osteotomy (PAO) correction. This was a retrospective study reporting on the first 25 cases of PAO performed with the use of an image analysis tool. This technology was used intra-operatively to assess the position of the supine coronal image in comparison to pre-operative standing images using a ratio of pelvic tilt (PT). Intra-operative PT, Tönnis angle, lateral center–edge angle (LCEA) and anterior wall index were compared to post-operative images. Post-operative radiographic parameters in the study group were compared with a control group of PAO cases performed prior to the implementation of the new software. The image analysis software was able to obtain intra-operative supine imaging that was equivalent to pre-operative standing imaging. When comparing the PAOs performed with the use of the software versus those without, the study group trended toward being more likely within the surgeon's defined target range of radiographic values, which was statistically significant for LCEA. This tool can be used to assure the surgeon that the intra-operative image being used for surgical decision-making is representative of the functional radiograph. PAOs performed with the use of this technology showed enhanced accuracy of surgical correction for the parameters within our defined target ranges. This may increase the ability of the surgeon to place the acetabular fragment more precisely within his or her goal parameters for acetabular reorientation correction.

## INTRODUCTION

Periacetabular osteotomy (PAO) is a technically challenging operation with emerging guidelines regarding the ideal placement of the acetabular fragment with reorientation [1–5]. Radiographic parameters currently used to determine optimal position include assessment of acetabular retroversion, wall balance, Tönnis angle (TA) and lateral center–edge angle (LCEA) of Wiberg [6–10]. However, these are difficult to directly measure on traditional intra-operative fluoroscopy.

Of these, version and wall balance have been recently suggested to be the most important when considering long-term patient outcomes [2, 4]. Both of these measurements have been shown to be highly influenced by the position of the pelvis at the time of imaging [11–14]. Therefore, it is imperative to ensure that the intra-operative image is equivalent to the pre-operative radiograph for proper surgical decision-making and execution. Imprecise intra-operative imaging could lead to sub-optimal placement and orientation of the acetabular fragment [14–16]. Since many PAO surgeons utilize standing radiographs pre-operatively, this adds an additional challenge intra-operatively when imaging is necessarily performed in a supine position.

PAO surgeons currently use both plain films and fluoroscopy to assess osteotomy correction, based on preference [8, 15, 17, 18]. Our institution's preference has been to utilize fluoroscopy intra-operatively, as we have found that fluoroscopy allows us to more easily adjust the tilt of the beam to match our pre-operative standing radiographs, and have found this helpful in improving operative workflow.

Newer technologic advances in digital radiography have been shown to increase accuracy of acetabular component positioning in total hip arthroplasty [19, 20]. One digital radiography resource (Radlink) is compatible with standard fluoroscopy equipment and includes image analysis and measurement capabilities. It interfaces with the fluoroscopy unit to stitch together multiple fluoroscopic images in real time to obtain a complete coronal view of the pelvis. This allows the surgeon to directly compare and adjust the overall tilt and version of the intra-operative image to be as similar as possible to the pre-operative radiographs. In addition, the system also allows for direct measurement of radiographic parameters on the fluoroscopic images during the surgery.

The main purpose of this study was to report on the use of intra-operative image analysis technology to enhance the

accuracy of intra-operative imaging. Secondly, to assess and compare acetabular correction, based on radiographic parameters, following PAO surgery with and without the use of this technology. Our hypothesis was that the analysis software would increase our ability to obtain identical intra-operative pelvic images compared to standing pre-operative images. Secondly, we hypothesized that the use of this software would enhance the surgeon's ability to achieve radiographic outcomes within a specified range including LCEA, TA, anterior wall index (AWI) and acceptable version assessment.

## MATERIALS AND METHODS

### Patient inclusion

This is an institutional review board-approved study that fell under the scope of our Hip Preservation Registry. Image analysis software (Radlink) was implemented in late 2019 and used whenever technologic resources were available for each PAO after that time point.

The study group consisted of all PAO cases performed with the use of image analysis up to the date of this study. This consisted of 25 consecutive PAOs that underwent surgery between 2019 and 2020, after the standard implementation of this tool. No cases were excluded in this time period. The control group consisted of the 40 consecutive PAO cases performed immediately prior to the implementation of Radlink in late 2019, to minimize any learning curve or experience bias. All surgeries were performed by the senior author (E.S.). All consecutive cases were included in both cohorts, and none were excluded based on the presence or absence of prior or concurrent hip arthroscopy, femoral osteochondroplasty or intra-articular procedures.

Indications for PAO at our institution include radiographic evidence of hip dysplasia with failure of non-operative management and minimal radiographic osteoarthritis (Tönnis grade 0 or 1), in setting of a congruent hip joint on a von Rosen view.

The surgical technique is previously described by the senior author in 2012 [21]. The procedure has since been modified slightly to include a curvilinear incision beginning one centimeter distal and medial to the anterior superior iliac spine and curving cephalad along the iliac spine.

The standard radiographic protocol for the senior author involves routine anteroposterior standing radiographs taken pre-operatively, and at regular intervals post-operatively starting at 6 weeks and continuing at intervals of 3 months, 6 months and then yearly radiographs. For the purpose of this study, pre-operative standing radiographs and 6-month post-operative standing radiographs were included for all patients. LCEA, AWI and TA were recorded for all patients [6, 10, 22]. Version was also classified as acceptable for each patient as adequate if there was an absence of retroversion with no crossover sign, and absence of excessive anteversion ( $AWI < 0.1$ ) [2, 6, 7].

### Intra-operative digital radiography and analysis technique

The Radlink software system interfaces with traditional fluoroscopy intra-operatively and is able to stitch incremental fluoroscopic images together in order to obtain a complete coronal image of the entire pelvis in real time, theoretically eliminating parallax distortion [23]. Additionally, it allows for direct digital measurements on its system.

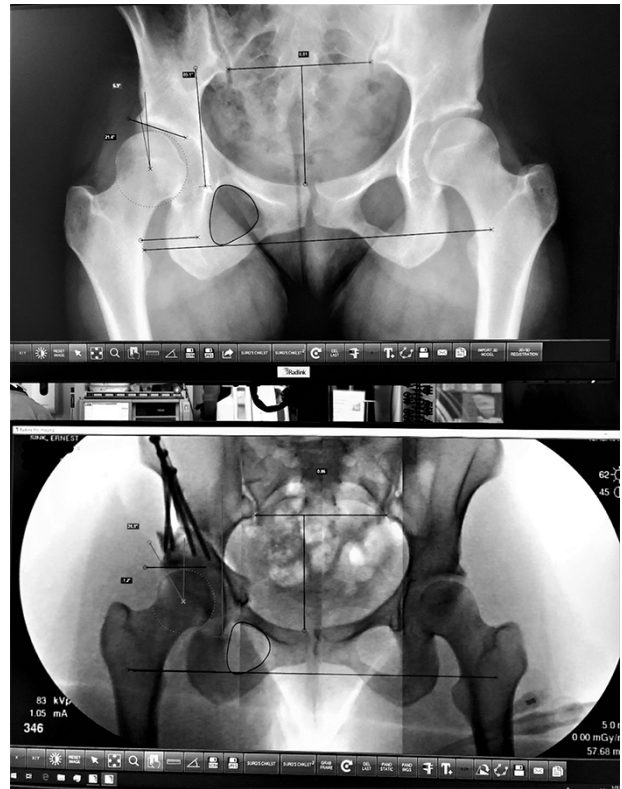


Fig. 1. Intra-operative configuration with pre-operative AP pelvis radiograph on top panel, and intra-operative stitched fluoroscopic digital image on bottom panel.

After a preliminary osteotomy correction was achieved, a fluoroscopic image centered on the pelvis was taken and corrected for rotational alignment with the goal of the coccyx being centered to the pubic symphysis. The quality of the image with regard to pelvic tilt (PT) (inlet or outlet) was then directly compared by matching a ratio of the pelvic width versus height on the pre-operative standing radiograph with the image intra-operatively using the image analysis system (Fig. 1). The tilt of the beam was then adjusted in order to achieve an intra-operative PT that was equal to the pre-operative PT ratio, as described in previous work [24]. In these cases, a ratio slightly less than the pre-operative PT (i.e. more outlet) was preferred to being slightly greater than pre-operative PT (i.e. more inlet).

After PT was adjusted to be within range, three additional fluoroscopic images were obtained consecutively from the operative to the non-operative hip, to include the full width of the pelvis. These images were stitched together to obtain an equivalent entire coronal view of the pelvis using fluoroscopy. Once the image was reconstructed, the LCEA, AWI and TA were measured, and the process was repeated until the desired correction was achieved.

### Study group

TA, LCEA and AWI were measured on all intra-operative stitched fluoroscopic images by a trained professional using the Radlink system with approval of the operating surgeon. Version was also classified as 'adequate' or 'inadequate' at 6 months as described above.

**Table I. Summary of postoperative radiographic measurements in both groups**

Variable	Study group					Control group				
	Mean	SD	Median	Min	Max	Mean	SD	Median	Min	Max
LCEA	35.1	2.63	35	40	30	35.6	4.1	36.7	26.8	42.9
TA	-2.47	4.44	-3.1	-8.9	13.7	-2.81	4.62	-3.15	-9.7	14.2
AWI	0.31	0.09	0.32	0	0.47	0.31	0.08	0.31	0.08	0.43

**Table II. Agreement between intra-operative Radlink imaging and 6-month post-operative PACs imaging**

Radiographic measurement	Mean difference	(95% CI)	P	ICC	(95% CI)	P
LCEA	2.21	(0.69 to 3.27)	0.006	0.79	(0.58 to 0.9)	<0.001
TA	-3.71	(-5.15 to -2.27)	<0.001	0.33	(-0.07 to 0.63)	0.05
AWI	-0.03	(-0.06 to 0.01)	0.201	0.36	(0.03 to 0.65)	0.03
PT (Po-I)	-0.04	(-0.07 to -0.01)	0.013	0.82	(0.64 to 0.92)	<0.001
PT (I-Pr)	-0.05	(-0.08 to -0.02)	0.005	0.84	(0.67 to 0.93)	<0.001

CI = confidence interval, Po-I = post-operative to intra-operative imaging, I-Pr = intra-operative to pre-operative imaging.

**Table III. Equivalence testing for pre-operative, intra-operative and post-operative PT**

Comparison	Mean difference	95% CI	P
Post-Pre	-0.01	(-0.04 to 0.02)	<0.001
Intra-Pre	0.03	(0.02 to 0.05)	<0.001
Post-Intra	-0.04	(-0.07 to -0.01)	<0.001

Post = post-operative, pre = pre-operative, intra = intra-operative.

The intra-operative LCEA, TA, PT and AWI measured on Radlink were then compared to 6-month post-operative radiographic measurements as measured with conventional methods via our institution's picture archiving and communication system (PACs) on post-operative radiographs (Table II). These measurements were performed by a hip preservation fellow who had previously completed a pediatric orthopedic fellowship. Equivalence testing for PT at all time points at a margin of error <0.1 was performed in order to assess the ability of the software to help replicate pre-operative PT intra-operatively and at 6 months post-operatively (Table III).

### Control group

The control group consisted of 40 consecutive PAOs prior to the institution of the Radlink system in 2019. Intra-operative measurements could not be obtained secondarily to the constraints of using standard fluoroscopy alone. TA, LCEA, AWI and version (as described above) were recorded on 6-month standing post-operative radiographs.

### Comparison between study and control groups

As there is no 'gold standard' for the radiographic parameters describing the ideal placement of the osteotomy fragment, previously reported normative data in coordination with the senior author's experience were used to define a range of 'target' values for LCEA, TA, AWI and acceptable version [2]. The parameters of LCEA within 25–40°, TA between -5° and 10°, AWI between 0.30 and 0.51 and acceptable version as defined as both by an

**Table IV. Mean differences for each radiographic parameter between the study and control groups**

Measurement	Difference (study-control)	95% CI	P
LCEA	-0.03	-0.07, 0.01	0.197
TA	-0.94	-3.17, 1.28	0.383
AWI	-0.03	-0.07, 0.01	0.201

**Table V. The proportion of cases within target range between the study and control groups**

Variable	Study	Control	P
LCEA	21 (84%)	31 (78%)	0.888
TA	15 (60.0%)	28 (70%)	0.407
AWI	13 (52%)	23 (58%)	0.664
Version	23 (92%)	33 (83%)	0.244

absence of retroversion and exclusion of excessive anteversion (AWI < 0.1) were used in this study [2, 6, 7, 9]. The proportions of patients who fell within the defined ranges for each radiographic variable were compared between cohorts (Table V).

### Statistical analysis

Differences between intra-operative and post-operative measurements in the study group were compared using the paired-samples *t*-test in Table II. Additionally, equivalence testing for PT at all time points at a margin of error <0.1 was performed (Table III).

Measurements at 6-month post-operative radiographs were compared between the study and control groups using a two-sample *t*-test in Table IV. The proportion of cases within each defined radiographic range was compared using a chi-square or Fisher's exact test as appropriate in Table V. Histograms with density (bell) curves of the data in Table V, broken down by group, were constructed and are shown in Fig. 2.

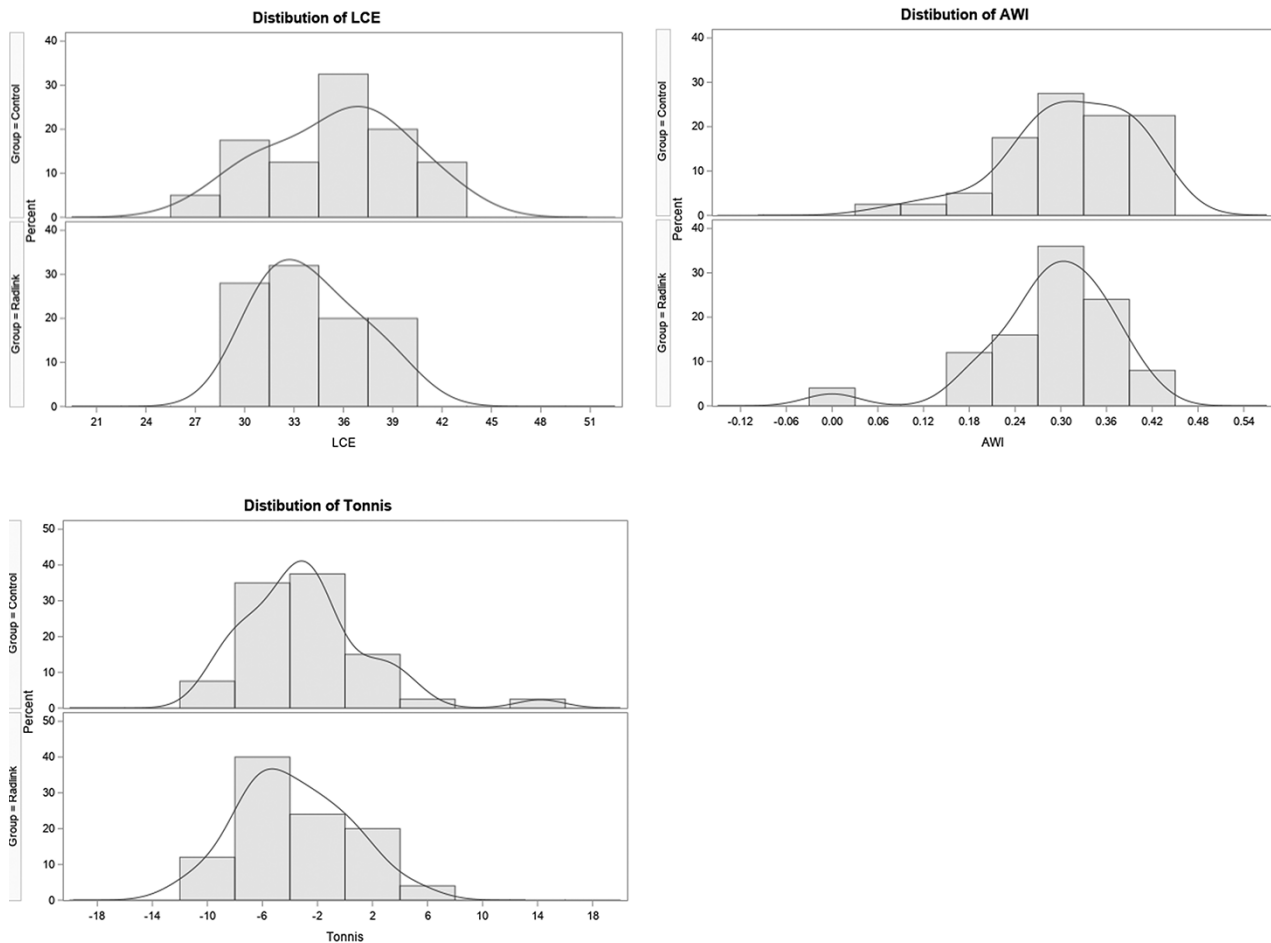


Fig. 2. Histogram showing the distribution of radiographic values in the control and study groups for LCE, TA and AWI.

## RESULTS

The observed post-operative radiographic data for LCEA, TA, and AWI for both the control and study groups are summarized in Table I. PT was equivalent across all three time points, indicating that we were able to obtain supine intra-operative coronal plane imaging using the intra-operative PT ratio equivalent to both pre-operative and post-operative standing imaging (Table III).

When examining the study group, the AWI did not differ significantly between intra-operative and post-operative imaging, although a small but significant difference in TA ( $-3.71^\circ$ ,  $P < 0.001$ ) and LCEA was observed ( $2.21^\circ$ ,  $P = 0.006$ ) (Table II). Intra-class correlation coefficients (ICCs) for LCEA, Tönnis and AWI were 0.79–0.36 (Table II); however, the proportion of cases within  $3^\circ$  compared intra-operatively to post-operatively was 100% (LCEA) and 64% (TA), and proportion of AWI within 0.1 was 76%.

At 6 months, post-operative radiographic continuous differences for LCEA, TA and AWI between the study and control groups did not significantly differ (Table IV). LCEA did statistically improve in the study group; however, no statistically significant differences in the proportion of cases within our defined target range for TA, AWI or version in the study group were found when compared to the control group (Table V).

The use of the image analysis software did overall result in a narrower range of values for each radiographic parameter (Fig. 2).

## DISCUSSION

Overall, the use of the image analysis software in our study had two main important functions: to help provide an accurate way of obtaining intra-operative imaging equivalent to our pre-operative imaging including PT and to enhance acetabular correction accuracy in multiple planes compared to using intra-operative fluoroscopy alone.

The use of this technology did overall result in a narrower range of values for each radiographic parameter, indicating that the software helped improve the accuracy of surgical correction for each measurement within our defined target ranges (Fig. 2).

There is still debate concerning the most appropriate imaging to use when evaluating hip pain (standing versus sitting) [15]. However, regardless of which position the surgeon chooses to have pelvis radiographs taken pre-operatively, the software such as the system used in our study allows the surgeon to closely replicate the pre-operative image, thus aiding in intra-operative decision-making.

Several studies have been published demonstrating the use of fluoroscopy alone in evaluating intra-operative positioning of the

PAO fragment with good results [8, 17, 18]. One work found that agreement between fluoroscopy and post-operative radiographs ranged from 0.63 to 0.80 for multiple different acetabular measurements including LCEA, TA, anterior center-edge angle (ACEA), AWI and posterior wall index [8]. Two others reported moderate to high correlations of TA, ACEA and LCEA when comparing intra-operative and post-operative imaging [17, 18]. In this study, we did find lower ICCs for Tönnis and AWI when comparing intra-operative to post-operative imaging than previously reported (Table II). However, LCEA was within 3° in 100% of cases, TA was within 3° in 64% of cases and AWI was within 0.1 in 76% of cases. When looking at cases upon which LCEA did disagree, in two instances on acetabuli were measured differently and in four instances, re-measurement of either the intra-operative or post-operative radiograph with replacement of the femoral head circle resulted in closer measurements.

In this current work, we found a mean difference of -0.03 in AWI when comparing our 6-month post-operative radiograph to intra-operative imaging data which was not statistically significant, indicating the intra-operative measurement would reliably predict the 6-month post-operative AWI. We found a difference of -3.71° for TA and 2.21° for LCEA, which were statistically but are not clinically significant. This is in comparison to mean differences reported in one study as LCEA of -2°, TA 2° and AWI of 0.02 [8].

The advantage that this software may provide is in those measurements directly or indirectly indicative of acetabular version. Importantly, the acetabular version that is dependent on PT can be better evaluated intra-operatively with image analysis technology, as we found that the software was able to accurately represent the PT on pre-operative and post-operative standing radiographs.

Although there is still no definitive conclusion about the 'optimal' placement of the acetabular fragment in the setting of PAOs, normative data exist for the parameters used in this study. Long-term outcomes from PAO surgery are likely to be at least partly directly impacted by position of the osteotomy fragment [1, 2, 25].

Regardless of which target range of radiographic parameters each individual surgeon believes to be ideal for PAO placement, the use of image analysis can increase the ability to achieve values within defined parameters intra-operatively. Our study showed that overall, the use of this software did increase the ability of the surgeon to place the fragment within a specified target range for commonly used radiographic parameters as shown in the histograms depicting these data in Fig. 2.

In a recently published article reviewing radiographic predictors of PAO survivorship, ACEA was shown to be significantly indicative of survivorship [2]. ACEA was not included in the current study secondary to lack of access to all false profile intra-operative imaging retrospectively. Throughout the time course of this study, the protocol has now evolved to routinely obtaining, measuring and documenting anterior center-edge digital radiographic images intra-operatively on every patient. Because this study represents the first 25 cases using the software, the data set included is not fully representative of the current protocol that evolved throughout the use of this tool.

There were several limitations to this study. Both cohorts had small numbers of patients, which may have prevented us from seeing a statistical difference that exists or does not exist were more cases available to be included in the study. The second limitation to this study is the lack of a validated acceptable range of difference for the PT ratio using the image analysis software. Obviously identical intra-operative and pre-operative PT ratios would indicate the best intra-operative imaging quality. However, intra-operatively we did note a parallax effect when obtaining the separate images in order to stitch together a complete coronal view of the pelvis. Consequently, in some cases an intra-operative PT ratio within 0.1 of the pre-operative ratio was deemed acceptable. The significance of this margin of difference is unknown, but this specific technique has been validated in the arthroplasty literature for acetabular component positioning in both anteversion and abduction, which is similarly reliant on the quality of intra-operative PT [15, 19, 20]. Regardless it did not affect prediction of AWI, acetabular version or 6-month PT accuracy.

We recommend that if an intra-operative pelvic tilt ratio is used that is not identical to the pre-operative pelvic tilt, this image should err on the side of more outlet rather than more inlet. This will ensure that the anterior wall coverage is not inadvertently overestimated on intra-operative imaging and subsequently decrease the risk of inadvertent insufficient anterior correction.

Finally, although we hypothesize that outcomes are related to the degree and ability by which we are able to correct the acetabular dysplasia, patient-reported outcomes were outside of the scope of the current study.

Most importantly, this study demonstrated that using the digital radiography system ensured that there was no change between PT, AWI, or LCEA when comparing intra-operative and post-operative imaging. This allows the surgeon to have confidence that, with a properly positioned image, the radiographic measurements that were satisfactory intra-operatively will not appear differently post-operatively. This may be particularly helpful early in the learning curve of PAO surgeons to give them instant feedback on the acetabular correction.

In conclusion, the use of image analysis technology is an effective way of obtaining intra-operative images representative of pre-operative functional imaging and may improve our ability to judge intra-operative positioning of the acetabular fragment. Our study demonstrated that the use of image analysis software may enhance the precision of obtaining radiographic correction in multiple planes within a defined target range.

## DATA AVAILABILITY

The authors confirm that the data supporting the findings of this study are available within the article and within the Hip Preservation Registry at the author's institution. Raw data is available upon request from the corresponding author (A.D.).

## ACKNOWLEDGEMENTS

None declared.

## CONFLICT OF INTEREST STATEMENT

None declared.

## FUNDING

The authors have received no funding or financial support for this work.

## REFERENCES

- Wells J, Schoenecker P, Duncan S *et al*. Intermediate-term hip survivorship and patient-reported outcomes of periacetabular osteotomy: the Washington University experience. *J Bone Joint Surg Am* 2018; **100**: 218–25.
- Wyles CC, Vargas JS, Heidenreich MJ *et al*. Hitting the target: natural history of the hip based on achieving an acetabular safe zone following periacetabular osteotomy. *JBJS* 2020; **102**: 1734–40.
- Wells J, Millis M, Kim Y-J *et al*. Survivorship of the Bernese periacetabular osteotomy: what factors are associated with long-term failure? *Clin Orthop Relat Res* 2017; **475**: 396–405.
- Albers CE, Steppacher SD, Ganz R *et al*. Impingement adversely affects 10-year survivorship after periacetabular osteotomy for DDH. *Clin Orthop Relat Res* 2013; **471**: 1602–14.
- Hayashi S, Hashimoto S, Matsumoto T *et al*. Overcorrection of the acetabular roof angle or anterior center–edge angle may cause decrease of range of motion after curved periacetabular osteotomy. *J Hip Preserv Surg* 2020; **7**: 583–90.
- Siebenrock KA, Kistler L, Schwab JM *et al*. The acetabular wall index for assessing anteroposterior femoral head coverage in symptomatic patients. *Clin Orthop Relat Res* 2012; **470**: 3355–60.
- Tannast M, Hanke MS, Zheng G *et al*. What are the radiographic reference values for acetabular under- and overcoverage? *Clin Orthop Relat Res* 2015; **473**: 1234–46.
- Wylie JD, Ferrer MG, McClincy MP *et al*. What is the reliability and accuracy of intraoperative fluoroscopy in evaluating anterior, lateral, and posterior coverage during periacetabular osteotomy? *Clin Orthop Relat Res* 2019; **477**: 1138–44.
- Hanson JA, Kapron AL, Swenson KM *et al*. Discrepancies in measuring acetabular coverage: revisiting the anterior and lateral center edge angles. *J Hip Preserv Surg* 2015; **2**: 280–6.
- Wiberg G. Studies on dysplastic acetabula and congenital subluxation of the hip joint: with special reference to the complication of osteoarthritis. *Acta Chir Scand* 1939; **83**: 1–135.
- Siebenrock KA, Kalbermatten DF, Ganz R. Effect of pelvic tilt on acetabular retroversion: a study of pelvis from cadavers. *Clin Orthop Relat Res* 2003; **407**: 241–8.
- Tannast M, Fritsch S, Zheng G *et al*. Which radiographic hip parameters do not have to be corrected for pelvic rotation and tilt? *Clin Orthop Relat Res* 2015; **473**: 1255–66.
- Tannast M, Zheng G, Anderegg C *et al*. Tilt and rotation correction of acetabular version on pelvic radiographs. *Clin Orthop Relat Res* 2005; **438**: 182–90.
- Troelsen A, Jacobsen S, Rømer L *et al*. Weightbearing anteroposterior pelvic radiographs are recommended in DDH assessment. *Clin Orthop Relat Res* 2008; **466**: 813–9.
- Kosuge D, Cordier T, Solomon LB *et al*. Dilemmas in imaging for periacetabular osteotomy: the influence of patient position and imaging technique on the radiological features of hip dysplasia. *Bone Joint J* 2014; **96-b**: 1155–60.
- Roussot MA, Salih S, Grammatopoulos G *et al*. What is the pelvic tilt in acetabular dysplasia and does it change following peri-acetabular osteotomy? *J Hip Preserv Surg* 2021; **7**: 777–85.
- Lehmann CL, Nepple JJ, Baca G *et al*. Do fluoroscopy and postoperative radiographs correlate for periacetabular osteotomy corrections? *Clin Orthop Relat Res* 2012; **470**: 3508–14.
- Wylie JD, Ross JA, Erickson JA *et al*. Operative fluoroscopic correction is reliable and correlates with postoperative radiographic correction in periacetabular osteotomy. *Clin Orthop Relat Res* 2017; **475**: 1100–6.
- Penenberg BL, Samagh SP, Rajae SS *et al*. Digital radiography in total hip arthroplasty: technique and radiographic results. *J Bone Joint Surg Am* 2018; **100**: 226–35.
- Hambright D, Hellman M, Barrack R. Intra-operative digital imaging: assuring the alignment of components when undertaking total hip arthroplasty. *Bone Joint J* 2018; **100-b**: 36–43.
- Tibor LM, Sink EL. Periacetabular osteotomy for hip preservation. *Orthop Clin North Am* 2012; **43**: 343–57.
- Tonnis D. *Congenital Dysplasia and Dislocation of the Hip in Children and Adults*. Berlin: Springer, 1987.
- Composite radiographic image that corrects effects of parallax distortion. USA patent 10,748,319. 2020.
- Penenberg B, Samagh S, Rajae S *et al*. Digital radiography in total hip arthroplasty technique and radiographic results. *JBJS* 2018; **100-A**: 226–35.
- Hartig-Andreasen C, Troelsen A, Thillemann TM *et al*. What factors predict failure 4 to 12 years after periacetabular osteotomy? *Clin Orthop Relat Res* 2012; **470**: 2978–87.