


The role of cardiopulmonary exercise testing in identifying and monitoring pulmonary veno-occlusive disease: a case report

Teresa Segura de la Cal ^{1,2,3,4,5,6}, Carmen Pérez-Olivares^{1,2,3,4,5},
María José Cristo Ropero⁷, Raquel Luna López^{1,2,3,4,5,6}, and
Pilar Escribano-Subías^{1,2,3,4,5*}

¹Department of Cardiology, Hospital Universitario 12 de Octubre, Madrid, Spain; ²Ciber-CV Centro de investigación Biomédica en Red de Enfermedades Cardiovasculares, Madrid, Spain; ³Centro de Referencia Nacional de Hipertensión Pulmonar Compleja, Madrid, Spain; ⁴ERN-Lung-Pulmonary Hypertension Referral Center, Madrid, Spain; ⁵Centro de Referencia nacional de Cardiopatías Congénitas del Adulto, Madrid, Spain; ⁶Instituto de Investigación Sanitaria del Hospital Universitario 12 de Octubre (Imas12), Red SAMID, Madrid, Spain; and ⁷Department of Cardiology, Hospital de Torrejón, Madrid, Spain

Received 7 December 2021; first decision 5 January 2022; accepted 26 March 2022; online publish-ahead-of-print 28 March 2022

Background

Pulmonary veno-occlusive disease (PVOD) is a subgroup of pulmonary arterial hypertension (PAH) where vascular remodelling affects mainly the post-capillary vessels. It is characterized by a particularly worse prognosis and by the risk of developing life-threatening pulmonary oedema, especially after PAH-targeted therapy. Therefore, suspicion of PVOD is crucial to guide the patient's management. In the absence of specific genetic or histological findings, diagnosis has traditionally relied on the recognition of non-invasive indicators associated with a high likelihood of PVOD. The cardiopulmonary exercise testing (CPET) arises as a promising additional tool both to identify these patients and to guide their management.

Case summary

We report the case of a young female patient with dyspnoea and clinical suspicion of PVOD. The diagnostic workup is thoroughly described stressing the valuable and readily accessible information that CPET can provide, in addition to the data of radiological and lung function tests. Once diagnosed, she was started on PAH-targeted therapy with subsequent improvement. The patient underwent a complete reassessment with satisfactory findings, including those of the CPET.

Discussion

Pulmonary veno-occlusive disease diagnosis is still one of the most difficult tasks that pulmonary hypertension physicians have to deal with. An accurate and timely PVOD diagnosis can be challenging, as it is to decide the most appropriate timing of referral to the lung transplant team, and CPET may serve these purposes. Through this case, we would like to review one of the typical clinical courses that PVOD may present and how to analyse the information provided by the diagnostic tests.

Keywords

Cardiopulmonary exercise test • CPET • Pulmonary veno-occlusive disease • Pulmonary arterial hypertension • EIF2AK4

ESC Curriculum

6.7 Manage a patient with right heart dysfunction • 9.6 Manage a patient with pulmonary hypertension • 9.7 Manage a patient with adult congenital heart disease

* Corresponding author. Email: pilar.escribano.subias@gmail.com

Handling Editor: Amardeep Ghosh Dastidar

© The Author(s) 2022. Published by Oxford University Press on behalf of European Society of Cardiology.

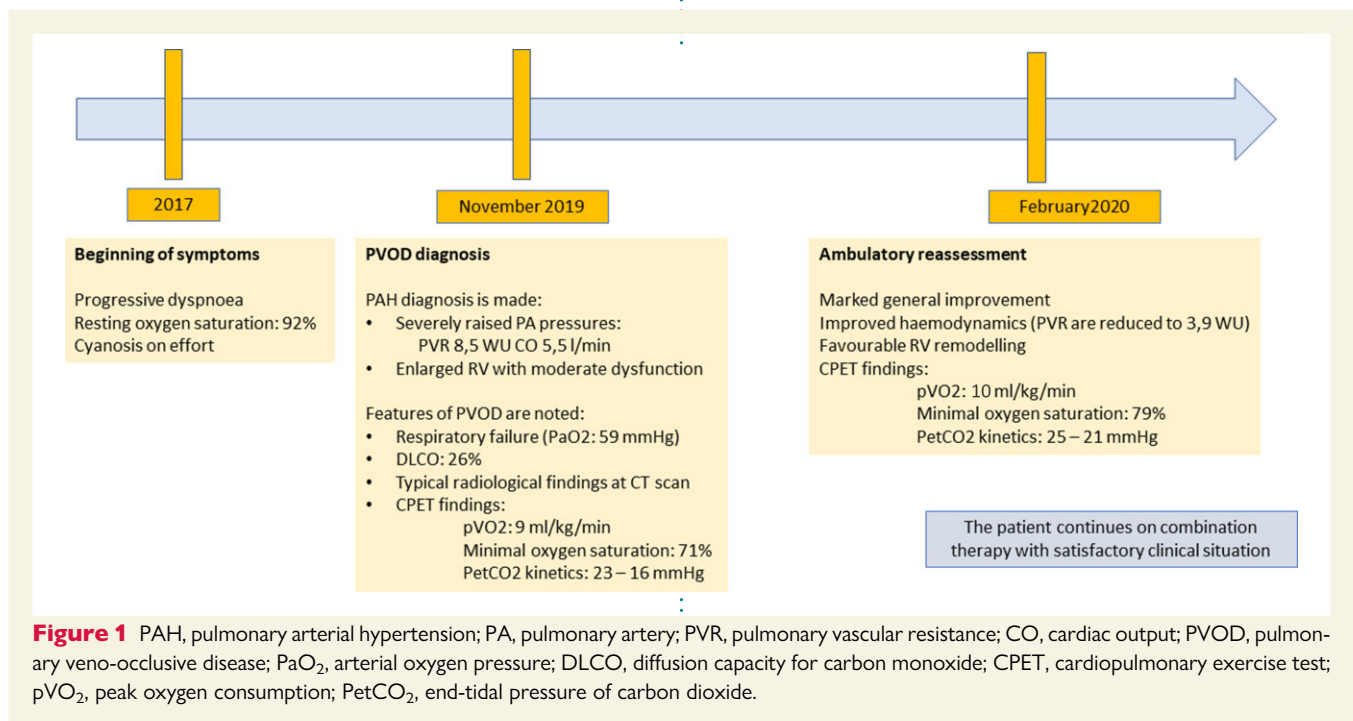
This is an Open Access article distributed under the terms of the Creative Commons Attribution-NonCommercial License (<https://creativecommons.org/licenses/by-nc/4.0/>), which permits non-commercial re-use, distribution, and reproduction in any medium, provided the original work is properly cited. For commercial re-use, please contact journals.permissions@oup.com

Learning points

- Pulmonary veno-occlusive (PVOD) disease may present in different forms with different degrees of haemodynamic and ventilatory impairment.
- A disproportion between the haemodynamic severity and the functional and ventilatory impairment exhibited at the cardiopulmonary exercise testing (CPET) may raise suspicion of an underlying PVOD.
- Reassessment of PVOD patients should include a CPET to correlate the haemodynamic findings with the functional status so a better roadmap can be designed for their management.

Timeline

Figure 1



Case presentation

We present a 37-year-old-female who complained of exertional dyspnoea accompanied by cyanosis on mild to moderate exercise. Her past medical history was unremarkable. On physical examination, resting oxygen saturation was 92%, cardiac auscultation revealed a loud second heart sound, lungs were clear, and there was no evidence of congestion. The ECG revealed sinus rhythm, right axis deviation of the QRS, and T wave inversion in the right precordial leads. The echocardiogram demonstrated an enlarged right ventricle (RV) with moderate dysfunction and systolic flattening of the interventricular septum. The arterial blood gas test showed low arterial oxygen pressure (PaO₂) (59 mmHg). The patient was admitted for a complete diagnostic workup. The combination of the exploratory and echocardiographic findings, along with the low resting PaO₂ and the cyanosis on effort, raised suspicion of pulmonary arterial hypertension (PAH) and, more specifically, of pulmonary veno-occlusive disease (PVOD). The right heart catheterization (RHC) confirmed severe pre-capillary pulmonary hypertension (PH): mean pulmonary

artery (PA) pressure: 51 mmHg, pulmonary vascular resistance (PVR): 8.5 WU, and preserved cardiac output (CO). Blood tests were normal and ruled out PAH-associated causes such as HIV or autoimmune diseases. Pulmonary veno-occlusive disease was considered the most probable diagnosis, so special attention was paid to the lung function tests and computerized tomography (CT) scan results. It was noteworthy that the diffusion capacity for carbon monoxide (DLCO) was severely reduced (26%), and the CT scan showed the typical PVOD findings (see [Supplementary material online](#)). The cardiopulmonary exercise testing (CPET) exhibited a severely reduced functional capacity with a peak oxygen consumption (PVO₂) of 9 mL/kg/min (37% predicted), profound desaturation on effort (SatO₂: 71%), and signs of severe ventilatory impairment, namely the abrupt increase in VE/VCO₂ values from the onset of exercise, instead of its usual initial fall; a high VE/VCO₂ slope at 57, and a severe reduction of PetCO₂ values with even a downward trend over the test [initial PetCO₂: 23 mmHg, final: 16 mmHg ([Figure 2](#))]. Pulmonary arterial hypertension-specific therapy was slowly initiated while monitoring for signs of pulmonary congestion. Sildenafil was

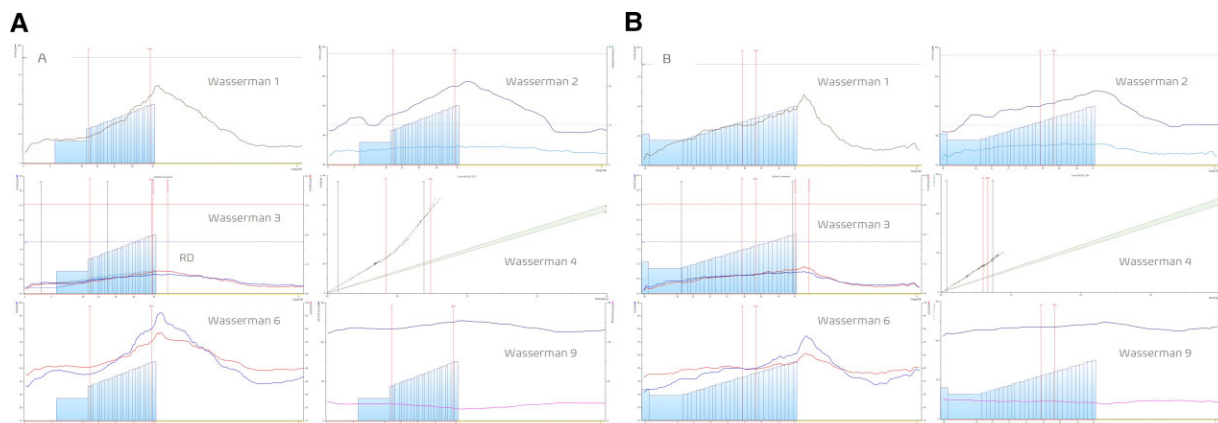


Figure 2 Cardiopulmonary exercise test at diagnosis (left-sided panel) and at reassessment (right-sided panel). Only Wasserman panels 1, 2, 3, 4, 6, and 9 are shown. Ventilation increases abruptly at the first cardiopulmonary exercise test, while its increase is gradual at reassessment (Wasserman panel 1). The oxygen pulse (O_2 Pulse) curve is flattened in both studies, but the heart rate has to increase to a greater extent at diagnosis (Wasserman panel 2). Peak oxygen consumption (PVO_2) is slightly higher at reassessment (9 mL/kg/min, 37% of predicted vs. 10 mL/kg/min, 39% of predicted). Importantly, post-exercise oxygen uptake recovery delay is longer at diagnosis in keeping with a worse clinical status (Wasserman panel 3). Wasserman panels 4, 6, and 9 reflect the severe ventilatory inefficiency that is present in PVOD patients. The minute ventilation/carbon dioxide production (VE/VCO_2) slope is elevated (Wasserman panel 4). The ventilatory equivalents for carbon dioxide (VE/VCO_2) and oxygen (VE/VO_2) are increased in both studies (Wasserman panel 6). Moreover, they lose their usual behaviour and increase from the beginning of the exercise; however, this increase is more abrupt at diagnosis. The end-tidal pressure of carbon dioxide ($PetCO_2$) is reduced at rest and exhibits a downward trend during the incremental exercise (Wasserman panel 9), but this abnormal pattern is more pronounced at diagnosis.

started along with diuretics. This was extremely well tolerated, so macitentan 10 mg was added. The patient was finally discharged on combination therapy, supplemental oxygen, and diuretics, with a carefully planned close follow-up. Importantly, an evaluation for a possible lung transplantation was requested to the respiratory team, and a genetic study was solicited.

A complete reevaluation was scheduled 4 months later. The genetic results revealed a pathogenic biallelic mutation in EIF2AK4. At that time, the patient reported marked symptomatic amelioration. The repeated RHC showed significant improvement: mean PA pressure dropped to 36 mmHg and PVR to 3.9 WU. The echocardiogram demonstrated favourable RV remodelling. Interestingly, although the CPET values were still in the severe range both for functional and for ventilatory impairment, the behaviour of most of the curves improved (Figure 2): (i) PVO_2 increased to 10 mL/kg/min (39% predicted) and showed a shorter post-exercise recovery delay, (ii) VE/VCO_2 slope was similar, but the morphology of the ventilatory equivalents curves changed significantly, exhibiting a less steep profile, (iii) $PetCO_2$ kinetics showed a more flattened behaviour with higher values at peak exercise (initial $PetCO_2$: 25 mmHg, final: 21 mmHg). This slight improvement was accompanied by a less pronounced desaturation (minimal: 79%). Considering this information, it was agreed to keep the patient off the transplant list and to maintain the same treatment. Two years later, she remains stable with a good subjective quality of life.

Discussion

Pulmonary veno-occlusive disease is characterized by a deeply disrupted alveolo-capillary membrane and by a pulmonary vascular

remodelling that affects mainly the post-capillary vessels. Hence, standard PAH-specific treatment may precipitate life-threatening pulmonary congestion because arterial vasodilation increases blood flow in the setting of obstructed venules. It is important to suspect this venular involvement in order to tailor the patient's treatment, which needs a delicate balance between PAH-specific therapy, diuretics, and oxygen administration.^{1,2}

A definite PVOD diagnosis may be established from the histologic examination of a lung specimen and/or the identification of biallelic mutations in the EIF2AK4 gene.³ Unfortunately, the majority of patients do not present a genetic mutation, and the risk of a lung biopsy appears prohibited in these patients. Therefore, hints to suspect a post-capillary involvement need to be drawn from the clinical history and investigations and have traditionally included the following: (i) lower resting oxygen saturation in PVOD compared with IPAH patients; (ii) a more profound desaturation on effort; (iii) a more severe reduction in DLCO levels (reflecting the poor status of the alveolo-capillary barrier); and (iv) Specific radiological findings such as mediastinal lymph node enlargement (translating the dilation of the lymphatic vessels), centrilobular ground-glass opacities, and smooth thickening of the interlobular septa (which probably result from the alveolar septal thickening and associated hyperplasia of the lining epithelium).³ In order to refine the non-invasive diagnosis of PVOD, our group has recently published its experience with 23 PVOD patients. We found that a disproportion between the haemodynamic severity and both the functional and ventilatory impairment depicted at the CPET may raise suspicion of PVOD.⁴ Besides diagnosis, the course of PVOD is difficult to predict and manage. Response and tolerance to PAH treatment vary greatly among PVOD patients, and many maintain disabling respiratory insufficiency despite a

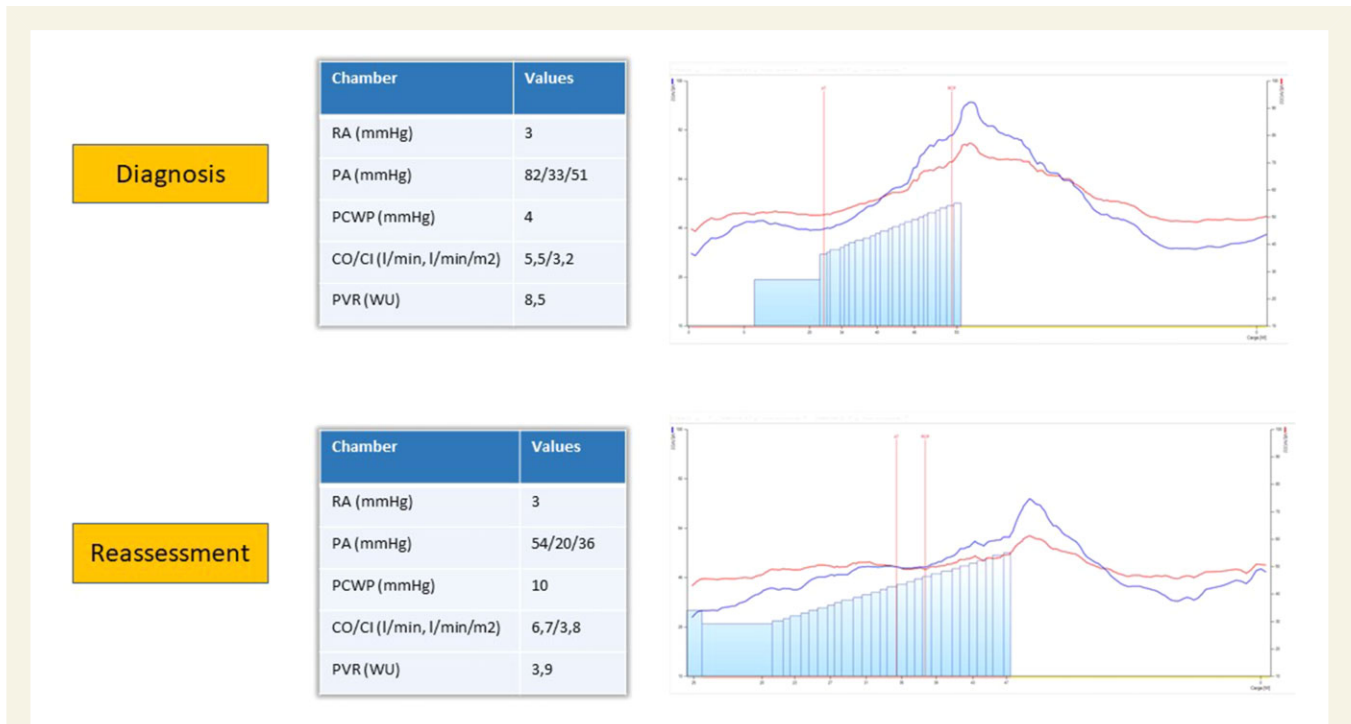

Figure 3 The changes in haemodynamics and in exercise performance patterns can be noted. (Upper panel) The pulmonary pressures are severely elevated. The morphology of the curves for the ventilatory equivalents shows a steep increase from the beginning of the test. (Lower panel) The pulmonary pressures have dropped significantly. The ventilatory equivalents still present an abnormal behaviour but a less marked increase throughout the test.

haemodynamic improvement.⁵ Therefore, lung transplantation remains the only option in some cases, and it is important to identify the perfect timing for their inclusion in the transplant list.

Our patient presented severe PAH at diagnosis, although the degree of functional and ventilatory impairment was considered excessive for a young patient with a good CO. Moreover, the morphology of the curves for the ventilatory equivalents with such a steep slope is not usually encountered in PH patients unless we are dealing with an extremely severe PAH or severe thromboembolic PH, another paradigm of ventilatory impairment. In terms of follow-up, our patient improved on combination therapy. The haemodynamic reassessment confirmed this. Regarding the CPET, although little improvement was noted in PVO_2 and in some of the ventilatory values, there were better $PetCO_2$ kinetics and a lower degree of desaturation. Likewise, the change in the morphology of the ventilatory equivalents curves is striking, and it is our view that this may translate a better alveolo-capillary coupling (Figure 3). Considering these results, it was agreed to maintain the patient on the same treatment and to delay her inclusion in the transplant list. Nevertheless, we stress the importance of an initial transplant evaluation in order to be ready for any possible course of the events in such an unpredictable disease, but at the same time and if possible, to prepare a close reevaluation on treatment to assess whether there is room for medical therapy. This patient exhibited such a significant improvement and, in this sense, CPET helped us feel more comfortable when deciding on a conservative strategy, as its satisfactory findings were in keeping with the results of other tests such as the RHC and the echocardiogram (see [Supplementary material online](#)).

Conclusions

Diagnosis and management of PVOD can be challenging, and CPET arises as a promising tool to help these purposes. Nevertheless, this disease is infrequent and may present in different forms, so extensive studies and multicentre collaboration are required to better define its exercise pattern and broaden our knowledge of this entity.

Lead author biography



Dr Teresa Segura de la Cal is a cardiology consultant at Hospital 12 de Octubre in Madrid, Spain, working at the units of Adult Congenital Heart Diseases and Pulmonary Hypertension. She has previously worked as an honorary clinical and research fellow in these areas at the Royal Brompton Hospital in London, UK.

Supplementary material

[Supplementary material](#) is available at *European Heart Journal – Quality of Care and Clinical Outcomes* online.

Acknowledgements

The authors wish to acknowledge Dr Paz Sanz Ayllón, Dr Sergio Alonso Charterina, Dr Alejandro Cruz Utrilla, and Dr Jair Tenorio for their dedication to the diagnosis and care of these patients.

Slide sets: A fully edited slide set detailing this case and suitable for local presentation is available as [Supplementary material online](#).

Consent: The authors confirm that written consent for submission and publication of this case report including images and associated text, has been obtained from the patients in line with COPE guidelines.

Conflict of interest: T.S.C. reports speaker and consultancy fees from Janssen Pharmaceutical Companies of Johnson & Johnson and nonfinancial support from Merck Sharp & Dohme. P.E.-S. has received research support from Janssen Pharmaceutical Companies of Johnson & Johnson and Merck; and has received speaker and consultancy fees from Janssen Pharmaceutical Companies of Johnson & Johnson, Bayer, Merck Sharp & Dohme, AOP Orphan Pharmaceuticals, and Ferrer. R.L.L., C.P.-O. and M.J.C.R. report speaker fees from Janssen Pharmaceutical Companies of Johnson & Johnson and nonfinancial support from Merck Sharp & Dohme.

Funding: This project was funded by project 'Bases Genético Moleculares de la Medicina de Precisión en la Hipertensión Arterial Pulmonar'. P.E.-S. received funding from Instituto de Salud Carlos III. Ministerio de Economía y Competitividad (<https://www.isciii.es/Paginas/Inicio.aspx>) (award number: PI 18/01233). The funders had no role in study design, data collection and analysis, decision to publish, or preparation of the manuscript.

References

1. Montani D, Achouh L, Dorfmüller P, Le Pavec J, Sztrymf B, Tchérakian C, Rabiller A, Haque R, Sitbon O, Jaïs X, Darteville P, Maître S, Capron F, Musset D, Simonneau G, Humbert M. Pulmonary veno-occlusive disease: clinical, functional, radiologic, and hemodynamic characteristics and outcome of 24 cases confirmed by histology. *Medicine* 2008;**87**:220–233.
2. Montani D, Lau EM, Dorfmüller P, Girerd B, Jaïs X, Savale L, Perros F, Nossent E, Garcia G, Parent F, Fadel E, Soubrier F, Sitbon O, Simonneau G, Humbert M. Pulmonary veno-occlusive disease. *Eur Respir J* 2016;**47**:1518–1534.
3. Navas Tejedor P, Palomino Doza J, Tenorio Castaño JA, Enguita Valls AB, Rodríguez Reguero JJ, Martínez Meñaca A, Hernández González I, Bueno Zamora H, Lapunzina Badía PD, Escribano Subías P. Variable expressivity of a founder mutation in the EIF2AK4 gene in hereditary pulmonary veno-occlusive disease and its impact on survival. *Rev Esp Cardiol (Engl Ed)* 2018;**71**:86–94.
4. Pérez-Olivares C, Segura de la Cal T, Flox-Camacho Á, Nuche J, Tenorio J, Martínez Meñaca A, Cruz-Utrilla A, de la Cruz-Bertolo J, Pérez Núñez M, Consortium SP, Arribas-Ynsaurriaga F, Escribano Subías P. The role of cardiopulmonary exercise test in identifying pulmonary veno-occlusive disease. *Eur Respir J* 2021;**57**:2100115.
5. Mandel J, Mark EJ, Hales CA. Pulmonary veno-occlusive disease. *Am J Respir Crit Care Med* 2000;**162**:1964–1973.