

A case of central nervous system infection by *Candida famata* in an immunosuppressed patient with HIV-1 infection

Joao Caria^{*}, Ema Leal, Andre Dias, Helder Pinheiro, Diana Póvoas, Fernando Maltez

Serviço de Doenças Infecciosas do Hospital de Curry Cabral, Centro Hospitalar Universitario de Lisboa Central, R. da Beneficência 8, Lisboa, 1050-099, Portugal

ARTICLE INFO

Keywords:

Candida famata
Central nervous system infection
Immunosuppressed
HIV
Epidural abscess

ABSTRACT

Invasive fungal infections caused by *Candida* species are increasingly observed in immunosuppressed patients. *Candida albicans* is the more often identified species and neurocandidiasis is associated with high mortality rates. Diagnosis and treatment of these infections are frequently challenging.

We report a case of central nervous system infection caused by *Candida famata* in an HIV-1 infected patient. To our best knowledge this is just the second published case of neural infection by this agent.

1. Introduction

Clinically relevant fungi causing CNS infection include yeasts, filamentous fungi, and dimorphic fungi. Yeasts are unicellular organisms and include the species of the genus *Candida* [1]. They are known to be etiological agents of disease in immunosuppressed hosts since the nineteenth century. With the significant advances in the treatment of cancer, the HIV epidemic, the use of immunosuppressant drugs in the treatment of immune-mediated inflammatory diseases, the rising number of transplant recipients and other miscellaneous causes of immunosuppression (hemodialysis, chronic liver disease and diabetic patients, as examples), *Candida* species became an important pathogen in the setting of invasive disease, including CNS infection [2].

Candida famata (formerly *Debaryomyces hansenii* and *Torulopsis candida*) is a yeast found in dairy products and ubiquitously in the soil. Previously thought not to be pathogenic to humans, since the beginning of this millennium *C. famata* has been identified in invasive candidiasis cases (0.2–2% of all *Candida* spp. hemoculture isolates) and ocular endophthalmitis [3]. To our knowledge, there is only one published case of CNS infection by this species [4], hence the importance of this report.

Although there is scarce data on *in vitro* susceptibilities of *C. famata* to antifungal agents, it appears to exhibit reduced susceptibility to echinocandins and azoles, particularly in the setting of prior antifungal exposure [5].

Meningitis and meningoencephalitis are the most common clinical syndromes in CNS disease caused by *Candida* spp. [6], affecting

disproportionately the immunosuppressed [7] and those with previous bacterial meningitis [8]. Although no randomized controlled trials have been performed to evaluate the most appropriate treatment for CNS infection, combination regimens of liposomal amphotericin B and flucytosine have been recommended [9,10]. Voriconazole has been considered an option due to its pharmacokinetic properties, especially managing infection by non-*albicans* *Candida* species [11].

2. Case

We present the clinical case of a 60-year-old, white, Portuguese man, with a relevant medical history of HIV infection diagnosed in 1998. Since the diagnosis, the patient had been on and off ART. Severe immunosuppression resulted from frequent ART withdrawal and in 2014 (lymphocyte count of 16 cells/ μ L at the time of that episode), the patient developed cryptococcal meningitis. This CNS infection led to cognitive sequelae and forced retirement. Since 2015, the patient has evidenced good adherence to ART, confirmed virological suppression since that year and a CD4⁺ count of 380 cells/ μ L in the last staging, eight months before the present episode.

On February 2021 (day 0), the patient was admitted to the emergency department (ED), after being found lying on the floor at home with a supraciliary incision wound. He was alert, agitated, with no memory of the event, feverish with an axillary temperature of 38.0 °C, having had a witnessed convulsive crisis that reversed with adequate treatment. On observation, the patient exhibited lethargy, mental

Abbreviations: ART, Antiretroviral therapy; CD4⁺, cluster of differentiation 4; CNS, Central nervous system; HIV, Human immunodeficiency virus.

^{*} Corresponding author. R. da Beneficência 8, Lisboa, 1050-099, Portugal.

E-mail address: caria@campus.ul.pt (J. Caria).

<https://doi.org/10.1016/j.mmcr.2022.09.004>

Received 11 July 2022; Received in revised form 19 September 2022; Accepted 20 September 2022

Available online 28 September 2022

2211-7539/© 2022 The Authors. Published by Elsevier B.V. on behalf of International Society for Human and Animal Mycology. This is an open access article under the CC BY-NC-ND license (<http://creativecommons.org/licenses/by-nc-nd/4.0/>).

confusion, without focal deficits or meningeal signs. Besides having a serum creatinine of 1.6 mg/dL and a creatine phosphokinase of 400 mg/dL, all other blood work admission parameters were unremarkable, including his inflammatory parameters, as stated by a C reactive protein (CRP) of 7.5 mg/L and normal leukogram. A cranioencephalic tomography was performed while being at the ED, which documented “grossly nodular, hyperdense, intraventricular/peri-ependymal lesions in the atrium of the left lateral ventricle, in both occipital horns and in the left sphenoid horn, as well as in the ventricle, with a slight densitometric enhancement after contrast” (Fig. 1).

Lumbar puncture (LP) was performed in ED and crystal clear cerebral spinal fluid (CSF) was collected. CSF analysis showed normal glyco-rhachia, pleocytosis - 29 leukocytes/ μ L with predominant mononuclear cells - and hyperproteinorrhachia - 214 mg/dL. CSF microscopic bacteriological (Gram stain), mycological and mycobacteriological (Ziehl-Neelsen) direct exam were negative, as well as enterovirus and herpesvirus (herpes virus 1 to 8) polymerase chain reaction (PCR) and *Cryptococcus* CSF antigen. Bacteriological, mycological and mycobacteriological CSF cultures were pending. Due to space-occupying lesions and aspects suggesting active hydrocephalus, dexamethasone therapy was initiated, ART therapy was kept and the patient was transferred to our medical ward on day +4.

On day +4 and during the first two weeks of hospitalization, he maintained slowed mentation, with periods of confusion, and increased difficulty in locomotion. In immunological staging it was confirmed serum HIV viral load suppression (<50 copies/mL) and TCD4⁺ count of 398 cells/ μ L. CSF analysis showed normal glyco-rhachia, pleocytosis - 22 leukocytes/ μ L with predominant mononuclear cells -, hyperproteinorrhachia - 170 mg/dL - and adenosine deaminase of 1 U/L. Also, CSF direct bacteriological, mycological and mycobacteriological direct exam, as well as CSF *Mycobacterium tuberculosis*, *Toxoplasma gondii* and John Cunningham (JC) Polyomavirus PCR and CSF VDRL were negative. Cultural exams were pending. HIV CSF viral load was undetectable.

On day +16, cranioencephalic (Fig. 2) and neuroaxis magnetic

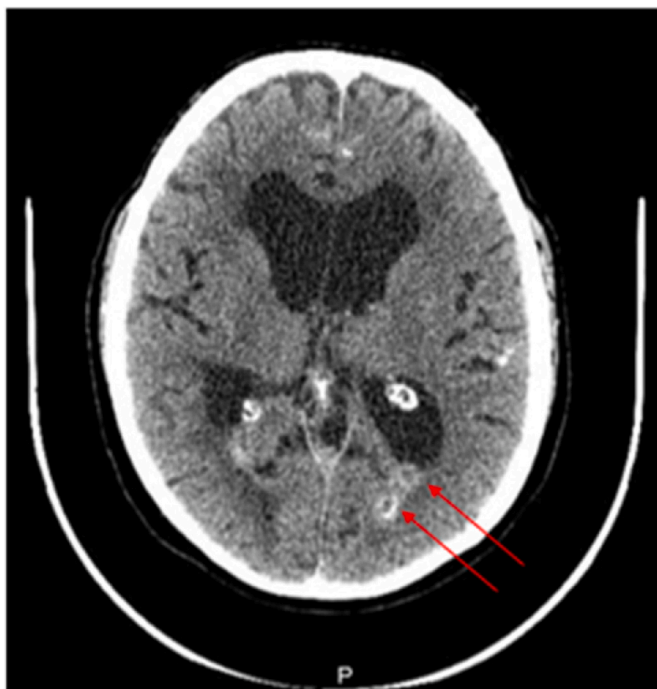

Fig. 1. Cranioencephalic (CE) computerized tomography on day 0. Ventricular enlargement suggestive of active hydrocephalus is apparent as well as two nodular contrast enhancing lesions in the left lateral ventricle (pointed by red arrows). (For interpretation of the references to colour in this figure legend, the reader is referred to the Web version of this article.)

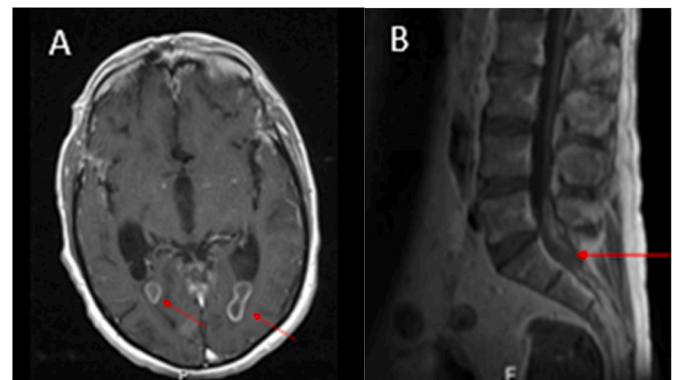


Fig. 2. Cranioencephalic (CE) and neuroaxis magnetic resonance imaging (MRI) performed on day +16. A- Focal lesions on occipital horns of both lateral and fourth ventricles in T1-weighted image (lesions are pointed with red arrows); B- Grossly fusiform expansive lesion with a probable intradural location (at L5-S1 level) with T1-weighted image (lesions are pointed with red arrows). (For interpretation of the references to colour in this figure legend, the reader is referred to the Web version of this article.)

resonance imaging (MRI) was performed, confirming all brain findings in previous exam and additionally reporting “in the study of the rachis, a grossly fusiform expansive lesion in the lumbosacral transition, in a probable intradural location, with signal evolution similar to that of the spinal cord on T1, and slight hypersignal on T2”, suggestive of infectious nature, eventual tuberculosis (with intracranial lesions compatible with tuberculomas, predominantly intraventricular, coexisting intradural lesions in the rachis and probable meningeal infiltration in some cortical sulci and cisternal spaces”.

Biopsy of the raquidian lesion (on day +27) and tissue sampling for mycologic and mycobacteriological exam was performed. As for the biopsy exam, direct microscopy revealed yeast-like structures, but identification of the agent was not possible either through culture or panfungal PCR (performed at the Portuguese national reference lab). Since clinical, epidemiological and imagiological findings pointed to CNS tuberculosis as most likely diagnosis, presumptive tuberculosis treatment was initiated with first-line antituberculous drugs. At this point, yeast-like structures present on biopsy direct microscopy were interpreted as sample contamination. The patient completed 32 days of a first-line antituberculous regimen (on day +59), without clinical or imaging improvement. At that point, CSF mycobacteriological cultural exams performed in the beginning of this episode proved negative as well as lesion biopsy cultural exams. Therefore, LP was repeated on day +59 (keeping pleocytosis - 13 leukocytes/ μ L with predominant mononuclear cells - and hyperproteinorrhachia - 240 mg/dL). CSF direct examination showed yeast-like structures and cultural growth in enriched liquid medium. Sample was sent to the national reference lab for fungus studies and genomic sequencing (Sanger method) allowed the identification of *Candida famata*, based on a 100% homology test. Treatment with intravenous liposomal amphotericin B (3.5 mg/kg/day dose) and oral flucytosine (100 mg/kg/day dose; divided in four equal doses) was started on day +63, which was carried out for 16 days. Due to lack of clinical improvement, liposomal amphotericin B and oral flucytosine combination therapy was stopped and voriconazole (200mg every 12 hours) monotherapy was initiated (on day +78).

LP was repeated (on day +91) after 13 days of therapy with voriconazole and although yeast-like structures were identified on direct microscopy there was no growth. Cytochemical properties were slightly improved concerning pleocytosis (11 leukocytes/ μ L with predominant mononuclear cells), but not on proteinorrhachia value (252 mg/dL). After two weeks of therapy with voriconazole, marked recovery on mental state as well in motricity was verified and the patient was discharged on day +97. In ambulatory follow-up, under therapy with voriconazole on the same dosage, clinical recovery was maintained and

LP was repeated after 71 days of therapy (day +149), still with observed yeast-like structures on direct exam, but with negative culture and keeping the same cytochemical properties. After 125 days of therapy (day +203), LP was again repeated, this time with negative direct microscopy and further negative cultural exams. Of note, that even though this was the first time CSF exam did not reveal pleocytosis, there was still evidence hyperproteinorrachia (159 mg/dL). After 275 days of therapy (day +353), while the patient was still on voriconazole in the same dose (with serum drug dosing confirming values in therapeutic interval) and having experienced a full clinical recovery, cranioencephalic MRI was repeated and revealed no significant changes from the MRI performed on day +16 with persistence of “grossly nodular and relatively well-defined lesions, with peripheral signal reinforcement, dispersed throughout the CSF circulation spaces, both in the sulcus-cisternal spaces and in the ventricular system”. After this result, the patient kept antifungal therapy with voriconazole and follow-up in outpatient clinic.

3. Discussion

This case elicits an interesting discussion on the pathogenesis of this infection. It occurred in a HIV patient with a relatively preserved immune function and with sustained virological suppression under ART therapy for years. Nevertheless, he had CD4⁺ counts of 200–500 CD4⁺ cells/ μ L, widely recognized as a risk factor for infections with non-AIDS defining pathogens, such as *Candida* species. More notoriously, the patient had history of severe immunosuppression, with a CD4⁺ lymphocyte nadir of 16 cells/ μ L. Severe immunosuppression by advanced HIV has been linked to persistent fungal gut colonization, as well as intestinal barrier disruption, both favoring microbial translocation and infection on long term even after suppressive ART [12].

The history of past CNS cryptococcosis in 2015 is another remarkable aspect regarding the pathogenesis of this invasive candidiasis case. Previous bacterial meningitis was identified in most patients that developed subsequent *Candida* meningitis [8]. It is hypothesized that disruption of blood brain barrier (BBB) by bacterial invasion could lead to permanent dysfunction in this barrier and therefore be an eliciting factor for subsequent fungal invasion. It is reasonable to think that an analogue mechanism could compromise the BBB of this patient after the CNS cryptococcosis, as the debilitating physical and mental sequelae probably reflect extensive morphological damage.

As for the clinical features of this neurocandidiasis case, the patient manifested aspects compatible with a meningoencephalitis (fever, maintained lethargy), although some of the most remarkable findings of meningitis or encephalitis, such as meningeal signs, sustained fever or sensory or motor focal deficits, respectively, were absent. The imagiological evidence of multiple lesions, adjacent and within ventricular location, altering CSF drainage mechanics and causing hydrocephalus with increased intracranial pressure, offer, indeed, a plausible explanation for the main clinical manifestations of this patient during most of his admission. Although the histopathological nature of these lesions was not completely uncovered by the imaging, these might correspond to cerebral microabscesses, which along with meningeal inflammation are the hallmark of CNS *Candida* infection findings described in literature [13]. Another important feature of this case was the finding of epidural abscess, despite the absence of classic symptoms (e.g back pain, sustained fever, neurological deficit). This finding allowed a biopsy and, although agent identification was not possible, the documentation of yeast-like structures on direct exam, not only directed the investigation efforts to the final identification of a mycological agent, but also reinforced *Candida* as the etiologic agent, since epidural abscess is also a presentation documented on literature for *Candida* invasive infections. Nonetheless, we didn't find other cases in literature of epidural abscess caused specifically by *Candida famata*.

To the best of our knowledge this is the second published case of CNS infection caused by *C. famata*. The other one was described by Prinsloo

et al. (2003) in South Africa in a HIV-positive 29-year-old male with meningitis due to fluconazole-susceptible *Candida famata* identified in CSF culture.

There were remarkable differences in the process of agent identification in these two cases. While in the South African patient's case, culture identification and antibiotic susceptibility testing were fast and straightforward, in the Portuguese patient's case identification was only possible through DNA sequencing after unsuccessful attempts of fungal culture in CSF and biopsy specimens. This was probably due to the intrinsic difficulty of *C. famata* identification, by semi-automatic methodologies such as MALDI-TOF, that most modern labs rely on, leading to misidentification of this species [14]. This fact alerts to the necessity of application of molecular and proteomic methods, which provide rapid and reliable alternatives to current phenotypical techniques in the identification of uncommon fungal agents.

Reduced susceptibility of *C. famata* to antifungals such as fluconazole and echinocandins derives from early *in vitro* studies [5]. Treatment failure that was verified in this patient with this regimen prompted the switch to voriconazole therapy. The experience with voriconazole in the context of neurocandidiasis is scarce and there are no formal recommendations for the treatment of infection by *C. famata*. We relied on this therapy knowing the excellent CSF penetration of this drug [11], and favorable susceptibility profile [15].

An important point of discussion is the timing of discontinuation of antifungal therapy. We must bear in mind the present recommendation of only considering therapy withdrawal when all signs and symptoms and CSF and radiological abnormalities have resolved [11]. Although after 125 days of therapy it was finally documented a negative result of both direct and cultural CSF exams, the persistence of hyperproteinorrachia (in a value which is more than three times above the upper limit) as well as radiological abnormalities (after 275 days of therapy) don't offer assurance on a decision to stop antifungal therapy. According to the present recommendations, the clinical team plans on keeping therapy with voriconazole until CSF and radiological abnormalities resolve.

Funding

There was no funding for this manuscript.

Declaration of competing interest

All authors declare that they have no conflicts of interest regarding this manuscript.

Acknowledgements

We present our sincere gratitude to all the members of Laboratório Nacional de Referência de Micologia do Instituto Nacional de Saúde Doutor Ricardo Jorge (National Mycology Reference Laboratory) for the technical and scientific contribution to the laboratory diagnosis.

References

- [1] R.R. Sharma, Fungal infections of the nervous system: current perspective and controversies in management, *Int. J. Surg.* 8 (8) (2010) 591–601.
- [2] J.M. Murthy, C. Sundaram, Fungal infections of the central nervous system, *Handb. Clin. Neurol.* 121 (2014) 1383–1401.
- [3] S.S. Al-Hedaithy, The yeast species causing fungemia at a university hospital in Riyadh, Saudi Arabia, during a 10-year period, *Mycoses* 46 (8) (2003) 293–298.
- [4] Prinsloo, et al., *Candida famata* central nervous system infection, *S. Afr. Med. J.* 93 (8) (2003) 601–602.
- [5] B.D. Beyda, S.H. Chuang, M.J. Alam, D.N. Shah, M.N. Tat, L. McCaskey, et al., Treatment of *Candida famata* bloodstream infections: case series and review of the literature, *J. Antimicrob. Chemother.* 68 (2) (2013) 438–443.
- [6] A.A. Panackal, P.R. Williamson, Fungal infections of the central nervous system, *Continuum* 6 (2015) 1662–1678.

- [7] M. Chen, C. Chen, Q. Yang, R. Zhan, *Candida* meningitis in neurosurgical patients: a single-institute study of nine cases over 7 years, *Epidemiol. Infect.* 148 (2020) e148.
- [8] M.H. Nguyen, V.L. Yu, Meningitis caused by *Candida* species: an emerging problem in neurosurgical patients, *Clin. Infect. Dis.* 21 (2) (1995) 323–327.
- [9] J. Sanchez-Portocarrero, E. Perez-Cecilia, O. Corral, J. Romero-Vivas, J.J. Picazo, The central nervous system and infection by *Candida* species, *Diagn. Microbiol. Infect. Dis.* 37 (2000) 169–179.
- [10] T.L. Chen, H.P. Chen, C.P. Fung, M.Y. Lin, K.W. Yu, C.Y. Liu, Clinical characteristics, treatment and prognostic factors of candidal meningitis in a teaching hospital in Taiwan, *Scand. J. Infect. Dis.* 36 (2004) 124–130.
- [11] P.G. Pappas, C.A. Kauffman, D.R. Andes, C.J. Clancy, K.A. Marr, L. Ostrosky-Zeichner, et al., Clinical practice guideline for the management of candidiasis: 2016 update by the infectious diseases society of America, *Clin. Infect. Dis.* 62 (4) (2016 Feb 15) e1–e50.
- [12] G. Barabona, M. Mahiti, M. Toyoda, et al., Advanced baseline immunosuppression is associated with elevated levels of plasma markers of fungal translocation and inflammation in long-term treated HIV-infected Tanzanians, *AIDS Res. Ther.* 18 (2021) 55.
- [13] G.L. Mandell, J.E. Bennett, R. Dolin, Mandell, Douglas, and Bennett's Principles and Practice of Infectious Diseases, sixth ed., Elsevier, Churchill Livingstone, 2005, pp. 2935–2938.
- [14] M. Castanheira, L.N. Woosley, D.J. Diekema, R.N. Jones, M.A. Pfaller, *Candida guilliermondii* and other species of *Candida* misidentified as *Candida famata*: assessment by Vitek 2, DNA sequencing analysis, and matrix-assisted laser desorption ionization-time of flight mass spectrometry in two global antifungal surveillance programs, *J. Clin. Microbiol.* 51 (2003) 117–124.
- [15] P. Badiie, H. Badali, T. Boekhout, et al., Antifungal susceptibility testing of *Candida* species isolated from the immunocompromised patients admitted to ten university hospitals in Iran: comparison of colonizing and infecting isolates, *BMC Infect. Dis.* 17 (1) (2017) 727.