

A different type of perforation: appendicitis after colonoscopy

Amani Jambhekar, Shawn Robinson, Ryan Lindborg, James Rucinski and Raffaele Borriello

Department of Surgery, New York Methodist Hospital, Brooklyn, NY 11215, USA

Corresponding author: Amani Jambhekar. Email: amani.jambhekar@gmail.com

Lesson

Physicians who perform colonoscopy should consider appendicitis in the differential diagnosis of post procedure abdominal pain. Diagnostic laparoscopy is a safe adjunct for evaluation in patients with suspected perforation after colonoscopy. It is important that all physicians be aware of this complication to ensure prompt diagnosis and intervention.

Keywords

Surgery, gastroenterology

Introduction

Appendicitis after colonoscopy is a rare condition that has been reported 13 times previously in the literature.^{1–13} Only one case was reported in a review of 3343 appendectomies.¹ One prior case of perforated appendicitis has been reported.² The pathophysiology appears to be related to insufflation leading to impaction of stool into the appendiceal orifice.^{1,3} The current report describes a case of perforated appendicitis approximately 12 h after colonoscopy.

Methods

A Medline search was performed from 1950 to November 2016 using PUBMED interface with key words [appendicitis] AND [colonoscopy]. Thirteen relevant papers were found using the reported search.

Case report

A 60-year-old male with a medical history of eczema and asthma underwent routine colonoscopy for screening at his gastroenterologist's office. The colonoscopy was uneventful and no polyps were found. No signs of inflammation around the base of the cecum or appendiceal orifice were found. The patient reported mild abdominal discomfort while drinking the oral contrast that morning, but the symptom subsided subsequently. Abdominal pain developed in the evening approximately 10 h after the colonoscopy. On examination in the emergency

department, there was localised right lower abdominal tenderness with no features of a more generalised peritonitis. The white blood cell count was $8.1/\text{mm}^3$ with 96.9% neutrophils. Further investigation with computed tomography showed features of early appendicitis. The appendix was 15 mm in diameter with an intraluminal appendicolith as well as adjacent oedema and with air within the lumen (Figures 1 and 2). Non-operative management was instituted with IV hydration and broad-spectrum IV antibiotic therapy. Over the next several hours, the white blood cell count rose to $20.7/\text{mm}^3$ with 91% neutrophils. At diagnostic laparoscopy, perforated appendicitis was found with no abnormality of the adjacent cecum. The pathologist's evaluation of the tissue confirmed perforated appendicitis. The patient was discharged on postoperative day two after an uneventful recovery.

Discussion

Complications following colonoscopy include abdominal pain and bloating (5–25%), cardiopulmonary complications related to sedation (5–11%), infection (4%), haemorrhage (0.1–0.6%) and perforation (<0.1%).¹⁴ In contrast, post colonoscopy appendicitis is rare and only 13 prior cases have been reported. In the reported cases, symptoms developed within 12 h to five days after the procedure. Several mechanisms have been postulated. The most widely proposed potential mechanism postulates that the insufflation process may force residual intestinal contents into the lumen of the appendix creating impaction with appendiceal luminal obstruction.¹ In one case, a swollen, obstructed appendix was visible on colonoscopy itself, suggesting that the obstruction may have developed in the preparation phase in response to aggressive catharsis.³ Other proposed mechanisms include local oedema from trauma induced by the endoscope or intervention causing temporary obstruction of the appendiceal orifice.⁴ It has also been suggested that excess pressure from

Figure 1. Axial computed tomography images of the described patient. Note air in the appendix.

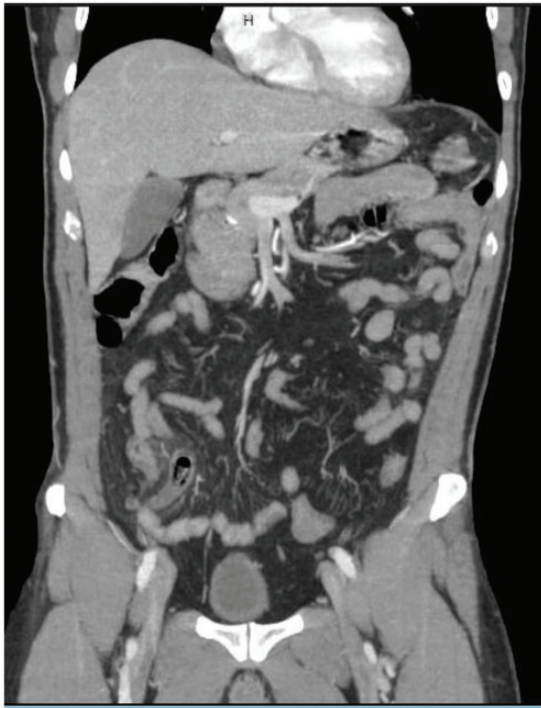
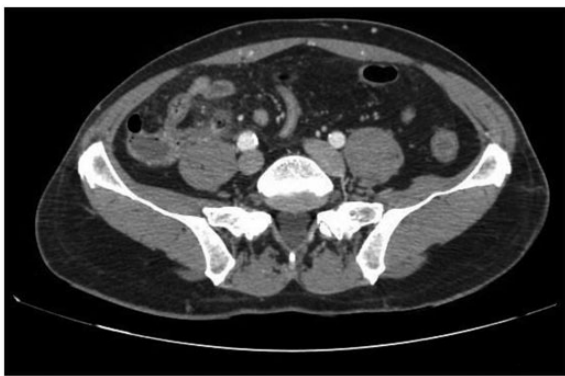


Figure 2. Coronal computed tomography images of the described patient. Note air in the appendix.



the endoscope at the appendiceal lumen and possible excess inflation can result in inflammation secondary to trauma or promote the formation of a faecolith.^{1,5-7}

One prior case of perforated appendicitis has been reported and was similar to the current case. The patient had no findings of acute appendicitis during

the colonoscopy procedure but diffuse peritonitis developed within 16 h of the procedure. This time course suggests that the perforation may have been related to excess pressure from the endoscope at the appendiceal lumen, and possible excess inflation.² In contrast, the patient described in this report developed abdominal pain but no sign of peritonitis prompting initial non-operative management. There was a faecolith prior to colonoscopy, but symptoms of abdominal discomfort developed during the preparatory phase suggesting that the obstruction occurred prior to the procedure. It is postulated that the barotrauma of the colonoscopy led to impaction, with obstruction of the appendiceal lumen, which then led to inflammation with perforation 12 h later.

Computed tomography is valuable when the diagnosis is not clear in a patient who has recently undergone colonoscopy and presents with significant physical findings.⁸ Because of the higher risk of extended hospital stay and complications associated with late or misdiagnosed appendicitis, physicians who perform colonoscopy should consider it in the differential diagnosis of post procedure abdominal pain.⁴ For surgeons, diagnostic laparoscopy is a safe adjunct for evaluation in patients with suspected perforation after colonoscopy and may also be used reliably to evaluate the appendix.^{9,10} It is important that all physicians be aware of this complication to ensure prompt diagnosis and intervention.

Declarations

Competing Interests: None declared.

Funding: None declared.

Ethics approval: Written informed consent for publication was obtained from the patient.

Guarantor: AJ.

Contributorship: AJ wrote the article. SR performed the literature review. RL and JR edited the article. RB was the primary surgeon who spearheaded the submission of the article.

Acknowledgements: We would like to thank all the supporting staff at our home institution for their help and support.

Provenance: Not commissioned; peer-reviewed by Benjamin Stubbs.

References

1. Lipton S and Estrin J. Postcolonoscopy appendicitis: a case report. *J Clin Gastroenterol* 1999; 28: 255-256.
2. Johnston P and Maa J. Perforated appendicitis after colonoscopy. *JSLs* 2008; 12: 335-337.
3. Petro M and Minocha A. Asymptomatic early acute appendicitis initiated and diagnosed during colonoscopy: a case report. *World J Gastroenterol* 2005; 11: 5398-5400.

4. Shaw D, Gallardo G and Basson MD. Post-colonoscopy appendicitis: a case report and systematic review. *World J Gastrointest Surg* 2013; 5: 259–263.
5. Hirata K, Noguchi J, Yoshikawa I, et al. Acute appendicitis immediately after colonoscopy. *Am J Gastroenterol* 1996; 91: 2239–2240.
6. Takagi Y and Abe T. Appendicitis following endoscopic polypectomy. *Endoscopy* 2000; 32: S49.
7. Vender R, Larson J, Garcia J, et al. Appendicitis as a complication of colonoscopy. *Gastrointest Endosc* 1995; 41: 514–516.
8. Volchok J and Cohn M. Rare complications following colonoscopy: case reports of splenic rupture and appendicitis. *JLS* 2006; 10: 114–116.
9. Kim J, Lee GJ, Baek JH and Lee WS. Comparison of the surgical outcomes of laparoscopic versus open surgery for colon perforation during colonoscopy. *Ann Surg Treat Res* 2014; 87: 139–143.
10. Kraemer M, Ohmann C, Leppert R and Yang Q. Macroscopic assessment of the appendix at diagnostic laparoscopy is reliable. *Surg Endosc* 2000; 14: 625–633.
11. Brandt E and Naess A. Acute appendicitis following endoscopic polypectomy. *Endoscopy* 1989; 21: 44.
12. Doohen R and Aanning H. Appendiceal colic: a rare complication of colonoscopy. *S D J Med* 2002; 55: 526–527.
13. Rosen MJ and Sands BE. Acute appendicitis following colonoscopy. *J Clin Gastroenterol* 2005; 39: 78.
14. Fisher DA, Maple JT, Ben-Menachem T, Cash BD, Decker GA, Early DS, et al. Complications of colonoscopy. *Gastrointest Endosc* 2011; 74: 745–752.