

Single stage circumferential lingual mucosal graft urethroplasty in near obliterative bulbar urethra stricture: A novel technique

Umesh Sharma, Sher Singh Yadav, Vinay Tomar, Amit Garg

Department of Urology and Renal Transplantation, SMS Medical College, Jaipur, Rajasthan, India

Abstract

Aims: This is a prospective study of the use and efficacy of a novel technique of circumferential tubularised lingual mucosal graft (LMG) in obliterative and near obliterative bulbar urethral stricture of >2 cm where excisional and augmented anastomotic urethroplasty are not feasible.

Materials and Methods: The stenotic urethral segment was opened dorsally in midline and fibrosed urethra was excised taking care to preserve the healthy spongiosum tissue. LMG (av. Length 3 cm) was placed from one end of corporal body towards spongy tissue in a circumferential manner. Another LMG was placed in similar manner to deal with longer stricture. The urethra was tubularised over 14 Fr silicone catheter.

Results: A total of 12 men, of mean age 47 years underwent this procedure. The mean follow up period was 11 months starting from July 2014 till manuscript submission. Follow up included voiding cystourethrogram at 3 weeks, cystoscopy at 3 months (one patient didn't turned up) and subsequent follow up. Mean stricture length was 4.66 cm (range, 3–8.5 cm) and mean operative time was 195 min. (range, 160 to 200 min.). The technique was successful (normal voiding with no need for any post-operative procedure) in 11(91.6%) patients. One patient developed early recurrence at 4 month of surgery and had anastomotic stricture which was successfully managed by direct visual internal urethrotomy.

Conclusion: Single stage circumferential tubularised graft urethroplasty is an excellent technique for strictures that include segments of obliterative and near obliterative diseased urethra. It provide a wider neourethra than patch graft urethroplasty.

Key Words: Circumferential, lingual mucosal graft, obliterative, urethral stricture

Address for correspondence:

Dr. Umesh Sharma, Department of Urology and Renal Transplantation, SMS Medical College and Associated Hospitals, Jaipur - 302 004, Rajasthan, India.
E-mail: drumeshkgmc@gmail.com

Received: 09.08.2015, Accepted: 16.10.2015

INTRODUCTION

Various reconstructive techniques have been described for bulbar urethral disease, and modifications are continuously

added to them. End-to-end anastomosis with complete excision of scar tissue is good for short bulbar urethral stricture. Longer strictures are dealt with tissue substitution either in the form

Access this article online	
Quick Response Code:	Website: www.urologyannals.com
	DOI: 10.4103/0974-7796.172215

This is an open access article distributed under the terms of the Creative Commons Attribution-NonCommercial-ShareAlike 3.0 License, which allows others to remix, tweak, and build upon the work non-commercially, as long as the author is credited and the new creations are licensed under the identical terms.

For reprints contact: reprints@medknow.com

How to cite this article: Sharma U, Yadav SS, Tomar V, Garg A. Single stage circumferential lingual mucosal graft urethroplasty in near obliterative bulbar urethra stricture: A novel technique. Urol Ann 2016;8:146-50.

of skin flap or oral mucosal grafts. In recent times, the buccal mucosa graft, whether laid dorsally or ventrally, has gained popularity.^[1,2] However in substitution urethroplasty, only the strictured urethra is incised leaving behind the rest of the scar tissue. Furthermore, substitution urethroplasty using oral mucosa is a tough exercise in near obliterative bulbar urethra when a thin strip of mucosa is present. To overcome this problem, Guralnick and Webster^[3] introduced the augmented anastomotic urethroplasty where stricture of up to 2 cm can be excised, but again this cannot be done in longer stricture failed urethroplasty and hypospadias cases due to the fear of tissue ischemia on account of urethral transection. The tubularized penile skin flap is an alternative for single stage reconstruction, but they are accompanied by high failure rate of up to 36% and recurrences requiring further surgeries.^[4-6] Furthermore, penile skin is inappropriate in patients having inflammatory diseases such as lichen sclerosis. In search of an alternative method, we describe a novel technique of circumferential placement of oral mucosal graft after complete excision of diseased urethra.

MATERIALS AND METHODS

This is a prospective, nonrandomized study including 12 patients. Our last patient was enrolled in July 2014 so that a minimum follow-up of 6 months can be done. Our inclusion criteria were near total obliterative stricture of the bulbar urethra of at least >2 cm were onlay urethroplasty and anastomotic urethroplasty cannot be done with or without stricture of variable length involving anterior urethra. The patients having stricture of <2 cm were excluded. Institutional Review Board approval was taken.

A total of eight patients did not know the cause of their stricture, 2 had a history of trauma, and remaining 2 had a history of prolonged catheterization. Three patients had co-morbid conditions at the time of admission, 1 patient had hepatitis B positive and had pelvic trauma resulting from fixed adductor deformity (no active liver disease), 1 had diabetes

mellitus, and 1 had hypertensive. The patients' characteristic, prior treatment, stricture location and length, and surgery performed were summarized in Table I.

Suprapubic cystotomy (SPC) was done in all patients since diversion allows the inflammation to resolve and also help in deciding the proximal extent of stricture during surgery. All patients underwent preoperative workup which includes cystoscopy, retrograde urethrogram, and voiding cystourethrogram (VCUG).

Mean stricture length was 4.66 cm (range, 3–8.5 cm). The mean operative time was 195 min (range, 160–200 min). This could be due to the initial learning curve for the first few operations. Intraoperative blood loss was negligible, and none of our patients required a postoperative blood transfusion.

All urethroplasty were done by a single surgeon (SSY). All patients were made sterile before proceeding for operation. The patients, whose urine were sterile, were given a single dose of the 2nd generation cephalosporin at the time of induction. The patients, whose urine culture were positive, were kept on antibiotic for at least 5–7 days before proceeding. The patients were laid down in lithotomy after nasal intubation. Two team approaches were used with senior consultant beginning with harvesting of lingual mucosal graft (LMG).

Statistical analysis

All the analyses were done using Statistical Package for the Social Science (SPSS) (SPSS, version 20.0, SPSS Inc., Chicago, Illinois, USA) software. Chi-square test was used to compare dichotomous/categorical variables. Unpaired *t*-test was used to detect the difference between two continuous variables. A *P* < 0.05 was considered statistically significant.

Operative technique

Lingual mucosa from the undersurface of the tongue was harvested in all patients. We did not close the harvested area so as to prevent the narrowing of the tongue, and also a wider graft can be harvested. The graft of 6–8 cm ×

Table 1: Patient ages, prior treatment, stricture location and length, and surgery performed

Pt (age)	Etiology	Stricture length	Prior treatment	Operation
1 (40)	Idiopathic	Distal bulbar = 3.5 cm	DVIU x 2	Circumferential tubularised
2 (52)	Idiopathic	Distal bulbar = 4 cm	DVIU x 1	Circumferential tubularised
3 (47)	Post traumatic	Distal bulbar = 3.5 cm	Open repair	Circumferential tubularised
4 (48)	Idiopathic	Mid bulbar = 3 cm	Dilatations	Circumferential tubularised
5 (35)	Post catheterisation	Bulbar + penile = 8 cm	No	Circumferential tubularised + dorsal onlay
6 (52)	Idiopathic	Mid/distal bulbar = 4.5 cm	No	Circumferential tubularised
7 (45)	Post traumatic	Distal bulbar = 3.5 cm	Open repair	Circumferential tubularised
8 (41)	Idiopathic	Bulbar = 5 cm	DVIU x 1	Circumferential tubularised
9 (54)	Idiopathic	Distal bulbar = 4 cm	DVIU x 1	Circumferential tubularised
10 (55)	Post catheterisation	Bulbar + penile = 8.5 cm	No	Circumferential tubularised + dorsal onlay
11 (49)	Idiopathic	Mid bulbar = 3.5 cm	Dilatations	Circumferential tubularised
12 (56)	Idiopathic	Mid/distal bulbar = 5 cm	Prior TURP, DVIU x 1	Circumferential tubularised

Pt.: Patient, TURP: Transurethral resection of prostate, DVIU: Direct visual internal urethrotomy

2.5 cm can be easily harvested from one side of the tongue [Figure 1].

Midline perineal incision was given. After dissecting through subcutaneous tissue, the bulbocavernosus muscle was divided on one side. Strictured urethra along with bulbospongiosus muscle was mobilized from corpora cavernosa around 180°, and urethra opened along the dorsal surface with spatulation done on both ends up to 1 cm into healthy urethra [Figure 2a]. Scarred urothelium was removed completely from corpora spongiosum to develop bed so that the graft take up would be better. Thinning of the graft was done, and the graft was placed horizontally in a circumferential manner starting from one end of corpora toward spongy tissue [Figure 2b]. LMG was then quilted to recipient bed in continuity to normal spatulated urethra. If necessary, another layer of the graft was placed above or below the previous graft [Figure 2c]. Placing the graft horizontally provide a wider lumen and also less suturing is done than placing the graft longitudinally

i.e., if 3–4 cm length of graft with width of 2.5 cm if placed horizontally would make a lumen of approximately 24–30 mm considering the contraction and loss in suturing. Stricture of remaining urethra, which were not obliterative, were dealt with LMG in dorsal onlay fashion. The urethra was tubularized over 14 F silicone catheter. The bulbospongiosus muscle was reapproximated. The wound was closed in multiple layers with absorbable sutures. In the postoperative period, the patients were put on anti-erection drugs such as diazepam.

The catheter was removed after 3 weeks, and SPC was clamped. VCUG was done for any extravasation and if not then SPC was removed after a couple of days. Our follow-up protocol was with urine analysis, flow rate, and postvoid residual assessment after 1 month, 3 months, 6 months, and then annually. Cystoscopy was done routinely at 3 months and earlier if there are any obstructive symptoms, flow rate deterioration, and elevated postvoid residual on ultrasonography. Failure was defined when there is a need for subsequent surgical intervention such as direct visual internal urethrotomy (DVIU).

RESULTS

The mean age of the patients was 47.8 years (range, 35–56 years). All 12 patients voided well after removal of per urethral catheter. There was no contrast extravasation on VCUG, which was done after 3 weeks, and all patients had wide patent urethra [Figure 3]. None of the patients developed graft pseudo-diverticulum, stenosis, fistula, or sacculation. None

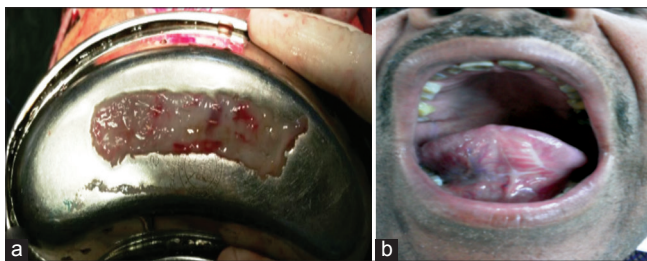


Figure 1: Post operative photograph of lingual graft and donor site (a) harvested lingual mucosal graft (4-6 cm * 2.5 cm) (b) post-operative photograph of donor site

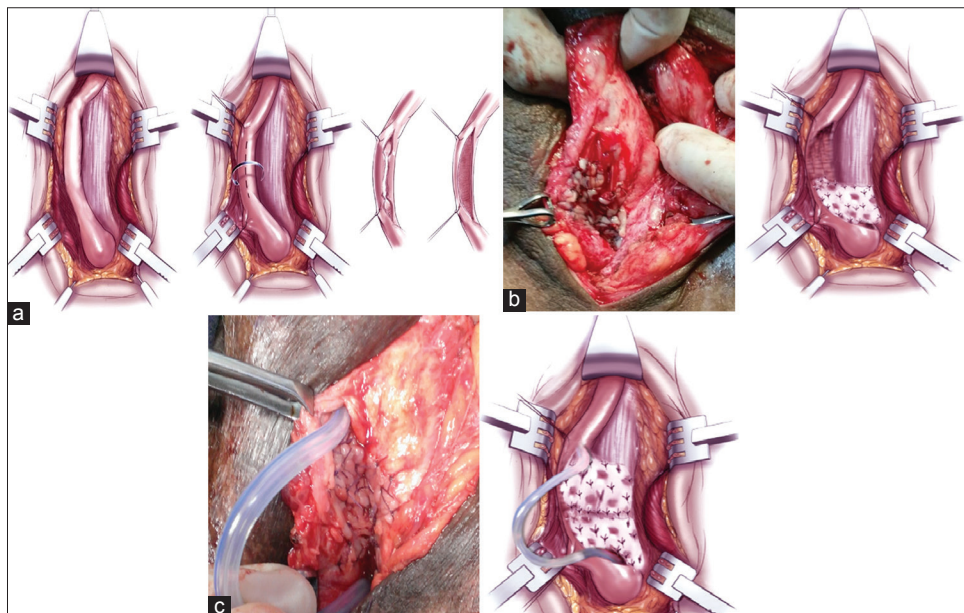


Figure 2: (a) Diagrammatic representation of urethra mobilization, dorsal incision, spatulation at both ends and excision of diseased urethra (b) Actual circumferential placement of graft along with diagrammatic representation (c) Circumferential placement of two grafts one above another with silicone catheter along with diagrammatic representation

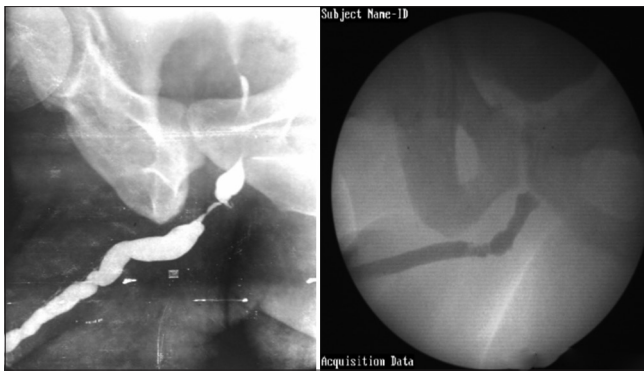


Figure 3: Preoperative and postoperative retrograde urethrogram after 1 month

of the patients required recatheterization. Of 12 patients, 11 turned out for routine follow-up cystoscopy at 3 months. All patients were found to have widely patent urethra with no evidence of stricture recurrence. One patient, who underwent circumferential tubularized and dorsal onlay urethroplasty for an 8.5 cm stricture, did not turn up for routine follow-up cystoscopy was later communicated telephonically and called for cystoscopy. He had mild straining during voiding, and his flow rate was 12 ml/s. He developed short recurrent stricture at the junction of dorsal onlay and circumferential tubularized graft. He later on underwent a successful DVIU followed by regular dilatation. On subsequent cystoscopy, the urethra was widely patent, and he no longer needed any dilatation and instrumentation. The remaining 11 patients did not develop recurrent stricture or required dilatation or any kind of instrumentation for a mean follow-up of 11.6 months (range 6–14 months). The maximum mean peak flow rate was 22.58 ml/s (23.54 ml/s if one patient who needed DVIU was excluded) at 1 month of follow-up and remained with an average mean of 20.58 ml/s on subsequent follow-up. The surgical outcomes and follow-up are summarized in Table 2. The initial success rate in our series was 91.6%.

Age, etiology, previous procedures, co-morbid conditions, stricture length, and operative time had no statistical impact on success rate, probably due to small sample size.

DISCUSSION

Various techniques have been described to manage obliterative or near obliterative long segment stricture of bulbar urethra such as substitution urethroplasty, augmented anastomotic urethroplasty, and staged repair. The ideal management is to completely excise the diseased segment as done in anastomotic urethroplasty, but this is not possible in long segments due to fear of chordee and/or penile shortening. In most of the cases, the stricture is incised, and graft is anastomosed with the margin leaving behind the diseased segment as such. This leads to inferior result as compared to anastomotic urethroplasty. It

Table 2: Surgery outcomes and follow up

Pt. no. (age)	Complications	Qmax (1 month)	Additional treatment	Qmax (6 month)	Follow up period (mo)
1 (40)		24 ml/s		22 ml/s	14
2 (52)		26 ml/s		22 ml/s	13
3 (47)		23 ml/s		20 ml/s	14
4 (48)		22 ml/s		20 ml/s	12
5 (35)		21 ml/s		19 ml/s	13
6 (52)		24 ml/s		21 ml/s	11
7 (45)		24 ml/s		21 ml/s	13
8 (41)		23 ml/s		20 ml/s	12
9 (54)		25 ml/s		22 ml/s	10
10 (55)	Recurrence	12 ml/s	DVIU	18 ml/s	11
11 (49)		24 ml/s		21 ml/s	10
12 (56)		23 ml/s		21 ml/s	6

is known that the best long-term result is achieved by complete excision of the stricture and end-to-end anastomosis of the healthy mucosa.^[7]

In our patients, diseased urethra was completely excised leaving behind the healthy spongiosum tissue, and thus this eliminated the option for augmented anastomotic urethroplasty.

Placing the lingual graft of 2–2.5 cm wide circumference literally converts them into a tubularized lingual graft. However, tubularized graft reported to have poor results.^[8] However, there is the significant fundamental difference in our technique and simple tubularized graft. In our patients, the graft is securely quilted dorsally to corporal tissue and ventrally to healthy spongiosum, thus promoting imbibition and inosculation which was not possible if tubularized graft is simply anastomosed. Furthermore, there is dual blood supply which probably resulted in good surgical outcome. We were able to harvest 6–8 cm long and 2–2.5 cm wide LMG from one side in every patient of our series. In doing so, we left the donor site unstitched without affecting the morbidity of the patients. Also by dividing and placing graft tissue together, one can deal with long strictures of >2.5 cm. Our technique has not been previously published. However, others have described different techniques for near-circumferential buccal mucosa tissue transfer substitution urethroplasty using a ventral approach.^[9-12] In ventral approach, corpus spongiosum is incised longitudinally, ventrally as well as dorsally, and the graft is placed between corporal bodies with another graft ventrally between spongiosum. One advantage of this technique is no significant mobilization of corpus spongiosum is required. However, mobilization of corpus spongiosum done in our series is not associated with compromised blood supply as the dorsal and bulbar artery is not compromised. The disadvantage of ventral approach may include compromised blood supply to spongy tissue as dissection involves both ventral and dorsal surface. Also along the distal bulbar urethra or proximal

penile, corpus spongiosum is less well-developed and robust, thus limiting the proper coverage of graft ventrally by spongiosum.

This is a small series with a limitation of ongoing follow-up after surgery. We recommend a larger group study with this novel technique to draw a true outcome and to establish a place in urethroplasty armamentarium.

CONCLUSION

Circumferential tubularized graft placement is a single stage reconstruction option for obliterative or near obliterative bulbar stricture of long segment or when urethral transection is to be avoided. The key to success is LMG, which is an excellent graft material, horizontal placement, thorough quilting to recipient bed promoting excellent graft take up.

Financial support and sponsorship

Nil.

Conflicts of interest

There are no conflicts of interest.

REFERENCES

- Barbagli G, Palminteri E, Guazzoni G, Montorsi F, Turini D, Lazzeri M. Bulbar urethroplasty using buccal mucosa grafts placed on the ventral, dorsal or lateral surface of the urethra: Are results affected by the surgical technique? *J Urol* 2005;174:955-7.
- Elliott SP, Metro MJ, McAninch JW. Long-term followup of the ventrally placed buccal mucosa onlay graft in bulbar urethral reconstruction. *J Urol* 2003;169:1754-7.
- Guralnick ML, Webster GD. The augmented anastomotic urethroplasty: Indications and outcome in 29 patients. *J Urol* 2001;165:1496-501.
- Markiewicz MR, Lukose MA, Margarone JE 3rd, Barbagli G, Miller KS, Chuang SK. The oral mucosa graft: A systematic review. *J Urol* 2007;178:387-94.
- Wiener JS, Sutherland RW, Roth DR, Gonzales ET Jr. Comparison of onlay and tubularized island flaps of inner preputial skin for the repair of proximal hypospadias. *J Urol* 1997;158:1172-4.
- McAninch JW, Morey AF. Penile circular fasciocutaneous skin flap in 1-stage reconstruction of complex anterior urethral strictures. *J Urol* 1998;159:1209-13.
- Andrich DE, Mundy AR. Urethral strictures and their surgical treatment. *BJU Int* 2000;86:571-80.
- Mundy AR. The long-term results of skin inlay urethroplasty. *Br J Urol* 1995;75:59-61.
- Palminteri E, Lazzeri M, Guazzoni G, Turini D, Barbagli G. New 2-stage buccal mucosal graft urethroplasty. *J Urol* 2002;167:130-2.
- Barbagli G, Palminteri E, Lazzeri M, Guazzoni G. One-stage circumferential buccal mucosa graft urethroplasty for bulbous stricture repair. *Urology* 2003;61:452-5.
- Goel A, Goel A, Jain A. Buccal mucosal graft urethroplasty for penile stricture: Only dorsal or combined dorsal and ventral graft placement? *Urology* 2011;77:1482-6.
- Palminteri E, Berdondini E, Shokeir AA, Iannotta L, Gentile V, Sciarra A. Two-sided bulbar urethroplasty using dorsal plus ventral oral graft: Urinary and sexual outcomes of a new technique. *J Urol* 2011;185:1766-71.

Author Help: Reference checking facility

The manuscript system (www.journalonweb.com) allows the authors to check and verify the accuracy and style of references. The tool checks the references with PubMed as per a predefined style. Authors are encouraged to use this facility, before submitting articles to the journal.

- The style as well as bibliographic elements should be 100% accurate, to help get the references verified from the system. Even a single spelling error or addition of issue number/month of publication will lead to an error when verifying the reference.
- Example of a correct style
Sheahan P, O'leary G, Lee G, Fitzgibbon J. Cystic cervical metastases: Incidence and diagnosis using fine needle aspiration biopsy. *Otolaryngol Head Neck Surg* 2002;127:294-8.
- Only the references from journals indexed in PubMed will be checked.
- Enter each reference in new line, without a serial number.
- Add up to a maximum of 15 references at a time.
- If the reference is correct for its bibliographic elements and punctuations, it will be shown as CORRECT and a link to the correct article in PubMed will be given.
- If any of the bibliographic elements are missing, incorrect or extra (such as issue number), it will be shown as INCORRECT and link to possible articles in PubMed will be given.