

CASE REPORT

Positive immunostaining for feline infectious peritonitis (FIP) in a Sphinx cat with cutaneous lesions and bilateral panuveitis

Bianca S. Bauer,* Moira E. Kerr,† Lynne S. Sandmeyer* and Bruce H. Grahn*

*Department of Small Animal Clinical Sciences, Western College of Veterinary Medicine, University of Saskatchewan, 52 Campus Drive, Saskatoon, SK, Canada; and †Prairie Diagnostic Services, University of Saskatchewan, 52 Campus Drive, Saskatoon, SK, Canada

Address communications to:

B. Bauer

Tel.: 306.966.7083

Fax: 306.966.7156

e-mail: bianca.bauer@usask.ca

Abstract

Feline infectious peritonitis (FIP) is a common, fatal, systemic disease of cats. This case report describes the antemortem diagnosis of FIP in a 2-year-old spayed female Sphinx cat that presented with a bilateral panuveitis and multiple papular cutaneous lesions. Histopathologically, the skin lesions were characterized by perivascular infiltrates of macrophages, neutrophils, with fewer plasma cells, mast cells, and small lymphocytes in the mid- to deep dermis. Immunohistochemistry for intracellular feline coronavirus (FeCoV) antigen demonstrated positive staining in dermal macrophages providing an antemortem diagnosis of a moderate, nodular to diffuse, pyogranulomatous perivascular dermatitis due to FIP infection. Obtaining an antemortem diagnosis of FIP can be a challenge and cutaneous lesions are rare in the disease. Recognition and biopsy of any cutaneous lesions in cats with panuveitis and suspected FIP can help establish an antemortem diagnosis of the disease.

Key Words: feline infectious peritonitis, immunohistochemistry, panuveitis, skin

INTRODUCTION

Feline infectious peritonitis (FIP) is a fatal, systemic disease caused by a mutated feline coronavirus (FCoV).¹ The disease was first recognized in the 1950s² and is characterized by a perivascular granulomatous to pyogranulomatous inflammation and vasculitis.³ Clinically, there are two main forms of FIP, 'wet' and 'dry', although occasionally cats can present with a mixture of both forms.⁴ Ocular involvement often occurs in the 'dry' form of the disease.⁵ The ocular manifestations of FIP were first described by Doherty⁶ in 1971 and include a pyogranulomatous panuveitis with fibrinous exudate in the anterior chamber, keratic precipitates, perivascular cuffing of retinal vessels, exudative retinal detachment, and optic neuritis.

Dermatologic lesions in association with spontaneous FIP are rare, with only three reports in the veterinary literature.^{7–9} Previously reported clinical lesions include truncal papules to nodules characterized by a pyogranulomatous vasculitis and folliculitis,⁹ small nodules over the neck and proximal forelimbs characterized by pyogranulomatous phlebitis in a cat with concurrent feline immunodeficiency virus (FIV) infection,⁷ and papular lesions over the neck and bilaterally over the thorax in a cat with FIP.⁸

The diagnosis of FIP is difficult, and typically, an antemortem diagnosis of FIP can be challenging, especially in noneffusive 'dry' cases.¹⁰ Histopathologic examination of biopsy or necropsy samples is considered the gold standard test, and immunohistochemistry (IHC) for the detection of intracellular FCoV antigen in macrophages is often required to confirm the disease.^{4,10–12} We report a case of the antemortem diagnosis of FIP based on positive immunostaining for intracellular FCoV in multiple skin lesions in a Sphinx cat with bilateral panuveitis.

CASE REPORT

A 2-year-old spayed female Sphinx cat presented to the Western College of Veterinary Medicine ophthalmology service for the evaluation of bilateral chemosis, prolapse of the third eyelids, sneezing and intermittent anorexia, and lethargy of 6-week duration. Three days prior to presentation, the owner noted multiple nonpruritic, raised skin lesions. Ocular examination revealed a normal neurophthalmic examination. Schirmer's tear tests (Schirmer Tear Test Strips; Alcon Canada, Mississauga, ON, Canada) were 13 and 24 mm/min in the right (OD) and left eyes (OS), respectively. The intraocular pressures were

estimated with a rebound tonometer (TonoVet; Tiolat, Helsinki, Finland) and were 9 mmHg bilaterally. Slit-lamp biomicroscopy (Osram 64222; Carl Zeiss Canada, Don Mills, ON, Canada) revealed bilateral chemosis and a prolapsed left third eyelid. Aqueous flare was present bilaterally, and fibrin with blood was evident in the right anterior chamber (Fig. 1). Indirect ophthalmoscopic examination (Heine Omega 200; Heine Instruments Canada, Kitchener, ON, Canada) following dilation with 0.5% tropicamide (Mydracyl, Alcon Canada) revealed multiple foci of chorioretinal cellular infiltration and retinal hemorrhage. The ophthalmic diagnosis was a bilateral panuveitis. Differential diagnoses included inflammatory, infectious, and neoplastic processes. On physical examination, multiple firm, nonpainful, 2–5 mm in diameter red papules were noted over the entire body (Fig. 2). Some of the papules were ulcerated. The remainder of the physical examination was unremarkable.

Ancillary diagnostics included evaluation of the following: complete blood cell count (CBC), serum biochemistry profile, urinalysis, serum protein electrophoresis, ELISA testing for FeLV and FIV, and FIP serum antibody titer. Abnormalities in the CBC included a mild anemia that was nonregenerative (Hct: 0.25 L/L; RI: 0.29–0.45 L/L)

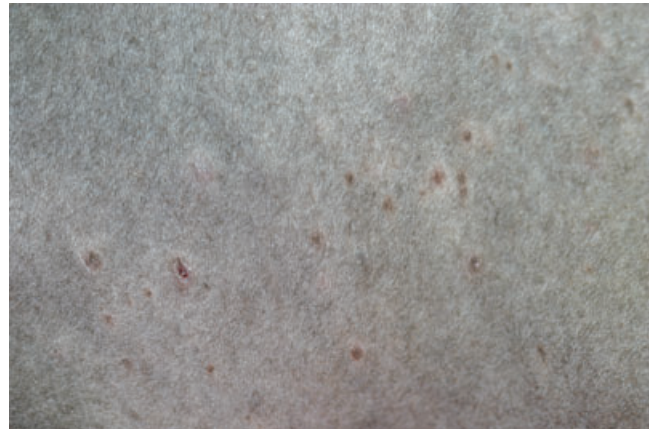


Figure 2. Left lateral thoracic wall, cat. Note multiple cutaneous papules.

and a chronic inflammatory leukogram (moderate leukocytosis [$37 \times 10^9/L$; RI: $3.9\text{--}18.0 \times 10^9/L$]; moderate neutrophilia [$30.3 \times 10^9/L$; RI: $2.1\text{--}15.0 \times 10^9/L$]; mild left shift [$0.7 \times 10^9/L$; RI: $0.0\text{--}0.1 \times 10^9/L$]; and mild monocytosis [$2.2 \times 10^9/L$; RI: $0.0\text{--}0.6 \times 10^9/L$]). An inflammatory serum protein profile (mild hypoalbuminemia [albumin: 26 g/L; RI 27–39 g/L]; mild hyperglobulinemia [globulin: 62 g/L; RI: 27–51 g/L]; and a low albumin to globulin ratio [0.42]) was noted, and a polyclonal gammopathy was present on serum protein electrophoresis. ELISA testing for FeLV and FIV was negative, and the FIP serum antibody titer was 1:51 200.

Two, six-millimeter punch skin biopsies were submitted for histopathologic examination, which revealed a nodular to diffuse, often perivascular, infiltrate of macrophages, neutrophils, with fewer plasma cells, mast cells, and small lymphocytes in mid- and deep dermis (Fig. 3a,b). Histochemical stains (PAS, Grocott, Fite and Gram stains) for infectious agents were negative. Immunohistochemistry for intracellular feline coronavirus (FeCoV) antigen (FIPV3-70, 1:500; Custom Monoclonals, West Sacramento, CA, USA) was positive in dermal macrophages (Fig. 3c). The histopathologic diagnosis was a moderate, nodular to diffuse, often perivascular pyogranulomatous dermatitis due to FIP infection.

Treatment with topical steroids (prednisolone acetate 1%) in both eyes four times daily was initiated as well as oral prednisolone (2 mg/kg/day) and human interferon- α (30 units once daily). Ten weeks after initial presentation, the cat was euthanized due to anorexia and progression of disease. The owner declined postmortem examination.

DISCUSSION

Feline corona viruses are transmitted by the fecal–oral route and typically cause mild enteric disease. After natural infection, cats begin to shed virus in their feces within 1 week and continue to shed for weeks or months with

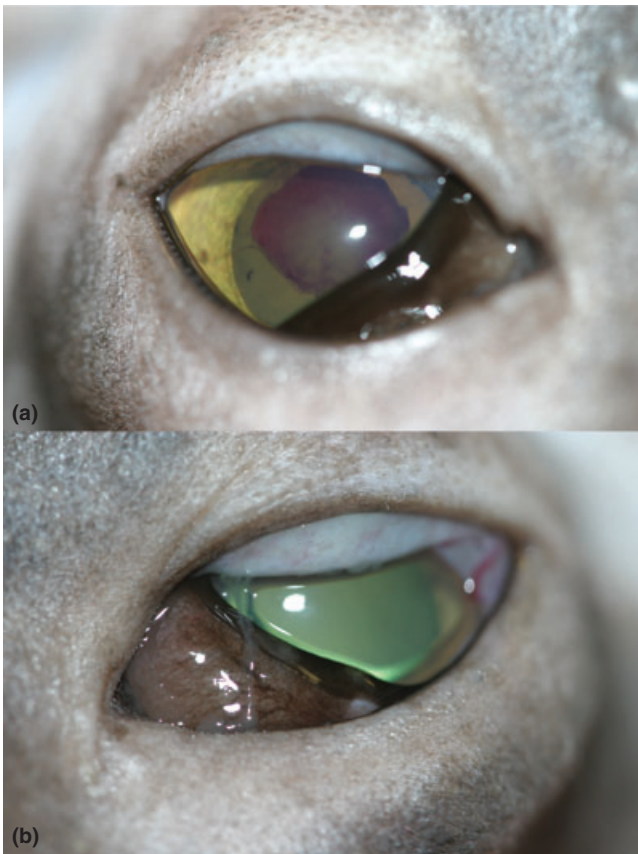


Figure 1. Clinical photograph of OD (a) and OS (b) upon initial presentation. Note the hyphema OD and chemosis and prolapse of the third eyelids OU.

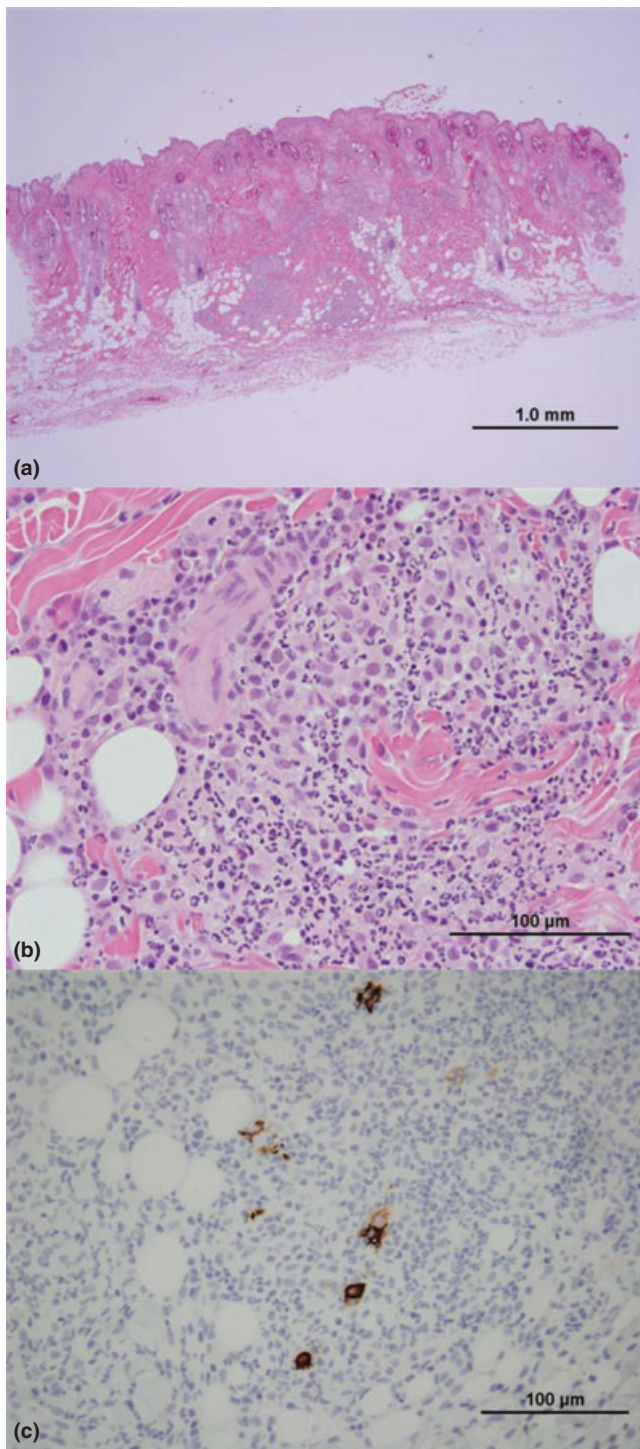


Figure 3. (a) Histopathology of skin lesion demonstrating nodular inflammatory infiltrate in mid- to deep dermis. Hematoxylin and eosin stain, 20 \times (b) Histopathology of skin lesion demonstrating pyogranulomatous perivascular inflammatory reaction. Hematoxylin and eosin stain, 600 \times (c) Immunohistochemical staining of skin lesion. Macrophages within the inflammatory infiltrate express feline coronavirus (FCoV) antigen. Streptavidin-biotin complex technique following protease pretreatment, 600 \times .

some asymptomatic carriers shedding for life.¹³ The FIP virus (FIPV) originates by a spontaneous mutation of the FCoV in individual cats often under conditions of immune suppression.¹⁴ FIP most typically occurs in domestic cats between 3 months and 3 years of age¹⁵ and is more common in patients from multicat households, catteries, and shelters.¹⁶ Pure-bred cats have been reported to be at a higher risk of developing FIP.¹⁷ It has been reported that 5–12% of cats seropositive for FCoV eventually develop FIP.¹⁸ There is no effective diagnostic protocol that can discriminate the avirulent FECV from the pathologic FIPV.¹⁶ The antemortem diagnosis of FIP is therefore difficult and should be based on a combination of history, signalment, clinical signs, and clinicopathological changes.¹⁰

Laboratory findings that are common, but not pathognomonic for FIP include lymphopenia, nonregenerative anemia, increased total serum protein concentration, hyperglobulinemia, a low albumin/globulin ratio, high serum concentrations of the acute phase protein α_1 -acid glycoprotein, and high FCoV antibody titers.¹⁹ Typical ocular manifestations of FIP include ‘mutton fat’ keratic precipitates, hyphema, aqueous flare, and an iridocyclitis/exudative chorioretinitis that is often accompanied by perivascular retinal granulomas with retinal detachments and optic neuritis.⁶ When ocular signs are present, they typically coexist with other systemic signs such as fever, anorexia, lethargy, weight loss, or neurologic signs.⁴

The history and clinical findings in this case were supportive of FIP although serum α_1 -acid glycoprotein levels supporting an inflammatory state were not measured and the FCoV antibody titers were at the high end of normal. RT-PCR may have provided additional diagnostic information to support FIP; however, a high percentage of cats that are RT-PCR positive will never develop FIP.²⁰ The histopathologic demonstration of a pyogranulomatous to mixed perivascularitis is considered the gold standard for a conclusive diagnosis of FIP.¹⁰ The yield of histopathologic lesions in Tru-Cut biopsies (usually from kidney or liver) is low and limits the potential application of this approach for an antemortem diagnosis of FIP.²¹ Furthermore, invasive methods (i.e. laparotomy or laparoscopy) are usually necessary to obtain the tissue samples for histopathologic examination.

Methods of virus detection include the demonstration of FCoV antigen in macrophages in effusions or tissue samples by IHC. While FCoV may be present systemically in healthy cats, only in FIP cases will there be sufficient viral antigen in macrophages to result in positive staining.²⁰ Demonstration of FCoV antigen in macrophages via IHC has a sensitivity of 57%²⁰; however, IHC is 100% predictive of FIP when positive staining of intracellular FCoV antigen in macrophages is demonstrated.²² Therefore, anti-FCoV IHC is mandatory to confirm/exclude the disease in doubtful cases.^{4,10–12} In this case, histopathologic examination of skin biopsies and positive

immunostaining of intracellular FCoV antigen in dermal macrophages provided the antemortem diagnosis of FIP.

At present, there is no effective prevention or treatment for FIP.^{10,23} Supportive treatment for FIP is aimed at suppressing the inflammatory immune response, usually with corticosteroids.²³ There are, however, no controlled studies demonstrating any beneficial effect of corticosteroids. Human interferon- α is an immuno-modulatory compound that has been demonstrated *in vitro* to have a direct antiviral effect protecting against viral replication;²⁴ however, *in vivo* experiments failed to demonstrate a reduced mortality in treated cases.²⁵ Although FIP is invariably progressive and fatal, temporary remission is possible.²⁶

The skin lesions in this case provided a definitive diagnosis of FIP and were easily visualized due to the lack of haircoat in this breed of cat. While a thorough physical examination is recommended in all cases of uveitis, careful examination and palpation of the skin and clipping of the fur may be rewarding in suspect cases of FIP. If cutaneous lesions are noted in a cat with a high clinical suspicion for FIP, then histopathologic examination of skin biopsies with IHC for intracellular FCoV antigen is strongly advocated.

REFERENCES

- Vennema H, Poland A, Foley J *et al.* Feline infectious peritonitis viruses arise by mutation from endemic feline enteric coronaviruses. *Virology* 1998; **243**: 150–157.
- Holzworth J. Some important disorders of cats. *The Cornell Veterinarian* 1963; **53**: 157–160.
- Kipar A, May H, Menger S *et al.* Morphologic features and development of granulomatous vasculitis in feline infectious peritonitis. *Veterinary Pathology* 2005; **42**: 321–330.
- Hartmann K. Feline infectious peritonitis. *Veterinary Clinics of North America Small Animal Practice* 2005; **35**: 39–79. vi.
- Tsai HY, Chueh LL, Lin CN *et al.* Clinicopathological findings and disease staging of feline infectious peritonitis: 51 cases from 2003 to 2009 in Taiwan. *Journal of Feline Medicine and Surgery* 2011; **13**: 74–80.
- Doherty MJ. Ocular manifestations of feline infectious peritonitis. *Journal of the American Veterinary Medical Association* 1971; **159**: 417–424.
- Cannon MJ, Silkstone MA, Kipar AM. Cutaneous lesions associated with coronavirus-induced vasculitis in a cat with feline infectious peritonitis and concurrent feline immunodeficiency virus infection. *Journal of Feline Medicine and Surgery* 2005; **7**: 233–236.
- Gross T. Pyogranulomatous vasculitis and mural folliculitis associated with feline infectious peritonitis in a Sphinx cat. *Veterinary Pathology* 1999; **36**: 507. (Abstract).
- Declercq J, De Bosschere H, Schwarzkopf I *et al.* Papular cutaneous lesions in a cat associated with feline infectious peritonitis. *Veterinary Dermatology* 2008; **19**: 255–258.
- Pedersen NC. A review of feline infectious peritonitis virus infection: 1963–2008. *Journal of Feline Medicine and Surgery* 2009; **11**: 225–258.
- Addie DD, Paltrinieri S, Pedersen NC. Recommendations from workshops of the second international feline coronavirus/feline infectious peritonitis symposium. *Journal of Feline Medicine and Surgery* 2004; **6**: 125–130.
- Giori L, Giordano A, Giudice C *et al.* Performances of different diagnostic tests for feline infectious peritonitis in challenging clinical cases. *Journal of Small Animal Practice* 2011; **52**: 152–157.
- Addie DD, Schaap IA, Nicolson L *et al.* Persistence and transmission of natural type I feline coronavirus infection. *Journal of General Virology* 2003; **84**(Pt 10): 2735–2744.
- Poland AM, Vennema H, Foley JE *et al.* Two related strains of feline infectious peritonitis virus isolated from immunocompromised cats infected with a feline enteric coronavirus. *Journal of Clinical Microbiology* 1996; **34**: 3180–3184.
- McReynolds C, Macy DM. Feline infectious peritonitis Part I. Etiology and diagnosis. *Compendium of Continuing Education for the Practicing Veterinarian* 1997; **19**: 1007–1016.
- Addie DD. Clustering of feline coronaviruses in multicat households. *Veterinary Journal* 2000; **159**: 8–9.
- Rohrbach BW, Legendre AM, Baldwin CA *et al.* Epidemiology of feline infectious peritonitis among cats examined at veterinary medical teaching hospitals. *Journal of the American Veterinary Medical Association* 2001; **218**: 1111–1115.
- Addie DD, Toth S, Murray GD *et al.* Risk of feline infectious peritonitis in cats naturally infected with feline coronavirus. *American Journal of Veterinary Research* 1995; **56**: 429–434.
- Paltrinieri S, Comazzi S, Spagnolo V *et al.* Laboratory changes consistent with feline infectious peritonitis in cats from multicat environments. *Journal of Veterinary Medicine A, physiology, pathology, clinical medicine* 2002; **49**: 503–510.
- Hartmann K, Binder C, Hirschberger J *et al.* Comparison of different tests to diagnose feline infectious peritonitis. *Journal of Veterinary Internal Medicine* 2003; **17**: 781–790.
- Giordano A, Paltrinieri S, Bertazzolo W *et al.* Sensitivity of Tru-cut and fine needle aspiration biopsies of liver and kidney for diagnosis of feline infectious peritonitis. *Veterinary Clinical Pathology* 2005; **34**: 368–374.
- Tammer R, Evensen O, Lutz H *et al.* Immunohistological demonstration of feline infectious peritonitis virus antigen in paraffin-embedded tissues using feline ascites or murine monoclonal antibodies. *Veterinary Immunology and Immunopathology* 1995; **49**: 177–182.
- Hartmann K, Ritz S. Treatment of cats with feline infectious peritonitis. *Veterinary Immunology and Immunopathology* 2008; **123**: 172–175.
- Weiss RC, Oostrom-Ram T. Inhibitory effects of ribavirin alone or combined with human alpha interferon on feline infectious peritonitis virus replication *in vitro*. *Veterinary Microbiology* 1989; **20**: 255–265.
- Weiss RC, Cox NR, Oostrom-Ram T. Effect of interferon or *Propionibacterium acnes* on the course of experimentally induced feline infectious peritonitis in specific-pathogen-free and random-source cats. *American Journal of Veterinary Research* 1990; **51**: 726–733.
- Ishida T, Shibana A, Tanaka S *et al.* Use of recombinant feline interferon and glucocorticoid in the treatment of feline infectious peritonitis. *Journal of Feline Medicine and Surgery* 2004; **6**: 107–109.