

Original paper

In vitro analysis of urinary stone composition in dual-energy computed tomography

Monika Stępień^{1A,B,C,D,E,F,G}, Robert Chrzan^{1A,B,C,D,E}, Wojciech Gawlas^{2A,B,F,G}

¹Department of Radiology, Jagiellonian University in Kraków, Collegium Medicum, Poland

²Department and Clinic of Urology, Jagiellonian University in Kraków, Collegium Medicum, Poland

Abstract

Purpose: Dual energy computed tomography (DECT) is a new method of computed tomography (CT) imaging, allowing the assessment of not only the object's morphology, but also its composition. The aim of the study was to evaluate the potential of *in vitro* DECT evaluation of urinary stones' chemical composition.

Material and methods: Six samples of surgically removed renal stones were scanned using DECT and analyzed by scanner vendor software. Uric acid stones were marked red and calcium stones white by the software. The real composition of the stones was finally verified using physicochemical laboratory analysis.

Results: In 5 out of 6 samples, the composition of stones in DECT (3 samples identified as uric acid and 2 samples as calcium) was consistent with the physicochemical analysis (3 samples identified as uric acid, 1 as calcium phosphate, 1 as calcium oxalate). In DECT it was not possible to determine more precisely the type of calcium compounds (calcium phosphate vs. calcium oxalate) as established in the physicochemical analysis.

In one stone identified in physicochemical analysis as uric acid, DECT detected a composite layered structure containing both uric acid and calcium compounds.

Conclusions: DECT allows uric acid to be distinguished from calcium urinary tract stones, which is crucial in the choice of appropriate therapy. Using the available hardware and software, it was not possible to more accurately distinguish types of calcified stones. Evaluation of the stone type in DECT may be limited in the case of mixed chemical composition.

Key words: urinary stone, dual energy computed tomography.

Introduction

Urolithiasis is a common disease associated with the presence of insoluble deposits in the urinary tract, which arise as a result of the precipitation of chemicals in the urine, when their concentration exceeds the solubility threshold. Kidney stones are found in 10-12% of men and about 5-6% of women throughout life [1]. Deposits can arise in various sections of the urinary tract, most commonly in the calyces and renal pelvis, and then move to the

ureter or bladder where they can grow or be excreted in the urine.

Sometimes the deposits reach a considerable size, and fill the entire renal pelvis and calyces (staghorn calculi), leading to kidney damage.

The most common deposits are composed of calcium oxalate, less frequently calcium phosphate, including calcium phosphate dihydrate (brushite), uric acid, magnesium ammonium phosphate (struvite) and cystine. In special cases, other types of urinary stones arise: xanthine

Correspondence address:

Monika Stępień, Department of Radiology, Jagiellonian University in Kraków, Collegium Medicum, 19 Kopernika St., 31-501 Kraków, Poland,
e-mail: mdmonikas@gmail.com

Authors' contribution:

A Study design · B Data collection · C Statistical analysis · D Data interpretation · E Manuscript preparation · F Literature search · G Funds collection

deposits (in inherited deficiency of xanthine oxidase), acid ammonium urate (in chronic diarrhea and hypokalemia), oxypurinol and xanthine (in chronic treatment with allopurinol or triamterene) [2].

Treatment of urolithiasis depends on the chemical composition, location and size of the deposits and may be conservative or surgical. Knowledge of the chemical composition may be crucial in choosing the right therapy and in forecasting the treatment results.

Chemolysis of deposits is possible only in some types of nephrolithiasis.

In the case of struvite, brushite, cystine and uric acid deposits, percutaneous rinsing with solubilizing agents (hemiacridrin, Suby's G, THAM, N-acetylcysteine) may be used.

For uric acid deposits, oral medications may also be effective to alkalinize the urine to pH of 6.5-7.2 using alkaline citrates or sodium bicarbonate; invasive treatment is implemented only when conservative treatment is ineffective.

Cystine deposits are best dissolved at pH = 7.0-7.5 using mainly D-penicillamine, alpha-MPG, captopril and tiopronin [3].

The most common method of urolithiasis treatment is lithotripsy with shock waves generated extracorporeally (extracorporeal shock wave lithotripsy – ESWL). This method uses electromagnetic, electrohydraulic or piezoelectric lithotripters, locating the stone with fluoroscopy and/or ultrasound. The optimal location for ESWL is the pelvis and calyces (especially upper and middle) and the proximal part of the ureter (above the sacroiliac joint line); in the distal part of the ureter, it is better to perform ureteroscopy. Usually ESWL is used in kidney deposits up to 20 mm in size and ureter deposits up to 10 mm [3]. Calcium oxalate and uric acid stones disintegrate relatively easily. Calcium phosphates, especially those containing brushite, crumble worse and cystine deposits definitely badly [4].

Other methods of treatment include: ureterorenoscopy (URS) involving removal of ureter stones under visual control using a ureterorenoscope and percutaneous nephrolithotomy (PCNL) based on removal of the deposit from the kidney or upper ureter, whole or crushed, using an endoscope inserted directly into the pelvico-calyceal system.

Determination of the chemical composition of ureteral concretions *in vivo* could significantly influence the selection of optimal therapeutic treatment.

Until recently, we did not have a diagnostic method to obtain such data before spontaneous expelling or surgical removal of concrement.

This situation changed only after the introduction of dual energy computed tomography (DECT).

The aim of DECT is to obtain two sets of data (images) during the acquisition of the same anatomical area at different values of X-ray energy (usually 80 keV and 140 keV) [5].

The theoretical principles of DECT were developed in the 1970s, but the first computed tomography scanners

with the practical implementation of this method, using various technical solutions, appeared only a few years ago.

DECT allows deposits containing uric acid to be distinguished from deposits which do not contain uric acid, in tests performed both *in vivo* and *in vitro* [6]. Due to the different chemical structure, uric acid deposits show higher radiodensity Hounsfield unit values using high-energy radiation (at higher kilovoltage), while other types of deposits (including calcium deposits) show higher radiodensity Hounsfield unit values using low-energy radiation (low kilovoltage) [7]. Data obtained in DECT are postprocessed using dedicated software, in which voxels containing uric acid are coded in a different color compared to voxels that do not contain uric acid.

The assessment of the usefulness of DECT in determining the chemical composition of urinary stones is an increasingly common subject of research [7-11]. Most of them are *in vivo* studies, but some focus on *in vitro* evaluation.

The aim of our study was to evaluate the possibilities of *in vitro* DECT assessment of urinary stones' chemical composition.

Material and methods

Six samples of surgically removed urinary stones were analyzed. The individual samples were placed in closed plastic containers. There were both single large and numerous small concretions within the samples.

The samples were scanned in the DECT technique using a Toshiba Aquilion Prime 80 computed tomography scanner, with the following parameters: voltage and current 135 kV and 100 mA or 80 kV and 570 mA, rotation time 0.5 s, configuration of detectors 80 × 0.5 mm, pitch 0.171, reconstruction interval and slice thickness 1 mm, FOV (field of view) 65 mm.

The CTDIvol (CT dose index) for the above protocol was 33.2 mGy.

After processing the data from scanning in the DECT technique, the axial images and the secondary 2D and 3D reconstructions were obtained.

The analysis of the above images was performed using Toshiba DE Stone Analysis software.

The elements of samples containing uric acid were marked by the program in red, while those containing calcium compounds were marked in white (Figures 1 and 2).

The composition of stone samples determined in the above way was compared with their composition evaluated in the laboratory tests during physico-chemical analysis.

Results

After DECT examination of six samples and data processing, axial images and secondary 2D and 3D reconstructions were obtained, with elements containing uric acid marked in red, and those containing calcium compounds in white (Figures 1-8).

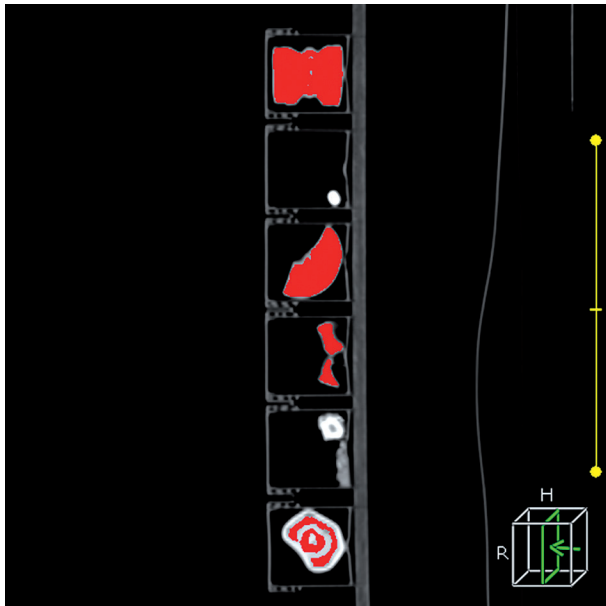


Figure 1. DECT – 6 samples of surgically removed urinary stones – 2D reconstruction in the sagittal plane; respectively from above: uric acid, calcium oxalate, uric acid, uric acid, calcium phosphate, layered stone containing both uric acid and calcium compounds; uric acid marked in red, calcium compounds in white

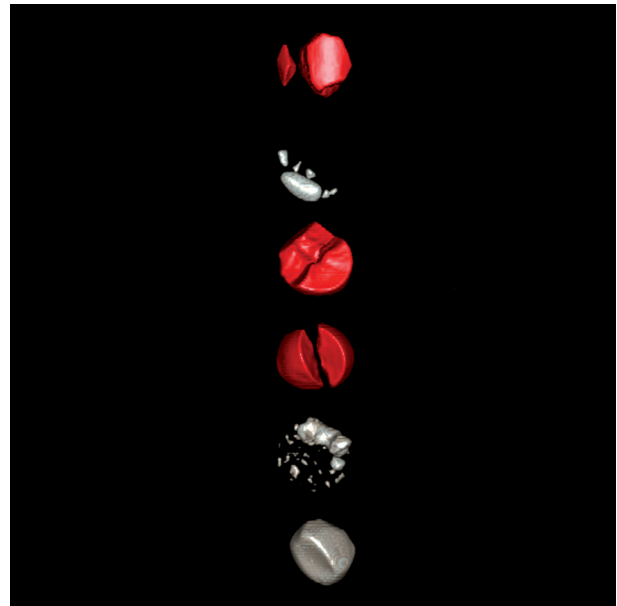


Figure 2. DECT – 6 samples of surgically removed urinary stones – 3D reconstruction; respectively from above: uric acid, calcium oxalate, uric acid, uric acid, calcium phosphate, layered stone containing both uric acid and calcium compounds; uric acid marked in red, calcium compounds in white

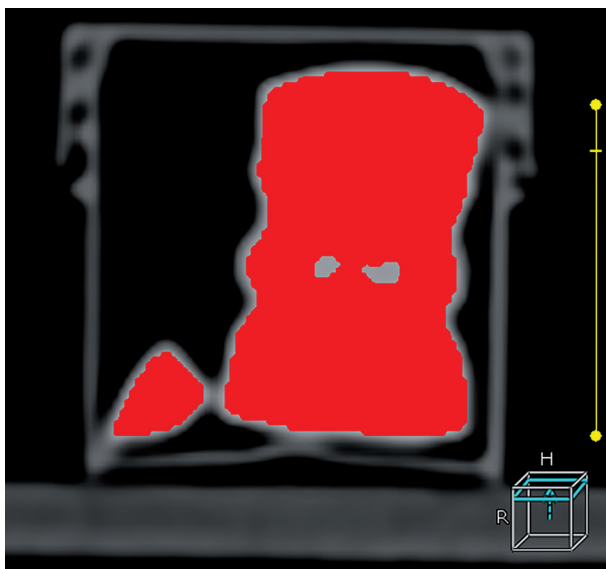


Figure 3. DECT – a sample of surgically removed urinary stone – axial cross section – uric acid




Figure 4. DECT – a sample of surgically removed urinary stone – axial cross section – calcium oxalate

In five out of six samples (Figures 3-7) the assessment of the stones' composition in DECT (three samples determined as uric acid and two samples as calcium compounds) agreed with the result of physico-chemical analysis (three samples defined as uric acid, one as calcium phosphate, one as calcium oxalate). In DECT technique, it was not possible to determine more precisely the type of calcium compounds (calcium phosphate vs. calcium oxalate), as verified in the physico-chemical study.

In one of the six samples (Figure 8), the stone determined in the physico-chemical analysis as a uric acid de-

posit, in DECT turned out to have a complex layered structure, containing both uric acid and calcium compounds.

Discussion

Commonly available multi-row CT allows the assessment of only the size and location of stones. Due to the overlapping ranges of CT attenuation values among different types of calculi, it is impossible to determine their chemical composition in a typical CT scan [12].

The introduction of the DECT method changed it – dual energy computed tomography allows one to differ-

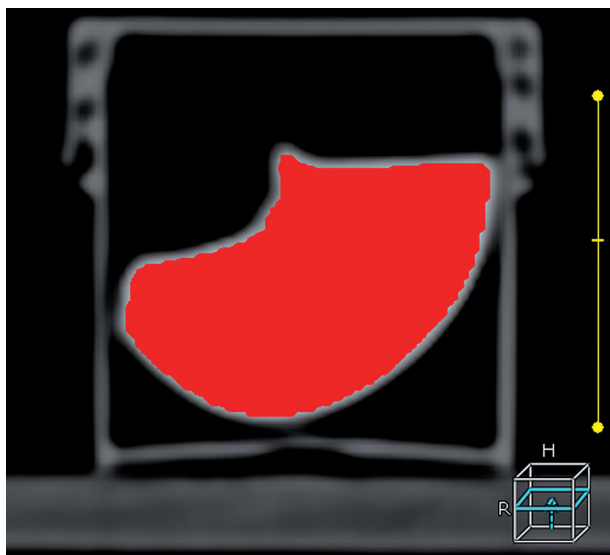


Figure 5. DECT – a sample of surgically removed urinary stone – axial cross section – uric acid

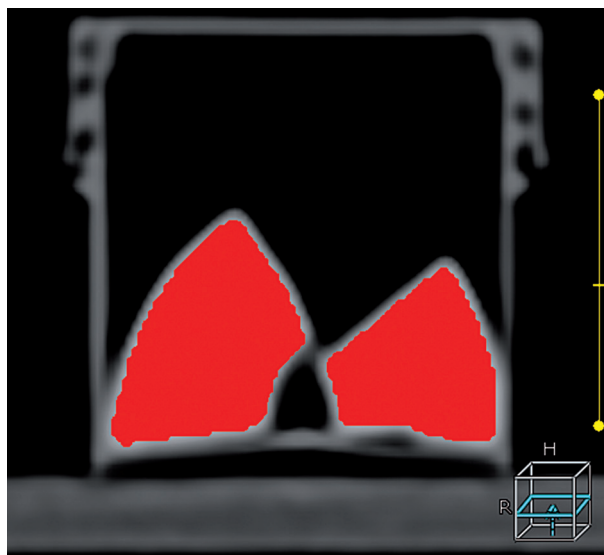


Figure 6. DECT – a sample of surgically removed urinary stone – axial cross section – uric acid




Figure 7. DECT – a sample of surgically removed urinary stone – axial cross section – calcium phosphate

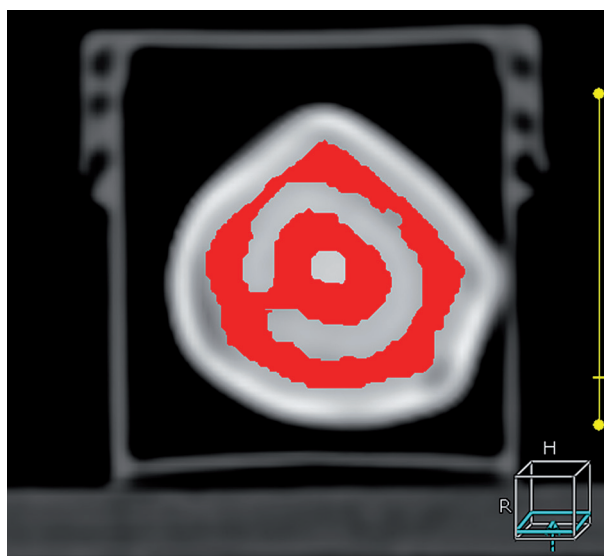


Figure 8. DECT – a sample of surgically removed urinary stone – axial cross section – layered concrement containing both uric acid and calcium compounds

entiate with high accuracy uric acid from non-uric acid stones, both *in vivo* [7,8] and *in vitro* [9-11].

Our *in vitro* DECT study of the stones' composition, with analysis performed by the scanner manufacturer's software, confirmed the possibility of distinguishing uric acid from calcium-containing concrements; however, it was not possible to determine more precisely the type of calcium compounds.

Similarly, Graser *et al.* [9] found that in DECT it is possible to reliably distinguish between uric acid and other types of stones, but the range of attenuation values for struvite stones largely overlapped with the range for mixed stones and partially with the range for calcified concrements.

According to data from the literature, more groups of deposits can be distinguished by means of more advanced software and modification of the beam filtration.

Hidas *et al.* [8], in a study using a CT scanner with a single x-ray tube and a dual array of high and low energy photon detectors, assessed the urinary stones in patients *in vivo* preoperatively and compared the results with post-operative X-ray diffraction analysis of the stones.

Before *in vivo* CT scanning, the researchers created a catalog of stones with known chemical composition, in which they assigned deposits to seven groups (including uric acid, cystine, struvite, apatite, weddellite, whewellite and brushite) and then they evaluated the ratio of low-energy attenuation to high-energy attenuation for every above-mentioned stone. Using data obtained from an *in vitro* CT study, researchers were able to distinguish between uric acid, cystine and calcium stones, in a CT study performed *in vivo*. Due to some similarity of chemical structure, technical limitations of the CT scanner

and differences in radiation beam absorption in patients with different body structures, it was not possible to distinguish between struvite stones and subtypes of calcium deposits.

Fung *et al.* [10], using a dual-source CT scanner with a tin filter attached to the X-ray tube emitting high-energy radiation, were able to differentiate *in vitro* stones containing uric acid, calcium oxalates and calcium phosphates. Application of a tin filter resulted in better separation of the attenuation values of oxalates and calcium phosphates, enabling their differentiation.

Similarly, Qu *et al.* [11] evaluated the composition of stones *in vitro*, using a dual energy, dual-source CT scanner with an additional tin filter. In this study it was possible to distinguish five groups of concrements (group 1: uric acid, uric acid dihydrate, ammonium acid urate; group 2: cystine; group 3: struvite; group 4: calcium oxalate monohydrate, calcium oxalate dihydrate, brushite; group 5: hydroxyapatite and carbonate apatite). However, the authors noted partial overlap of the features of some concrement types. Moreover, the additional tin filter is an option available only from some manufacturers.

In our dual energy CT study, in most cases the assessment of the chemical composition of stones agreed with the result of the physico-chemical analysis (uric acid vs. calcium deposits); in one case, however, we found discordance. The reason was a mixed-layered structure of the stone, built of both uric acid and calcium compounds.

Similarly, Manglaviti *et al.* [7], investigating the concrements with a dual-source CT apparatus, in four cases found a discrepancy between the CT assessment of the chemical composition of concrements and the result of the crystallographic study. All the erroneously evaluated concrements had a mixed chemical structure (they con-

tained uric acid and hydroxyapatite) and had a diameter below 1 cm. Probably the mixed chemical structure of the concrement, combined with its small size, contribute to the accuracy reduction in the DECT technique analysis.

Our study concerned the use of DECT technique to assess urinary stone composition *in vitro*, whereas in the case of such *in vivo* assessment, the radiation dose used during the study becomes an important factor. The computed tomography dose index (CTDIvol) for our protocol was 33.2 mGy, which is a significantly higher value than that used in standard abdominal and pelvic examinations (about 7-18 mGy) and much higher than the value in the dedicated low-dose protocol for the assessment of urinary tract stones (approx. 4 mGy). Fortunately, in the case of *in vivo* evaluation, the DECT protocol with the higher dose is used only in the range including the location of the concrements. Moreover, Chaytor *et al.* [13] found that reliable *in vivo* DECT assessment of stone composition is possible using a lower CTDIvol value of 11.7 mGy.

Conclusions

1. Dual-energy CT technique enables differentiation of uric acid from calcium-containing urinary stones.
2. Using the available hardware and software, more detailed distinction of calcified stone subtypes was not possible.
3. Evaluation of urinary stones' chemical composition in dual-energy computed tomography may be limited in the case of concrements with mixed chemical composition.

Disclosure

The authors report no conflict of interests.

References

1. Edvardsson V, Indridason O, Haraldsson G, et al. Temporal trends in the incidence of kidney stone disease. *Kidney Int* 2013; 83: 146-152.
2. Sułowicz W, Stompór T, Drabczyk R. Kamica nerkowa. In: Gajewski P (ed.). *Interna Szczeklika* 2016. Medycyna Praktyczna, Liszki 2016; 1567.
3. Świniarski P. Kamica nerkowa – rodzaje, objawy, leczenie. *Przegląd Urologiczny* 2014; 2: 13.
4. Koźmińska E. Kamica moczowa. In: Borkowski A (ed.). *Urologia*. Wydawnictwo Lekarskie PZWL, Warszawa 2015; 207-210.
5. Johnson TRC. Dual-energy CT: general principles. *AJR Am J Roentgenol* 2012; 199: S3-S8.
6. Dale J, Gupta Rajan T, Marin D, et al. Imaging advances in urolithiasis. *J Endourol* 2017; 31: 623-629.
7. Manglaviti G, Tresoldi S, Guerrer CS, et al. In vivo evaluation of the chemical composition of urinary stones using dual-energy CT. *AJR Am J Roentgenol* 2011; 197: W76-83.
8. Hidas G, Eliahou R, Duvdevani M, et al. Determination of renal stone composition with dual-energy CT: in vivo analysis and comparison with x-ray diffraction. *Radiology* 2010; 257: 394-401.
9. Graser A, Johnson TR, Bader M, et al. Dual energy CT characterization of urinary calculi: initial in vitro and clinical experience. *Invest Radiol* 2008; 43: 112-119.
10. Fung GS, Kawamoto S, Matlaga BR, et al. Differentiation of kidney stones using dual-energy CT with and without a tin filter. *AJR Am J Roentgenol* 2012; 198: 1380-1386.
11. Qu M, Ramirez-Giraldo JC, Leng S, et al. Dual-energy dual-source CT with additional spectral filtration can improve the differentiation of non-uric acid renal stones: an ex vivo phantom study. *AJR Am J Roentgenol* 2011; 196: 1279-1287.
12. Platt JF, Kaza RK. Renal applications of dual-energy CT. *Abdom Radiol (NY)* 2016; 41: 1122-1132.
13. Chaytor RJ, Rajbabu K, Jones PA, et al. Determining the composition of urinary tract calculi using stone-targeted dual-energy CT: evaluation of a low-dose scanning protocol in a clinical environment. *Br J Radiol* 2016; 89: 20160408.