

# Out of the blue: Blue blood.!

Sir,  
A 29-year-old male patient with carcinoma of the gastroesophageal junction was posted for transhiatal esophagectomy. Intraoperatively, 2 units of packed red cells were ordered for transfusion to the patient and were issued to the patient as per the departmental standard operating procedure including pretransfusion testing and mandatory visual inspection. During transfusion in the operation theater, anesthesiologists noticed a distinct blue hue in the tubings of the blood administration set [Figure 1]. Immediately transfusion was stopped and noticing that the color of the blood bag being normal, a different blood administration set was connected and transfusion was restarted. The blue color reappeared in the administration set. The transfusion was stopped and the blood bag along with

the transfusion set was received by the transfusion department. The blood bag had no discoloration. The tubing of the administration set carrying blood had bluish discoloration which intensified under artificial source of light. The blood that was allowed to flow through the administration set was collected in a clean test tube and was noticed not to have any discoloration or hemolysis. The administration set was flushed with normal saline repeatedly and was then compared with another unused new administration set. This particular administration set (manufactured by P. H. Medisurge, Ahmedabad, Gujarat, India) had a bluish tinge [Figure 2]. The problem was noticed only with the particular batch (lot no ABT-07) of administration set and did not recur after changing the batch.

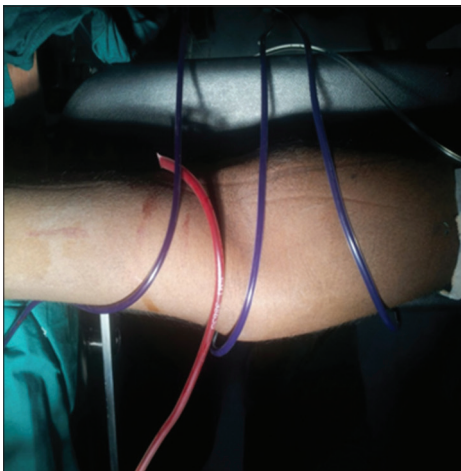


Figure 1: Blood in the infusion set with a blood bag tube for comparison

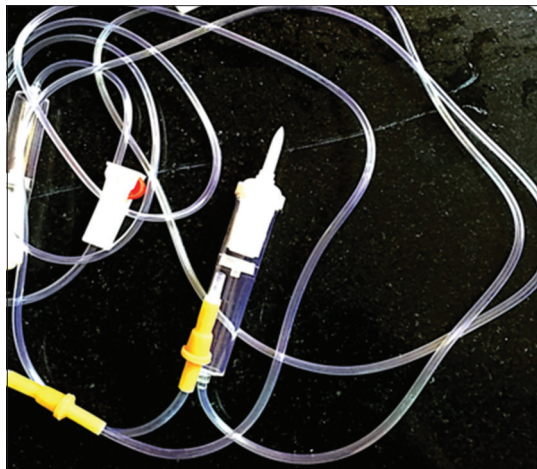


Figure 2: Completely flushed blood administration set


**Financial support and sponsorship**  
Nil.

**Conflicts of interest**  
There are no conflicts of interest.

**Lenin Babu Elakkumanan,  
Jayasree Cherukat<sup>1</sup>, Jane Nithya Tolson,  
Sarath Sistla<sup>2</sup>, Abhishekh Basavarajegowda<sup>1</sup>**  
*Departments of Anaesthesiology, <sup>1</sup>Transfusion Medicine and  
<sup>2</sup>General Surgery, Jawaharlal Institute of Postgraduate Medical  
Education, Puducherry, India*

**Address for correspondence:**  
Dr. Abhishekh Basavarajegowda,  
Department of Transfusion Medicine, Jawaharlal Institute of  
Postgraduate Medical Education, Room No. 185, Superspeciality  
Block, Puducherry - 605 006, India.  
E-mail: drabhighowda@gmail.com

This is an open access article distributed under the terms of the Creative Commons Attribution-NonCommercial-ShareAlike 3.0 License, which allows others to remix, tweak, and build upon the work non-commercially, as long as the author is credited and the new creations are licensed under the identical terms.

Access this article online	
Website: <a href="http://www.ajts.org">www.ajts.org</a>	Quick Response Code:
DOI: 10.4103/ajts.AJTS_75_16	

**How to cite this article:** Elakkumanan LB, Cherukat J, Tolson JN, Sistla S, Basavarajegowda A. Out of the blue: Blue blood.!. *Asian J Transfus Sci* 2017;11:212.

© 2017 Asian Journal of Transfusion Science | Published by Wolters Kluwer - Medknow