

Case Report

Pro- and anti-inflammatory cytokine expression and histopathological characteristics in canine brain with traumatic brain injury

Chi-Ho Yu¹, Ji-Young Yhee¹, Jong-Hyuk Kim¹, Keum-Soon Im¹, Na-Hyun Kim¹, Dong-In Jung², Hee-Chun Lee³, Seung-Ki Chon⁴, Jung-Hyang Sur^{1,*}

¹Department of Pathobiology, Small Animal Tumor Diagnostic Center, College of Veterinary Medicine, Konkuk University, Seoul 143-701, Korea

Departments of ²Internal Medicine, and ³Medical Imaging, College of Veterinary Medicine, Gyeongsang National University, Jinju 660-701, Korea

⁴Hyu Animal Clinic, Iksan 570-973, Korea

We analyzed the expression level and cellular localization of pro- and anti-inflammatory cytokines and histopathologically characterized canine traumatic brain injury (TBI). Canine TBI brains revealed subarachnoid and cerebral cortical hemorrhage, neutrophilic infiltration, neuronal necrosis, astrocytosis, and vasogenic edema. Immunohistochemical evaluations suggested that both pro-inflammatory cytokines [interleukin (IL)-1 β , IL-6, and tumor necrosis factor- α] and anti-inflammatory cytokines [IL-10 and transforming growth factor-beta (TGF- β)] were highly expressed in neurons and neutrophils. In particular, the highest magnitude of expression was identified for IL-1 β and TGF- β . This data helps describe the pathologic characteristics of canine TBI, and may help in the design of potential therapeutic approaches to control secondary damage by inflammatory cytokines.

Keywords: interleukin-1, interleukin-6, transforming growth factor-beta, traumatic brain injury, tumor necrosis factor-alpha

Traumatic brain injury (TBI) is caused by mechanical insults including compression, stretching, and laceration. Post-TBI progressive neuronal damage and loss can be divided into two different mechanisms. The initial damage is the direct result of mechanical injury. Secondary or delayed damage results from intra-cerebral or subdural hemorrhage, which causes the release of trauma-induced neurochemical substances including inflammatory cytokines, free radicals, and complement components with neurotoxic effects on neurons and glial cells [4,6,8,9,11].

TBI in dogs is generally less prevalent than human TBI

[12]. The most common causes of head trauma in dogs include traffic accidents and vehicular trauma, while other causes include falls, penetrating wounds, and kicks [3]. Although canine TBI studies are increasing in frequency [2,5,7,10], post-trauma pathological studies and inflammatory responses are poorly understood in canine patients; most studies have evaluated mice and rats. Human and dog clinical studies of inflammation in TBI have been limited to blood or cerebrospinal fluid sampling from the patients. As such, relatively rare histopathological analyses exist concerning TBI in clinical cases from dog post-mortem specimens.

In this study, we sought to provide a histopathological analysis of canine acute TBI, to characterize the expression of anti-inflammatory cytokines [Interleukin (IL)-10 and transforming growth factor-beta (TGF- β)] and pro-inflammatory cytokines [IL-1 β , IL-6, tumor necrosis factor-alpha (TNF- α)] in the canine acute TBI brain. In addition, we performed semi-quantitative analyses regarding the expression of inflammatory cytokines in the canine acute TBI brain.

Brain specimens, ranging in age from 1.5 to 15 years, were examined at the Department of Pathology, Konkuk University Animal Teaching Hospital, Korea. Brain specimens were collected from nine dogs who had sustained TBIs to vehicular trauma or falls. Histopathological analysis was based on hematoxylin and eosin staining by a veterinary pathologist. Canine brains from dogs with no clinical history of neurologic disease were used as negative controls.

Tissue sections were prepared from formalin-fixed, paraffin-embedded blocks. Serial 4 micrometer-thick sections were acquired from each paraffin-block for immunohistochemical staining (EnVision System-HRP; Dako, USA). A set of monoclonal and polyclonal

*Corresponding author

Tel: +82-2-450-4153; Fax: +82-2-455-8124

E-mail: jsur@konkuk.ac.kr

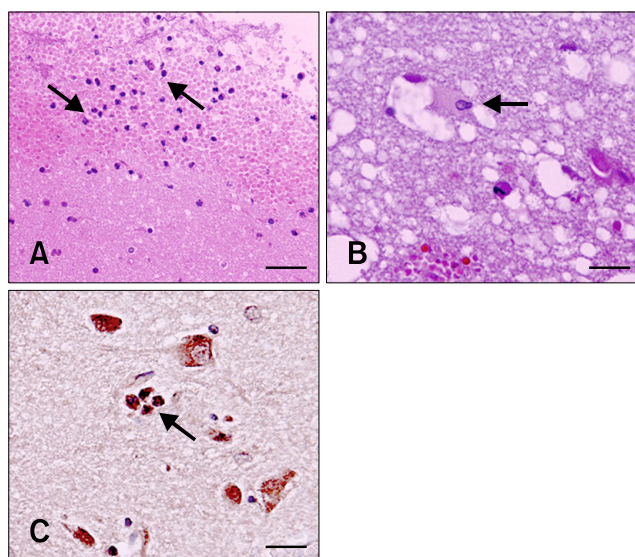


Fig. 1. Dog brain with traumatic brain injury. (A) Neutrophils mixed with red blood cells are infiltrated into the cerebral cortex. (B) Gemistocyte was observed around the lesion with infiltrated red blood cells. (C) Strong positive signals for TGF- β of the cytoplasm of neurons and neutrophils (arrow) were observed in the contusion area. A and B: H&E stain, C: Immunohistochemical staining; counterstain with hematoxylin. Scale bars = 100 μ m (A); 18 μ m (B and C).

antibodies were used: IL-1 β , IL-6, TNF- α , TGF- β , Iba-1 (Santa Cruz, USA), IL-10 (R&D Systems, USA), and glial fibrillary acidic protein (GFAP; Dako, USA).

The hematoma was microscopically identified in the cerebral cortex and subarachnoid space. Neutrophil infiltration was identified in the cerebral cortex along with hemorrhages (Fig. 1A). Lesions revealed necrotic neurons, gemistocytes, astrocytes, and vasogenic edema. Neuronal necrosis resulted in neuronal cytoplasmic eosinophilia with pyknotic nuclei. Gemistocytes characterized the synthesis of increased glial filament, eccentric nuclei, and abundant pink homogenous cytoplasm were indicated in the gray matter around the lesion (Fig. 1B). Astrocytosis and vasogenic edema around the vessels were observed in the gray matter adjacent to pathologic lesions.

GFAP was weakly expressed in normal brain tissue, while in traumatic cases, expression of GFAP was strong throughout the cerebral cortex. Astrocytosis was detected in the gray matter adjacent to the peri-hematoma, particularly at sites with severe cortical hemorrhage.

Results of immunohistochemical studies are summarized in Table 1. Expression of pro- and anti-inflammatory cytokines was determined by immunohistochemistry (IHC) of paraffin-embedded sections from control and TBI brains. The control brains showed little expression of inflammatory cytokines in the brain. In contrast, immunoreactivity for pro-inflammatory cytokines (IL-1 β ,

Table 1. The results of immunochemistry for inflammatory cytokines

No.	TNF- α	IL-1 β	IL-6	IL-10	TGF- β
1	++	++	++	+	+++
2	++	++	+	+	++
3	++	+++	+	+	++
4	++	++	+	+	++
5	+++	+++	+	+	+
6	++	++	+	+	++
7	++	+++	+	+	++
8	+++	+++	++	+	++
9	++	+++	+	+	+++

+: positive, ++: moderate positive, +++: strong positive.

IL-6, and TNF- α) and anti-inflammatory cytokines (TGF- β and IL-10) were identified in all TBI brains. IL-1 β , IL-6, and TNF- α expression were observed in both neutrophils and neurons. As with the pro-inflammatory cytokines, immunoreactivity to IL-10 and TGF- β was also detected in neutrophils and neurons (Fig. 1C). Expression of cytokines was exuberant in the damaged parenchyma around the peri-hematoma and as well as in the inflammatory cells of the hematoma.

IHC was used to analyze IL-1 β , IL-6, TNF- α , IL-10, and TGF- β expression in TBI brains. Pro-inflammatory cytokines including IL-1 β , IL-6, and TNF- α IHC resulted in an average number of positive cells under 1.3 mm² of 206, 190, and 108 in TBI brains, respectively. Results for anti-inflammatory cytokines, including IL-10 and TGF- β were an average number of positive cells under 1.3 mm² of 62 and 327 in TBI brains, respectively.

This study described histopathological characterization, anti- and pro-inflammatory cytokine expression, and semi-quantitative analysis of inflammatory cytokines in the canine TBI brain. For the first time in a canine-based study, significant expression of both pro- and anti-inflammatory cytokines in acute TBI brains was identified compared to control brains. Inflammatory cytokines were also observed in neutrophils in the contusion and peri-contusion areas. Semi-quantitative analysis demonstrated that IL-1 β levels were much more highly expressed than levels of IL-6 and TNF- α with respect to pro-inflammatory cytokines and with respect to anti-inflammatory cytokines, TGF- β expression was increased more than that of IL-10. Further, histopathological characterization indicated marked hematoma of cerebral cortex and subarachnoid space, infiltration of neutrophils, neuronal necrosis, gemistocytes, astrocytosis, and vasogenic edema. In this study, neuronal cell bodies were shrunken and eosinophilic, and nuclei were pyknotic. Astrocytes increase in number and size in

response to injury and swell after brain injuries including TBIs and strokes due to the increased uptake of sodium, chloride, and potassium that occurs in order to maintain homeostasis [12]. GFAP of immunohistochemical analysis demonstrated astrocyte enlargement and increased number in the peri-hematoma lesion. Astrocytes transform into gemistocytic astrocytes (gemistocytes) with irreversible injury. Gemistocytes have eccentric and enlarged nuclei, abundant pink homogenous cytoplasm, and increased glial filament. Gemistocytes were observed in the damaged cortex of TBI in H&E stained samples.

TBI activates an inflammatory reaction initiated by the release of pro-inflammatory cytokines; IL-1 β , IL-6, and TNF- α have been observed in the human and rodent brain after TBI [1,13]. Our study supports previous findings, and, to our knowledge, identifies both the distribution and level of cytokine expression in the acute TBI canine brain. The present study also demonstrates that inflammatory cytokines such as IL-1 β , IL-6, TNF- α , IL-10, and TGF- β contribute to brain inflammation following the mechanical traumatic damage in the canine brain. Furthermore, IL-1 β and TGF- β are major contribute to brain inflammation in cases of canine TBI.

Acknowledgments

We thank to Ms. R. H Jang for excellent technical assistance. This paper was supported by Konkuk University Research Fund in 2009. This report represents part of the thesis submitted by Dr. C. H Yu to fulfill the requirements of a Ph.D.

References

1. **Allan SM, Rothwell NJ.** Cytokines and acute neurodegeneration. *Nat Rev Neurosci* 2001, **2**, 734-744.
2. **Foley C, Bracker K, Drellich S.** Hypothalamic-pituitary axis deficiency following traumatic brain injury in a dog. *J Vet Emerg Crit Care (San Antonio)* 2009, **19**, 269-274.
3. **Fossom T.** *Small Animal Surgery*. 3rd ed. Chap. 37. pp.1379-1380, Mosby, St. Louis, 2007.
4. **Goss JR, Styren SD, Miller PD, Kochanek PM, Palmer AM, Marion DW, DeKosky ST.** Hypothermia attenuates the normal increase in interleukin 1 β RNA and nerve growth factor following traumatic brain injury in the rat. *J Neurotrauma* 1995, **12**, 159-167.
5. **Hayes GM.** Severe seizures associated with traumatic brain injury managed by controlled hypothermia, pharmacologic coma, and mechanical ventilation in a dog. *J Vet Emerg Crit Care (San Antonio)* 2009, **19**, 629-634.
6. **Holmin S, Schalling M, Höjeberg B, Nordqvist AC, Skeftruna AK, Mathiesen T.** Delayed cytokine expression in rat brain following experimental contusion. *J Neurosurg* 1997, **86**, 493-504.
7. **Kitagawa M, Okada M, Kanayama K, Sakai T.** Traumatic intracerebral hematoma in a dog: MR images and clinical findings. *J Vet Med Sci* 2005, **67**, 843-846.
8. **Kontos HA, Wei EP.** Superoxide production in experimental brain injury. *J Neurosurg* 1986, **64**, 803-807.
9. **Kossmann T, Stahel PF, Morganti-Kossmann MC, Jones JL, Barnum SR.** Elevated levels of the complement components C3 and factor B in ventricular cerebrospinal fluid of patients with traumatic brain injury. *J Neuroimmunol* 1997, **73**, 63-69.
10. **Laurent S, Thibaud JL, Hordeaux J, Reyes-Gomez E, Delisle F, Blot S, Colle MA.** Chronic traumatic brain injury in a dog. *J Comp Pathol* 2010, **143**, 75-80.
11. **Lynch DR, Dawson TM.** Secondary mechanisms in neuronal trauma. *Curr Opin Neurol* 1994, **7**, 510-516.
12. **McGavin MD, Zachary JF.** *Pathologic Basis of Veterinary Disease*. 4th ed. Chap. 14. pp. 938-939, Mosby, St. Louis, 2006.
13. **Morganti-Kossmann MC, Rancan M, Stahel PF, Kossmann T.** Inflammatory response in acute traumatic brain injury: a double-edged sword. *Curr Opin Crit Care* 2002, **8**, 101-105.