



Locked posterior dislocation of the shoulder: A systematic review

Ozgur Basal¹

Recep Dincer²

Bulent Turk³

- Locked posterior dislocation of the shoulder is very rare. Seizures and trauma are the most common causes of this injury.
- There is no current benchmark treatment strategy for these rare cases.
- This study has shown that reconstruction of the shoulder joint in an anatomical way in acute and chronic cases up to 16 weeks provides good results.
- The purpose of this study is to evaluate the results of different treatment procedures with outcomes and to compare the results of the same procedures in acute and chronic cases.

Keywords: locked posterior dislocation of the shoulder; posterior fracture-dislocation of the shoulder; reverse Hill-Sachs lesion

Cite this article: *EFORT Open Rev* 2017;3:15-23.

DOI: 10.1302/2058-5241.3.160089

Introduction

Locked posterior dislocation of the shoulder (LPDS) is an uncommon condition that is often misdiagnosed and becomes chronic due to an inadequate physical examination. LPDS cases include actual fracture-dislocations, impression fractures and isolated posterior dislocations without any fracture pattern.¹⁻³ Posterior fracture-dislocation of the shoulder (PFDS) is rare in orthopaedic practice, constituting only 2% to 4% of all shoulder dislocations, and its annual incidence is 0.6 in 100 000.^{4,5} Impression fracture of the anteromedial humeral head (also called 'reverse Hill-Sachs lesion' [RHL]) is reported to occur in 40% to 90% of patients with an initial dislocation.^{6,7} In addition to their rarity, what makes LPDS cases important is that they are easily missed. These cases are frequently missed in the initial examination as the occurrence of the dislocation is overlooked because urgent

treatment of the seizure is the priority.^{5,8} Cases that are diagnosed after three weeks are called 'neglected' PFDSs, while cases neglected for more than three weeks are called 'chronic' PFDSs.⁹ When the literature is reviewed, almost all chronic PFDS cases were reported to be LPDSs.¹⁰ However, the group of LPDS may include the cases of PFDS as well because it can only occur with a RHL. Thus, it is necessary to evaluate the surgical and conservative treatment results of two different patient groups separately. PFDS cases are classified by the number of fragments, as described by Neer.¹¹ According to this classification, the treatment results of fractures with three and four parts are not satisfactory. The number of fragments, the time elapsed from injury to surgery, age, treatment options and the experience of the surgeon all affect the results. There is no generally accepted approach for the treatment of neglected PFDS cases. However, the treatment is decided according to the amount of impaction (%) in isolated cases accompanied by the RHL. In these isolated cases, techniques such as the disimpaction of the fracture, lesser tubercle transfer, reconstruction with allograft and the filling of the defect are described.¹²⁻¹⁵ Arthroplasty is preferred in cases in which 50% or more of the articular surface is affected.¹⁶

There is no gold standard treatment for LPDS and no specific study on the treatment algorithm has been published. This article provides a systematic review of the current literature, describes the diagnosis and discusses the different treatment options for LPDS.

Materials and methods

Posterior dislocation cases reported between 1987 and 2016 and accompanied by PFDS, as well as isolated RHLs, were included in this study. The PubMed, Web of Science and ScienceDirect databases were scanned for this purpose. Databases were searched using the term 'posterior dislocation and shoulder' in the title/abstract/keyword parts according to the Boolean operator scanning

Table 1. Inclusion/exclusion criteria

Inclusion criteria	Exclusion criteria
General adult population	Case reports/series with no details about patients (age, treatment, follow-up, results)
PFDS or RHL with 20% and over defect	Only observation or descriptive studies without follow-up
Cases with treatment and detailed result	Cases with shoulder instability or recurrence
Patients with a minimum of ten months follow-up	Review articles, radiological reports, technical notes
Interval between injury and treatment reported patients	Patients with glenoid bone loss or fracture
Original publications in English language	At least one of these scores not reported cases (CMS, ASES, Rowe, Neer, JOA)

LPDS, locked posterior dislocation of shoulder; PFDS, posterior fracture-dislocation of shoulder; RHL, reverse Hill-Sachs lesion; CMS, Constant-Murley score; ASES, American Shoulder and Elbow Surgeons; JOA, Japanese Orthopedic Association

Table 2. Etiological distribution of acute and chronic cases

LPDS	Seizure n (%)	Fall n (%)	RTA n (%)	Electrocution n (%)	Sports injuries n (%)
Acute cases	34 (45.9)	23 (31.1)	11 (14.9)	4 (5.4)	2 (2.7)
Chronic cases	52 (66.7)	14 (17.9)	5 (6.4)	6 (7.7)	1 (1.3)
Undetailed case series	80 (39.8)	73 (36.31)	31 (15.42)	17 (8.45)	0
Total	166 (47.02)	110 (31.16)	47 (13.31)	27 (7.64)	3 (0.84)

RTA: road traffic accidents

principles. The articles which were especially reported were those with numerical shoulder scores, such as Constant-Murley scoring (CMS). In total, 1120 articles were found in PubMed, 796 in Web of Science and 238 in ScienceDirect. Articles taken from all three databases were combined with Endnote X7 software. Duplicated publications were removed. The Endnote library was simplified according to the inclusion/exclusion criteria (Table 1). Articles in English for adult patients were included. Full-text scanning was made for 486 articles after the selection. The cases were divided into two groups according to our conformity criteria of acute or misdiagnosed/chronic. The articles were scanned with the words ‘missed’, ‘neglected’, ‘chronic’, ‘overlooked’, ‘unreduced’ and ‘undiagnosed’ in order to separate chronic or neglected cases. LPDSs that were diagnosed late were noted within the specified criteria. Finally, this study included 30 articles (111 cases) in the acutely treated LPDS group and 31 articles (91 cases) in the neglected LPDS group. In total, 104 neglected and 124 acutely treated shoulders were assessed according to the treatment and its results.

Statistical analysis

All data are expressed as means ± standard deviation (SD). Statistical analysis was performed using SPSS 20.0 (IBM, Chicago, IL, USA). Descriptive statistics are reported as the mean with the range for continuous measures and as the number and percentage of discrete measures. Independent samples t-test was used to compare acute and chronic groups. Non-parametric data were analysed by the Mann-Whitney U and Wilcoxon tests for two independent samples. K independent samples with the Kruskal-Wallis test was used to compare selected cases. The values of $p < 0.05$ were considered as significant.

Results

PFDS cases made up a major part of acutely treated LPDS cases. Of 124 acute LPDS that we included in our study, 94 (75.8%) were also PFDS. Only 20 shoulders (19.23%) in the chronic LPDS group were treated with the PFDS diagnosis. When LPDS cases are assessed aetiologically, the most frequent cause in both acute and chronic cases was a seizure. This was followed by falling and traffic accidents (Table 2). The seizure-related LPDS rate of incidence (66.7%) was higher in chronic cases than acute cases. There were 26 LPDS patients with bilateral involvement, 23 (88.46%) of which were attributed to seizures and three (11.64%) were caused by electric shock. We believe that seizure-related LPDS is frequently neglected in the first examination ($p = 0.021$). The other most frequent reasons for LPDS are falling (including indirect traumas), traffic accidents and electric shocks. Acute and chronic percentages are close (31.1% to 17.9%) in trauma-related LPDS cases, and this verifies that LPDS cases are fractures that can be easily neglected. LPDS cases can be missed in the initial examination independently of aetiology despite radiological and clinical findings.

The time from injury to surgery (TFIS) duration also affects the results of chronic LPDS treatment. However, whether the poor results are related to a time delay or the preferred method of treatment is not clear. The treatments and results of the cases included in the study are listed in Table 3. The cases in which two or more of the summarized treatment methods were applied together were named ‘combined procedures’ (e.g. open reduction and stabilization with modified McLaughlin procedure). In this study, the average TFIS was found to be 23.30 ± 41.68 weeks (3 to 344). Although LPDS cases with longer delay were reported in the literature, they were not included in

Table 3. Analysis of acute and chronic LPDS cases according to age, bilaterality, RHL, CMS and follow-up

	Age	Bilaterality n (%)	RHL (%)	CMS	Follow-up
Acute cases	43.87 ± 13.82	13 (23.7)	33.68 ± 11.06	83.54 ± 12.08	34.67 ± 23.33
Chronic cases	45.18 ± 12.02	13 (20.3)	38.97 ± 9.91	75.96 ± 16.95	40.19 ± 17.04

Table 4. The treatments and results of the cases included in the study

	Acute					Chronic					p-values	
	n	RHL (%) Mean ± SD	Constant score Mean ± SD	Min- max. CMS	Follow-up (months)	n	TFIS (week)	RHL (%) Mean ± SD	Constant score Mean ± SD	Min-max. CMS		Follow-up (months)
Arthroplasty (TSA/HA)	8	50 ± 8.16	59 ± 11.14	49-71	25.87 ± 24.99	17	65.59 ± 89.8	49.5 ± 5.5	60.61 ± 10.20	42-82	27.36 ± 14.49	0.885
Allograft/autograft fixation	10	37.5 ± 10.87	86.78 ± 3.60	83-95	48.2 ± 29.33	4	12.75 ± 8.62	40 ± 8.16	89.67 ± 3.51	86-93	35 ± 24.08	0.160
McLaughlin/modified McLaughlin procedure	5	29.4 ± 3.58	99.33 ± 1.15*	98-100	65.4 ± 26.84	28	15.61 ± 15.27	34.83 ± 5.42	78.40 ± 10.71	60-86	23.57 ± 10.92	0.023*
Modified McLaughlin procedure + graft fixation	0					7	8.43 ± 6	39.29 ± 6.73	83.5 ± 5.36	77-90	22.43 ± 4.96	
Balloon expansion + PMMA injection	1	NR	84.5	84.5	24	2	3	30	79 ± 1.41	78-80	22	
Glenoid augmentation + graft	0					8	21.37 ± 9.91	39.25 ± 11.27	77.5 ± 18.08	55-98	43 ± 8.7	
Rotational osteotomy	0					9	21.56 ± 17.98	30.56 ± 7.26	71.67 ± 18.87	40-90	21.67 ± 6.95	
Frozen spherical-shaped allograft	1	35	†		12	25	14.32 ± 9.08	40.8 ± 8.12	79.52 ± 18.90	40-100	81.72 ± 33.43	
Combined procedures	3	NR	90.33 ± 6.35	83-94	24	1	12	30	69	69	36	
Closed reduction (with or without pin fixation)	19	24.83 ± 4	85 ± 15.11	58-100	38.63 ± 27.67	2	6 ± 2.83	20	100	100	48	
Anatomic reconstruction with plate or K-wire fixation	67	NR	82.6 ± 11.24	16-100	28.79 ± 15.26	1	8	75%	NR		24	
Bioabsorbable screw reconstruction	2	45	92.5 ± 3.54	90-95	26	0						
Open reduction	8	NR	†		57.5 ± 33.18	0						
Total	124					104						

*there is a significant difference between groups (p < 0.05)

†improper result or outcome

TSA, total shoulder arthroplasty; HA, hemiarthroplasty; RHL, reverse Hill-Sachs lesion; SD, standard deviation; PMMA, polymethyl methacrylate; K, Kirschner; CMS, Constant-Murray score; TFIS, time from injury to surgery; NR, not reported

the study since they did not fit our inclusion criteria. Of 104 late-diagnosed shoulders, 75 (72.11%) were diagnosed within 16 weeks of the injury.

The average CMS of the missed LPDS cases operated within weeks 3 and 16 was 79.09 ± 15.72 (mean 52) and the score of those that were operated after week 16 was 67.83 ± 18.72 (mean 20). There was a significant difference between both groups and this difference resulted from the group that was operated between weeks 3 and 16 (p = 0.022). Upon investigating the preferred treatment options and results in acute and chronic LPDS cases, arthroplasty cases affected the results negatively in both groups (Table 4). When different treatment methods in chronic LPDS cases were compared, while there was no significant difference between those to which arthroplasty was applied and those to which rotational osteotomy was

applied (p = 0.134); a statistical difference was found between the arthroplasty group and other treatment methods (p < 0.05). There was a significant difference between chronic LPDS cases treated with open reduction and allograft/autograft and the group in which rotational osteotomy was applied (p = 0.023). When the treatment results in the acutely treated group were compared, the CMS of the cases treated with open reduction and allograft/autograft had significantly higher scores when compared with those to which anatomical reconstruction with a plate or K-wire was applied (p = 0.018). On the other hand, no significant difference was found between the cases in which closed reduction was applied in the acutely treated group and the cases anatomically reconstructed with a plate or K-wire (p = 0.26). PFDS cases to which only open reduction (without fixation) was applied in the acute

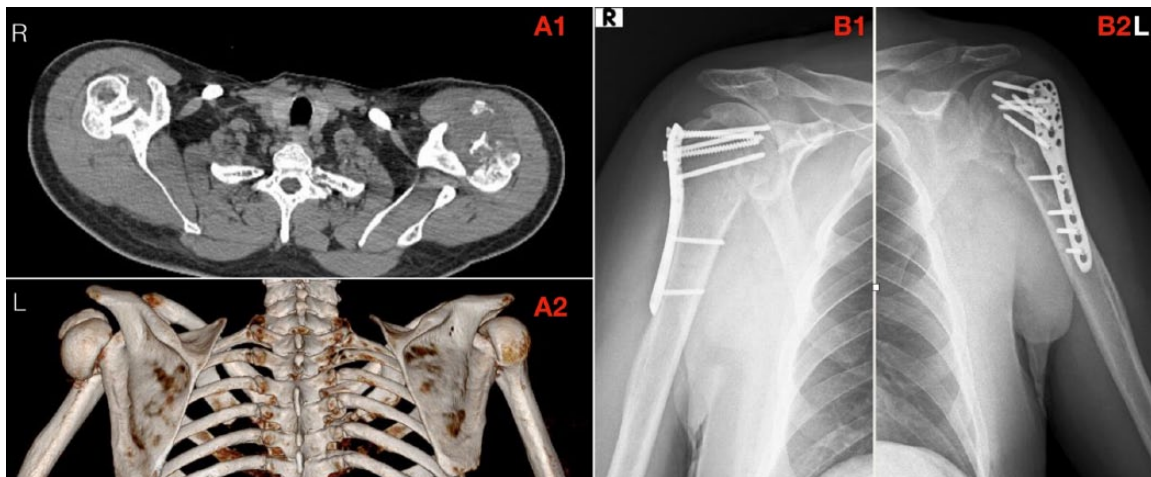


Fig. 1 Pre-operative axial and three-dimensional tomography scans (A1, A2) and post-operative radiographs of the both shoulders at 24 months (B1, B2 / R, right; L, left) of a 37-year-old male who sustained an LPDS during a seizure and was treated at the fifth week after injury.

LPDS group are summarized in Table 3. The results of this treatment, especially in dislocations with two- and three-part fractures, were reported to be excellent and satisfactory, but precise comparison could not be made since they had no CMS (Table 3).

There are common treatment methods recommended in both acute and chronic LPDS cases. These are the McLaughlin procedure, filling of the Hill-Sachs defect with allograft/autograft, balloon expansion + polymethyl methacrylate injection, closed reduction and arthroplasties. Of these treatment methods, only the McLaughlin procedure yields better results in acute cases ($p = 0.023$). Other treatment methods yield similar results in acute and chronic LPDS cases. Thirty-five acute LPDS cases treated with anatomical reconstruction fixed with a plate or K-wire were compared with 25 chronic LPDS cases treated with a spherical-shaped allograft obtained from the femoral head. No statistically significant difference was found between these two treatment groups ($p = 0.869$) (Table 5).

In chronic LPDS cases, no significant difference was observed between the results of the treatment performed using a graft and without using a graft in addition to the modified McLaughlin procedure ($p = 0.460$). Re-dislocation was observed in two cases of both groups. While avascular necrosis (AVN) is observed more frequently in acute cases despite being dependent on the treatment options, allograft flattening and arthritis were observed more in chronic cases.

Discussion

It is generally difficult to diagnose LPDS and it is frequently missed in the initial evaluation. Although the misdiagnosis rates were reported to be in the range of 60% to 80%, it

was found to be 51% in our study.⁶² Shoulder dislocations can be divided into two: locked shoulder dislocations and unstable shoulders.⁶⁴ Significant symptoms may occur such as swelling, pain and limitation of movement in the shoulder after injury. The most frequent reason for misdiagnosis is that anteroposterior (AP) radiographs are usually normal. Focusing on the seizure and not asking for the AP radiograph in PFDS cases with no direct trauma can cause misdiagnosis.

Seizures, falling/indirect trauma, traffic accidents, electric shocks and sports injuries, respectively, are the causes.^{62,64,65} Although seizure cases usually develop in an epileptic background, these seizures can rarely be seen in hypoglycaemic coma, vitamin D deficiency, aortic dissection, brain tumour and idiopathically.^{33,35,60,66,67} Higher rates of seizure-related chronic LPDS (66.7%) can be explained by the under-diagnosis of these cases. LPDS cases are a subset of posterior shoulder dislocations and they include cases with PFDS and isolated reverse Hill-Sachs defect. Although such a differentiation is not made in the literature, a major part (75.8%) of acute cases was made up of PFDS cases in our study. LPDS cases with PFDS and isolated RHL require different treatment procedures. No clear treatment algorithm has been suggested in PFDS cases when choosing the treatment according to the size of the defect in isolated RHL cases.

Closed reduction (with or without pin fixation), open reduction, open reduction and internal fixation (ORIF), ORIF + bone grafting and hemiarthroplasty are the preferred methods in the treatment of acute PFDS.^{5,11,40,41,54} Total shoulder prosthesis, McLaughlin procedure, spherical-shaped allograft fixation, glenoid augmentation and ORIF are certainly the preferred treatment methods in chronic PFDS;^{7,10,14-16} however, objective data for each

Table 5. Shoulders with acute or delayed diagnosis and authors' treatment procedures

Author	Shoulder (N)	Treatment option	Diagnosis
Kokkalis et al ¹⁴	6	Modified McLaughlin technique + allograft	Delayed
Martinez et al ¹⁵	6	Spherical-shaped femoral head allograft fixation	Delayed
Aksekili et al ¹⁰	7	Glenoid augmentation with autograft	Delayed
Diklic et al ²	13	Spherical-shaped femoral head allograft fixation	Delayed
Keppler et al ¹⁷	9	Rotational osteotomy	Delayed
Shams et al ⁷	11	Modified McLaughlin technique + grafting	Delayed
Cheng et al ¹⁶	7	Total shoulder arthroplasty	Delayed
Abdel-Hameed et al ⁹	3	Modified McLaughlin technique + grafting	Delayed
Gavriliadis et al ¹⁸	3	Shoulder arthroplasty	Delayed
Gerber and Lambert ¹⁹	4	Spherical-shaped femoral head allograft fixation	Delayed
Elmali et al ²⁰	2	Spherical-shaped femoral head allograft fixation	Delayed
Benhamida et al ²¹	2	Modified McLaughlin technique + grafting	Delayed
Amir et al ²²	2	McLaughlin technique	Delayed
Jacquot et al ¹³	2	Balloon expansion and PMMA injection	Delayed
Rodia et al ²³	1	Allograft fixation	Delayed
Ivkovic et al ²⁴	2	Autograft fixation/Hemiarthroplasty	Delayed
Bock et al ⁵	1	Allograft/Autograft fixation	Delayed
Verma et al ²⁵	1	Closed reduction	Delayed
Bekmezci and Altan ²⁶	1	Modified McLaughlin technique + grafting	Delayed
Kumar et al ²⁷	1	Combined procedures*	Delayed
Chalidis et al ²⁸	1	Modified McLaughlin technique + grafting	Delayed
Takase et al ²⁹	1	Hemiarthroplasty	Delayed
Karachalios et al ³⁰	1	Open reduction and posterior capsular reconstruction	Delayed
Tellisi et al ³¹	2	ORIF/CR	Delayed
Dervin et al ³²	1	Modified McLaughlin technique + grafting	Delayed
Aparicio et al ³³	2	Modified McLaughlin technique + grafting	Delayed
Poyanli et al ³⁴	2	Hemiarthroplasty/Modified McLaughlin technique	Delayed
Torrens et al ³⁵	2	Allograft/Autograft fixation/Hemiarthroplasty	Delayed
Kılıçoğlu et al ³⁶	2	Hemiarthroplasty	Delayed
Popelka ³⁷	1	Total shoulder arthroplasty	Delayed
Delcogliano et al ³⁸	4	Modified McLaughlin/McLaughlin technique	Delayed
Begin et al ³⁹	2	Allograft/Autograft fixation	Acute
Khayal et al ⁴⁰	1	Allograft/Autograft fixation	Acute
Altan et al ⁶	1	Allograft/Autograft fixation (mosaicplasty)	Acute
Duralde and Fogle ⁴¹	4	Closed reduction	Acute
Bock et al ⁵	5	Allograft/Autograft fixation	Acute
Cooke and Hackney ⁴²	2	Hemiarthroplasty	Acute
Fukuda et al ⁴³	1	Anatomic reconstruction with plate or K-wire fixation	Acute
Claro et al ⁴⁴	4	Anatomic reconstruction with plate or K-wire fixation Hemiarthroplasty Closed reduction and pin fixation	Acute
Miller and Lynch ⁴⁵	3	Modified McLaughlin technique + grafting	Acute
Iosifidis et al ⁴⁶	2	Closed reduction	Acute
Assom et al ⁴⁷	2	OR and bioabsorbable screw fixation	Acute
De Wall et al ⁴⁸	3	Closed reduction and pin fixation	Acute
Ide et al ⁴⁹	1	Anatomic reconstruction with plate or K-wire fixation	Acute
Hayes et al ⁵⁰	1	Anatomic reconstruction with plate or K-wire fixation	Acute
Altay et al ⁵¹	10	Anatomic reconstruction with plate or K-wire fixation	Acute
Soliman and Koptan ¹²	21	Anatomic reconstruction with plate or K-wire fixation	Acute
Fiorentino et al ⁵²	5	Anatomic reconstruction with plate or K-wire fixation Combined procedures*	Acute
Robinson et al ³	28	Anatomic reconstruction with plate or K-wire fixation	Acute
Martens and Hessels ⁵³	2	Anatomic reconstruction with plate or K-wire fixation Hemiarthroplasty	Acute
Finkelstein et al ⁵⁴	2	Modified McLaughlin technique	Acute
Ogawa et al ⁵⁵	10	OR/CR	Acute
Page et al ⁵⁶	2	Hemiarthroplasty	Acute
Oakes and McAllister ⁵⁷	1	Anatomic reconstruction with plate or K-wire fixation	Acute
Jacquot et al ¹³	1	Balloon expansion and PMMA injection	Acute
Ketenci et al ⁵⁸	2	CR	Acute
Aparicio et al ³³	4	CR	Acute
Ito et al ⁵⁹	1	Hemiarthroplasty	Acute
Toker et al ⁶⁰	1	Allograft/Autograft fixation	Acute
Riggenbach et al ⁶¹	1	Hemiarthroplasty	Acute
Mastrokalos et al ⁶²	1	Spherical-shaped femoral head allograft fixation	Acute

*combined procedures: open reduction and stabilization with modified McLaughlin procedure
OR, open reduction; CR, closed reduction; PMMA, polymethyl methacrylate; K, Kirschner

Table 6. Distribution of complications according to the groups

	Acute LPDS	Chronic LPDS
Avascular necrosis	6	2
Allograft collapse	1	3
Allograft flattening	1	10
Redislocation	2	2
Nonunion	1	-
Arthrosis/stiffness	-	7
Total	11/124 (8.87%)	24/104 (23.07%)

method are not yet ensured since there are no large case series for each treatment method.

In this review, no difference was found between acute and chronic cases in which the RHL was filled with allograft or autograft independently of the percentage of the defect. The spherical femoral head allograft (SSFHA)-treated shoulders were also compared with allograft/autograft fixed group. The difficulties in supplying and the cost of frozen femoral head allografts are also a disadvantage. This analysis showed that there was no significant difference between those treated using the femoral head allograft and standard allo/autograft ($p = 0.413$). When acute and chronic cases treated with the McLaughlin procedure were compared, it was observed that the CM scores of acute LPDS cases were better ($p = 0.023$). According to this result, the success of the McLaughlin procedure decreases as TFIS increases. No difference was observed between acute and chronic groups in the case series treated using arthroplasty and allograft/autograft (Table 4).

The SSFHA was used in two different neglected LPDS case series by Diklic et al and Gerber and Lambert.^{2,18} Although the average CM scores of this method applied in cases with a defect in the range of 20% to 60% in reported studies are satisfactory, the complication rates are high. The SSFHA procedure may not be a good option considering its cost and complication rates.

There was no significant difference between chronic LPDS cases that are treated with rotational osteotomy or arthroplasty among the different treatment options ($p = 0.134$). Nine LPDS cases reported by Keppler et al were treated with rotational osteotomy.¹⁷ The average Rowe score of nine cases in total was found to be 71.67 ± 18.87 . Although the average HSL (Hill-Sachs Lesion) is less when compared to other chronic LPDS treatment groups, rotational osteotomy results were found to be lower. It was considered that this treatment method is not a good treatment option for chronic LPDS cases, but it can be an alternative to hemiarthroplasty cases.

The acutely treated LPDS group was made up of PFDS cases at a rate of 75.8%. Cases treated with anatomical reconstruction and internal fixation in this group were three- and four-part fracture-dislocations. Cases treated with closed reduction (with/without pin fixation) mainly consisted of two- and three-part fracture-dislocations. No

statistically significant difference was found between the treatment results of these two groups ($p = 0.260$). On the other hand, excellent and satisfactory results were obtained in the group including acute PFDS cases to which only open reduction was applied. The results of this group could not be compared with other groups since they were not scored over 100. Consequently, six humeral head AVNs that developed in acute LPDS cases were observed in the groups to which only open reduction was applied. The fact that AVN complication is observed more in cases to which open reduction is applied may be due to its containing three- and four-piece fractured dislocation cases and surgeon-related factors. Liu et al reported on a series of 18 patients with malunited chronic PFDS who were treated with anatomical reconstruction.⁶⁹ They reconstructed two-part (lesser tubercle) malunited fracture dislocations, and after a mean follow-up of 38.1 ± 16.5 , the mean CMS was 83.9 ± 8.3 . In our study, no sufficient data were found on the treatment of malunited PFDS cases with anatomical reconstruction and internal fixation in the chronic LPDS group. However, it was reported that performing osteotomy, anatomical reconstruction and fixation suitable for the fracture line in malunited PFDS cases would not constitute risk of AVN (Table 6).⁶⁸

The biggest challenge encountered in the planning of this review is that the treatment methods and assessment methods applied differ significantly. Forty-four different outcome scores in total, 22 of which were clinician-based and 21 of which were patient-based, were defined in the literature.⁶⁹ The scoring methods in which scoring is performed over 100 were found to be CMS, ASES (American Shoulder and Elbow Surgeons), Rowe, Neer and Japanese Orthopaedic Association scores.^{1,15,50,70} The most widely used study results scored over 100 were included in this study.

When the treatment results of chronic LPDS cases are examined in detail, successful results are obtained in the cases operated in the first 16 weeks, while a decrease occurs in the CM scores of the cases treated after 16 weeks. In late diagnosed cases, it was reported that the shoulder can be anatomically reconstructed up to six months.^{5,8} In this study, we found the treatment results after four months to be 67.83 ± 18.72 .

The modified McLaughlin technique is a frequently used technique for cases with an HSL in the range of 25% to 50%.^{7,9,13,34} The defect is filled by the osteotomized lesser tubercle with this technique. A graft can be added to the modified McLaughlin procedure according to the size of the defect.¹³ In the series of cases reported by Castagna et al, 16 cases with a defect in the range of 20% to 50% (41.9 years on average) were treated with the modified McLaughlin technique.⁸ The average times of delay of these cases were reported to be 5.7 months and the average CMS were reported to be 75.2. The results of this case

series in which no complication is observed are lower when compared with our review data. In this technique, it is seen that joint ranges of motion theoretically decrease. The modified McLaughlin procedure may yield less successful results in PFDS cases. On the other hand, shoulder instability may develop in active individuals as a result of the changes in the tendon length in the long term, just as in the Magnuson-Stack procedure.⁷¹

Post-treatment complication rates were found to be 8.87% in acute LPDS cases and 23.07% in chronic LPDS cases. The most frequent complications of shoulder fracture-dislocations are AVN, secondary osteoarthritis and shoulder stiffness.⁷²

Conclusions

LPDS has a complex injury pattern which includes PFDS, RHL and isolated PDSS. The number of bony fragments, time lapsed from injury to surgery, age, chosen treatment and the experience of the surgeon all affect the results. The strategy in delayed case series of reconstructing the shoulder joint in an anatomical way within a diagnostic delay period of up to 16 weeks instead of opting for a shoulder arthroplasty seems to be a promising one, knowing the outcome of shoulder arthroplasty. Reconstruction should be attempted to retain the humeral head and restore its shape primarily in delayed PFDS cases if potential signs of AVN are absent. Also, the surgeon should keep in mind that arthroplasty treatment as a salvage procedure has many pros and cons and should be selected very carefully.

AUTHOR INFORMATION

¹Agri State Hospital, Turkey.

²Erzurum Training and Research Hospital, Turkey.

³Kahta State Hospital, Turkey.

Correspondence should be sent to: Ozgur Basal, Ministry of Health, Agri State Hospital, Orthopaedics and Traumatology, Agri, Turkey.

Email: basalozgur@gmail.com

ICMJE CONFLICT OF INTEREST STATEMENT

None declared.

FUNDING

No benefits in any form have been received or will be received from a commercial party related directly or indirectly to the subject of this article.

LICENCE

© 2018 The author(s)

This article is distributed under the terms of the Creative Commons Attribution-Non Commercial 4.0 International (CC BY-NC 4.0) licence (<https://creativecommons.org/licenses/by-nc/4.0/>) which permits non-commercial use, reproduction and

distribution of the work without further permission provided the original work is attributed.

REFERENCES

- Schliemann B, Muder D, Gessmann J, Schildhauer TA, Seybold D.** Locked posterior shoulder dislocation: treatment options and clinical outcomes. *Arch Orthop Trauma Surg* 2011;131:1127-1134.
- Diklic ID, Ganic ZD, Blagojevic ZD, Nho SJ, Romeo AA.** Treatment of locked chronic posterior dislocation of the shoulder by reconstruction of the defect in the humeral head with an allograft. *J Bone Joint Surg [Br]* 2010;92:71-76.
- Robinson CM, Seah M, Akhtar MA.** The epidemiology, risk of recurrence, and functional outcome after an acute traumatic posterior dislocation of the shoulder. *J Bone Joint Surg [Am]* 2011;93:1605-1613.
- Robinson CM, Akhtar A, Mitchell M, Beavis C.** Complex posterior fracture-dislocation of the shoulder. Epidemiology, injury patterns, and results of operative treatment. *J Bone Joint Surg [Am]* 2007;89:1454-1466.
- Bock P, Kluger R, Hintermann B.** Anatomical reconstruction for Reverse Hill-Sachs lesions after posterior locked shoulder dislocation fracture: a case series of six patients. *Arch Orthop Trauma Surg* 2007;127:543-548.
- Altan E, Senaran H, Acar MA, Aydin K, Ozbaydar MU.** Mozaicplasty technique for treatment of reverse Hill-Sachs lesion. *Tech Shoulder Elbow Surg* 2013;14:1-4.
- Shams A, El-Sayed M, Gamal O, ElSawy M, Azzam W.** Modified technique for reconstructing reverse Hill-Sachs lesion in locked chronic posterior shoulder dislocation. *Eur J Orthop Surg Traumatol* 2016;26:843-849.
- Castagna A, Delle Rose G, Borroni M, et al.** Modified McLaughlin procedure in the treatment of neglected posterior dislocation of the shoulder. *Chir Organi Mov* 2009;93(S1):S1-S5.
- Abdel-Hameed SK, Alzalabany A-KAI, Abdel-Aal MA, Soltan A-A.** Reconstruction of humeral head defect in locked posterior dislocation shoulder. A case series of nine patients. *Open Journal of Orthopedics* 2015;5:25-33.
- Aksekili MA, Uğurlu M, Işık Ç, et al.** Posterior bone block of chronic locked posterior shoulder dislocations with glenoid augmentation: a retrospective evaluation of ten shoulders. *Int Orthop* 2016;40:813-820.
- Neer CS II.** Displaced proximal humeral fractures. II. Treatment of three-part and four-part displacement. *J Bone Joint Surg [Am]* 1970;52:1090-1103.
- Soliman OA, Koptan WM.** Four-part fracture dislocations of the proximal humerus in young adults: results of fixation. *Injury* 2013;44:442-447.
- Jacquot F, Costil V, Werther JR, et al.** Balloon treatment of posterior shoulder dislocation with reverse Hill-Sachs injury: description of a new technique. *Int Orthop* 2013;37:1291-1295.
- Kokkalis ZT, Mavrogenis AF, Ballas EG, Papanastasiou J, Pappagelopoulou PJ.** Modified McLaughlin technique for neglected locked posterior dislocation of the shoulder. *Orthopedics* 2013;36:e912-e916.
- Martinez AA, Navarro E, Iglesias D, et al.** Long-term follow-up of allograft reconstruction of segmental defects of the humeral head associated with posterior dislocation of the shoulder. *Injury* 2013;44:488-491.
- Cheng SL, Mackay MB, Richards RR.** Treatment of locked posterior fracture-dislocations of the shoulder by total shoulder arthroplasty. *J Shoulder Elbow Surg* 1997;6:11-17.

- 17. Keppler P, Holz U, Thielemann FW, Meinig R.** Locked posterior dislocation of the shoulder: treatment using rotational osteotomy of the humerus. *J Orthop Trauma* 1994;8:286-292.
- 18. Gavriilidis I, Magosch P, Lichtenberg S, Habermeyer P, Kircher J.** Chronic locked posterior shoulder dislocation with severe head involvement. *Int Orthop* 2010;34:79-84.
- 19. Gerber C, Lambert SM.** Allograft reconstruction of segmental defects of the humeral head for the treatment of chronic locked posterior dislocation of the shoulder. *J Bone Joint Surg [Am]* 1996;78:376-382.
- 20. Elmalı N, Taşdemir Z, Sağlam F, Gülabi D, Baysal Ö.** One-stage surgical treatment of neglected simultaneous bilateral locked posterior dislocation of shoulder: a case report and literature review. *Eklemler Hastalıkları Cerrahisi* 2015;26:175-180.
- 21. Benhamida MK, Ouertatani M, Hasayri I, et al.** Locked posterior dislocation of the shoulder: A report of three cases. *Chir Main* 2015;34:98-101.
- 22. Amir MA, Alenazi B, Wyse RK, et al.** Neglected bilateral posterior shoulder fracture dislocation in an uncontrolled seizure patient. *Pak J Med Sci* 2015;31:1018-1020.
- 23. Rodia F, Ventura A, Touloupakis G, Theodorakis E, Ceretti M.** Missed posterior shoulder dislocation and McLaughlin lesion after an electrocution accident. *Chin J Traumatol* 2012;15:376-378.
- 24. Ivkovic A, Boric I, Cicak N.** One-stage operation for locked bilateral posterior dislocation of the shoulder. *J Bone Joint Surg [Br]* 2007;89:825-828.
- 25. Verma NN, Sellards RA, Romeo AA.** Arthroscopic reduction and repair of a locked posterior shoulder dislocation. *Arthroscopy* 2006;22:e1251-1255.
- 26. Bekmezci T, Altan E.** Management and prognostic factors for delayed reconstruction of neglected posterior shoulder fracture-dislocation. *Arch Trauma Res* 2015;4:e29903.
- 27. Kumar S, Chopra RK, Kashyap A, Arora S.** Missed posterior shoulder dislocation with malunited proximal humerus fracture. *Chin J Traumatol* 2013;16:375-378.
- 28. Chalidis BE, Papadopoulos PP, Dimitriou CG.** Reconstruction of a missed posterior locked shoulder fracture-dislocation with bone graft and lesser tuberosity transfer: a case report. *J Med Case Reports* 2008;2:260.
- 29. Takase K, Watanabe A, Yamamoto K.** Chronic posterior dislocation of the glenohumeral joint complicated by a fractured proximal humerus: a case report. *J Orthop Surg (Hong Kong)* 2006;14:204-207.
- 30. Karachalios T, Bargiotas K, Papachristos A, Malizos KN.** Reconstruction of a neglected posterior dislocation of the shoulder through a limited posterior deltoid-splitting approach. A case report. *J Bone Joint Surg Am* 2005;87:630-634.
- 31. Tellisi NK, Abusitta GR, Fernandes RJ.** Bilateral posterior fracture dislocation of the shoulders following seizure. *Saudi Med J* 2004;25:1727-1729.
- 32. Dervin GF, Brunet JA, Healey DC.** A modification of the McLaughlin procedure as salvage for missed locked posterior fracture-dislocation of the humeral head: a case report. *J Bone Joint Surg Am* 2002;84-A:804-807.
- 33. Aparicio G, Calvo E, Bonilla L, Espejo L, Box R.** Neglected traumatic posterior dislocations of the shoulder: controversies on indications for treatment and new CT scan findings. *J Orthop Sci* 2000;5:37-42.
- 34. Poyanli O, Gokcen B, Unay K, Akan K, Esenkaya I.** Bilateral posterior shoulder dislocation with defect secondary to hypoglycemic coma. *J Orthop Sci* 2011;16:125-128.
- 35. Torrens C, Santana F, Melendo E, Marlet V, Caceres E.** Osteochondral autograft and hemiarthroplasty for bilateral locked posterior dislocation of the shoulder. *Am J Orthop (Belle Mead NJ)* 2012;41:362-364.
- 36. Kilicoglu O, Demirhan M, Yavuzer Y, Alturfan A.** Bilateral posterior fracture-dislocation of the shoulder revealing unsuspected brain tumor: case presentation. *J Shoulder Elbow Surg* 2001;10:95-96.
- 37. Popelka V.** [Chronic locked posterior shoulder dislocation treated by anatomical total shoulder arthroplasty]. *Acta Chir Orthop Traumatol Cech* 2016;83:55-61.
- 38. Delcogliano A, Caporaso A, Chiossi S, et al.** Surgical management of chronic, unreduced posterior dislocation of the shoulder. *Knee Surg Sports Traumatol Arthrosc* 2005;13:151-155.
- 39. Begin M, Gagey O, Soubeyrand M.** Acute bilateral posterior dislocation of the shoulder: one-stage reconstruction of both humeral heads with cancellous autograft and cartilage preservation. *Chir Main* 2012;31:34-37.
- 40. Khayal T, Wild M, Windolf J.** Reconstruction of the articular surface of the humeral head after locked posterior shoulder dislocation: a case report. *Arch Orthop Trauma Surg* 2009;129:515-519.
- 41. Duralde XA, Fogle EF.** The success of closed reduction in acute locked posterior fracture-dislocations of the shoulder. *J Shoulder Elbow Surg* 2006;15:701-706.
- 42. Cooke SJ, Hackney RG.** Bilateral posterior four-part fracture-dislocations of the shoulders following electric shock: A case report and literature review. *Inj Extra* 2005;36:90-95.
- 43. Fukuda A, Nishimura A, Kato K, Sudo A.** Arthroscopically assisted minimally invasive plate osteosynthesis for posterior fracture-dislocation of the shoulder. *J Orthop Sci* 2014;19:194-197.
- 44. Claro R, Sousa R, Massada M, Ramos J, Lourenço JM.** Bilateral posterior fracture-dislocation of the shoulder: report of two cases. *Int J Shoulder Surg* 2009;3:41-45.
- 45. Miller BG, Lynch B.** Excellent long-term results for acute operative management of locked posterior shoulder dislocation. *ANZ J Surg* 2007;77:95.
- 46. Iosifidis MI, Giannoulis I, Traios S, Giantsis G.** Simultaneous bilateral posterior dislocation of the shoulder: diagnostic problems and management. A case report. *Knee Surg Sports Traumatol Arthrosc* 2006;14:766-770.
- 47. Assom M, Castoldi F, Rossi R, Blonna D, Rossi P.** Humeral head impression fracture in acute posterior shoulder dislocation: new surgical technique. *Knee Surg Sports Traumatol Arthrosc* 2006;14:668-672.
- 48. De Wall M, Lervick G, Marsh JL.** Posterior fracture-dislocation of the proximal humerus: treatment by closed reduction and limited fixation: a report of four cases. *J Orthop Trauma* 2005;19:48-51.
- 49. Ide J, Honda K, Takagi K.** Posterior dislocation of the shoulder associated with fracture of the humeral anatomical neck with 11-year follow-up after early open reduction and internal fixation. *Arch Orthop Trauma Surg* 2003;123:118-120.
- 50. Hayes PR, Klepps S, Bishop J, Cleeman E, Flatow EL.** Posterior shoulder dislocation with lesser tuberosity and scapular spine fractures. *J Shoulder Elbow Surg* 2003;12:524-527.
- 51. Altay T, Oztürk H, Us RM, Günel I.** Four-part posterior fracture-dislocations of the shoulder. Treatment by limited open reduction and percutaneous stabilization. *Arch Orthop Trauma Surg* 1999;119:35-38.
- 52. Fiorentino G, Cepparulo R, Lunini E, et al.** Posterior shoulder fracture-dislocation: double approach treatment. Our experience. *Acta Biomed* 2016;87:184-190.
- 53. Martens C, Hessels G.** Bilateral posterior four-part fracture-dislocation of the shoulder. *Acta Orthop Belg* 1995;61:249-254.
- 54. Finkelstein JA, Waddell JP, O'Driscoll SW, Vincent G.** Acute posterior fracture dislocations of the shoulder treated with the Neer modification of the McLaughlin procedure. *J Orthop Trauma* 1995;9:190-193.

- 55. Ogawa K, Yoshida A, Inokuchi W.** Posterior shoulder dislocation associated with fracture of the humeral anatomic neck: treatment guidelines and long-term outcome. *J Trauma* 1999;46:318-323.
- 56. Page AE, Meinhard BP, Schulz E, Toledano B.** Bilateral posterior fracture-dislocation of the shoulders: management by bilateral shoulder hemiarthroplasties. *J Orthop Trauma* 1995;9:526-529.
- 57. Oakes DA, McAllister DR.** An atypical appearance of a posterior dislocation of the shoulder with a fracture of the proximal humerus. *J Shoulder Elbow Surg* 2001;10:182-185.
- 58. Ketenci IE, Duymus TM, Ulusoy A, et al.** Bilateral posterior shoulder dislocation after electrical shock: A case report. *Ann Med Surg (Lond)* 2015;4:417-421.
- 59. Ito H, Takayama A, Shirai Y.** Posterior dislocation of the shoulder with a large fracture segment: a case report. *J Shoulder Elbow Surg* 2000;9:238-241.
- 60. Toker G, Ozan F, Bora OA.** Treatment of reverse Hill-Sachs lesion by autograft reconstruction. *Acta Orthop Traumatol Turc* 2012;46:398-402.
- 61. Riggensbach MD, Najarian RG, Bishop JY.** Recurrent, locked posterior glenohumeral dislocation requiring hemiarthroplasty and posterior bone block with humeral head autograft. *Orthopedics*. 2012;35:e277-e282.
- 62. Mastrokalos DS, Panagopoulos GN, Galanopoulos IP, Papagelopoulos PJ.** Posterior shoulder dislocation with a reverse Hill-Sachs lesion treated with frozen femoral head bone allograft combined with osteochondral autograft transfer. *Knee Surg Sports Traumatol Arthrosc* 2017;25:3285-3288.
- 63. Xu W, Huang L-X, Guo JJ, et al.** Neglected posterior dislocation of the shoulder: A systematic literature review. *J Orthop Translat* 2015;3:89-94.
- 64. Mouzopoulos G.** The "Mouzopoulos" sign: a radiographic sign of posterior shoulder dislocation. *Emerg Radiol* 2010;17:317-320.
- 65. Robinson CM, Aderinto J.** Posterior shoulder dislocations and fracture-dislocations. *J Bone Joint Surg [Am]* 2005;87:639-650.
- 66. Diklić I, Ganić Z, Stevanović V, Crnobaric A, Blagojević Z.** [Treatment of unreduced posterior dislocations of the shoulder]. *Acta Chir Iugosl* 2006;53:63-67.
- 67. O'Neill D, Nair JR, Binyamin KA.** Simultaneous bilateral posterior fracture dislocation of the shoulders in a young man with unexpected severe vitamin D deficiency. *Int J Gen Med* 2012;5:399-402.
- 68. Agarwal M, Khan WS, Trehan R, Syed AA, Giannoudis PV.** Bilateral posterior fracture-dislocation of the shoulder presenting as a dissecting aneurysm of the thoracic aorta: an uncommon presentation of a rare injury. *J Emerg Med* 2008;35:265-268.
- 69. Liu X, Zhu Y, Lu Y, et al.** Locked posterior shoulder dislocation associated with isolated fractures of the lesser tuberosity: a clinical study of 22 cases with a minimum of 2-year follow-up. *J Orthop Trauma* 2015;29:271-275.
- 70. Harvie P, Pollard TCB, Chennagiri RJ, Carr AJ.** The use of outcome scores in surgery of the shoulder. *J Bone Joint Surg [Br]* 2005;87-B:151-154.
- 71. Fukuda A, Nishimura A, Kato K, Sudo A.** Arthroscopically assisted minimally invasive plate osteosynthesis for posterior fracture-dislocation of the shoulder. *J Orthop Sci* 2014;19:194-197.
- 72. Ahmad CS, Wang VM, Sugalski MT, Levine WN, Bigliani LU.** Biomechanics of shoulder capsulorrhaphy procedures. *J Shoulder Elbow Surg* 2005;14(S1):12S-18S.