

Testis sparing surgery for small testicular masses and frozen section assessment

Muhammad Jamal Khan*, Nish Bedi*, Muhammad Naim Che Rahimi, Jas Kalsi

Department of Urology, Frimley Health NHS Foundation Trust, Wexham Park Hospital Slough, Berkshire, United Kingdom

*These authors contributed equally to the work

Citation: Khan MJ, Bedi N, Rahimi MNC, Kalsi J. Testis sparing surgery for small testicular masses and frozen section assessment. Cent European J Urol. 2018; 71: 304-309.

Article history

Submitted: March 25, 2018

Accepted: Aug. 6, 2018

Published online: Aug. 16, 2018

Corresponding author

Muhammad Jamal Khan
Frimley Health NHS
Foundation Trust
Wexham Park Hospital
Slough
Department of Urology
Wexham Street
SL2 4HL Slough, UK
phone: +44 1753 634 844
dmjkhan@yahoo.com

Introduction We present our experience with patients who had suspected testicular masses, managed by a frozen section assessment and testicular sparing surgery.

Material and methods We performed a retrospective review of all patients over the last 5 years, who underwent a frozen section assessment and testicular sparing surgery for small testicular lesions. The frozen section assessment was compared with the final histology.

Results Twelve patients were identified. The mean age of patients was 40 years (22–58 years). The mean lesion size was 9.8 mm (3–18 mm). Presentations varied: a testicular lump was palpable in 7 patients and 3 patients were referred due to infertility with a subsequent ultrasound, which showed incidental testicular lesions. Two patients presented with testicular pain. Tumour marker levels were within the normal limits in all patients.

The frozen section assessment correctly determined 10 out of 12 (83%) lesions, showing 1 (8%) lymphoma, 2 (17%) seminomas, 3 (25%) fibrosis, 3 (25%) low-grade Leydig cell tumours and 1 (8%) adenomatous tumour. The frozen section reported a benign epidermal cyst in 1 case, whilst the final histology showed a pre-pubertal type teratoma, a rare and low risk tumour. One patient (8%) had an indeterminate lesion, which proved to be a benign adenomatous tumour on final histology. All malignant cases were correctly identified.

There was no malignancy in 9 out of 12 (75%) patients therefore they had testicular sparing surgery. Three patients had orchidectomy, two due to a seminoma and one due to an indeterminate lesion. One patient developed a postoperative haematoma requiring antibiotics but there were no other complications.

Conclusions Our findings demonstrate that partial orchidectomy with a frozen section assessment is useful in small testicular masses and testicular sparing surgery can be considered in order to prevent a radical orchidectomy in selected patients.

Key Words: testis-sparing surgery ↔ small testicular masses ↔ frozen section assessment ↔ orchidectomy

INTRODUCTION

Radical orchidectomy is currently considered to be the standard treatment for testicular tumours of malignant or unknown origin [1, 2]. Testis sparing surgery (TSS) is not recommended by the European Association of Urology (EAU) guidelines in the presence of a normal contralateral testicle. However, it can be an option in special cases such

as in synchronous bilateral testicular tumours, metachronous contralateral tumours or a tumour in a solitary testicle where the tumour volume is less than 30% of the testicular volume [1]. The drawback of such an approach is that a high proportion of histologically proven benign testicular tumours have been removed by radical orchidectomy [3, 4]. Similarly, the increased use of high-frequency ultrasonography performed for different reasons, such as male

infertility and scrotal pain, has led to an increase in the incidental findings of small testicular masses that might be benign [5].

Radical orchidectomy performed for small testicular masses can lead to problems, such as a distorted body image, sexual dysfunction and reduced semen parameters. Therefore, frozen section assessment (FSA) and testis sparing surgery (TSS) have been discussed and may be an option to overcome these problems. There are studies suggesting that FSA is accurate and effective in preventing radical surgery [6–9]. The reported specificity and sensitivity of FSA of a testicular tumour has risen up to 100% [6, 10, 11, 12] and this might play a paramount role in the management of small testicular masses. However, the supporting evidence comes from retrospective studies.

The aim of our study is to report our experience in testis sparing surgery done for small testicular masses and the role of frozen section assessment in sparing the unnecessary orchidectomy in selected patients

MATERIAL AND METHODS

We performed a retrospective review of all patients over the past 5 years (2013 to 2017), who underwent a frozen section assessment and testicular sparing surgery for small testicular lesions (<2 cm). The frozen section assessment was compared with the final histology. A total of 12 patients were identified. A pre-operative evaluation of all patients was done, including history and clinical examination; analysis of testicular tumour markers (alpha-fetoprotein, beta human chorionic gonadotrophin and lactate dehydrogenase) and an ultrasound scan of the testes. All patient cases were pre-operatively discussed in a cancer multidisciplinary meeting to make sure that testicular sparing surgery was appropriate. All patients were aware of the fact that they may need a radical orchidectomy if frozen section assessment was positive for cancer or deemed inconclusive or inaccurate.

The standard surgical technique was used (Figure 1, 2 and 3). An inguinal incision was performed and the external oblique aponeurosis opened. The cord was then identified and with minimal handling the cord was freed from the cremasteric fibres and a soft clamp placed across it. The testicle was exteriorised via the inguinal approach. The lesion was identified by palpation and the use of an intra-operative ultrasound. Using a microscope, an incision was made in the tunica albuginea, while avoiding the vessels. The lesion was excised with at least 2 mm of healthy margin and sent for pathological examination. A fur-

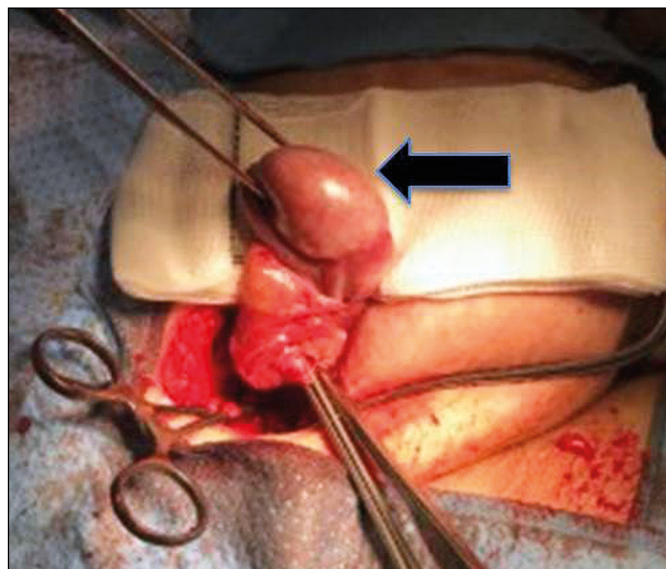


Figure 1. The standard inguinal orchidectomy approach, using soft clamps on the cord and exterioration of the testicle, as shown by the arrow. The lesion is then identified by ultrasound. Incision in the tunica is made between the vessels to remove the lesion.

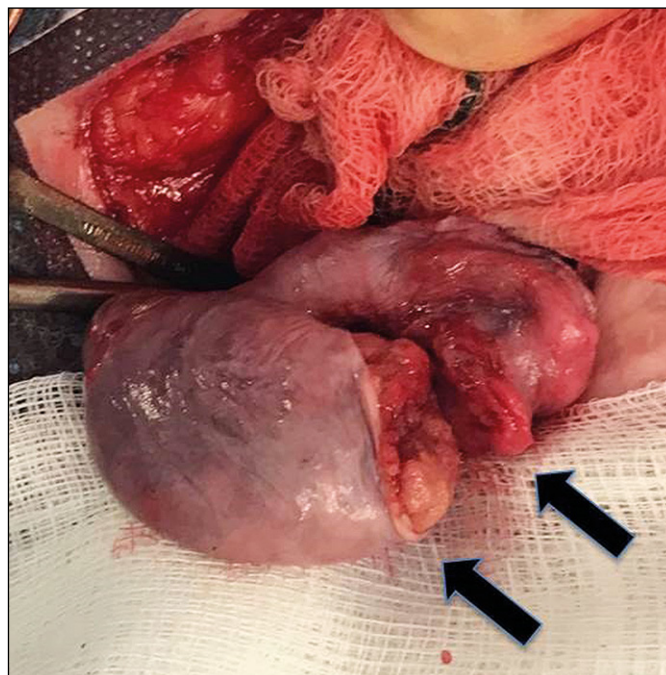


Figure 2. Arrows show the excision of the lesion from the testicle, with a 2 mm margin.

her random sample was sent for a formal histology to exclude an intratubular germ cell neoplasia (ITGCN). An experienced histopathologist immediately performed the frozen section assessment. A radical orchidectomy was performed if there was a strong suspicion of a germ cell tumour or if the

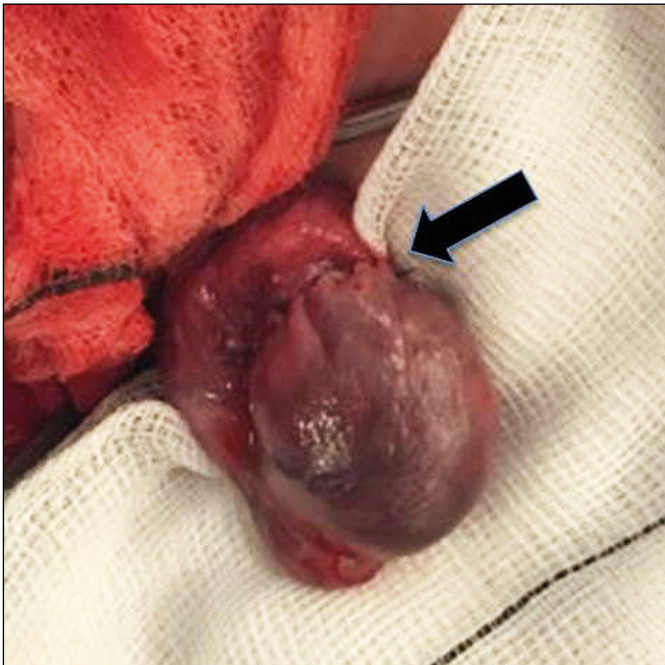


Figure 3. Shows closure of the testis, with an arrow demonstrating the suture line. The testicle is placed back once the lesion is confirmed as benign, by the frozen section assessment.

FSA was inconclusive. An experienced team of histopathologists reported the FSA and final histology. Post operatively patients were followed up in the clinic, reassured and discharged if no cancer was found. This study was registered with the trust audit and research department. Descriptive statistics were used in order to analyse and present the data.

RESULTS

In total 12 patients, who underwent TSS for small testicular masses, were identified. Table 1 displays patients' characteristics, ultrasound scan (USS) findings and testicular tumour markers (TTM). Table 2 shows the FSA, final histology and final outcome. The mean patient age was 40 years (22–58 years). The mean lesion size was 9.8 mm (3–18 mm). Presentations varied: a testicular lump was palpable in 7 patients and 3 patients were referred due to infertility with a subsequent ultrasound revealing incidental testicular lesions. Two patients presented with testicular discomfort or pain. All tumour marker levels were within normal limits in all patients. The mean warm ischemia time was 35 minutes (30–45 minutes). The mean operative time was 112 minutes (100–120 minutes). The frozen section assessment correctly determined 10 out of 12 (83%) lesions, showing 1 (8%) lymphoma, 2 (17%) seminomas, 3 (25%) fibrosis,

3 (25%) low-grade Leydig cell tumours and 1 (8%) adenomatous tumour. The frozen section reported a benign epidermal cyst in 1 case, whilst the final histology showed a pre-pubertal type teratoma, a rare low-risk tumour. One patient (8%) had an indeterminate lesion, which proved to be a benign adenomatous tumour on final histology.

There was no malignancy in 9 out of 12 (75%) patients. They all had TSS thus avoiding the radical orchidectomy. Three out of twelve (25%) patients had orchidectomy; one for an indeterminate lesion on FSA, which proved to be a benign adenomatous tumour on final histology and two for a seminoma. One patient underwent a bilateral orchidectomy (patient's choice) for a lymphoma. Most importantly, all malignant cases (1 lymphoma and 2 seminomas) were correctly diagnosed by FSA. One patient developed a postoperative haematoma requiring antibiotics. There were no other complications.

DISCUSSION

In a systematic review by Giannarini G. et al. [2] it was acknowledged that there have been no randomised controlled trials comparing TSS to radical orchidectomy due to the low incidence of testicular tumours and the long accrual time. Hence the evidence on this subject is limited to retrospective studies and case reports only. On the basis of the available evidence it is recommended that TSS should be considered for: small malignant germ cell tumours (GCTs) with imperative indications for surgery and normal preoperative endocrine function; small Leydig cell tumours even with an elective indication for surgery (normal contralateral testicle) and small non-palpable tumours detected by ultrasound with elective indications, provided that there is no cancer on final histology. Giannarini G. et al. have recommended adjuvant radiotherapy for malignant GCTs. Heidenreich A et al. reported their follow up results of 73 patients from over 7 years, who underwent organ-sparing surgery. They concluded that organ-sparing surgery is a viable therapeutic approach to bilateral testicular germ cell tumours with an excellent post-operative outcome in highly selected patients [13]. A small prospective study of 15 patients who underwent TSS for small testicular masses shows that only 2 patients had a malignant tumour [14]. There was no disease recurrence after a mean follow-up of 19.2 months. They consider TSS a safe option for small testicular masses in selected patients.

There are several studies, which stress that benign testicular tumours are common among small sized lesions. These studies report that 60% to 77% of tu-

Table 1. Characteristics of patients, examination findings, USS findings and TTM

	Age (years)	Presentation	Past urological history	Testes examination	USS findings	Contralateral testis	TTM
1	42	Left testicular mass-asymptomatic	Left orchidopexy at age 10 for undescended testis	Mass in the left testis	8 mm left upper pole lesion	Normal	Normal
2	41	Infertility and azoospermia	None	Normal	7 mm left lower pole lesion	Normal	Normal
3	30	Infertility and azoospermia	None	Normal	11 mm right upper pole lesion	Normal	Normal
4	58	Right epididymal cyst growing in size	Right epididymal cyst	Normal testes	11 mm right testicular lesion	Normal	Normal
5	54	Painful lump in the right testis	Right varicocele embolization	Mass in the right testis	Bilateral lesions max 5 mm	Bilateral lesions	Normal
6	43	Painful lump in the left testis	Left sided infected epididymal cyst	Solid mass in the left testis	15 mm lower pole lesion	Normal	Normal
7	48	Right testicular mass-asymptomatic	No	Mass in the right testis	14 mm right lower pole lesion	Normal	Normal
8	43	Right testicular mass-painful	No	Solid mass in the right testis	18 mm right lower pole lesion	Normal	Normal
9	36	Infertility	Azoospermia. Bilateral atrophic testes	Bilateral small testes	2 lesions in left upper and lower pole of testis; 3mm and 2mm	Bilateral small testes with microcalcifications	Normal
10	33	Discomfort in the right testis	Right sided orchidopexy for UDT	Normal	Microlithiasis and 10 mm lesion	Orchidectomy for atrophic testis	Normal
11	22	Left testicular pain	No	Normal apart from small left testis	4.6 mm lesion left testis	Normal	Normal
12	36	Right testicular mass		Mass in the right testis	10.4 mm lesion	Normal	Normal

USS – ultrasound scan; TTM – testicular tumour markers; UDT – undescended testis

mours smaller than 20 mm were benign, and 80% of lesions under 5 mm were benign. However, the definite diameter cutoff is difficult to define. One study suggests that even larger lesions up to 25 mm in diameter were in up to 69% cases benign. They consider TSS safe and effective in patients with small benign lesions [15].

FSA is gaining an increasingly prominent role during TSS despite the initial concerns due to the potential sampling error and insufficient quality of frozen section preparation [16]. FSA has recently proved to be a highly reliable method for characterization of testicular tumours. Tokuc et al. [16] and Elert et al. [17] found that FSA was able to identify all malignant and benign testicular tumours among 26 and 354 cases, respectively. Similarly, Leroy et al. [6] reported a sensitivity of 81% for benign and 100% for malignant tumours in 15 patients, and Connolly et al. [10] reported a 94.2% positive predictive value and a 92.6% negative predictive value for malignancy in 80 patients. A recent study by Matei D.V. et al. [9], of 144 patients reported sensitivity and specificity of FSA to be 93% and 98%, respectively for malignant tumours, and 90% and 99%, respectively for benign

tumours. They have recommended FSA and TSS for small, non-palpable, multiple or uncommonly presenting masses in a solitary testicle or both testes. Carmignani et al. [5] reported the issue of the incidentally discovered small testicular tumours on ultrasonography. They reported that 80% of their patients had benign histology and suggested that conservative surgery was reasonable in these cases. In our study 75% of patients had benign lesions, which were correctly identified by the FFA. These findings are consistent with previously published reports, which describe the efficacy and safety of TSS for small testicular masses [6, 10, 17]. Furthermore, the mean size of the lesion in our study was 9.8 mm (3–18 mm), which also supports previously published reports, which state that tumours smaller than 20 mm are mostly benign [18, 19, 20].

The use of an operating microscope might not be mandatory for every case of TSS, especially in large, palpable masses. However, careful exploration of the testicular parenchyma and maximal respect for the vascular supply of the testis is better achieved when a microscope is used. The use of this instrument has been reported in the literature to increase the effi-

Table 2. Frozen section assessment, final histology and outcome/follow-up

	FSA	TSS or Orchiectomy	Final histology	Outcome/follow-up
1	Benign epidermal cyst	TSS	Prepubertal type teratoma	3 months post-op: CT C/A/P – normal TTM – normal Testes USS – normal Under surveillance
2	Differentials between lymphoma or less likely spermatocytic seminoma	TSS	High-grade B-cell lymphoma	CT C/A/P: Normal Patient opted for bilateral orchiectomy which was followed by chemotherapy
3	Leydig cell tumour (low-grade)	TSS	Low-grade Leydig cell tumour	USS of testes at 3 months – normal CT scan at 12 months – normal
4	Scar tissue only	TSS	Cystic rete testis only	Post-op haematoma requiring antibiotics USS at 2 months post-op – normal Discharged
5	Hyalinised scar tissue	TSS	Hyalinised scar tissue	Discharged after normal follow-up
6	Indeterminate. Can't rule out cancer	Orchiectomy	Benign adenomatoid tumour	No issues – discharged
7	Adenomatous tumour	TSS	Benign adenomatous tumour	Discharged
8	Low-grade leydig cell tumour	TSS	Low-grade leydig cell tumour	To be followed up for review
9	Low-grade leydig cell tumour	TSS	Low-grade Leydig cell tumour	To be followed up for review
10	Seminoma	Orchiectomy	Seminoma	No metastasis on CT Under surveillance
11	Benign tissue	TSS	Fibrous tissue	Normal follow-up Discharged
12	Seminoma	Orchiectomy	Seminoma	Under surveillance

FSA – frozen section assessment; TSS – testis sparing surgery; CT C/A/P – computer tomography scan chest/abdomen/pelvis; USS – ultrasound scan

cacy of the operation and the possibility of sparing healthy tissue [21].

The limitations of our study are the retrospective nature of the study including a small number of patients and the inability to evaluate the hormonal function of the preserved testes. However our study does suggest that most small testicular lesions are benign. This finding and the reliability of the FSA clearly justify avoiding unnecessary radical orchiectomy and performing TSS instead.

CONCLUSIONS

Our findings suggest that surgical exploration and FSA should be considered in patients with indeterminate small testicular lesions and TSS should be considered to prevent radical orchiectomy in selected patients.

CONFLICTS OF INTEREST

The authors declare no conflicts of interest.

References

- Albers P, Albrecht W, Algaba F, et al. EAU Guidelines on Testicular Cancer. European Association of Urology 2017:13-14. Available from: URL: <https://uroweb.org/guidelines/testicularcancer/>.
- Giannarini G, Dieckmann KP, Albers P, Heidenreich A, Pizzocaro G. Organ-sparing surgery for adult testicular tumours: a systematic review of the literature. *Eur Urol.* 2010; 57: 780-790.
- Haas GP, Shumaker BP, Cerny JC. The high incidence of benign testicular tumors. *J Urol.* 1986; 136: 1219-1220.
- Kressel K, Schnell D, Thon WF, Heymer B, Hartmann M, Altwein JE. Benign testicular tumors: a case for testis preservation? *Eur Urol.* 1988; 15: 200-204.
- Carmignani L, Gadda F, Gazzano G, et al. High incidence of benign testicular neoplasms diagnosed by ultrasound. *J Urol.* 2003; 170: 1783-1786.
- Leroy X, Rigot JM, Aubert S, Ballereau C, Gosselin B. Value of frozen section examination for the management of nonpalpable incidental testicular tumors. *Eur Urol.* 2003; 44: 458-460.
- Passarella M, Usta MF, Bivalacqua TJ, Hellstrom WJ, Davis R. Testicular-sparing surgery: a reasonable option in selected patients with testicular lesions. *BJU Int.* 2003; 91: 337-340.
- Bojanic N, Bumbasirevic U, Bojanic G, Vukovic I, Milojevic B, Pekmezovic T. Testis sparing surgery for treatment of small testicular lesions: Is it feasible even in germ cell tumors? *J Surg Oncol.* 2017; 115: 287-290.
- Matei DV, Vartolomei MD, Renne G, et al. Reliability of Frozen Section Examination

- in a Large Cohort of Testicular Masses: What Did We Learn? *Clin Genitourin Cancer*. 2017; 15: e689-696.
10. Connolly SS, D'Arcy FT, Bredin HC, Callaghan J, Corcoran MO. Value of frozen section analysis with suspected testicular malignancy. *Urology*. 2006; 67: 162-165.
11. Ates F, Malkoc E, Zor M, et al. Testis-Sparing Surgery in Small Testicular Masses Not Suspected to Be Malignant. *Clin Genitourin Cancer*. 2016; 14: e49-53.
12. Silverio PC, Schoofs F, Iselin CE, Tille JC. Fourteen-year experience with the intraoperative frozen section examination of testicular lesion in a tertiary university center. *Ann Diagn Pathol*. 2015; 19: 99-102.
13. Heidenreich A, Weissbach L, Holtl W, et al. Organ sparing surgery for malignant germ cell tumor of the testis. *J Urol*. 2001; 166: 2161-2165.
14. Gentile G, Brunocilla E, Franceschelli A, et al. Can testis- sparing surgery for small testicular masses be considered a valid alternative to radical orchiectomy? A prospective single-center study. *Clin Genitourin Cancer*. 2013; 11: 522-526.
15. Shilo Y, Zisman A, Raz O, et al. Testicular sparing surgery for small masses. *Urol Oncol*. 2012; 30: 188-191.
16. Tokuc R, Sakr W, Pontes JE, Haas GP. Accuracy of frozen section examination of testicular tumors. *Urology*. 1992; 40: 512-516.
17. Elert A, Olbert P, Hegele A, Barth P, Hofmann R, Heidenreich A. Accuracy of frozen section examination of testicular tumors of uncertain origin. *Eur Urol*. 2002; 41: 290-293.
18. Muller T, Gozzi C, Akkad T, Pallwein L, Bartsch G, Steiner H. Management of incidental impalpable intratesticular masses of ≤ 5 mm in diameter. *BJU Int*. 2006; 98: 1001-1004.
19. Horstman WG, Haluszka MM, Burkhard TK. Management of testicular masses incidentally discovered by ultrasound. *J Urol*. 1994; 151: 1263-1265.
20. Comiter CV, Benson CJ, Capelouto CC, et al. Nonpalpable intratesticular masses detected sonographically. *J Urol*. 1995; 154: 1367-1369.
21. De SS, Isgro G, Varca V, et al. Microsurgical testis-sparing surgery in small testicular masses: seven years retrospective management and results. *Urology*. 2012; 79: 858-862. ■