

4-in-1 Quadricepsplasty for Fixed and Habitual Dislocation of Patella



Justin M. Hire, M.D., and Shital N. Parikh, M.D.

Abstract: Fixed and habitual dislocations of patella represent the most severe forms of patellar instability and frequently require surgical intervention. Isolated medial patellofemoral ligament (MPFL) reconstruction, which has been the cornerstone of treatment for episodic patellar dislocation, is inadequate to address such complex instability patterns. The purpose of this report is to describe the 4-in-1 quadricepsplasty technique for stabilization of fixed and habitual dislocation of patella. The 4 components of quadricepsplasty are lateral retinacular releases and lengthening, Roux-Goldthwait patellar tendon hemi-transfer, modified Insall's proximal "tube" realignment, and quadriceps slide-lengthening.

Introduction

Fixed (locked, permanent) and habitual (obligatory) dislocations of patella frequently present in the first decade of life. The child is brought in due to complaints such as knee deformity, genu valgum, frequent falls, giving way episodes, abnormal gait, or decreased function. The parents may not be aware of patellar dislocation. Patellar instability may be associated with syndromes such as Down's syndrome or Nail-Patella syndrome. Although children can learn to compensate, the instability frequently gets worse with growth. At times, patient may present later in life with long-standing or neglected deformities. Bracing, physical therapy, and conservative management can help with some of the symptoms but are not sufficient to address patellar instability. Surgery should not be delayed, as there is a risk of painful arthrosis, and the trochlea has higher potential to remodel after patellar stabilization at a younger age.

Since the etiology of fixed and habitual dislocation of patella is an externally rotated and shortened quadriceps mechanism, isolated MPFL reconstruction cannot address such instability patterns. Quadricepsplasty, defined as reorientation of quadriceps mechanism with or without lengthening, is essential. Several techniques of quadricepsplasty have been reported in the literature.¹⁻⁵ The purpose of this report is to describe our 4-in-1 quadricepsplasty technique to address complex patellar instability patterns, including pearls and pitfalls of the technique (Table 1). The 4 components of quadricepsplasty are lateral retinacular releases and lengthening, Roux-Goldthwait patellar tendon hemi-transfer modified Insall's proximal "tube" realignment, and quadriceps slide-lengthening.²⁻⁷ (Fig 1, Video 1). As part of preoperative planning, genetic referral is performed in patients with syndromic association. Knee radiographs, full-length hip-to-ankle radiographs and magnetic resonance imaging (MRI) of the knee are obtained to evaluate anatomic risk factors for patellar instability.

This study was completed after review and approval by our Institutional Review Board.

Surgical Technique

Patient Positioning

The patient is positioned supine with a bump under the operative hip. General anesthesia with adequate muscle relaxation and a femoral nerve block are performed. A nonsterile tourniquet is placed over the proximal thigh, which can be deflated to assess patellar tracking. Preoperative antibiotics are administered. The

From Cincinnati Children's Hospital, Department of Orthopedics, Cincinnati, Ohio, U.S.A.

Full ICMJE author disclosure forms are available for this article online, as supplementary material.

Received November 5, 2021; accepted December 4, 2021.

Address correspondence to Shital N. Parikh, M.D., Cincinnati Children's Hospital, 3333 Burnet Ave., Department of Orthopedics, Cincinnati, OH 45229-3039, U.S.A. E-mail: Shital.parikh@cchmc.org

© 2022 THE AUTHORS. Published by Elsevier Inc. on behalf of the Arthroscopy Association of North America. This is an open access article under the CC BY-NC-ND license (<http://creativecommons.org/licenses/by-nc-nd/4.0/>).

2212-6287/211570

<https://doi.org/10.1016/j.eats.2021.12.004>

Table 1. Pearls and Pitfalls

Pearls	Pitfalls
<ul style="list-style-type: none"> • Midline knee incision is utilitarian. • All lateral adhesions to the patella should be completely released, including release of vastus lateralis tendon. Tag the released VL tendon. • Keep articular surfaces moist during surgery. • The position of the “inferior stitch” for tube quadricepsplasty is variable and dependent on the amount of quadriceps dysplasia. The correct position of this stitch is found by “trial and error” method. • Medial and distal reattachment of lateral half of patellar tendon would allow for some patellar distalization. • The intact medial half of patellar tendon would keep extensor mechanism intact. • Quadriceps tendon lengthening is not necessary if 90° knee flexion could be achieved with patella positioned over the trochlea. • Postoperative cast would help the patellar tendon to heal at its new attachment site. 	<ul style="list-style-type: none"> • Surgery should not be delayed, as fixed and habitual dislocations of patella are likely to get worse with growth. • The lateral half of patellar tendon should be sharply cut at its insertion to avoid tibial tuberosity growth disturbances. • Overtensioning of tissues or persistent subluxation should be avoided by checking patellofemoral tracking and knee flexion periodically. • The infrapatellar pat pad should be maintained for patellar vascularity after extended medial and lateral arthrotomy. • Prevent patella eversion or “spin out” by placing a suture from the medial aspect of the patella to the overlying medial flap.

tourniquet is inflated. Knee arthroscopy is performed if preoperative MRI shows any intra-articular pathology (Fig 2). The knee is flexed about 45-60° over a triangle for the surgery.

Approach

An anterior midline incision measuring 12-15 cm is performed between the distal femoral medial and lateral condyles and taken distally to just medial to the tibial tubercle. The dislocated patella is not considered during skin incision. Superficial dissection is performed to expose the quadriceps tendon, vastus medialis oblique (VMO), vastus lateralis tendon (VL), medial and lateral retinaculum, iliotibial band (ITB), patellar tendon, and tibial tuberosity (TT) (Fig 3).

Arthrotomy and Lateral Retinacular Release and Lengthening

Wide lateral releases are performed to release all adhesions between the subcutaneous tissues, VL, ITB, and lateral retinaculum. Medial and lateral parapattellar incisions are then marked (Fig 3). A coronal plane Z-lengthening of lateral retinaculum is performed by making an incision through the superficial retinacular layer about 5 mm from lateral border of the patella.⁸ Using sharp dissection, the surgeon develops the plane between the superficial oblique fibers and the deep transverse fibers in a posterior direction for about 2 cm. The posterior cut is then made through the deep transverse fibers of lateral retinaculum. This cut would include the capsule and

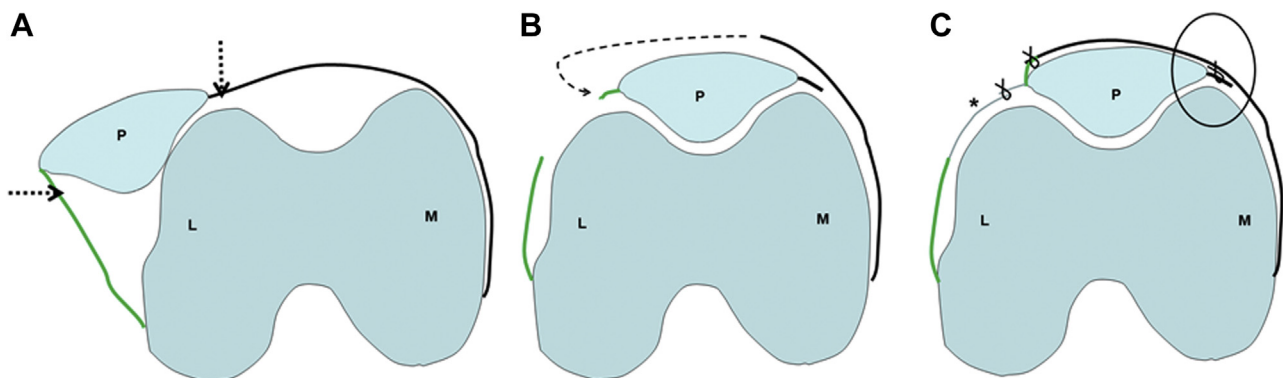


Fig 1. Schematic diagram of the knee showing key steps of the 4-in-1 quadricepsplasty technique. (A) Medial and lateral parapattellar arthrotomy (dashed arrows) is performed, and patella is mobilized after wide lateral releases. (B) The medial aspect of the medial flap containing vastus medialis oblique, and medial retinaculum is brought over the patella (curved, dashed arrow) and sutured to the lateral aspect of patella, thus encasing the patella in a quadriceps tube. (C) A medial patellar suture (circled) and lateral lengthening (*) would help prevent patellar spin-out and eversion. L, lateral femoral condyle; M, medial femoral condyle; P, patella.

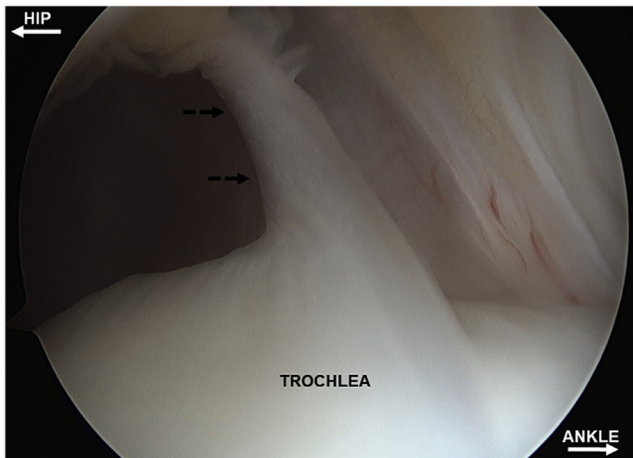


Fig 2. Right knee arthroscopy viewing from the lateral portal in a patient with Nail-patella syndrome. The intra-articular trochlear septum (dashed arrows) divides the knee in medial and lateral half and precludes the patella from entering the trochlea. The septum extends down to the intercondylar notch and is taken down with a shaver, before proceeding with open quadricepsplasty.

synovial layer (Fig 4). The incision is extended proximally for about 5 cm into the rectus femoris tendon, thus separating the VL tendon, which is tagged.

A medial parapatellar arthrotomy is performed from 5 cm proximal to the patella to the TT (Fig 5). At this time, only the quadriceps and patella tendon are attached to the patella with no attachments on the medial or lateral side (Fig 6). The medial flap containing the VMO, and medial retinaculum is mobilized by dissecting them from subcutaneous tissues (Fig 7). The patellofemoral joint is assessed for any chondral lesions, which can be addressed at this time. The cartilage surfaces are kept moist throughout the procedure.

Roux-Goldthwait Procedure

The patella is positioned on the trochlea and held with a tentative suture if required (Fig 8). This would reveal the lateral vector of the patellar tendon, which is frequently underappreciated when the patella is subluxed or dislocated. The paratenon is incised in the midline and reflected. The patellar tendon is split in the center. The lateral half of the patella tendon is sharply detached from its insertion on TT, avoiding the cartilage apophysis. A hemostat is placed underneath the intact medial half of the patellar tendon from medial to lateral, and the detached lateral half is passed medially.

The periosteum is exposed medial and distal to the TT. Using a no. 2 FiberWire (Arthrex, Naples, FL) suture, the surgeon places a locking Krackow stitch in the tendon stump, and the tendon is sutured to the periosteum.⁶ (Fig 9). Care is taken to minimize dissection around the infrapatellar fat pad, which provides blood supply to the patella.

Proximal “Tube” Quadricepsplasty

The medial flap containing the VMO, and medial retinaculum is brought over the quadriceps tendon and patella and sutured to the to the superolateral and inferolateral aspect of the patella using provisional sutures (Fig 10). This would create a quadriceps tube with the patella in between.⁷ Patellofemoral tracking is evaluated through range of motion. The location of the inferior stitch, which marks the lower extent of the tube, may have to be changed depending on knee motion limitations and patellofemoral tracking. If the inferior stitch has too much tension, it would pull the patella into eversion during knee motion or restrict knee flexion. In such instances, the inferior stitch is repositioned more proximally at the mid patella level. If flexion is still limited to less than 90°, deflate the tourniquet and reassess. If not improved, a Cobb elevator is passed along the anterior and lateral femoral cortex to separate the vastus intermedius for

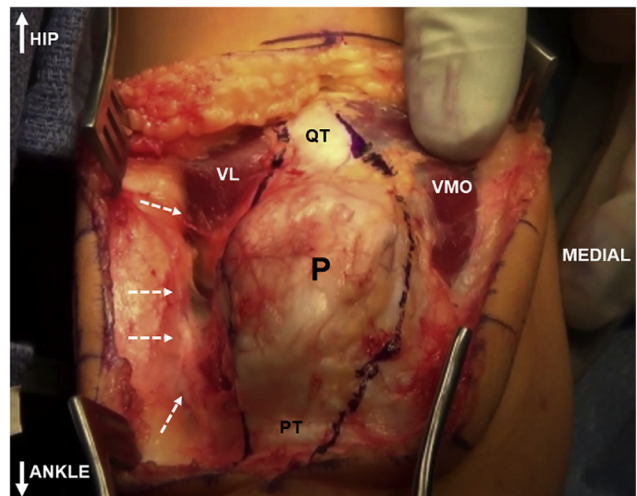


Fig 3. Right knee viewing from the top. The patella (P), vastus medialis (VMO), quadriceps tendon (QT), patellar tendon (PT), and vastus lateralis (VL) are exposed. Wide lateral release is performed by taking down all adhesions on the lateral side (dashed arrows) between VL, lateral retinaculum, iliotibial band, and subcutaneous tissues. The medial and lateral parapatellar arthrotomy incisions are planned.

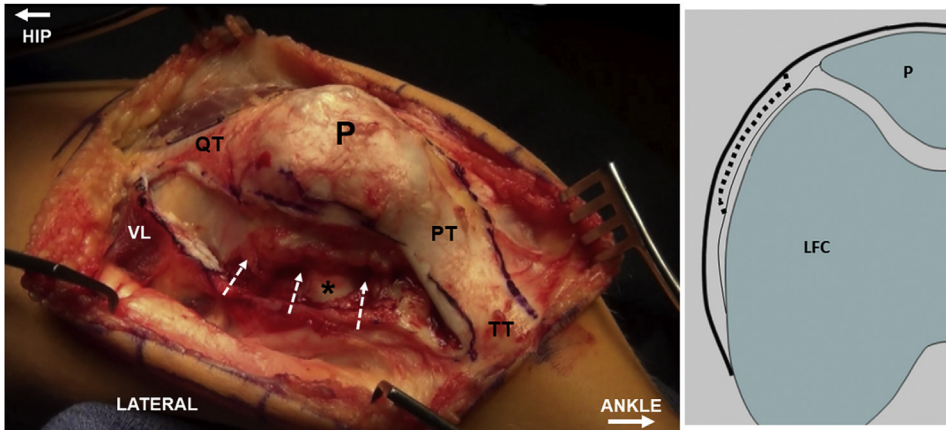


Fig 4. Right knee viewing from the lateral side. Lateral arthrotomy is performed via lateral retinacular lengthening (dashed arrows). The schematic diagram shows the plane of Z-lengthening (dashed line) between superficial oblique and deep transverse lateral retinacular layers. The vastus lateralis tendon (VL) is detached from quadriceps tendon (QT) and tagged. The lateral femoral condyle (LFC) is visualized (*). P, patella; PT, patellar tendon; TT, tibial tuberosity.

about 7 to 10 cm, which will allow increased excursion.

Quadriceps Slide and Lengthening

The quadriceps tendon length is achieved in a stepwise approach. Release of all lateral tethers would increase the quadriceps tendon excursion. Lifting vastus intermedius from anterior femur would further mobilize the quadriceps tendon. The VL tendon is allowed to slide proximally and sutured in a lengthened fashion with knee at 90° flexion, as described later. If the knee cannot be flexed to 90° with the patella relocated, then Z-lengthening of quadriceps tendon is performed. Z-lengthening is

performed by first incising the quadriceps tendon in its midline for about 5 cm from superior aspect of patella. The distal transverse cut is made lateral from midline, and the proximal transverse cut is made medial from midline (Fig 11). The knee is then flexed to about 90°, the two flaps of quadriceps tendon are allowed to slide, and they are sutured using no. 2 FiberWire suture.

Definitive fixation is performed once 90° or greater knee flexion can be achieved with acceptable patellofemoral tracking. The inferior patellar provisional suture from quadriceps tube is removed. The VMO/medial retinacular flap is elevated with Allis tissue-holding forceps. The medial border of the patella is sutured to the undersurface of the medial flap using a

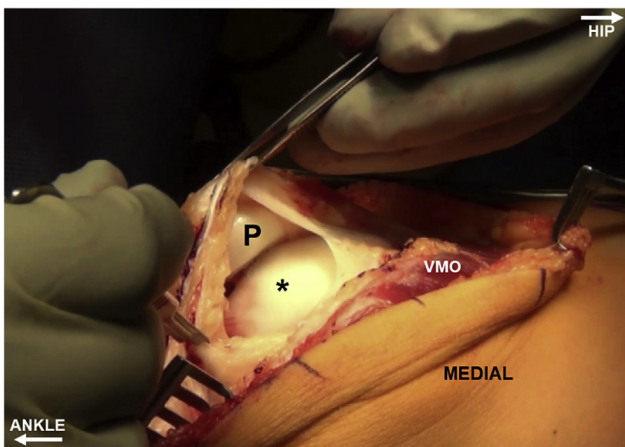


Fig 5. Right knee viewing from the medial side. Medial parapatellar arthrotomy is performed in a standard fashion extending from quadriceps tendon to tibial tuberosity. P, patella; VMO, vastus medialis; The asterisk (*) denotes the medial femoral condyle.

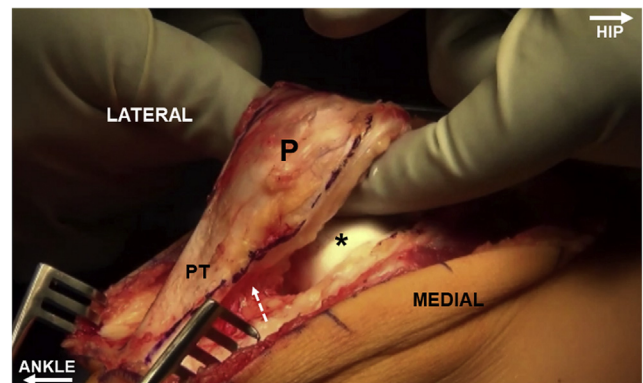


Fig 6. Right knee viewing from the medial side. After performing medial and lateral parapatellar arthrotomy, the patella (P) is mobilized by releasing any intra-articular adhesions. The infrapatellar fat pad (dashed arrow) is preserved. PT, patellar tendon. The asterisk (*) denotes medial femoral condyle.

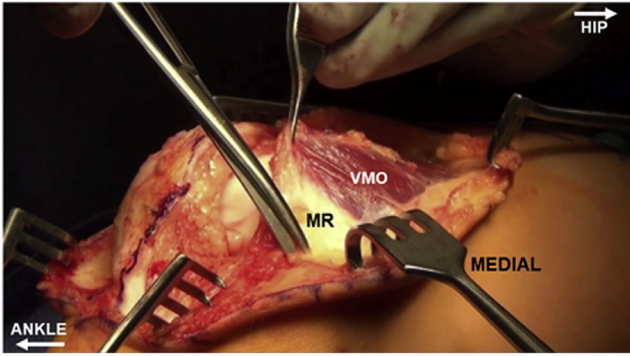


Fig 7. Right knee viewing from the medial side. The medial flap consisting of vastus medialis (VMO), and the medial retinaculum (MR) is mobilized by dissecting it from the subcutaneous tissues.

nonabsorbable suture (Fig 12). This will prevent eversion of the patella. The medial flap is then brought over the patella, and the previously placed inferior suture is replaced with no. 2 FiberWire suture. Knee range of motion and patellar tracking are periodically evaluated to avoid excessive tension on the suture lines during knee flexion. Additional 0 Vicryl (Ethicon, Somerville, NJ) sutures are placed along the entire medial flap to suture it to the lateral aspect of the quadriceps tendon and lateral border of the patella (Fig 13). Distal to the inferior-most patellar stitch, the medial flap will pass obliquely across the patella and it can be secured in this position with additional sutures.

Closure

The patellar tendon insertion is reinforced with additional 0 Vicryl sutures. The VL tendon is sutured to the rectus tendon or to the superolateral aspect of the patella, depending on the resting position of the VL with the knee in flexion, resulting in VL tendon lengthening (Fig 14). The previously performed Z lengthening flaps of the lateral retinaculum are sutured in a lengthened fashion⁸ (Fig 15). This would close some of the lateral defect and resist patellar eversion. The subcutaneous tissue and skin are closed in layers. An above-knee cast is applied with the knee in 15-20° of flexion, primarily to allow the patellar tendon and other soft tissues to heal in its new position.

Rehabilitation Protocol

Toe touch weight bearing with crutches or walker is allowed. The cast is removed at 3 weeks. A knee

immobilizer may be used for 2-3 additional weeks after cast removal. Physical therapy is then started to assist with range of motion, but it is often not required for children younger than 5-7 years of age. Swimming is encouraged. Range of motion, especially knee flexion, continues to improve throughout the first year.

Discussion

Several techniques of quadricepsplasty have been described in the literature.^{1,4-8} The advantages of the current technique are universal midline incision without the need for autograft or allograft tissue, intraoperative fluoroscopy, or any implants (Table 2). No bony procedures are required. MPFL reconstruction has been described along with quadricepsplasty, but it is usually not required.

Potential complications of quadricepsplasty include knee stiffness, extensor lag, and recurrent instability. Knee stiffness can be minimized by ensuring at least 90° of flexion intraoperatively. Postoperatively, physical therapy should be considered in older patients. Patellar eversion (rotation and dislocation about the vertical axis) is prevented by suturing the undersurface of the medial flap to the medial patella and stabilizing laterally with lateral retinacular lengthening. The medial transfer of lateral half of patellar tendon routed underneath the intact medial part of patellar tendon also helps to prevent patellar eversion. The alternatives to hemi-transfer of patellar tendon are complete transposition of patellar tendon

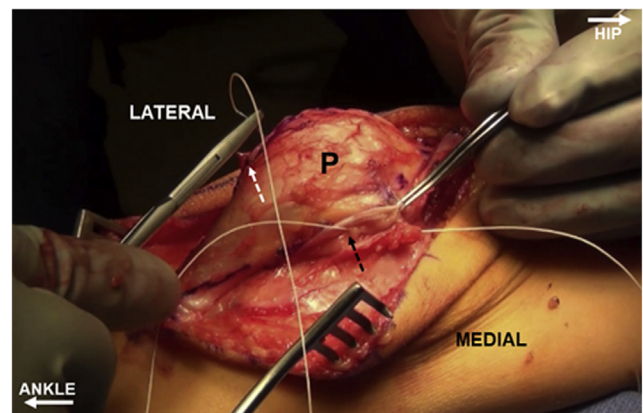


Fig 8. Right knee viewing from the medial side. The patella (P) is positioned on the trochlea, and a stay suture between the medial flap (black dashed arrow) and lateral border of patella (white dashed arrow) is used to tentatively position the patella on the trochlea. The lateralized vector of patellar tendon is observed.

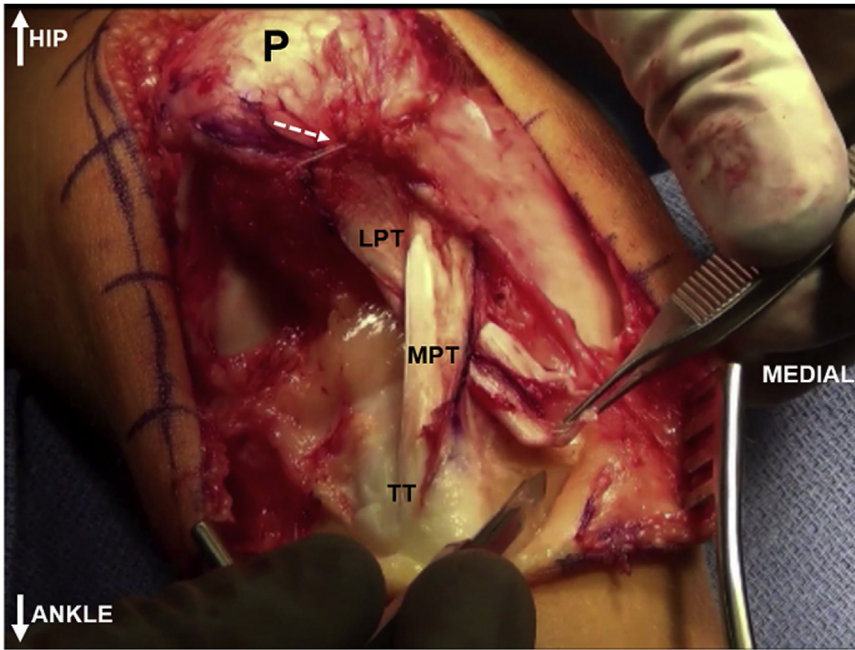


Fig 9. Right knee viewing from the top. Roux-Goldthwait hemi-transfer of patellar tendon is performed by detaching the lateral half of patellar tendon (LPT) from tibial tuberosity (TT), bringing it underneath the intact medial half (MPT) and suturing it to medial periosteum. The suture securing the patella in the trochlea is visualized (white dashed arrow).

or tibial tuberosity osteotomy in skeletally mature patients. The need for lengthening of the quadriceps tendon is assessed as the last part of surgery as there is potential for quadriceps weakness and resultant extensor lag. Long-term outcome studies will assist in informing patients and their family concerning complications and functional results.

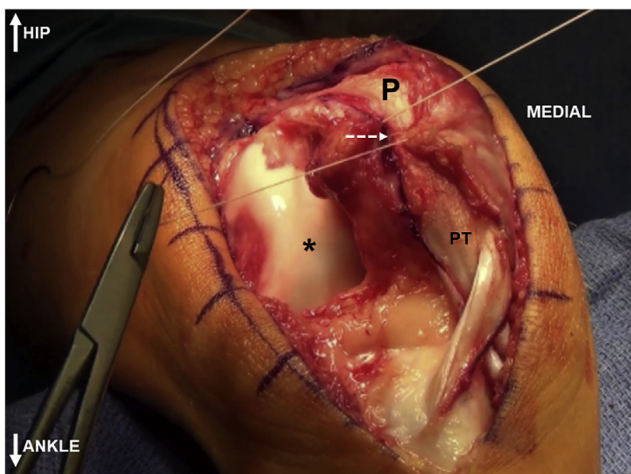


Fig 10. Right knee viewing from the lateral side. After patellar tendon (PT) hemi-transfer, tube quadricepsplasty is performed by bringing the medial flap over the patella (P) and suturing it to the lateral aspect of patella (white dashed arrow). Once the patella is repositioned on the trochlea, the void on the lateral aspect of knee and lateral femoral condyle (*) are seen.

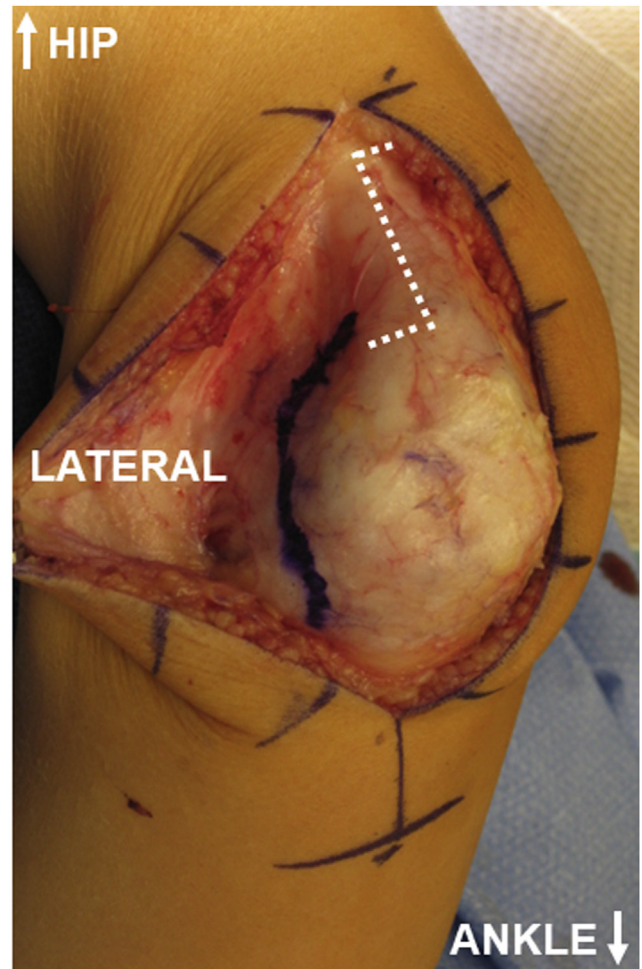


Fig 11. Right knee viewing from the lateral side in another patient. When formal quadriceps tendon lengthening is required, a Z-plasty is performed. The orientation of transverse cuts for Z-lengthening are distal-lateral and proximal-medial.

Fig 12. Right knee viewing from the lateral side in another patient. A medial stich (black dashed arrow) between the medial border of patella (P) and medial flap would avoid patella spin-out after tube quadricepsplasty. Detachment of vastus lateralis tendon (*) from quadriceps tendon (QT) is seen. LR, lateral retinaculum; PT, patellar tendon

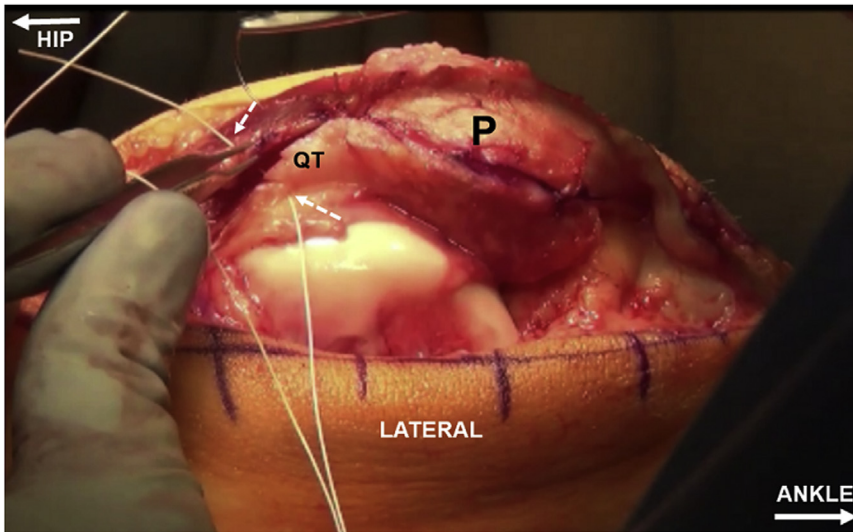
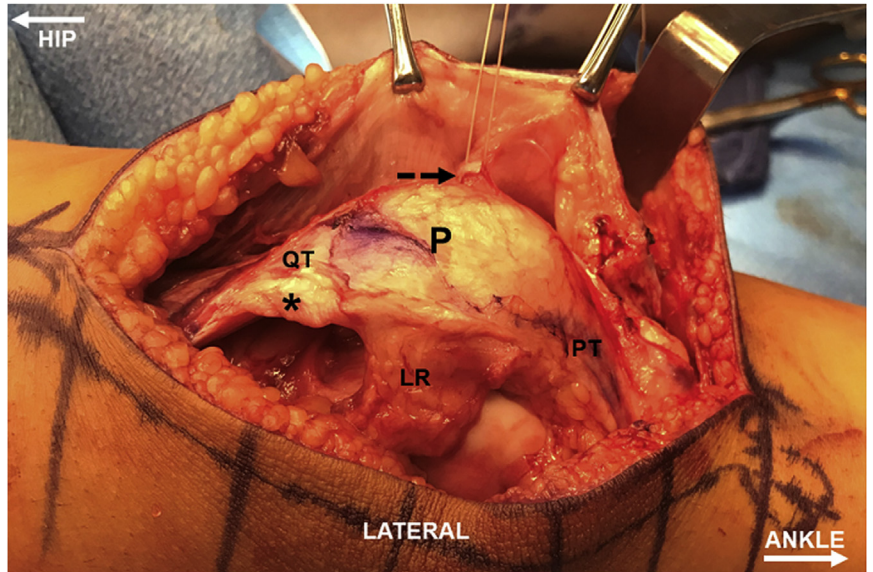
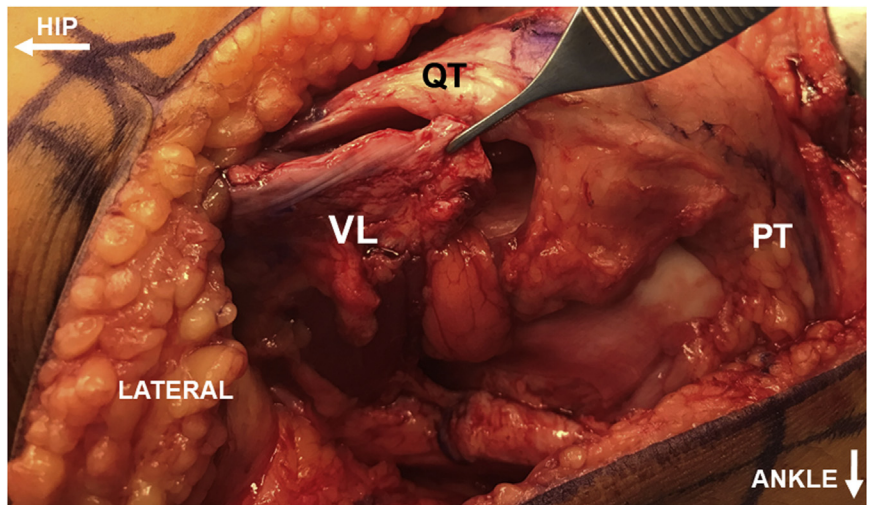


Fig 13. Right knee viewing from the lateral side. The tube quadricepsplasty is extended proximally by suturing (white dashed arrows) medial flap to the lateral border of quadriceps tendon (QT). P, patella.

Fig 14. Right knee viewing from the lateral side in another patient. With the knee flexed to 90°, the quadriceps mechanism would slide distally. In this position, the vastus lateralis tendon (VL) is sutured to the quadriceps tendon (QT), causing effective lengthening of the quadriceps mechanism. PT, patellar tendon



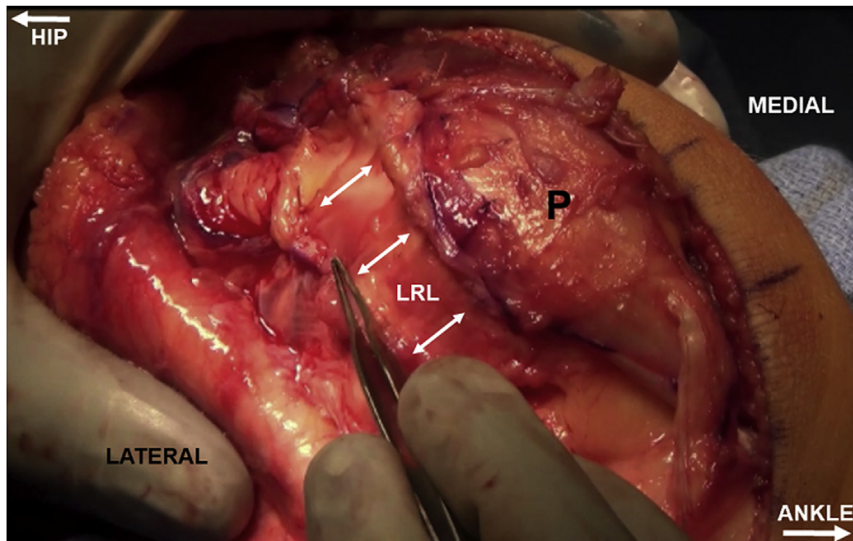


Fig 15. Right knee viewing from the lateral side. Lateral retinacular lengthening (LRL) is performed during closure (white arrows). P, patella.

Table 2. Advantages and Disadvantages

Advantages	Disadvantages
<ul style="list-style-type: none"> • Midline knee incision could be used for future surgical procedures. • Releases around the patella would avoid large muscles releases from the femur. • Step-wise procedures would allow for adjustment of tensioning of tissues and controlled lengthening of structures. • Intact medial half of patellar tendon would maintain extensor mechanism continuity. • Medial and distal reattachment of lateral half of patellar tendon would allow for some patellar distalization. • Does not preclude concomitant or future MPFL reconstruction or guided growth procedures • No need for implants or fluoroscopy • No bony procedures involved, thus minimizing the risks for growth disturbances 	<ul style="list-style-type: none"> • Older the patient and more long-standing the deformity, more challenging is the procedure for patellar relocation due to tissue fibrosis and shortening • All repaired tissues should be reinforced and briefly protected post-operatively to ensure adequate healing. • There is a possibility of avascular necrosis of patella due to wide releases. • A large void may be left on the lateral side, which may lead to scarring or swelling. • An extensor lag may persist as the quadriceps mechanism is lengthened during the procedure. • Femoral nerve block for postoperative pain control can accentuate the extensor lag.

References

1. Benoit B, Laflamme GY, Laflamme GH, Rouleau D, Delisle J, Morin B. Long-term outcome of surgically-treated habitual patellar dislocation in children with coexistent patella alta. Minimum follow-up of 11 years. *J Bone Joint Surg Br* 2007;89:1172-1177.
2. Joo SY, Park KB, Kim BR, Park HW, Kim HW. The 'four-in-one' procedure for habitual dislocation of the patella in children: early results in patients with severe generalised ligamentous laxity and aplasia of the trochlear groove. *J Bone Joint Surg Br* 2007;89:1645-1649.
3. Malagelada F, Rahbek O, Sahirad C, Ramachandran M. Results of operative 4-in-1 patella realignment in children with recurrent patella instability. *J Orthop* 2018;15:13-17.
4. Danino B, Deliberato D, Abousamra O, Singh S, Klingele K. Four-in-one extensor realignment for the treatment of obligatory or fixed, lateral patellar instability in skeletally immature knee. *J Pediatr Orthop* 2020;40:503-508.
5. Sever R, Fishkin M, Hemo Y, Wientroub S, Yaniv M. Surgical treatment of congenital and obligatory dislocation of the patella in children. *J Pediatr Orthop* 2019;39:436-440.
6. Goldthwait JEV. Fixed dislocation of the patella. The report of a case of twenty years' duration, successfully treated by transplantation of the patella tendons with the tubercle of the tibia. *Ann Surg* 1899;29:62-68.
7. Insall J, Bullough PG, Burstein AH. Proximal "tube" realignment of the patella for chondromalacia patellae. *Clin Orthop Relat Res* 1979;144:63-69.
8. Hayden DJ, Doshi C, Parikh SN. Lateral patellar retinaculum Z-lengthening. *Arthrosc Tech* 2021;10:e1883-e1887.