



MitraClip for Severe Mitral Regurgitation from Chordal Rupture during Balloon Aortic Valvuloplasty

CASE REPORT

AKIVA ROSENZVEIG, BA 

SYED ZAID, MD 

JOSHUA HSU, BA

HASAN AHMAD, MD

JOSHUA GOLDBERG, MD 

*Author affiliations can be found in the back matter of this article



ABSTRACT

Transcatheter aortic valve replacement (TAVR) has become an established alternative to surgical aortic valve replacement for high-, intermediate-, and low-risk patients. Paravalvular leak (PVL) is a complication of TAVR that can be effectively treated with balloon dilation and vascular plugs. We report a case of an 86-year-old male presenting with symptomatic severe aortic stenosis. After the index TAVR procedure, mild-to-moderate PVL was noted. Two years post-operation, the patient presented with symptomatic severe PVL, which was initially treated by balloon dilation with additional volume. During balloon dilation, the balloon slipped into the left ventricle and tore a chord, leading to new severe mitral regurgitation (MR) while the PVL remained unchanged. Subsequently, an Amplatzer vascular plug II (Abbott) was successfully used to reduce the PVL to mild, and a MitraClip NTR (Abbott) was used to successfully reduce the MR to trivial. Although balloon dilation can be an effective method for reducing PVL, mitral valve chordal rupture is a rare complication if the wire is entrapped in the chordae and the balloon slips into the ventricle.

CORRESPONDING AUTHOR:

Joshua B. Goldberg, MD

Cardiothoracic Surgery,
Westchester Medical Center,
Valhalla, New York, US

Joshua.Goldberg@wmchealth.org

KEYWORDS:

aortic stenosis; chordal rupture;
mitral regurgitation; MitraClip;
paravalvular leak; transcatheter
aortic valve replacement

TO CITE THIS ARTICLE:

Rosenzweig A, Zaid S, Hsu J,
Ahmad H, Goldberg J. MitraClip
for Severe Mitral Regurgitation
from Chordal Rupture during
Balloon Aortic Valvuloplasty.
Methodist DeBakey Cardiovasc J.
2022;18(1):73-77. doi: 10.14797/
mdcvj.1111

INTRODUCTION

Transcatheter aortic valve replacement (TAVR) has become an established alternative to surgical aortic valve replacement for high-, intermediate-, and low-risk patients.¹ One of the vulnerabilities of TAVR compared to surgical aortic valve replacement (SAVR) has been paravalvular leak (PVL). Although the incidence of PVL has declined due to improved valve designs, it remains a complication of TAVR with a reported prevalence ranging from 7% to 40%.² One approach used to reduce PVL is balloon dilation. Herein, we report the pitfalls and caution that must be taken when using balloon dilation for the treatment of PVL.

CASE REPORT

An 86-year-old male presented to our hospital for evaluation of angina and worsening dyspnea on exertion that led to marked limitation of physical activity. These symptoms, along with the patient's history of coronary artery disease, were consistent with a diagnosis of heart failure. The patient's medical history included prior percutaneous coronary intervention on two occasions, mild chronic obstructive pulmonary disease, and chronic kidney disease.

Diagnostic catheterization showed 75% and 60% stenosis of the first diagonal branch of the left anterior descending artery and the middle right coronary artery, respectively. Transthoracic echocardiography showed an aortic valve area of 0.8 cm², a mean gradient of 35 mm Hg,

and a max velocity of 3.72, thereby meeting the criteria to be considered symptomatic severe aortic stenosis. He also had moderate aortic insufficiency (2+) and moderate mitral regurgitation (2+).

The patient was referred for transfemoral TAVR. The Society of Thoracic Surgeons mortality risk score was 4.57%, indicating intermediate risk for TAVR. Pre-procedure anatomy characterization using multidetector computed tomography (CT) noted a large annulus with an area of 709.7 mm², annular calcification, and severe valvular calcification. Due to the large aortic annulus size, the decision was made to use the largest (29 mm) Sapien 3 prosthetic valve (Edwards Lifesciences) and to deliver the catheter via right transfemoral access under conscious sedation. The valve prosthesis was undersized 8.6% to the annulus and 5.4% to the left ventricular outflow tract. Predilation, which was our routine practice at the time, was performed with 25 mm balloon aortic valvuloplasty (Figure 1A). The 29 mm S3 valve was overexpanded an additional 3 mL during deployment to account for the large annulus (Figure 1B). Postprocedural transthoracic echocardiography (TTE) showed mild to moderate PVL.

Two years later, the patient presented with symptoms of New York Heart Association (NYHA) class III heart failure. TTE showed severe PVL. A review of the patient's pre-TAVR CT scan showed a medium-sized area of annular calcification with inadequate sealing—the likely location of the PVL. This was confirmed with transesophageal echocardiography (TEE). We subsequently decided to perform additional balloon dilation of the valve as an

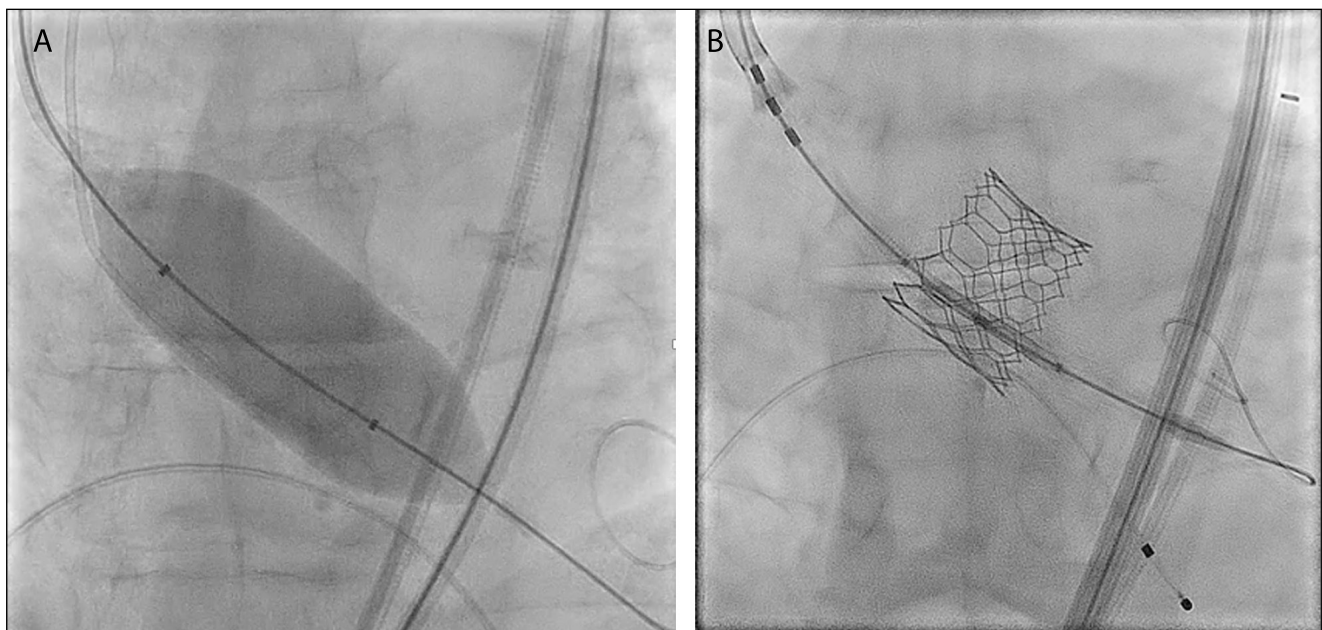
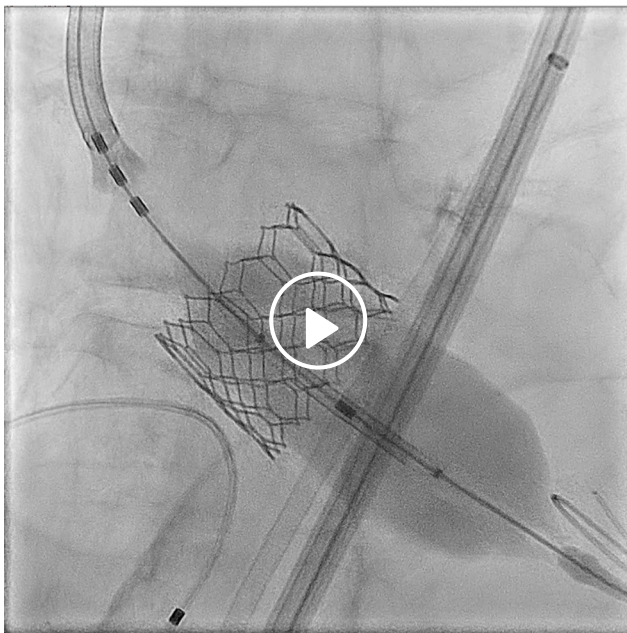


Figure 1 Perioperative fluoroscopy showing (A) dilation and (B) fully expanded valve.

initial step to reduce the PVL followed by PVL closure with a vascular plug, if needed. With the patient under general anesthesia, we used TEE guidance to fill an Edwards balloon an additional 5 mL over nominal volume and dilated the valve, which did not improve the PVL (Video 1). The balloon had slipped into the ventricle during balloon dilation, and TEE immediately showed severe mitral regurgitation with hypotension, which was medically treated. Wire entrapment in the chordae was not noted before balloon dilation but was likely unrecognized (Figure 2).

The patient remained hemodynamically stable, and the PVL was successfully reduced to mild with an Amplatzer



Video 1 Perioperative fluoroscopy showing dilated balloon slipping into the left ventricle; also at <https://youtube.com/shorts/Yj-x1ei9OCw>

vascular plug II (Abbott). The severe mitral regurgitation was subsequently reduced to trivial with a single MitraClip NTR (Abbott) during the same procedure (Figure 3). The patient was discharged home in 48 hours. On 30-day follow-up, the patient's heart failure improved from NYHA III to NYHA I, and he was off home oxygen and experiencing no symptoms.

DISCUSSION

Paravalvular leak is a known complication of TAVR, more so than after SAVR at both 1 and 2 years post procedure, and the presence of moderate or greater PVL after TAVR is associated with increased mortality.³ The common predictors of PVL post-TAVR are annular calcification, annular eccentricity, and undersizing or malpositioning of the device.⁴ Balloon dilation has been reported as an effective treatment for PVL arising from valvular calcification and device undersizing. Both a higher degree of valve calcification and transfemoral approach predict the need for balloon dilation, which has been shown to reduce PVL; periprocedural balloon dilation was successful in our case.⁵ In patients with extremely large annuli (> 683 mm²), it has been shown that despite valve undersizing, it is possible to achieve the same proportion of PVL as in smaller annuli.⁶ When dilating the valve, one must be careful to avoid wire entrapment in the mitral valve chordal apparatus, balloon slippage into the left ventricle, and damage to the mitral chordae. The mitral subvalvular complex consists of the fibrocollagenous tendinous cords, which originate from the papillary muscles.⁷ The papillary muscles are connected to the free wall of the left ventricle, while the tendinous cords attach to the free edges and ventricular aspects of the mitral leaflets. The cords are

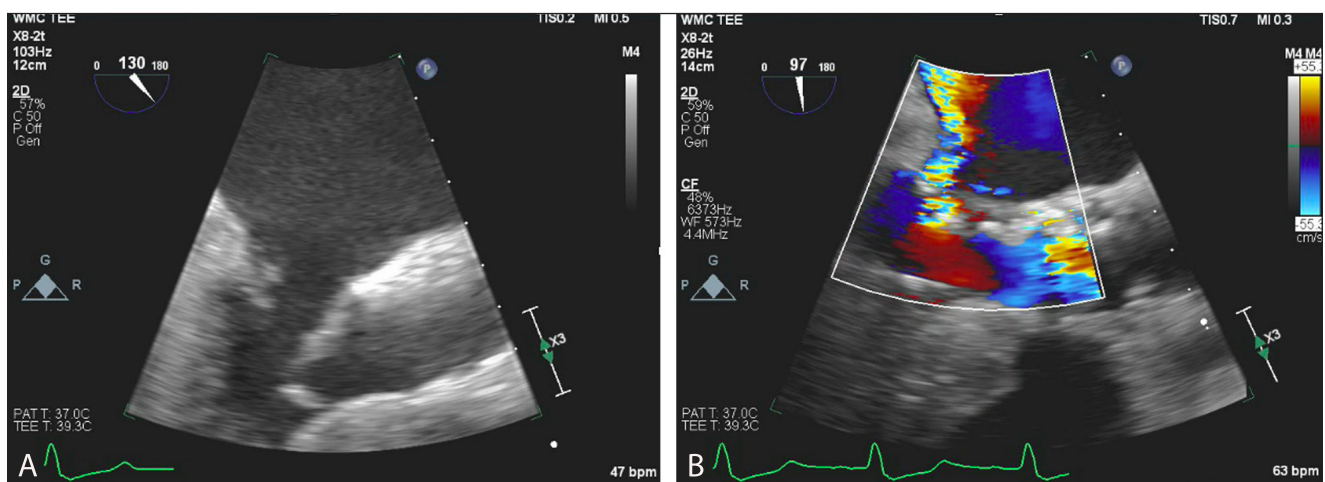


Figure 2 Transesophageal echocardiography showing (A) chordal rupture and (B) severe mitral regurgitation.

thinnest at their sites of insertion on the leaflets, thereby predisposing them to chordal rupture at that site. Due to the proximity of the aortic valve to the mitral valve

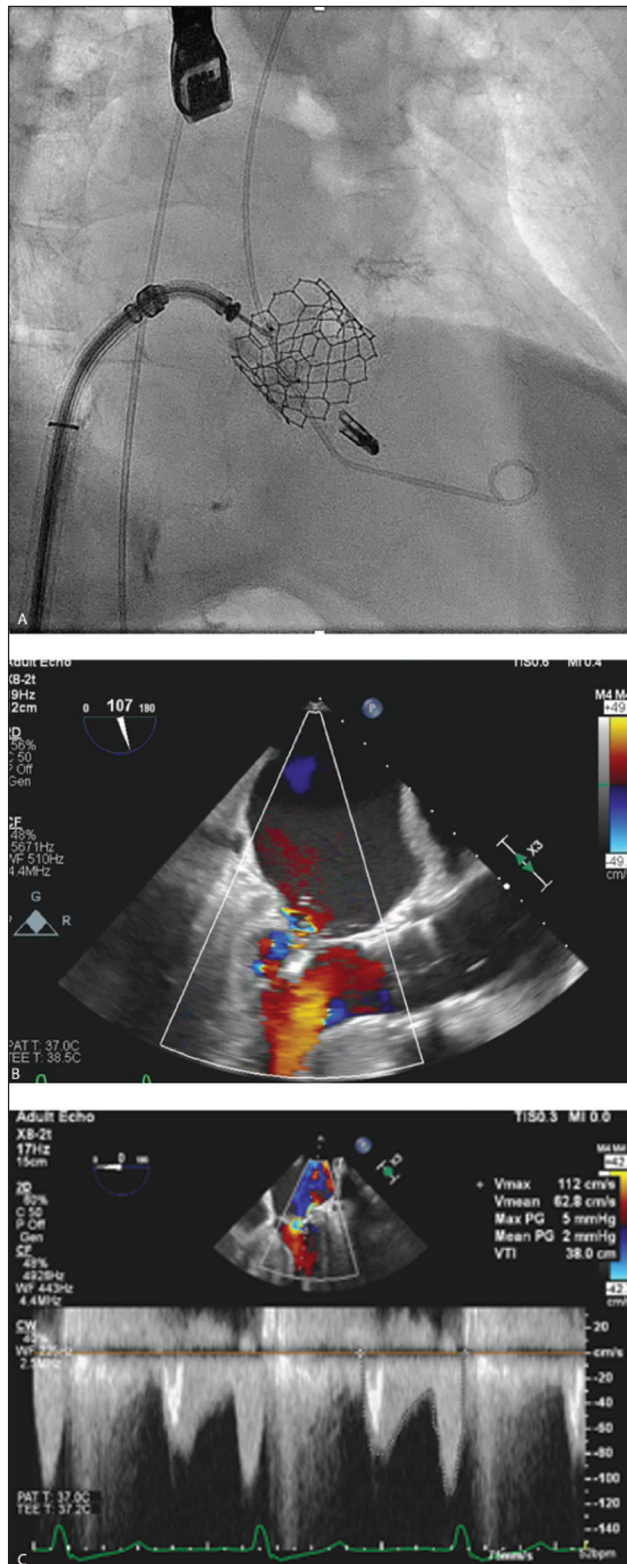


Figure 3 (A) Deployed MitraClip and (B, C) improved mitral regurgitation on transesophageal echocardiographic views.

apparatus, one must be cautious not to impact the mitral apparatus when intervening on the aortic valve. Although the balloon was deployed rapidly to ensure an appropriate reduction in cardiac output to facilitate safe deployment, the balloon slipped. We believe that the wire was trapped in the chordae, and the balloon slippage led to the pulling and subsequent rupturing of the chordae. We report chordal rupture related to balloon slippage during aortic valve balloon dilation as a possible rare complication that may be successfully treated with an emergency MitraClip procedure.

CONCLUSION

This case highlights the importance of recognizing the various treatment options for PVL as well as their indications and pitfalls. Although balloon dilation has been shown to be an effective option to reduce PVL, the operator must use extreme caution deploying the balloon so as not to impact the mitral subvalvular structures. When considering the use of dilatation, mitral valve chordal rupture should be included as a possible perioperative complication.

COMPETING INTERESTS

The authors have no competing interests to declare.

AUTHOR AFFILIATIONS

Akiva Rosenzweig, BA  orcid.org/0000-0001-6757-8841

New York Medical College, Valhalla, New York, US

Syed Zaid, MD  orcid.org/0000-0001-9426-3618

Houston Methodist Hospital, Houston, Texas, US

Joshua Hsu, BA

New York Medical College, Valhalla, New York, US

Hasan Ahmad, MD

Westchester Medical Center, Valhalla, New York, US

Joshua Goldberg, MD  orcid.org/0000-0003-1810-4361

Westchester Medical Center, Valhalla, New York, US

REFERENCES

1. **Mack MJ, Leon MB, Thourani VH, et al.** Transcatheter aortic valve replacement with a balloon-expandable valve in low risk patients. *N Engl J Med.* 2019 May 2;380(18):1695-1705. doi: [10.1056/NEJMoa1814052](https://doi.org/10.1056/NEJMoa1814052)
2. **Bhushan S, Huang X, Li Y, et al.** Paravalvular Leak After Transcatheter Aortic Valve Implantation Its Incidence, Diagnosis, Clinical Implications, Prevention, Management,

- and Future Perspectives: A Review Article. *Curr Probl Cardiol*. 2021 Aug 5;100957. doi: [10.1016/j.cpcardiol.2021.100957](https://doi.org/10.1016/j.cpcardiol.2021.100957)
3. **Kodali SK, Williams MR, Smith CR**, et al. Two-year outcomes after transcatheter or surgical aortic-valve replacement. *N Engl J Med*. 2012 May 3;366(18):1686-95. doi: [10.1056/NEJMoa1200384](https://doi.org/10.1056/NEJMoa1200384)
 4. **Généreux P, Head SJ, Hahn R**, et al. Paravalvular leak after transcatheter aortic valve replacement: the new Achilles' heel? a comprehensive review of the literature. *J Am Coll Cardiol*. 2013 Mar 19;61(11):1125-36. doi: [10.1016/j.jacc.2012.08.1039](https://doi.org/10.1016/j.jacc.2012.08.1039)
 5. **Nombela-Franco L, Rodés-Cabau J, DeLarochellière R**, et al. Predictive factors, efficacy, and safety of balloon post-dilation after transcatheter aortic valve implantation with a balloon-expandable valve. *JACC Cardiovasc Interv*. 2012 May;5(5):499-512. doi: [10.1016/j.jcin.2012.02.010](https://doi.org/10.1016/j.jcin.2012.02.010)
 6. **Tang GHL, Zaid S, George I**, et al. Impact of aortic root anatomy and geometry on paravalvular leak in transcatheter aortic valve replacement with extremely large annuli Using the Edwards SAPIEN 3 Valve. *JACC Cardiovasc Interv*. 2018 Jul 23;11(4):1377-1387. doi: [10.1016/j.jcin.2018.03.034](https://doi.org/10.1016/j.jcin.2018.03.034)
 7. **Van Mieghem NM, Piazza N, Anderson RH**, et al. Anatomy of the mitral valvular complex and its implications for transcatheter interventions for mitral regurgitation. *J Am Coll Cardiol*. 2010 Aug 17; 56(8):617-26. doi: [10.1016/j.jacc.2010.04.030](https://doi.org/10.1016/j.jacc.2010.04.030)

TO CITE THIS ARTICLE:

Rosenzweig A, Zaid S, Hsu J, Ahmad H, Goldberg J. MitraClip for Severe Mitral Regurgitation from Chordal Rupture during Balloon Aortic Valvuloplasty. *Methodist DeBakey Cardiovasc J*. 2022;18(1):73-77. doi: [10.14797/mdcvj.111](https://doi.org/10.14797/mdcvj.111)

Submitted: 28 March 2022 **Accepted:** 11 April 2022 **Published:** 20 September 2022

COPYRIGHT:

© 2022 The Author(s). This is an open-access article distributed under the terms of the Attribution-NonCommercial 4.0 International (CC BY-NC 4.0), which permits unrestricted use, distribution, and reproduction in any noncommercial medium, provided the original author and source are credited. See <https://creativecommons.org/licenses/by-nc/4.0/>.

Methodist DeBakey Cardiovascular Journal is a peer-reviewed open access journal published by Houston Methodist DeBakey Heart & Vascular Center.