

Intercondylar Ganglion Cyst with Mucoïd Degeneration of Posterior Cruciate Ligament of Knee: Report of A Rare Case and Review of Literature

Vandana V Ahluwalia¹, DayanandaSagar.G¹, Shamrendra Narayan¹, Arun Gupta²

What to Learn from this Article?

Clinical features and MRI appearance of PCL mucoïd degeneration and intercondylar ganglion cyst.

Abstract

Introduction: Mucoïd degeneration and Ganglion cysts arising from the posterior cruciate ligament (PCL) of the knee are rare. The aetiology, clinical features and Magnetic resonance imaging (MRI) appearance of PCL mucoïd degeneration and intercondylar ganglion cyst are discussed.

Case Report: We present a 36 year-old male patient who presented with chronic right knee pain for the duration of 5-6 months. No evidence of ligament instability on clinical examination was found. A diagnosis of PCL mucoïd degeneration and intercondylar ganglion cyst was made on MRI.

Conclusion: Mucoïd degeneration and ganglion cyst involving PCL are uncommon lesions and represents the spectrum of same pathology. MR imaging is sensitive, specific, accurate and noninvasive, while providing multiplanar imaging and superior identification of the anatomical and morphological relationship of the synovial tissue to the surrounding structures, an additional intra-articular lesions can also be detected.

Keywords: ganglion cyst, mucoïd degeneration, intercondylar, posterior cruciate ligament.

Author's Photo Gallery



Dr. Vandana V
Ahluwalia



Dr. Dayananda
Sagar G



Dr. Shamrendra
Narayan



Dr. Arun Gupta

Introduction

Intra-articular ganglion cysts especially those arising from the cruciate ligaments are very uncommon, with a reported prevalence of 0.2%–1.3% on MR imaging[1,2] and 0.1%–0.6% on knee arthroscopy[1,2]. Posterior cruciate ligament (PCL) ganglion cysts occur less frequently than those arising from the anterior cruciate ligament (ACL). Here we describe a rare case of mucoïd degeneration of PCL with intercondylar ganglion cyst.

Case Report

A 36 year old male patient presented with history of right knee pain exacerbated by squatting for 5-6 months. He did not experience locking or the sensation of giving way. There was no history of trauma and was not an avid sports person. He had not undergone any prior treatment.

On physical examination, he had a full range of motion of the right knee, but terminal flexion was painful. There was moderate tenderness over the posteromedial joint line, but no palpable lump was detected. No clinical evidence of ligament instability was found. Radiographs of the right knee were normal. Magnetic resonance (MR) imaging of the knee was performed.

The MR findings revealed a homogenous T1 iso/hyperintense soft tissue mass extending within inter-condylar notch abutting the posterior margin of PCL. The PCL outline was also distended by similar

¹Department of Radiodiagnosis, Sarojini Naidu Medical College Agra, Uttar Pradesh – 282002, India.

²Joint Replacement and Arthroscopy Surgeon OJAS Clinic, E-8, Tanki road, Kamla Nagar, Agra, Uttar Pradesh – 282004, India.

Address of Correspondence

Dr. Dayananda Sagar G, M.B.B.S
Junior Resident-III (M.D., Radiodiagnosis)
Department of Radiodiagnosis, Sarojini Naidu Medical College
Agra, Uttar Pradesh – 282002, India
Ph: +919760021533.
Email: drvahluwalia@gmail.com

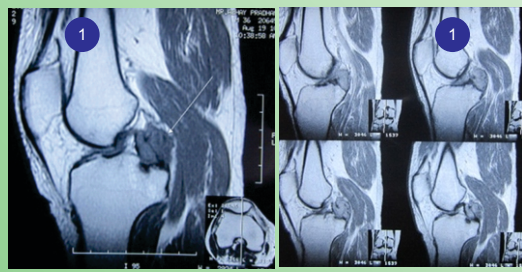


Figure 1 & 2 : Sagittal T1W image of right knee : A homogenous iso/hyperintense soft tissue mass extending within intercondylar notch abutting the posterior margin of PCL. The PCL is also distended by similar signal intensity soft tissue with intact outline of its fibres.

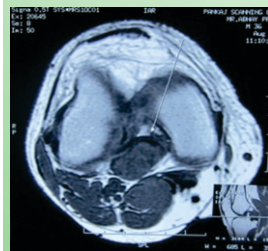


Figure 3 : Axial T1W image of right knee: distension of PCL outline with Iso/hyperintense signal with a homogenous iso-intense mass in relation to PCL.

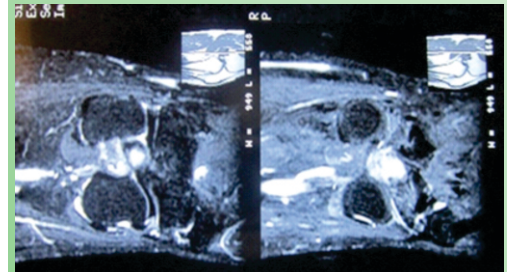


Figure 4 : Coronal T2W & STIR image of right knee: Fusiform enlargement of PCL with relative preservation of its fibrous structure with hyperintense signal. Note the early intra-articular extension along the PCL attachment.

signal intensity soft tissue with intact outline of its fibres. The fusiform ligamentous enlargement gave a “celery stalk” appearance with relative preservation of its fibrous structures which appears hyperintense on T2 and STIR sequences. There was early intra-articular extension along the PCL attachment. ACL outline was maintained in course, caliber and signal.

Arthroscopy confirmed mucoid degeneration of PCL with extraligamentous collection. Arthroscopic decompression and debridement of mucoid tissue was done under spinal anesthesia. The tissue was sent for histopathology which confirmed the diagnosis of Posterior cruciate ligament mucoid degeneration with intercondylar notch/ganglion cyst

Discussion

Mucoid degeneration of cruciate ligaments is a rare process that has been discussed in few reports. Pathogenesis of mucoid degeneration is unclear and is thought to be related to repeated trauma. Ganglion cysts have also been attributed to mucoid degeneration in the connective tissue from which they arise.

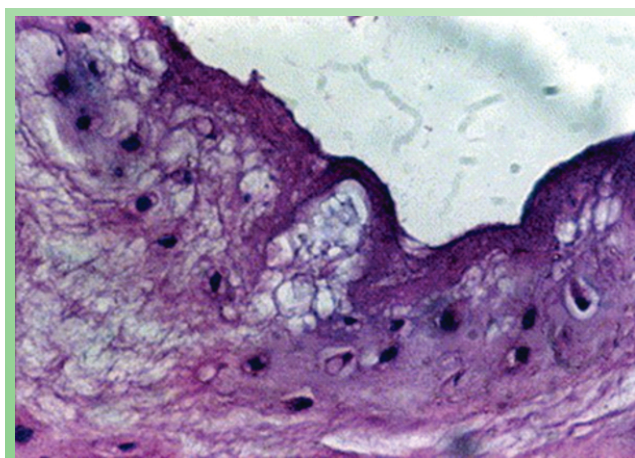


Figure 5 : Photomicrograph showing Mucoid Degeneration of PCL (H&E, original magnification x 40).

In 1924, Caan [3] first described the anterior cruciate ligament ganglion during a routine dissection. Currently, two theories relating to the pathogenesis of ganglion cysts exist, although the true cause is still unknown [4-6]. The first theory attributes the presence of ganglion cysts to being a product of mucinous degeneration of the connective tissue [6,7]. The second theory considers it a cause of herniation of synovial tissue through a defect in the joint capsule or tendon sheath, similar to those of wrist joint origin [4,8]. For both theories, the relationship to previous trauma is uncertain and has not been documented.

Mucoid degeneration and intra articular ganglion cysts of knee are rare lesions. These lesions are predominantly incidental findings on MR imaging and arthroscopy. Most commonly mucoid degeneration and ganglion cyst involves ACL than PCL. Brown and Dandy found that only six of 35 ganglion cysts arising from the cruciate ligaments were from the PCL [9], similar to the findings of Bui-Mansfield and Youngberg, where eight of 23 cruciate ligament ganglion cysts arose from the PCL[2] and those of Krudwig et al, where only 16 of 49 cruciate ligament ganglion cysts arose from the PCL[10].

Intercondylar ganglion cyst are seen within or extending from the intercondylar area. They contain thick, sticky, clear, colourless, jellylike material. These cysts are often associated with mucoid degeneration of cruciate ligament with degenerative cysts at its attachment. Kaatee et al. [4] described how long-standing pressure of a ganglion cyst against an adjacent hard surface may produce an indentation through gradual erosion of the bone, creating an intraosseous ganglion. The high incidence of intraosseous ganglia in patients with either mucoid degeneration of the cruciate ligament or intrasubstance cruciate ligament ganglia suggests that these two entities may share a similar pathogenesis.

Ganglion cysts of the cruciate ligaments are usually asymptomatic, and are often hard to diagnose clinically due

to the lack of specific symptoms and signs. Symptomatic patients may present with pain aggravated with flexion or activity, increased pain during posture change, locking, clicking or popping sensations, and a decreased range of motion. Ganglion cysts arising from the PCL may impinge between the ligament and the intercondylar roof, limiting flexion through mechanical block. Because the intercondylar notch is relatively spacious, it may take time for the mass to develop into a size large enough to cause symptoms.

IMAGING FEATURES:

Mucoid degeneration on MRI shows a relatively maintained outline of cruciate ligament, increased girth compared to normal, T1 intermediate/hypointense and T2 intermediate/hyperintense signal intensity, normal orientation of the ligament, and “celery-stalk” appearance. Ganglion cyst may appear fluid-filled, with low T1 and high T2- and proton-weighted signal, and could be sharply demarcated with homogeneous appearance. Ganglion cyst may occur either in the substance of the ligament extending into intercondylar area or at the attachment site leading to intraosseous expansion.

Conclusion

Mucoid degeneration and ganglion cyst involving PCL are uncommon lesions and represents the spectrum of same pathology. MR imaging is sensitive, specific, accurate and noninvasive, while providing multiplanar imaging capability with its attendant advantages. Superior identification of the anatomical and morphological relationship of the synovial tissue to the surrounding structures is possible, and additional intra-articular lesions can also be detected.

Though rare, the diagnosis of mucoid degeneration of cruciate ligament of knee has to be kept in mind in a patient presenting with knee pain, especially in terminal flexion and extension, without significant history of trauma.

Imaging-guided percutaneous aspiration of cyst contents should be considered initially for symptomatic patients,

with arthroscopic surgery reserved for patients that do not respond satisfactorily.

Clinical Message

Mucoid degeneration and ganglion cysts of cruciate ligament are uncommon lesions and are increasingly being evaluated and recognized as a cause of chronic pain in a non-traumatic knee. Early diagnosis and treatment is crucial in limiting the ligament instability and need for arthroscopic reconstruction.

References

1. Durante JA. Ganglion cyst on the posterior cruciate ligament: case report. *J Can Chiropr Assoc* 2009; 53: 334-8.
2. Bui-Mansfield LT, Youngberg RA. Intraarticular ganglia of the knee: prevalence, presentation, etiology and management. *AJR Am J Roentgenol* 1997; 168:123-7.
3. Caan P. Cyst formation (ganglion) in an anterior cruciate ligament of the knee. *Deutsch Z Chir* 1924; 186:403-408.
4. Kaatee R, Kjartansson O, Brekkan A. Intraarticular ganglion between the cruciate ligaments of the knee. *Acta Radiol* 1994; 35:434-436.
5. Doyle RW. Ganglia and superficial tumors. *Practitioner* 1946; 156:267-277
6. Kumar A, Bickerstaff DR, Grimwood JS, SuvarnaSK. Mucoid cystic degeneration of the cruciate ligament. *J Bone Joint Surg Br* 1999; 80:304-305.
7. Fealy S, Kenter K, Dines JS, Warren RF. Mucoid degeneration of the anterior cruciate ligament. *Arthroscopy* 2001; 17:37-39.
8. Angelides AC, Wallace PF. The dorsal ganglion of the wrist: its pathogenesis, gross and microscopic anatomy and surgical treatment. *J Hand Surg* 1976; 1:228-235.
9. Brown MF, Dandy DJ. Intra-articular ganglia in the knee. *Arthroscopy* 1990; 6:322-3.
10. Krudwig WK, Schulte KK, Heinemann C. Intra-articular ganglion cysts of the knee joint: a report of 85 cases and review of the literature. *Knee Surg Sports Traumatol Arthrosc* 2004; 12:123-9.

Conflict of Interest: Nil
Source of Support: None

How to Cite this Article:

Ahluwalia VV, DayanandaSagar.G, Narayan S, Gupta A. Intercondylar Ganglion Cyst With Mucoid Degeneration Of Posterior Cruciate Ligament Of Knee Report Of - A Rare Case And Review Of Literature- *Journal of Orthopaedic Case Reports*. 2014 Jan-Mar;4(1): 32-34