



## Original Article

# Snapping scapula syndrome: arthroscopic surgical treatment<sup>☆</sup>



Alexandre Tadeu do Nascimento<sup>a,b,\*</sup>, Gustavo Kogake Claudio<sup>a</sup>

<sup>a</sup> Grupo de Ombro e Cotovelo, Hospital Orthoservice, São José dos Campos, SP, Brazil

<sup>b</sup> Departamento Médico, Confederação Brasileira de Rugby, São Paulo, SP, Brazil

## ARTICLE INFO

## Article history:

Received 2 August 2017

Accepted 5 September 2017

Available online 10 October 2018

## Keywords:

Bursitis

Arthroscopy

Shoulder pain

Escápula

## ABSTRACT

**Objectives:** To evaluate the results of patients undergoing arthroscopic surgical treatment for snapping scapula syndrome.

**Methods:** This is a retrospective study of 11 patients undergoing scapulothoracic arthroscopy for the treatment of snapping scapula syndrome. The study included patients with clinical diagnosis of snapping scapula syndrome who did not show pain improvement after at least six months of physical therapy. Patients were assessed using the DASH, UCLA, visual analogue pain assessment (VAS), and Short-Form 36 (SF36) scores.

**Results:** The mean age at surgery was 38.4 years (21–48). The mean duration of symptoms before surgery was 2.8 years (range 6 months to 6 years). The mean follow-up duration was 12 months (range: 6.4–28). The mean postoperative scores were: DASH, 7.8 points; VAS, 1.5 points, being ten cases (90%) of mild pain and one case (10%) of moderate pain; UCLA, 32; and SF-36, 79.47.

**Conclusions:** The arthroscopic approach for the treatment of snapping scapula syndrome presents excellent functional results.

© 2018 Sociedade Brasileira de Ortopedia e Traumatologia. Published by Elsevier Editora Ltda. This is an open access article under the CC BY-NC-ND license (<http://creativecommons.org/licenses/by-nc-nd/4.0/>).

## Ressalto de escápula: tratamento cirúrgico artroscópico

## RESUMO

**Objetivo:** Avaliar os resultados funcionais de pacientes submetidos ao tratamento cirúrgico artroscópico para ressalto de escápula.

**Métodos:** Estudo retrospectivo de 11 pacientes submetidos a artroscopia escapulotorácica para tratamento de ressalto de escápula. Foram incluídos no estudo pacientes com diagnóstico de ressalto de escápula que não apresentaram melhoria da dor com tratamento fisioterápico por no mínimo seis meses. Os pacientes foram avaliados pelo escore de Dash, UCLA, pela classificação visual analógica de dor (EVA) e pelo Short-Form 36 (SF36).

## Palavras-chave:

Bursite

Artroscopia

Dor de ombro

Escápula

<sup>☆</sup> Study conducted at Hospital Orthoservice, São José dos Campos, SP, Brazil.

\* Corresponding author.

E-mail: [dr.nascimento@icloud.com](mailto:dr.nascimento@icloud.com) (A.T. Nascimento).

<https://doi.org/10.1016/j.rboe.2017.09.012>

2255-4971/© 2018 Sociedade Brasileira de Ortopedia e Traumatologia. Published by Elsevier Editora Ltda. This is an open access article under the CC BY-NC-ND license (<http://creativecommons.org/licenses/by-nc-nd/4.0/>).

**Resultados:** A média de idade na cirurgia foi de 38,4 anos (21 a 48). O tempo médio de sintomas antes da cirurgia foi de 2,8 anos (variação de seis meses a seis anos). O seguimento médio foi de 12 meses (variação de 6,4 a 28). A média dos escores pós-operatórios foi de 7,8 pontos no Dash; 1,5 ponto no EVA, dez casos (90%) de dores leves e um caso (10%) de dores moderadas; 32 pontos no UCLA e 79,47 pontos no SF-36.

**Conclusão:** A abordagem artroscópica para tratamento de ressalto de escápula apresenta excelentes resultados funcionais.

© 2018 Sociedade Brasileira de Ortopedia e Traumatologia. Publicado por Elsevier Editora Ltda. Este é um artigo Open Access sob uma licença CC BY-NC-ND (<http://creativecommons.org/licenses/by-nc-nd/4.0/>).

## Introduction

Snapping scapula is a disorder that varies in its clinical manifestations from a mild to a disabling disorder, characterized by scapulothoracic movements that produce an audible and/or palpable crackling, pain, and snapping sensation.<sup>1</sup> The sound is produced by a tactile-acoustic phenomenon that occurs as a consequence of an anomalous tissue between the thoracic wall and the scapula. While most patients who present these sounds do not report other symptoms, some report pain at the time of the noise.<sup>2</sup> Many causes have been suggested for this syndrome, one of which is the effort of the upper limb in repetitive movements, particularly in activities above shoulder level, which produce microtraumas and a local bursitis that can generate a bony spur at the level of the muscle fixation on the scapula.<sup>3</sup> In a study of patients with snapping scapula, it was suggested that scapulothoracic bursitis was caused by an abnormal curvature of the superomedial scapular angle, skeletal abnormalities, or soft tissue changes.<sup>4</sup> The superomedial angle, formed by the upper border and the edge of the scapula body, normally ranges from 124° to 162°. Anatomical variations in the superomedial angle may have clinical implications in the onset of snapping scapula.<sup>5</sup> In a cadaveric study, 8.6% (60) of 700 scapulae presented flexion >35°. Approximately 6% of the scapulae presented a hook-shaped prominence, known as the Luschka tubercle, in their superomedial angle. This tubercle may be in contact with the rib cage, resulting in painful crackling.<sup>6</sup> Snapping scapula may result from scapular dyskinesia, which in turn is observed with great frequency in patients with glenohumeral joint pathology. In some studies, dyskinesia was observed in 14 of 22

patients with shoulder instability, in seven of seven patients with impingement syndrome, and in 15 of 15 patients with rotator cuff disorders.<sup>7,8</sup> Physical therapy may be beneficial for pain relief. Stabilizer strengthening and resistance training are extremely important.<sup>1</sup> In cases of physical therapy failure, bursectomy with or without partial scapulectomy is the most effective primary treatment to date.<sup>9</sup>

## Material and methods

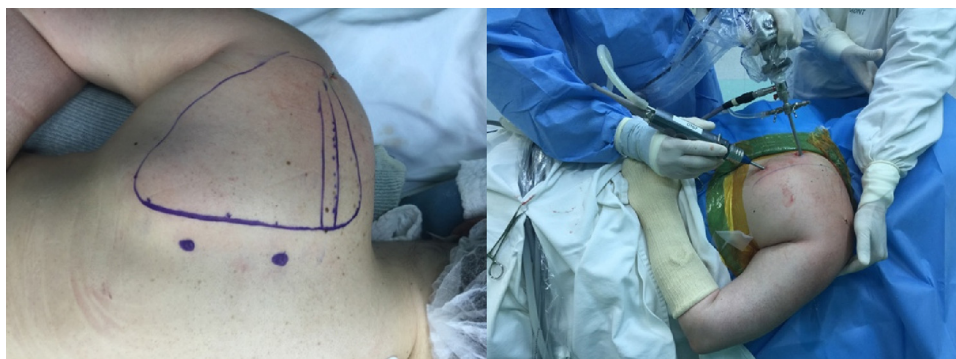This is a retrospective study of 11 patients undergoing scapulothoracic arthroscopy for the treatment of snapping scapula. The study included patients with a diagnosis of snapping scapula who did not present improvement of pain symptoms after at least six months of physical therapy focused on the strengthening of the scapular muscles. Patients with snapping scapula secondary to scapular fracture or those with a history of previous surgical procedure in this bone were not included in the study.

The UCLA, Dash, VAS, and SF-36 scores were applied to all patients pre and postoperatively.

## Surgical technique

The procedure was performed with the patient in the prone position with the arm extended and rotated internally, with the back of the hand resting over the lumbar region (chicken wing; Fig. 1).

This position elevates the medial scapular border and opens the scapulothoracic spaces for endoscopic exploration.



**Fig. 1 – Patient in the chicken wing position.**

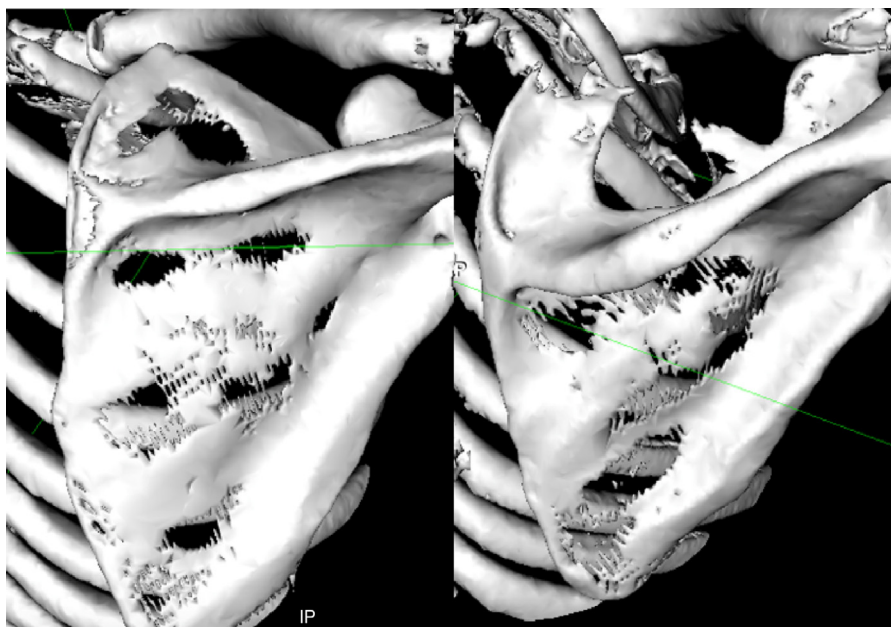


Fig. 2 – Pre- and postoperative tomography with 3D reconstruction.

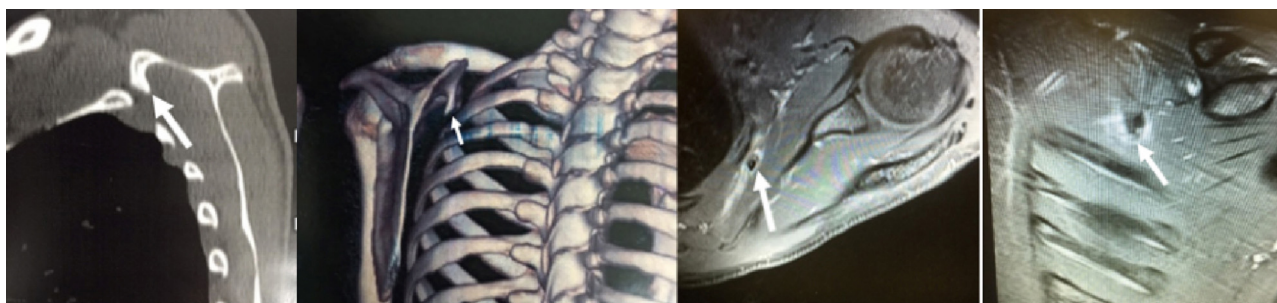


Fig. 3 – Tomography and magnetic resonance imaging showing a bone tumor in the superomedial region of the scapula.

The bone processes are marked on the skin (superomedial scapular angle, medial scapular border, and scapular spine), as well as the two medial parascapular portals (Fig. 1). The initial entrance portal is located medial to the scapular angle, immediately below the level of the scapulothoracic spine, 3 cm from its medial border; a second portal is positioned approximately 4 cm below the first portal. In order to access the superior angle of the scapula, a portal located superiorly to it may be required.<sup>10</sup> After the subscapular region is infiltrated with saline solution for initial distension, portals are made for the insertion of the trochanter for the arthroscope. An infusion pump with a mean pressure of 60 mmHg is used to inflate the scapulothoracic space. Due to the infusion of saline solution under pressure, care must be taken to ensure that the procedure does not exceed 40 min. The joint is inspected and special attention is given to some anatomical landmarks. The first landmark to be identified is the serratus muscle. Superomedial bursectomy is performed without violating this muscle or its fascial insertion. Another landmark is the subspinal bursa, which must be resected and debrided. The final landmark is the superomedial bone angle, which can be identified with an external needle for orientation. Any bone prominence

identified in this region is excised with a bone shaver; 5–10-mm thickness is resected and aligned to the bone axis of that region.<sup>11</sup>

### Postoperative period

In the postoperative period, patients were left in a sling for approximately five days, for comfort only; after this period, movement was authorized according to their pain. Postoperative control radiographs and a tomography were performed six months after the surgery (Fig. 2). Physical therapy for range of motion gain was started after two weeks; strengthening exercises were initiated after full range of motion was achieved. Patients were authorized to return to sport activities three months after surgery.

### Statistical analysis

Statistical analysis compared the pre and postoperative measurements using Student's *t*-test. Two-tailed paired tests were used in all cases;  $p < 0.05$  were considered significant.



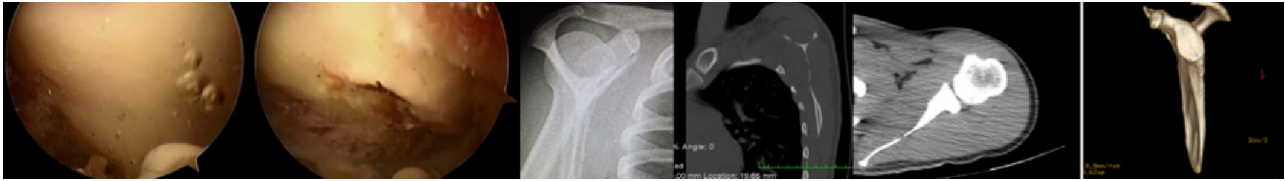

Fig. 4 – Intraoperative, radiographic, and tomography images, post bone tumor resection.

Table 1 – DASH, UCLA, and VAS results.<sup>a</sup>

	DASH	UCLA	VAS
Preoperative period	42.1 ± 19.8 (11.6–75.8)	23.3 ± 3.3 (18–28)	7.5 ± 1.4 (5–10)
Postoperative period	7.8 ± 9.2 (0.83–23.3)	32 ± 2.7 (27–35)	1.5 ± 1.4 (0–5)
p-Value	<0.01	<0.01	<0.01

<sup>a</sup> Values are presented as mean and standard deviation; the range is in parentheses.

## Results

The inclusion criteria were met by 11 patients, seven men and four women. The mean age at surgery was 38.4 years (21–48). The mean duration of symptoms prior to surgery was 2.8 years (range: 6 months to 6 years). The mean follow-up was 12 months (range: 6.4–28). Five right shoulders and six left shoulders were operated. Overall, eight patients (72%) described their jobs as requiring upper limb effort or activity above shoulder level. One patient (9%) presented snapping due to an osteochondroma in the superomedial region of the scapula (Fig. 3), on its ventral face. This patient had her bone tumor completely removed by scapulothoracic arthroscopy (Fig. 4) and presented complete symptom remission. The other ten patients did not present bone alterations. Six patients (55%) had undergone surgery due to rotator cuff injury and two patients (18%) had a diagnosis of shoulder impingement syndrome on the same side of the snapping scapula.

The study included patients diagnosed with snapping scapula that showed unsatisfactory or no improvement after conservative treatment, which consisted of six months of physical therapy focused on parascapular muscle strengthening. The results regarding the improvement in the UCLA, VAS, and Dash scores are shown in Table 1. The mean postoperative scores were 7.8 points in the Dash; 1.5 points in the VAS, ten cases (90%) of mild pain and one (10%) of moderate pain; 32 points in the UCLA score; and 79.47 in the SF-36. Only one patient presented only a very slight improvement with the procedure; nonetheless, in this patient, the Dash score was reduced from 71.66 to 23.33; the VAS reduced from 8 to 5, and the UCLA increased from 18 to 27. No complications resulting from the surgical procedure were observed.

The results of the SF-36 were subdivided according to its areas; Table 2 presents the detailed results.

## Discussion

Snapping scapula is a disorder that varies in its clinical manifestations from a mild to limiting disorder. Many causes

have been suggested for this syndrome, and osteochondroma accounts for approximately 15% of cases.<sup>12</sup> In the present study, in the cases of snapping scapula that required surgery, only one case of osteochondroma (9%) was observed. As shown in other studies,<sup>8</sup> the majority of patients (73% of cases) presented some shoulder pathology, which probably led to scapular dyskinesia and, subsequently, snapping scapula onset. As previously demonstrated, in cases of physical therapy failure, bursectomy with or without partial scapulectomy is the most effective primary treatment to date.<sup>9</sup> Although technically complex, arthroscopic surgery for the treatment of snapping scapula presents several theoretical advantages over open surgical treatment. In the present study, the bursectomy procedure was associated with partial scapulectomy in all cases, except in the case of osteochondroma, in which only tumor resection was performed together with bursectomy. The main advantage of the arthroscopic procedure is that it preserves the muscle attachments, thereby eliminating the need for immobilization in the postoperative period and had a shorter rehabilitation period.<sup>13</sup> Patients in the study used a sling for postoperative comfort only, for approximately five days, with no significant complaints or complications. Patients were authorized to return to sport practice merely three months after the surgery. A statistically significant improvement was observed in practically all functional scores evaluated, including those that evaluate the quality of life. These results are in agreement with the literature, which has demonstrated excellent results with this procedure for the treatment of snapping scapula.<sup>9</sup> In the present study, no complications related to the procedure were observed.

## Conclusion

The surgical arthroscopic treatment of snapping scapula presents good results in the functional scores; it is effective, safe, and allows early rehabilitation. A statistically significant improvement was observed in almost all functional scores evaluated. In the present study, no complications related to the procedure were observed.

**Table 2 – Pre and postoperative SF-36 results.<sup>a</sup>**

	Functional capacity	Limitation due to physical aspects	Pain	General health	Vitality	Social aspects	Limitations due to emotional aspects	Mental health
Preoperative	60 ± 23.1 (25–95)	20.5 ± 31.3 (0–75)	39.4 ± 28.1 (0–90)	50 ± 20.2 (15–80)	65.5 ± 20.2 (35–100)	68.2 ± 23.3 (12.5–87.5)	24.2 ± 36.8 (0–100)	69.1 ± 14.3 (40–88)
Postoperative	79.5 ± 20.3 (35–100)	88.6 ± 25.9 (25–100)	76.2 ± 13.3 (52–90)	63.8 ± 14.1 (37–80)	82.7 ± 12.5 (55–100)	85.2 ± 10.9 (62.5–100)	54.5 ± 52.2 (0–100)	80 ± 11.2 (56–100)
p-Value	0.02	<0.01	<0.01	0.04	0.03	0.01	0.16	0.02

<sup>a</sup> Values are presented as mean and standard deviation; the range is in parentheses.

## Conflicts of interest

The authors declare no conflicts of interest.

## REFERENCES

- Manske RC, Reiman MP, Stovak ML. Nonoperative and operative management of snapping scapula. *Am J Sports Med.* 2004;32(6):1554–65.
- Milch H. Partial scapulectomy for snapping of the scapula. *J Bone Joint Surg Am.* 1950;32(3):561–6.
- Nascimento AT, Claudio GK. Snapping scapula. Arthroscopic resection of osteochondroma of the subscapularis superomedial angle. Case report and literature review. *Rev Bras Ortop.* 2017;52(2):220–3.
- Milch H, Burman MS. Snapping scapula and humerus varus. Report of six cases. *Arch Surg.* 1933;26:570–88.
- Aggarwal A, Wahee P, Harjeet, Aggarwal AK, Sahni D. Variable osseous anatomy of costal surface of scapula and its implications in relation to snapping scapula syndrome. *Surg Radiol Anat.* 2011;33(2):135–40.
- Edelson JG. Variations in the anatomy of the scapula with reference to the snapping scapula. *Clin Orthop Relat Res.* 1996;(322):111–5.
- Paletta GA Jr, Warner JJ, Warren RF, Deutsch A, Altchek DW. Shoulder kinematics with two-plane X-ray evaluation in patients with anterior instability or rotator cuff tearing. *J Shoulder Elbow Surg.* 1997;6(6):516–27.
- Kibler WB, McMullen J. Scapular dyskinesia and its relation to shoulder pain. *J Am Acad Orthop Surg.* 2003;11(2):142–51.
- Warth RJ, Spiegl UJ, Millett PJ. Scapulothoracic bursitis and snapping scapula syndrome: a critical review of current evidence. *Am J Sports Med.* 2015;43(1):236–45.
- Ruland LJ 3rd, Ruland CM, Matthews LS. Scapulothoracic anatomy for the arthroscopist. *Arthroscopy.* 1995;11(1):52–6.
- Bhatia DN. Scapulothoracic endoscopy for the painful snapping scapula: endoscopic anatomy and scapulothoracic technique. *Arthrosc Tech.* 2015;4(5):e551–8.
- Kumar N, Ramakrishnan V, Johnson GV, Southern S. Endoscopically-assisted excision of scapular osteochondroma. *Acta Orthop Scand.* 1999;70(4):394–6.
- Harper GD, McIlroy S, Bayley JI, Calvert PT. Arthroscopic partial resection of the scapula for snapping scapula: a new technique. *J Shoulder Elbow Surg.* 1999;8(1):53–7.