

Single Case

Dupilumab-Induced Lichen Planus: A Case with Oral and Cutaneous Eruptions

Laura Kern Luisa Kleinheinrich Robert Feldmann Paul Sator
Alexander Stella Friedrich Breier

Department of Dermatology, Hietzing Municipal Hospital, Vienna, Austria

Keywords

Atopic dermatitis · Dupilumab · Lichen planus · Drug eruption

Abstract

Lichen planus is a chronic, inflammatory, immune-mediated dermatosis affecting the patient's skin, scalp, mucous membranes, and nails. Drug-induced lichen planus is described after the administration of antimalarials, β -blockers, methyldopa, NSAIDs, penicillamines, and sodium aurothiomalate. The use of biologicals such as adalimumab, etanercept, and infliximab has also been linked with the appearance of lichenoid eruptions in the recent past. In this case, we report on a patient developing oral and cutaneous lichen planus after the administration of dupilumab. The lichenoid lesions occurred after 11 months of the drug's administration and involved the buccal walls, trunk, and extremities. Dupilumab had been administered in an effort to counter severe atopic dermatitis exacerbations. Dupilumab is associated with a downregulation of T-helper 2 cell activation by blocking the Interleukin-4/Interleukin-13 pathway, so leading to a TH1/TH2 imbalance. This imbalance may cause a shift toward a TH1-mediated immune response and be an explanation for the drug-induced lichen planus. Dupilumab was discontinued, and the patient was treated with oral corticosteroids and UVB phototherapy, leading to a significant improvement in the lichen planus lesions.

© 2022 The Author(s).

Published by S. Karger AG, Basel

Introduction

Lichen planus (LP) is an immune-mediated inflammatory dermatosis affecting the skin, scalp, nails, and mucous membranes. Clinical appearance of cutaneous LP is characterized by polygonal, flat-topped, violaceous, confluent, pruritic papules. The most common sites for cutaneous involvement are the wrists, forearms, and distal extremities [1, 2].

While the etiology of LP is not yet fully understood, several disease-triggering factors have been described, including viral infections, vaccines, and certain diseases [3]. Furthermore, an increasing number of drugs, such as antimalarials, β -blockers, methyldopa, NSAIDs, penicillamines, and sodium aurothiomalate, have been associated with the development of LP as a rare adverse effect. These lesions are referred to as drug-induced LP [4]. The development of LP has also been observed in patients being treated with biologicals in the recent past [3].

Although a case displaying lichenoid drug eruptions involving the administration of dupilumab was reported recently, no mucous membranes were involved in this case [5]. Here, we present a 23-year-old patient suffering from the occurrence of cutaneous and oral lichenoid eruptions during the administration of dupilumab.

Case Report

A 23-year-old woman who had suffered from severe atopic dermatitis (AD) since early childhood was referred to our clinic after her condition had worsened progressively, and she had begun displaying severe pruritus in the past couple of months. A clinical examination showed a manifestation of eczema in the neck, elbow, upper arm, abdominal wall, and retroauricular regions. The patient's treatment consisted of topical steroids, antihistamines, and UVB phototherapy. Due to her worsening condition, dupilumab therapy was initiated, with a first dose of 600 mg and continuing doses of 300 mg being administered every other week. After 2½ weeks, complete eczema remission was clinically observed, and the symptoms of pruritus showed clear signs of improvement.

After 11 months of dupilumab treatment, however, flat-topped violaceous papules appeared, affecting the patient's wrists, fingers, abdominal wall, upper thighs, and lower legs. The lichenoid lesions involved the oral mucous membrane, with manifestations both on the buccal walls and in the labial region (shown in Fig. 1).

Histological examination of a skin biopsy obtained from the right upper thigh area showed hyperkeratosis, acanthosis, liquefaction degeneration of the basal cell layer of the epidermis, and a band-like lymphocytic infiltrate in the upper dermis (shown in Fig. 2). The histological changes were consistent with LP. There was no evidence to suggest eosinophilic granulocytes in the dermal tissue.

Dupilumab treatment was discontinued, and as a result of extensive, symptomatic disease, the patient was treated with an oral corticosteroid. Methylprednisolone was administered for 10 days and tapered over the subsequent 6 weeks. The lichenoid lesions showed a marked improvement when subjected to this therapy. During the tapering period, no AD lesions were observed. However, after the withdrawal of oral corticosteroids, very subtle AD lesions appeared on the head and extremities.

Discussion

In the recent past, a temporal correlation has been described between the administration of biologics such as adalimumab, etanercept, and infliximab and the sudden appearance of lichenoid eruptions [6, 7]. Kim et al. reported on a patient with lichenoid rash appearance

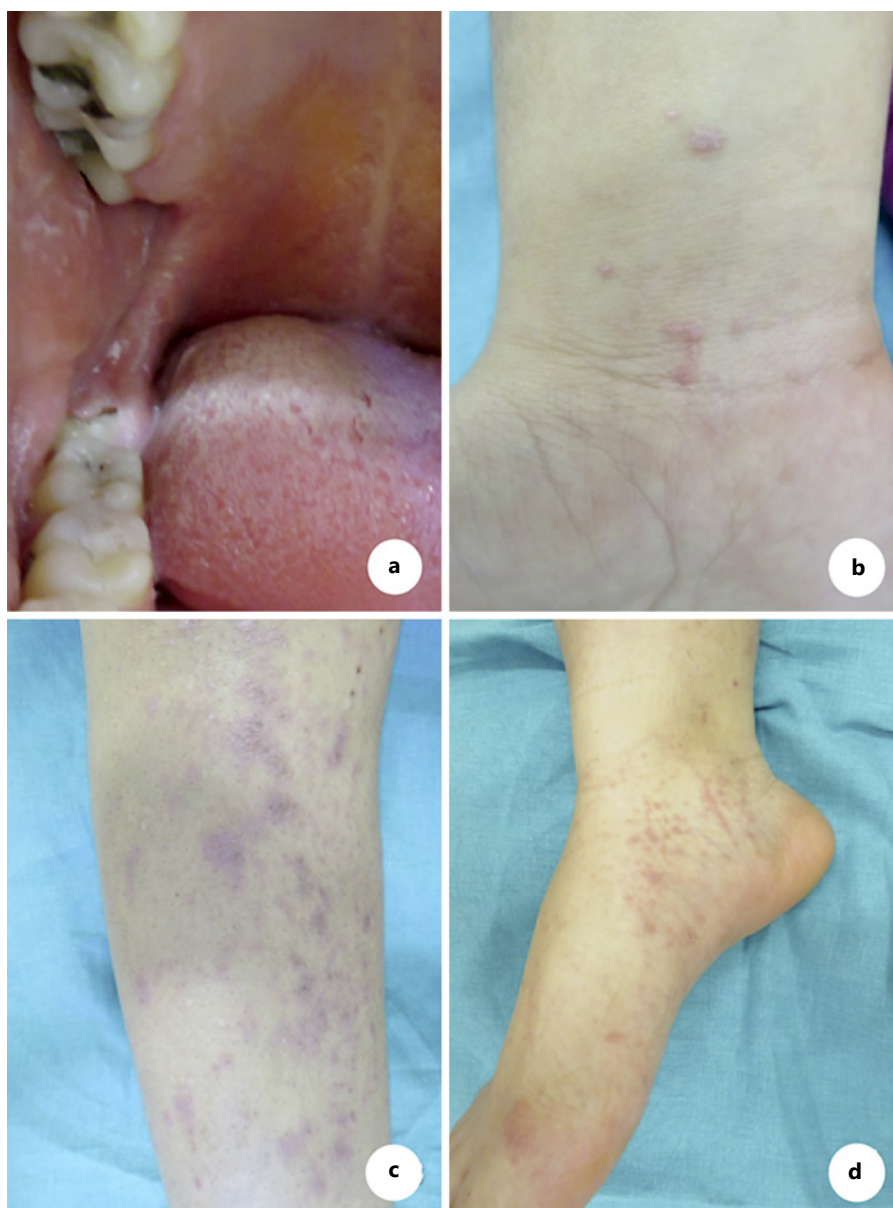


Fig. 1. Lichenoid eruptions after 11 months of dupilumab treatment; **a** oral LP; **b, c** cutaneous eruptions. **d** Köbner phenomenon.

during the administration of dupilumab. In this case, however, there were no findings of mucous lesions [5].

In our case, lichenoid lesions involved both the skin and mucous membranes. The clinical and histopathological findings confirmed LP.

Based on the following observations, we assume a linkage between dupilumab and the occurrence of LP. First, the lichenoid lesions occurred after months of administration of dupilumab. Second, the skin showed marked improvement after withdrawal, leaving light post-inflammatory hyperpigmentation. Third, after 6 months of drug withdrawal, no recurrence of the LP lesions has been observed.

Since lichenoid drug eruptions are described as a TH1-mediated dermatosis [2], we emphasize the hypothesis of a T-cell shift induced by dupilumab, as proposed by Kim et al. [5].

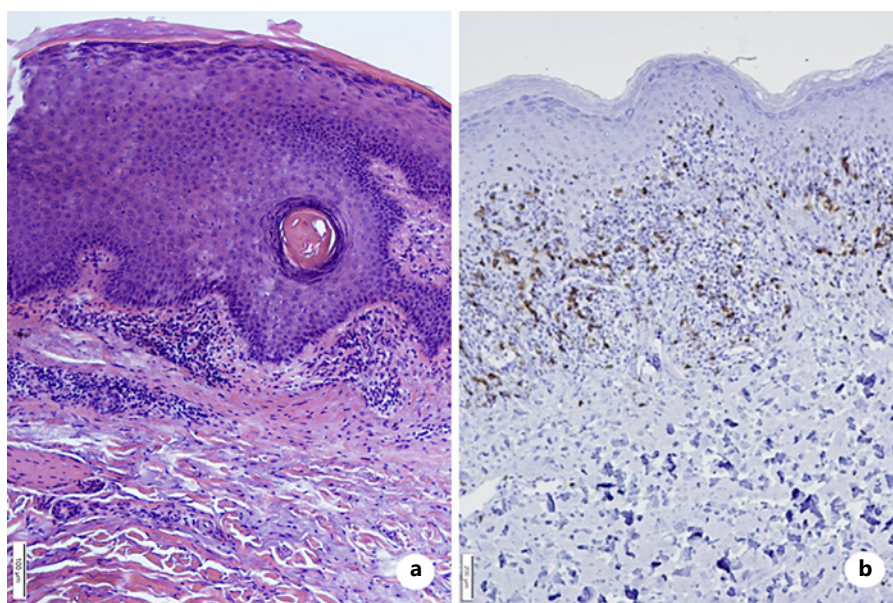


Fig. 2. **a** Hyperkeratosis, acanthosis, and band-like lymphocytic infiltrate in the upper dermis (H&E). **b** CD 8 + accumulation in the dermis and infiltration of single lymphocytes into the epidermis (immunohistochemistry).

Considering that LP lesions developed predominately in non-involved AD areas, it may be assumed that T cells residing in the AD lesions did not shift into TH1 cells. Dupilumab is a humanized IgG4 monoclonal antibody. By targeting the IL-4 receptor alpha chain and by doing so blocking the IL-4/IL-13 signaling pathway, dupilumab has been shown to downregulate TH2 activation [8]. This leads to a TH1/TH2 imbalance, resulting in a TH1-dominated immune response [5].

In case of reoccurrence of moderate-to-severe AD, novel treatment options such as JAK inhibitors may be initiated. These substances inhibit pathways like the IL-6 immune response, resulting in different effects on the inflammatory immune response compared to dupilumab [9].

Reported intervals between the first administration of the drug and the appearance of LP have ranged from several days to years [4]. In our case, the lesions appeared after 11 months.

Treatment of drug-induced LP consists of withdrawal of the offending drug. In extensive or prolonged cases, corticosteroids can be administered (orally: up to 0.5 mg/kg BW) and/or UV phototherapy (narrow-band UVB: 311 nm) [3, 4, 10, 11]. In our case, discontinuation of dupilumab and the administration of oral corticosteroids showed an improvement in the skin and oral lesions, leaving post-inflammatory hyperpigmentation. After 4 months of observation, there has been no recurrence of LP lesions since the withdrawal of dupilumab.

In rare cases, AD can present with nontypical LP-like morphology. A case of hypertrophic LP-like AD has been observed in the past. However, this patient had no involvement of mucous membranes, and histopathological changes were consistent with AD [12]. In contrast, our patient experienced lesions of the oral mucosa, indicating typical LP lesions. The correct distinction between AD and LP is important since LP may be associated with underlying diseases such as viral hepatitis [3].

To the best of our knowledge, this case report is the first appearance of a cutaneous and oral LP in a patient being treated with dupilumab. Although it is a rare occurrence, it further strengthens the hypothesis that dupilumab leads to a TH1-dominated immune response [5].

While further research on this topic is needed, we emphasize the need for clinical examination of lichenoid eruptions in patients undergoing therapy with dupilumab.

Statement of Ethics

Written and informed consent was obtained from the patient for publication of the details of the medical case and accompanying images. Ethical approval is not required for this study in accordance with local or national guidelines.

Conflict of Interest Statement

The authors declare that there is no conflict of interest.

Funding Sources

This article did not receive grants from any funding agency either in the public, commercial, or not-for-profit sectors.

Author Contributions

Laura Kern: investigation and writing of the original draft. Friedrich Breier: reviewing, editing, critical revision, and supervision. Luisa Kleinheinrich: investigation and contribution to the conception of the report. Robert Feldmann and Paul Sator: critical revision and supervision. Alexander Stella: histological examination of the skin biopsy and critical revision. All authors have read and approved the content of the final report.

Data Availability Statement

All data generated or analyzed during this study are included in this article.

References

- 1 Wilson E. *On diseases of the skin: A system of cutaneous medicine*. Seventh American from the 6th and rev. English ed. Philadelphia: H. C. LeaBost Med Surg J.; 1868. p. 808.
- 2 Gorouhi F, Davari P, Fazel N. Cutaneous and mucosal lichen planus: a comprehensive review of clinical subtypes, risk factors, diagnosis, and prognosis. *ScientificWorldJournal*. 2014;2014:742826.
- 3 Ioannides D, Vakirlis E, Kemeny L, Marinovic B, Massone C, Murphy R, et al. European S1 guidelines on the management of lichen planus: a cooperation of the European Dermatology Forum with the European Academy of Dermatology and Venereology. *J Eur Acad Dermatol Venereol*. 2020;34(7):1403–14.
- 4 Ellgehausen P, Elsner P, Burg G. Drug-induced lichen planus. *Clin Dermatol*. 1998;16(3):325–32.
- 5 Kim TE, Shin MK. De novo case of lichenoid eruption following dupilumab treatment. *JAAD Case Rep*. 2021;13:71–2.
- 6 Asarch A, Gottlieb AB, Lee J, Masterpol KS, Scheinman PL, Stadercker MJ, et al. Lichen planus-like eruptions: an emerging side effect of tumor necrosis factor- α antagonists. *J Am Acad Dermatol*. 2009;61(1):104–11.
- 7 Musumeci ML, Lacarrubba F, Micali G. Onset of lichen planus during treatment with etanercept. *Am J Clin Dermatol*. 2010;11(Suppl 1):55–6.
- 8 Seegräber M, Srouf J, Walter A, Knop M, Wollenberg A. Dupilumab for treatment of atopic dermatitis. *Expert Rev Clin Pharmacol*. 2018;11(5):467–74.

- 9 Cotter DG, Schairer D, Eichenfield L. Emerging therapies for atopic dermatitis: JAK inhibitors. [J Am Acad Dermatol](#). 2018;78(3 Suppl 1):S53–S62. Available from:
- 10 Iraj F, Faghihi G, Asilian A, Siadat AH, Larijani FT, Akbari M. Comparison of the narrow band UVB versus systemic corticosteroids in the treatment of lichen planus: a randomized clinical trial. [J Res Med Sci](#). 2011;16(12):1578–82.
- 11 Manousaridis I, Manousaridis K, Peitsch WK, Schneider SW. Individualizing treatment and choice of medication in lichen planus: a step by step approach. [JDDG J der Dtsch Dermatologischen Gesellschaft](#). 2013;11(10):981–91.
- 12 De Castro MEPC, Boufleur K, Souza P, Nociti T, Melo JM, Arruda LK, et al. Hypertrophic lichen planus-like atopic dermatitis: a case report. [World Allergy Organ J](#). 2015;8(Suppl 1):A214.