

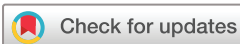Heyde's syndrome: a systematic review of case reports

Bibek Saha ,¹ Eric Wien,^{1,2} Nicholas Fancher,¹ Melissa Kahili-Heede,¹ Nathaniel Enriquez,^{1,2} Alena Velasco-Hughes^{1,3}

To cite: Saha B, Wien E, Fancher N, *et al.* Heyde's syndrome: a systematic review of case reports. *BMJ Open Gastro* 2022;**9**:e000866. doi:10.1136/bmjgast-2021-000866

► Additional supplemental material is published online only. To view, please visit the journal online (<http://dx.doi.org/10.1136/bmjgast-2021-000866>).

Received 20 December 2021
Accepted 27 March 2022



© Author(s) (or their employer(s)) 2022. Re-use permitted under CC BY-NC. No commercial re-use. See rights and permissions. Published by BMJ.

¹John A. Burns School of Medicine, University of Hawai'i at Manoa, Honolulu, Hawaii, USA

²Internal Medicine Residency Program, University of Hawai'i at Manoa, Honolulu, Hawaii, USA

³Queen's Medical Group Hospitalist Program, Queen's Medical Center, Honolulu, Hawaii, USA

Correspondence to

Bibek Saha;
bsaha2@hawaii.edu

ABSTRACT

Objective Heyde's syndrome (HS), a rare condition characterised by a unique relationship between severe aortic stenosis and angiodysplasia, is often diagnosed late increasing the risk for a prolonged hospital course and mortality in the elderly. The leading hypothesis explaining the aetiology of HS is acquired von Willebrand syndrome (AVWS) but not all studies support this claim. While individual cases of HS have been reported, here we present the first systematic review of case reports and focus on the prevalence of AVWS.

Design A systematic search was conducted through PubMed/MEDLINE, CINAHL-EBSCO, Web of Science and Google Scholar since inception. The resulting articles were screened by two independent reviewers based on inclusion criteria that the article must be a case report/series or a letter to the editor in English describing HS in an adult patient.

Results Seventy-four articles encompassing 77 cases met the inclusion criteria. The average age was 74.3±9.3 years old with a slight female predominance. The small intestine, especially the jejunum, was the most common location for bleeding origin. Capsule endoscopy and double balloon enteroscopy were superior at identifying bleeding sources than colonoscopy ($p=0.0027$ and $p=0.0095$, respectively) and oesophagogastroduodenoscopy ($p=0.0006$ and $p=0.0036$, respectively). The mean duration from symptom onset to diagnosis/treatment of HS was 23.8±39 months. Only 27/77 cases provided evidence for AVWS. Surgical and transcatheter aortic valve replacement (AVR) were superior at preventing rebleeding than non-AVR modalities ($p<0.0001$).

Conclusion Further research is warranted for a stronger understanding and increased awareness of HS, which may hasten diagnosis and optimal management.

INTRODUCTION

Diverticular disease and angiodysplasia/arteriovenous malformations (AVMs) are the predominant causes of lower gastrointestinal bleeding (LGIB) in the elderly population.¹ Heyde's syndrome, a rare condition most commonly observed in the elderly, is characterised by a unique relationship between aortic stenosis and gastrointestinal bleeding, where the source of bleeding is characteristically angiodysplasia.² The current leading

Key messages

What is already known on this topic

- ⇒ The leading hypothesis explaining the pathophysiology of Heyde's syndrome (HS) is acquired von Willebrand syndrome (AVWS).
- ⇒ HS is classically associated with severe aortic stenosis.
- ⇒ Angiodysplasia is classically located in the right colon.
- ⇒ The gold-standard treatment for HS is aortic valve replacement.

What this study adds

- ⇒ A majority of cases of HS are diagnosed without providing evidence for AVWS and a minority of cases cannot be explained by AVWS.
- ⇒ HS is possible in the context of moderate aortic stenosis.
- ⇒ Angiodysplasia in HS is predominantly located in the small intestine.
- ⇒ Capsule endoscopy and double balloon enteroscopy (DBE) are superior at identifying bleeding sources in HS than colonoscopy and oesophagogastroduodenoscopy.
- ⇒ Balloon aortic valvuloplasty and endoscopic clipping may be treatment modalities to consider if there are relative/absolute contraindications to aortic valve replacement.

How this study might affect research, practice and/or policy

- ⇒ When conventional diagnostic tools such as oesophagogastroduodenoscopy and colonoscopy are unremarkable in suspected HS, gastroenterologists should follow up with capsule endoscopy, followed by DBE to assess for small bowel angiodysplasia.
- ⇒ Moderate aortic stenosis should not rule out HS.
- ⇒ Laboratory evidence of AVWS should be sought in HS but the absence of AVWS does not rule out the diagnosis.

hypothesis explaining the pathophysiology of Heyde's syndrome is acquired von Willebrand syndrome (AVWS).² Specifically, evidence for the destruction of high molecular weight (HMW) von Willebrand factor (vWF) multimers on gel electrophoresis secondary to shearing by a stenotic aortic

valve resulting in AVWS, and consequent gastrointestinal haemorrhage has been demonstrated in the literature.³ However, there have been cases where no such evidence was found, making this hypothesis somewhat controversial.³ While many cases of Heyde's syndrome have been reported since 1958, when Dr. Heyde first discovered this unique association, no comprehensive systematic review of case reports has been conducted. Here, we present such a systematic review and summarise the epidemiology, risk factors, clinical features, diagnostic workup, including the prevalence of AVWS, and management of Heyde's syndrome as based on reported cases.

METHODS

We enlisted MK-H, an information services and instruction librarian, to conduct an extensive systematic search through major databases including PubMed/MEDLINE, CINAHL-EBSCO, Web of Science (Core Collection, Biological Abstracts, SciELO Citation Index), and Google Scholar since inception, limiting the search to articles in English. The search was performed in June 2021. We built search strategies (online supplemental appendix A) to contain sets of terms reflecting our topic of interest, including Heyde's syndrome, aortic stenosis, gastrointestinal bleeding, angiodysplasia, AVWS and the patient population (adults). Deduplication and screening of articles were undertaken using EndNote reference management software and systematic review tool, Rayyan QCRI.⁴ Specifically, two authors (BS and NF) independently screened all titles and abstracts retrieved in the literature search for relevance. The remaining articles underwent a full-text assessment to determine eligibility for data synthesis based on the inclusion criteria that the article must be in English, be a case report/series or a letter to the editor, but not a review, where the patient must be ≥ 18 years old and present with Heyde's syndrome involving a native aortic valve. Additional information regarding the inclusion and exclusion criteria can be found in online supplemental appendix B. Any disagreements between the two reviewers were mediated by discussion or resolved by a third reviewer (EW).

We collected information regarding study ID (author information and year of publication), population demographics (age and sex), patient comorbidities, severity of the aortic stenosis (modality used for diagnosis, valve area, transvalvular pressure gradients, peak blood velocity across the valve, left ventricular ejection fraction (EF)), characteristics of the gastrointestinal bleed (location, cause of the bleed), diagnostics (modality utilised to identify source of bleed(s), number of modalities used until source was discovered, time from symptom onset to diagnosis/treatment, evidence of AVWS), management (surgical or transcatheter aortic valve replacement (SAVR/TAVR) or another type of therapeutic), and outcomes (improvement of AVWS, recurrence of bleeding) using a standardised data abstraction form.

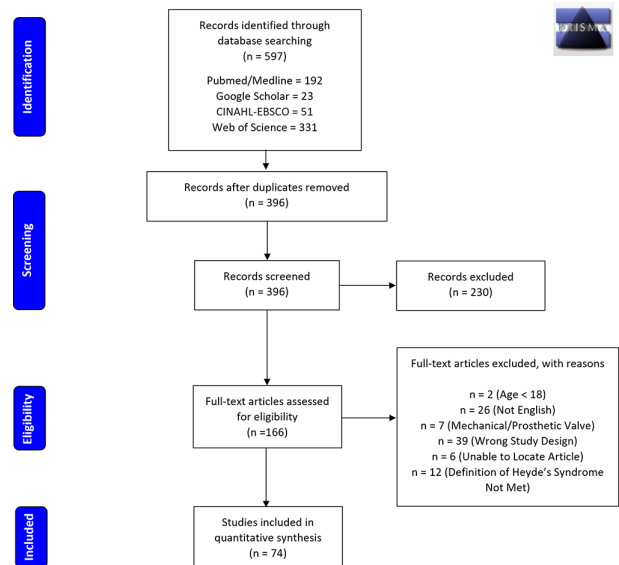


Figure 1 PRISMA flow diagram for search and review strategy. PRISMA, Preferred Reporting Items for Systematic Reviews and Meta-Analyses.

Statistical analysis

Descriptive statistics were calculated to summarise patient characteristics. Specifically, means and SD were calculated for continuous variables whereas percentages and frequencies were calculated for categorical variables. To compare between groups, statistical tests used included two-tailed Student's t-test as well as two-tailed Fisher's exact test. These tests were conducted using Microsoft Excel and GraphPad Prism V.9.2.0. Our results were reported following an adapted version of the Preferred Reporting Items for Systematic Reviews and Meta-Analyses guidelines.

RESULTS

Demographics/risk factors

Our search yielded 597 titles, but only 166 articles were eligible for full-text assessment after deduplication and the screening procedure (figure 1). Ninety-two of these studies did not meet the inclusion criteria (figure 1). The remaining 74 articles encompassed 77 cases used for quantitative synthesis.^{3,5-77} The articles span 35 years, with 68/74 papers being published in 2000 and onwards. The earliest reported case was in 1986 with the most recent being reported in 2021. The average age of patients was 74.3 ± 9.3 years old with the majority being female (56%; table 1). However, the age range spanned 42–93 years old (table 1). There was no significant difference in age between males and females (males: 73.1 ± 8.5 ; females: 75.2 ± 10 ; $p=0.31$; table 1). The most common comorbidity was hypertension (25/77), followed by coronary artery disease (21/77), congestive heart failure (18/77), type 2 diabetes mellitus (12/77), atrial fibrillation (10/77) and chronic kidney disease/end-stage renal disease (10/77; table 1).

Table 1 Demographics and risk factors

	n	%
Sex:		
Male	34	44.2
Female	43	55.8
		Mean±SD
Age, all patients (years)	77	74.3±9.3
Age, males (years)	34	73.1±8.5*
Age, females (years)	43	75.2±10.0*
Aortic valve measurements:		
Area (square cm)	55	0.7±0.3
Peak pressure gradient (mm Hg)	36	93.7±34.0
Mean pressure gradient (mm Hg)	44	56.0±18.6
Peak blood velocity (m/s)	21	4.9±0.8
Severity of valvular disease:		Percentage of total cases (%)
Very severe aortic stenosis (VSAS)†	32	41.6
Severe aortic stenosis (SAS)‡	37	48.1
Moderate aortic stenosis§	3	3.9
Severity not stated	5	6.5
		Percentage of cases by severity (%)
VSAS, males	11	34.4*
VSAS, females	21	65.6*
SAS/moderate, males	21	52.5
SAS/moderate, females	19	47.5
Comorbidities:		Percentage of all comorbidities (%)
Hypertension	25	19.8
Coronary artery disease	21	16.7
Congestive heart failure	18	14.3
Type 2 diabetes mellitus	12	9.5
Atrial fibrillation	10	7.9
Chronic kidney disease	10	7.9
Hyperlipidaemia	8	6.3
History of stroke or TIA	7	5.6
Chronic obstructive pulmonary disease	6	4.8
Obesity	3	2.4
Obstructive sleep apnoea	2	1.6
Primary biliary cholangitis	2	1.6
Thyroid conditions¶	2	1.6

*Within a section, values labelled with a common superscript do not differ ($p>0.05$).

†VSAS defined by valve area $<0.6\text{ cm}^2$, mean aortic pressure gradient $\geq 60\text{ mm Hg}$ and/or peak blood velocity $>5\text{ m/s}$.

‡SAS defined by valve area $<1.0\text{ cm}^2$, mean aortic valve pressure gradient $\geq 40\text{ mm Hg}$ and/or peak blood velocity $>4\text{ m/s}$.

§Moderate aortic stenosis defined by valve area $1\text{--}1.5\text{ cm}^2$, mean aortic valve pressure gradient $20\text{--}40\text{ mm Hg}$ and/or peak blood velocity $3\text{--}4\text{ m/s}$.

¶Includes both hyperthyroidism and hypothyroidism.

TIA, transient ischaemic attack.

Aortic valve characteristics and EF

The average aortic valve area was $0.71\pm 0.31\text{ cm}^2$, with the range being $0.3\text{--}2.4\text{ cm}^2$ (table 1). The average peak and average mean transvalvular pressures across the aortic

valve were $93.7\pm 34\text{ mm Hg}$ and $56\pm 18.6\text{ mm Hg}$, respectively (table 1). The mean peak blood velocity through the aortic valve was $4.9\pm 0.79\text{ m/s}$ (table 1). Sixty-six, thirty and nineteen cases met the criteria for severe aortic

stenosis based on the aortic valve area, mean transvalvular pressure gradient across the valve and peak blood velocity through the aortic valve, respectively. Using these three parameters in conjunction, enough information was available to determine the severity of the stenosis for 72/77 of the cases. Specifically, 3/72 cases demonstrated moderate stenosis, 37/72 cases had severe aortic stenosis and 32/72 cases met the criteria for very severe aortic stenosis (table 1).⁷⁸ Taken together, out of the 77 cases, approximately 90% of patients had confirmed severe/very severe aortic stenosis. There was no significant difference ($p=0.155$) in the incidence of very severe aortic stenosis between males and females (table 1). The mean left ventricular EF was $57.6\pm 14.6\%$ with 33/77 cases and 7/77 cases presenting with preserved and reduced EF, respectively.

Gastrointestinal bleeding characteristics

The cause of the bleeding was almost always some form of angiodysplasia (intestinal vascular ectasia, AVMs, dieulafoy's lesion) or less commonly gastric antral vascular ectasia (GAVE) syndrome, where the source of the bleeding was successfully identified in 85.7% of the cases (table 2). In 62.3% of cases, there was only one source of bleeding, whereas 22% of cases had ≥ 2 sources identified (table 2). In total, there were 90 identified sources of bleeding. Overall, 51 and 31 out of the 90 total sources of bleeding originated from the small intestine and colon, respectively. Specifically, the most common location of bleeding origin was the jejunum (22/90), followed by the duodenum (13/90), ileum (11/90), cecum (10/90) and ascending colon (10/90; table 2).

Diagnostics

A total of 84 procedures/imaging modalities were able to identify and locate these 90 sources of bleeding (table 3). The diagnostic modality that was most frequently able to locate the sources of bleeding was capsule endoscopy (20/84), followed by colonoscopy (16/84), oesophago-gastroduodenoscopy (EGD; 10/84), different imaging techniques (9/84) and double balloon enteroscopy (DBE; 6/84; table 3). While these numbers reflect the definitive identification of the sources of bleeding, the average number of procedures/imaging modalities that were required per case until the source was discovered was 3.5 ± 1.5 , with a range of 1–7 (table 3). That is, there were procedures/imaging modalities that were used initially but were unsuccessful at locating the source of bleeding. The procedures/imaging modalities that failed to identify the source of bleeding the most frequently were colonoscopy (failed 35 times), followed by EGD (failed 31 times), and different imaging techniques (failed 26 times; table 3). In contrast, capsule endoscopy failed a total of 10 times and DBE failed a total of 1 time. Taken together, DBE had the highest detection rate in that it was able to identify the source of bleeding 86% of the time it was used, closely followed by capsule endoscopy (67%; table 3). However, in the six cases where DBE

Table 2 Gastrointestinal bleed characteristics

	n	%
Source of bleeding identified?		
Yes	66	85.7
No	10	13
No of sources of bleeding*		Percent of total cases identified (%)
1	48	62.3
2	12	15.6
3 or more	5	6.5
Source of bleeding location:		
Stomach	7	7.8
Small intestine (unspecified)	5	5.6
Duodenum	13	14.4
Jejunum	22	24.4
Ileum	11	12.2
Small intestine total	51	56.7
Colon (unspecified)	9	10
Cecum	10	11.1
Ascending colon	10	11.1
Transverse colon	1	1.1
Descending colon	1	1.1
Colon total	31	34.4
Rectum	1	1.1
Other sources of bleeding identified†		Percent of other sources identified (%)
Diverticulosis	4	28.6
Gastritis/autoimmune gastritis	4	28.6
Peptic ulcer disease	2	14.3
Bleeding polyp (colonic, gastric)	2	14.3
Other	2	14.3

*Number of distinct gastrointestinal bleeding sources identified per patient.
†Gastrointestinal bleeding sources identified other than angiodysplasia or gastric antral vascular ectasia syndrome.

was able to successfully identify the source of bleeding, capsule endoscopy was performed prior to the procedure. Specifically, in four of six cases, capsule endoscopy was able to identify the source of bleeding prior to DBE. For the remaining two cases, DBE was solely able to identify the source of bleeding. The procedures/modalities with the worst detection rates were EGD (24%) followed by imaging (26%), gastroscopy (27%) and colonoscopy (31%; table 3). Overall, capsule endoscopy had a significantly greater detection rate for the source/location of the bleed when compared with colonoscopy ($p=0.0027$) and EGD ($p=0.0006$; table 3). Similarly, DBE too had a superior ability to detect the source/location of the bleed

Table 3 Diagnostics

	Total attempts	Success rate (%)
Diagnostic modalities (GI bleed)		
Gastroscopy	15	26.7
Capsule endoscopy	30	66.7*
EGD	41	24.4†
Push enteroscopy	3	33.3
DBE	7	85.7*
Endoscopy (unspecified)	11	81.8
Colonoscopy	51	31.4†
Imaging‡	35	25.7
	n	Mean±SD
No of modalities required to identify bleeding source	84	3.5±1.5
	n	Percent of total cases (%)
Evidence of AVWS found§	27	35.1
Evidence of AVWS not found	9	11.7
AVWS not assessed¶	9	11.7
AVWS assessment not stated**	32	41.6

*†Within a section, values labelled with different superscripts differ ($p < 0.05$), however, values labelled with a common superscript were not compared with one another.

‡Includes angiography, scintigraphy, arteriogram, CT enteroclysis, and barium studies.

§81.5% of these diagnoses were based on gel electrophoresis results.

¶Case reports which stated that they did not assess for AVWS.

**Case reports which did not describe whether or not they assessed for AVWS.

AVWS, acquired von Willebrand syndrome; DBE, double balloon enteroscopy; EGD, oesophagogastroduodenoscopy.

when compared with colonoscopy ($p=0.0095$) and EGD ($p=0.0036$; [table 3](#)). While the bleeding in these cases were assumed to be from angiodysplasia/GAVE syndrome, in 14/77 cases there were other possible sources of bleeding identified during diagnostic workup. The most common of these were diverticulosis (4/14) and gastritis/autoimmune gastritis (4/14; [table 2](#)).

The mean duration from symptom onset to the diagnosis or treatment of Heyde's syndrome was 23.8 ± 39 months with the range being 0.25–240 months. In 50/77 cases, there was no explicit evidence of AVWS. Specifically, in 9/77 cases, laboratory studies were unremarkable for AVWS ([table 3](#)). Additionally, in another 9/77 cases, the authors explicitly stated that they did not assess for AVWS ([table 3](#)). Similarly, for the remaining 32/77 cases, the authors did not report conducting any studies to assess for AVWS ([table 3](#)). In the 27/77 cases where there was evidence of AVWS, 22 of these cases reported this finding based on decreased HMW vWF multimers on multimeric analysis via gel electrophoresis ([table 3](#)).

Table 4 Management and outcomes

	Frequency utilised (%)	Success rate in stopping bleeding (%)
Therapeutic procedure for Heyde's syndrome:		
SAVR	49.3	92.1*
TAVR/TAVI	24.7	84.2*
Alternative treatments†	26	45‡
Efficacy of alternative treatments†:	No of times attempted	Success rate in stopping bleeding (%)
Balloon aortic valvuloplasty	3	66.7§
Clipping procedure	7	57.1§
Epinephrine injection	7	42.9
Supportive therapy alone	6	33.3
Argon plasma coagulation	16	25§
Cauterisation/coagulation (unspecified)	9	11.1§
Colon/small bowel resection	7	28.6
Octreotide	4	50
Bentall procedure	1	100
Oestrogen	1	0
Desmopressin or vWF supplementation	2	50
Tranexamic acid	1	0
	n	Percent of AVWS cases (%)
Resolution of AVWS following treatment	16	59.3

*‡§Within a section, values labelled with different superscripts differ ($p < 0.05$), and those with a common superscript do not differ ($p > 0.05$).

†Any treatment not involving valve replacement. AVWS, acquired von Willebrand syndrome; SAVR, surgical aortic valve replacement; TAVR/TAVI, transcatheter aortic valve replacement/implantation; vWF, von Willebrand factor.

Treatment and outcomes

For management, 38/77, 19/77 and 20/77 received SAVR, TAVR and no valve replacement, respectively ([table 4](#)). Out of the 57 people that received SAVR or TAVR, bleeding resolved in 51 patients, reoccurred in 4 patients, and for the remaining 2 patients, the outcome was not stated. Specifically, the bleeding recurrence after SAVR was 5.3%, and 10.5% after TAVR. However, the bleeding

recurrence when the treatment did not involve valve replacement was 50%. Taken together, valve replacement was significantly more effective at preventing rebleeding as compared with alternative treatments ($p < 0.0001$) but with no difference in efficacy between TAVR and SAVR ($p = 0.5899$; [table 4](#)). In 8/51 cases where the bleeding resolved in the SAVR/TAVR group, the bleeding stopped prior to the valve replacement due to another treatment modality. However, in 20/51 cases, while other treatment modalities were attempted, bleeding did not stop until TAVR/SAVR was performed.

Treatments that were attempted prior to TAVR/SAVR included balloon aortic valvuloplasty (BAV), endoscopic clipping, epinephrine injections, supportive therapy alone, argon plasma coagulation (APC), cauterisation/embolisation/coagulation (unspecified), small bowel/colon resection, octreotide and desmopressin/vWF supplementation. BAV and desmopressin/vWF supplementation had the best ability to stop the bleeding when used (1/2) whereas APC and catheterisation/embolisation/coagulation (unspecified) had the worst chances (1/11 and 1/7, respectively) of resolving the bleeding. Similarly, in the group that did not receive valve replacement, treatment options used included BAV, endoscopic clipping, epinephrine injections, supportive therapy alone, APC, cauterisation/embolisation/coagulation (unspecified), small bowel/colon resection, octreotide, Bentall Procedure and oestrogen. In this group, BAV (1/1), clips (2/2), the Bentall procedure (1/1) and octreotide (2/3) had the highest chance of resolving the bleeding when used. In contrast, colon/small bowel resection (1/4) and catheterisation/embolisation/coagulation (0/2) had the lowest ability to stop the bleeding. When the data from the group that underwent TAVR/SAVR is combined with the group that did not undergo valve replacement, with respect to the efficacy of these alternative treatment options in stopping bleeding, supportive therapy alone (33%), colon/small bowel resection (29%), APC (25%) and cauterisation/embolisation/coagulation (11%) had the lowest success rates. In contrast, BAV (67%), endoscopic clipping (57%), octreotide (50%) and epinephrine injections (43%) had the best chances of stopping the bleeding. However, BAV was not significantly superior at preventing bleeding recurrence when compared with APC ($p = 0.2219$) and cauterisation/embolisation/coagulation ($p = 0.1273$). Similarly, clipping was not significantly different from APC ($p = 0.1819$) and cauterisation/embolisation/coagulation ($p = 0.1058$) in preventing the recurrence of gastrointestinal bleeding ([table 4](#)). Following treatment, the AVWS improved in 16 of 27 cases, where the improvement was based on increasing/normalised HMW vWF multimers in 14/16 cases ([table 4](#)).

DISCUSSION

Gastrointestinal bleeding is a common cause of morbidity, mortality and hospital admissions in the

elderly population with an approximate prevalence of 3.1% in the hospital setting.⁷⁹ The most common cause of gastrointestinal bleeding in this population is peptic ulcer disease. Although the incidence of upper gastrointestinal bleeds increases with age, LGIB have a greater than 200-fold increase in incidence from the third to the ninth decade of life where age is also positively correlated with a longer hospital course.⁸⁰ While angiodysplasia are typically small and often clinically irrelevant, they are the second most common cause of LGIB in the elderly and can present with massive or occult gastrointestinal haemorrhage.⁸⁰ This has significant clinical implications, especially in the context of Heyde's syndrome which is rare and, therefore, infrequently considered in the differential diagnosis. This study, to our knowledge, is the first systematic review of case reports focusing on this condition.

While ~92% of the articles were published on or after 2000, it is unlikely that the incidence of Heyde's syndrome has increased this drastically since the late 1900s but rather physicians are becoming more aware of this unique diagnosis. The risk factors for Heyde's syndrome identified in this study include older age, female sex, comorbid conditions including hypertension, coronary artery disease, congestive heart failure, type 2 diabetes mellitus, atrial fibrillation and chronic kidney disease/end-stage renal disease as well as severe/very severe aortic stenosis. Aortic stenosis secondary to calcification typically begins in the sixth decade of life and becomes symptomatic in the seventh or eighth which is in accordance with the mean age of the patients in this study.⁸¹ Similarly, the majority of cases involved females which was expected based on previous literature and given that females have a higher life expectancy and therefore are more likely to develop aortic stenosis that is severe.⁸² However, unlike previously reported,⁸² the average age in our review did not differ significantly between males and females but did show a trend of females being slightly older. This discrepancy may have been due to the small sample size of our study decreasing the power to detect a difference. Hypertension, coronary artery disease and congestive heart failure were the most common comorbidities of Heyde's syndrome which is not surprising given that these conditions are frequently associated with both aortic stenosis and older age. Similarly, 13% of patients also had chronic kidney disease/end-stage renal disease which is in agreement with previous studies that demonstrated a relationship between angiodysplasia and chronic renal failure.⁸² To our surprise, while ~90% of patients had severe/very severe aortic stenosis, 3.9% of patients with Heyde's syndrome had moderate aortic stenosis suggesting that Heyde's syndrome, as a cause of gastrointestinal bleeding, should not be completely ruled out in this setting. Although we expected a more severe degree of aortic stenosis in females, while there was a trend suggesting a higher incidence of VSAS in females, there was no significant difference. This however can be explained by the fact that there was no significant

difference in age between males and females in our study and also by the limited sample size.

While the majority of the cases (62.3%) involved only one site of bleeding, there was a considerable proportion of cases (22%) where there were 2–5 different locations that were involved. This is important to be aware of when performing diagnostic procedures and suggests that a thorough investigation may be warranted to rule out multiple sites of bleeding. With respect to location, the literature on isolated angiodysplasia has shown that these vascular malformations are most commonly found in the cecum and ascending colon.⁸³ However, in our study of Heyde's syndrome, the angiodysplasia were most frequently identified in the three components of the small intestine with the jejunum being the most common location overall. This has multiple implications. First, this data may suggest that the most common locations for the formation of isolated angiodysplasia and the angiodysplasia seen in Heyde's syndrome may differ. Additionally, it also suggests that in Heyde's syndrome, the small bowel, especially the hard-to-reach places such as the distal duodenum, jejunum and proximal ileum should be examined. In accordance with the above, while colonoscopy and EGD were the most commonly used diagnostic procedures to workup the gastrointestinal bleed, they had two of the worst detection rates. In contrast, DBE and capsule endoscopy, both of which can examine the entire small intestine, had the best detection rates and were superior to EGD and colonoscopy with respect to the identification of the location of the gastrointestinal bleed. Taken together, given that the average number of diagnostic procedures/imaging modalities that were required per case until the source of bleeding was discovered was 3.5 ± 1.5 , we strongly recommend utilising capsule endoscopy followed by DBE when there is gastrointestinal bleeding in the setting of suspected Heyde's syndrome (online supplemental figure 1), especially if other modalities such as EGD and colonoscopy have failed to find a source. While DBE can be both diagnostic as well as therapeutic, we recommend using capsule endoscopy first given that DBE is more invasive, more time-consuming for the gastroenterologist, and requires a highly skilled operator. However, capsule endoscopy should be followed up with DBE for therapeutic purposes and especially if the source of bleeding remains unidentified.

In our study, the average duration from symptom onset to the diagnosis and/or treatment of Heyde's syndrome was extremely variable and delayed. This, however, is not unexpected given that Heyde's syndrome is rare and unknown to many. Additionally, the poor detection rate of the most commonly used diagnostic procedures/imaging modalities for the gastrointestinal bleeds may have been contributory. To our surprise, while the literature details AVWS related to shear stress as the main hypothesis to explain the pathophysiology of Heyde's syndrome,² in ~65% of cases, there was no explicit evidence of AVWS. Specifically, in ~11.7% of cases, the authors conducted laboratory studies to assess for AVWS

but found no such evidence. This suggests that there is at least a minority of patients with Heyde's syndrome where the pathophysiology cannot be explained by AVWS alone. Therefore, other hypotheses of the pathophysiology of Heyde's syndrome should be considered in such situations. Such alternative explanations include connective tissue abnormalities predisposing for both aortic stenosis and angiodysplasia, hypoxia-induced fixed vasodilation secondary to the decreased cardiac output resulting in angiodysplasia, and mucosal hypoxia secondary to cholesterol emboli from the stenotic aortic valve causing the formation of angiodysplasia.⁸⁴ Additionally, in the remaining ~53.2% of cases, the researchers either explicitly or implicitly stated that they did not assess for AVWS. This was largely unexpected given that in the current literature, AVWS is strongly advocated as the connection between the aortic stenosis and gastrointestinal bleeding seen in Heyde's syndrome.² While we are not refuting this argument and do believe it is the primary mechanism, our study indicates that a majority of cases diagnosed Heyde's syndrome without providing evidence for this leading hypothesis. We strongly recommend that future studies provide evidence of AVWS, instead of making this assumption, as this will allow us to have a more accurate understanding of the prevalence of AVWS in Heyde's syndrome. Similarly, this will allow us to have better insight into the percentage of Heyde's syndrome cases that may be better explained by alternative hypotheses. Lastly, of the cases that provided evidence of AVWS, 18.5% did not provide this evidence based on gel electrophoresis, which is the gold standard. We recommend assessing for AVWS with only gel electrophoresis if feasible, given that other modalities are less specific for the condition.³³ Finally, AVWS improved or resolved in the majority of cases after treatment which is in accordance with the literature.⁸⁵

As expected, based on the literature,⁸⁴ SAVR/TAVR were significantly more effective in preventing bleeding recurrence when compared with alternative treatments that did not involve aortic valve replacement. However, there was no significant difference with respect to bleeding recurrence between SAVR and TAVR suggesting that the type of valve replacement should be chosen in the context of the patient's comorbidities where TAVR may be favourable if the patient is a poor surgical candidate. Indeed, TAVR was selected over SAVR in multiple case reports included in this study due to high surgical risk.^{6 48 61} However, based on our results, if the patient is at high risk of severe bleeding from dual antiplatelet therapy that is commonly administered after TAVR or there are contraindications to TAVR in this setting, we recommend BAV, endoscopic clipping, octreotide and epinephrine injections either alone or in combination as alternatives to have the best chance of stopping the gastrointestinal bleeding. In contrast, we recommend against supportive therapy alone, colon/small bowel resection, APC and cauterisation/



embolisation/coagulation given their poor ability to stop bleeding recurrence. This has substantial implications given APC, cautery and electrocoagulation are currently commonly used to treat angiodysplasia.⁸⁶ While we did not reach statistical significance when comparing BAV to APC and cauterisation/embolisation/coagulation as well clipping to APC and cauterisation/embolisation/coagulation with respect to the ability to stop gastrointestinal bleeds in the context of Heyde's syndrome, this was most likely due to our small sample size. This suggests that prospective studies on these alternative treatments for Heyde's syndrome may be warranted.

Our study had several limitations. First was the somewhat vague reporting of the timeline in case reports. However, we made our best attempts to accurately approximate the duration from symptom onset to diagnosis/treatment of Heyde's syndrome. Additionally, given the lack of systematic reporting with respect to the assessment of AVWS, we were unable to uncover and make conclusions regarding the true prevalence of AVWS in Heyde's syndrome. Furthermore, while unlikely, it is important to consider the possibility of publication bias whereby cases that involved obscure sites of bleeding were only reported in the literature. However, based on our assessment, the main purpose of reporting these cases appeared to be to highlight the condition of Heyde's syndrome in general irrespective of whether the bleeding sites were obscure or not. This is supported by the evidence that the angiodysplasia among the reported cases were discovered throughout the gastrointestinal tract. Lastly, we excluded articles in foreign languages as well as conference abstracts which may have provided additional information on this rare condition. Nevertheless, our study has numerous strengths. First, we performed a systematic review of the English literature using multiple reputable databases with the assistance of a professional librarian and provided an overview of the epidemiology, risk factors, pathophysiology, diagnostic characteristics, management and outcomes of a rare condition that would be otherwise difficult to study in isolation or at a single centre. Additionally, we involved multiple reviewers and utilised a standard abstraction form to limit bias.

In summary, we present a systematic review of case reports on Heyde's syndrome. While awareness of this rare condition is increasing, the diagnosis is often challenging and delayed which may increase the risk of a longer hospital course and mortality. Heyde's syndrome should be considered in the context of gastrointestinal bleeding in the elderly who have severe aortic valve stenosis, but a moderate degree of stenosis should not rule out the condition. Similarly, laboratory evidence of AVWS should be sought but the absence of AVWS does not rule out the diagnosis of Heyde's syndrome. Gastroenterologists should have a high degree of suspicion of Heyde's syndrome in the elderly when conventional diagnostic tools such as EGD and colonoscopy are unremarkable and should follow-up with capsule endoscopy and subsequent

DBE to assess for small bowel angiodysplasia. Gold-standard treatments involve TAVR and SAVR but if contraindications are present or if there is a high risk of severe bleeding with antiplatelet therapy, alternative treatment strategies such as BAV and endoscopic clipping can be considered. However, prospective studies are warranted to assess the efficacy of these other methods on preventing bleeding recurrence in Heyde's syndrome. Similarly, more research on the alternative hypotheses of the pathophysiology of Heyde's syndrome is necessary given not all cases can be explained by AVWS. Taken together, further research is crucial to allow for a stronger understanding and increased awareness of Heyde's syndrome, which may permit more timely diagnosis and optimal management improving patient outcomes.

Acknowledgements We would like to thank the John A. Burns School of Medicine as well as the University of Hawaii Internal Medicine Residency Program.

Contributors All authors have contributed to and taken the time to ensure the integrity of the work and approve the final manuscript. BS and AV-H are the guarantors for this study. Specific contributions of each author can be found below. Study conceptualisation and design: BS, EW and AV-H. Systematic literature search: BS, NF, MK-H and EW. Acquisition, analysis or interpretation of data: all the authors. Drafting of the manuscript: BS, NF, EW and AV-H. Critical revision of the manuscript for important intellectual content: all the authors. Statistical analysis: BS. Administrative, technical or material support: MK-H, BS and AV-H. Study supervision: EW and AV-H.

Funding The authors have not declared a specific grant for this research from any funding agency in the public, commercial or not-for-profit sectors.

Competing interests None declared.

Patient consent for publication Not applicable.

Provenance and peer review Not commissioned; externally peer reviewed.

Data availability statement All data relevant to the study are included in the article or uploaded as online supplemental information.

Supplemental material This content has been supplied by the author(s). It has not been vetted by BMJ Publishing Group Limited (BMJ) and may not have been peer-reviewed. Any opinions or recommendations discussed are solely those of the author(s) and are not endorsed by BMJ. BMJ disclaims all liability and responsibility arising from any reliance placed on the content. Where the content includes any translated material, BMJ does not warrant the accuracy and reliability of the translations (including but not limited to local regulations, clinical guidelines, terminology, drug names and drug dosages), and is not responsible for any error and/or omissions arising from translation and adaptation or otherwise.

Open access This is an open access article distributed in accordance with the Creative Commons Attribution Non Commercial (CC BY-NC 4.0) license, which permits others to distribute, remix, adapt, build upon this work non-commercially, and license their derivative works on different terms, provided the original work is properly cited, appropriate credit is given, any changes made indicated, and the use is non-commercial. See: <http://creativecommons.org/licenses/by-nc/4.0/>.

ORCID iD

Bibek Saha <http://orcid.org/0000-0002-1976-126X>

REFERENCES

- 1 Chait MM. Lower gastrointestinal bleeding in the elderly. *World J Gastrointest Endosc* 2010;2:147–54.
- 2 Loscalzo J. From clinical observation to mechanism--Heyde's syndrome. *N Engl J Med* 2012;367:1954–6.
- 3 Duarte-Chavez R, Fegley MW, Stone LE. Heyde/Heyde-Warkentin syndrome: a case report and literature review. *International Journal of Academic Medicine* 2016;2:243–8.
- 4 Ouzzani M, Hammady H, Fedorowicz Z, et al. Rayyan-a web and mobile APP for systematic reviews. *Syst Rev* 2016;5:210.

- 5 Abi-Akar R, El-Rassi I, Karam N, *et al.* Treatment of Heyde's syndrome by aortic valve replacement. *Curr Cardiol Rev* 2011;7:47–9.
- 6 Ahmed T, Haque R. Heyde's syndrome complicating management in a patient with high bleeding and thrombotic risks. *Cureus* 2020;12:e8280.
- 7 Akutagawa T, Shindo T, Yamanouchi K, *et al.* Persistent gastrointestinal angiodysplasia in Heyde's syndrome after aortic valve replacement. *Intern Med* 2017;56:2431–3.
- 8 Alshuwaykh O, Krier MJ. A case of Heyde syndrome with resolution of gastrointestinal bleeding two weeks after aortic valve replacement. *Am J Case Rep* 2018;19:924–6.
- 9 Amaral LTW, Manguiera CLP, Silva MMdeA, *et al.* Gastrointestinal bleeding and aortic stenosis: a case of Heyde syndrome. *Radiol Cardiothorac Imaging* 2021;3:e200615.
- 10 Balbo CP, Seabra LP, Galoro VG, *et al.* Heyde's syndrome and transcatheter aortic valve implantation. *Arq Bras Cardiol* 2017;108:378–80.
- 11 Benton SM, Kumar A, Crenshaw M, *et al.* Effect of transcatheter aortic valve implantation on the Heyde's syndrome. *Am J Cardiol* 2014;114:953–4.
- 12 Bhutani MS, Gopalswamy N, Gupta SC. Heyde's syndrome: the controversy continues. *Am J Gastroenterol* 1994;89:954.
- 13 Capuano F, Angeloni E, Roscitano A, *et al.* Blackish pigmentation of the aorta in patient with alkaptonuria and Heyde's syndrome. *Aorta* 2014;2:74–6.
- 14 Casson AG, McKenzie NN. Heyde's syndrome. *Chest* 1988;94:891–2.
- 15 Chukwudum CA, Vera S, Sharma M, *et al.* Heyde syndrome: a case report and literature review. *Cureus* 2020;12:e7896.
- 16 D'Souza PM, Blostein MD. Diagnosis of Heyde's syndrome by abnormal closure times despite normal von Willebrand's activity. *Blood Coagul Fibrinolysis* 2011;22:622–3.
- 17 Dahiya DS, Kichloo A, Zain E-A, *et al.* Heyde syndrome: an unusual cause of gastrointestinal bleeding. *J Investig Med High Impact Case Rep* 2021;9:2324709621997279.
- 18 Dall'Ara G, Grotti S, Conficoni E, *et al.* Early resolution of Heyde's syndrome following transcatheter aortic valve replacement. *Semin Thromb Hemost* 2021;47:102–4.
- 19 Dos Santos VM, Dos Santos LAM, Modesto AAD, *et al.* Heyde syndrome in a 71-year-old man who underwent chest radiotherapy at young age. *An Sist Sanit Navar* 2013;36:339–45.
- 20 Dosi RV, Ambaliya AP, Patell ND, *et al.* Gastric antral vascular ectasia with aortic stenosis: Heyde's syndrome. *Indian J Med Sci* 2012;66:86–9.
- 21 Famularo G, Gasbarrone L, Minisola G. Octreotide for Heyde's syndrome: a case report. *Presse Med* 2014;43:1281–3.
- 22 Figuinha FCR, Spina GS, Tarasoutchi F. Heyde's syndrome: case report and literature review. *Arq Bras Cardiol* 2011;96:e42–5.
- 23 Floudas CS, Moyssakis I, Pappas P, *et al.* Obscure gastrointestinal bleeding and calcific aortic stenosis (Heyde's syndrome). *Int J Cardiol* 2008;127:292–4.
- 24 Fukuhara K, Kondo T, Miyoshi H, *et al.* Rotational thromboelastometry-guided perioperative management of coagulation in a patient with Heyde's syndrome undergoing transcatheter aortic valve implantation. *JA Clin Rep* 2019;5:3.
- 25 Gandhi V, Philip S, Nagral S. Heyde syndrome. *Trop Gastroenterol* 2010;31:120–1.
- 26 Garcia LR, Garzesi AM, Tripoli G, *et al.* Heyde syndrome treated by conventional aortic valve replacement. *Braz J Cardiovasc Surg* 2019;34:630–2.
- 27 García-Martín A, Moreno A, Moro C. Heyde's Syndrome. *Revista Española de Cardiología (English Edition)*. 2011; 64, 75–7.
- 28 Giovannini I, Chiarla C, Murazio M, *et al.* An extreme case of Heyde syndrome. *Dig Surg* 2006;23:387–8.
- 29 Giusti de Marle M, Sgreccia A, Carmenini E, *et al.* Infective endocarditis from *Enterococcus faecalis* complicating colonoscopy in Heyde's syndrome. *Postgrad Med J* 2004;80:619–20.
- 30 Godinho AR, Amorim S, Campelo M, *et al.* Severe aortic stenosis: forgotten associations. *Rev Port Cardiol* 2014;33:563.e1–563.e4.
- 31 Godino C, Pavon AG, Mangieri A, *et al.* Aortic valvuloplasty as bridging for TAVI in high-risk patients with Heyde's syndrome: a case report. *Case Rep Med* 2012;2012:946764.
- 32 Gökaslan G, Eren NT. Starr-Edwards caged ball valve pursuing to astonish us-38 years in mitral position. *Anadolu Kardiyol Derg* 2012;12:690–1.
- 33 Hudzik B, Wilczek K, Gasior M. Heyde syndrome: gastrointestinal bleeding and aortic stenosis. *CMAJ* 2016;188:135–8.
- 34 Hui YT, Lam WM, Fong NMS, *et al.* Heyde's syndrome: diagnosis and management by the novel single-balloon enteroscopy. *Hong Kong Med J* 2009;15:301–3.
- 35 Iijima M, Itoh N, Murase R, *et al.* A surgical case of aortic stenosis with recurrent gastrointestinal bleeding: Heyde syndrome. *Int J Surg Case Rep* 2018;53:281–4.
- 36 İlkeli E, Albeyoğlu Şebnem, Çiloğlu U, *et al.* Heyde's syndrome. *Asian Cardiovasc Thorac Ann* 2014;22:592–4.
- 37 Islam S, Islam E, Cevik C, *et al.* Aortic stenosis and angiodysplastic gastrointestinal bleeding: Heyde's disease. *Heart Lung* 2012;41:90–4.
- 38 Kapila A, Chhabra L, Khanna A. Valvular aortic stenosis causing angiodysplasia and acquired von Willebrand's disease: Heyde's syndrome. *BMJ Case Rep* 2014;2014:bcr2013201890.
- 39 Khazi FM, Siddiqi NR, Karaly YM, *et al.* Heyde's Syndrome - An Enigma. *J Saudi Heart Assoc* 2021;33:95–100.
- 40 Konstantinos K, Vogiatzis I. Heyde sendromu: ağır aort stenozu ile anemi arasındaki ilişki. *Cukurova Medical Journal* 2016;41:825–6.
- 41 Ledingham D. Heyde's syndrome: exploring the link between aortic stenosis and an acquired bleeding disorder. *BMJ Case Rep* 2013;2013:bcr2013009306.
- 42 Leibovitz E, Harpaz D, Elly I, *et al.* Persistent anemia in otherwise asymptomatic severe aortic stenosis: a possible indication for valve replacement? *Isr Med Assoc J* 2004;6:400–2.
- 43 Magro VM. An unclear anemia in an elderly subject with aortic stenosis. *Electronic Journal of General Medicine* 2015;12:170–3.
- 44 Mahboobi SK. Heyde's syndrome and postoperative bleeding after aortic valve replacement - Is there a role for prophylactic desmopressin? *J Clin Anesth* 2019;56:142.
- 45 Maor NR. Heyde syndrome: resolution of anemia after aortic valve surgery. *Isr Med Assoc J* 2013;15:387–9.
- 46 Martínez-Caselles A, Martínez-Pascual C, Sánchez-Torres A, *et al.* Beyond Heyde's syndrome. *Rev Esp Enferm Dig* 2012;104:615–6.
- 47 Milla M, Hernández E, Mérida E. Heyde syndrome: correction of anaemia after aortic valve replacement in a hemodialysis patient. *Nefrología* 2018;38:327–9.
- 48 Mirna M, Lichtenauer M, Theurl T, *et al.* Transcatheter aortic valve implantation in a patient with suspected hereditary von Willebrand disease and severe gastrointestinal bleeding - a case report. *Scott Med J* 2019;64:142–7.
- 49 Morishima A, Marui A, Shimamoto T, *et al.* Successful aortic valve replacement for Heyde syndrome with confirmed hematologic recovery. *Ann Thorac Surg* 2007;83:287–8.
- 50 Michot J-M, Treton X, Brink C, *et al.* Severe gastro-intestinal angiodysplasia in context of Heyde's syndrome durably cured after aortic valve replacement. *Presse Med* 2012;41:763–6.
- 51 Natowitz L, Defraigne JO, Limet R. Association of aortic stenosis and gastrointestinal bleeding (Heyde's syndrome). Report of two cases. *Acta Chir Belg* 1993;93:31–3.
- 52 Negi SI, Xu R, Anand A. Medical image. A murmur and a bleed: the Heyde syndrome. *N Z Med J* 2013;126:95–7.
- 53 Noor A, Abadco D. Heyde syndrome complicated by a Dieulafoy lesion. *Ochsner J* 2020;20:326–30.
- 54 Obeidat AE, Kim J. Recurrent gastrointestinal bleeding in a patient with severe aortic valve stenosis: a diagnosis of Heyde's syndrome. *Cureus* 2021;13:e15442.
- 55 Ogano M, Iwasaki Y-ki, Takano H, *et al.* Successful colectomy for the treatment of repetitive bleeding from colonic angiodysplasia in a patient with Heyde syndrome. *Intern Med* 2006;45:355–8.
- 56 Ohta S, Watanabe T, Morita S, *et al.* Massive jejunal bleeding due to Heyde syndrome successfully treated with double balloon endoscopy. *Clin J Gastroenterol* 2009;2:187–9.
- 57 Olearchyk AS. Heyde's syndrome. *J Thorac Cardiovasc Surg* 1992;103:823–4.
- 58 Olearchyk AS. Lactobacillus endocarditis necessitating combined mitral and aortic valve Replacement—A case report. *Vasc Surg* 1993;27:219–25.
- 59 Pires P, Costa I, Raposo A. You Can't Heyde Forever. *Eur J Case Rep Intern Med* 2018;5:000896.
- 60 Pozzi M, Hanss M, Petrosyan A, *et al.* Resolution of acquired von Willebrand syndrome after transcatheter aortic valve implantation through a left transcarotid approach. *Int J Cardiol* 2014;176:1350–1.
- 61 Pyxaras SA, Santangelo S, Perkan A, *et al.* Reversal of angiodysplasia-derived anemia after transcatheter aortic valve implantation. *J Cardiol Cases* 2012;5:e128–31.
- 62 Ramachandran R, Uqdah H, Jani N. A case of recurrent obscure gastrointestinal bleeding: Heyde's syndrome - case report and review. *J Community Hosp Intern Med Perspect* 2018;8:127–9.
- 63 Rashid S, Malkin C, Schlosshan D, *et al.* Severe aortic stenosis, critical coronary artery disease, and transfusion-dependent angiodysplasia - A management conundrum. *J Cardiol Cases* 2016;13:87–9.
- 64 Undas A, Windyga J, Bykowska K, *et al.* Heyde's syndrome without a decrease in large von Willebrand factor multimers: a case of intestinal bleedings reversed by valve replacement in a patient with aortic stenosis. *Thromb Haemost* 2009;101:773–4.



- 65 Scheffer SM, Leatherman LL. Resolution of Heyde's syndrome of aortic stenosis and gastrointestinal bleeding after aortic valve replacement. *Ann Thorac Surg* 1986;42:477–80.
- 66 Schmid W, Steindl-Munda P, Petra S-M, et al. Estimation of platelet function under high shear conditions to assist a rapid diagnosis of Heyde syndrome. *Platelets* 2008;19:636–40.
- 67 Schwaiger JP, Ludwiczek O, Graziadei I, et al. A vicious circle: Heyde syndrome in mild aortic stenosis. *CASE* 2019;3:171–6.
- 68 Shibamoto A, Kawaratani H, Kubo T, et al. Aortic valve replacement for the management of Heyde syndrome: a case report. *J Nippon Med Sch* 2017;84:193–7.
- 69 Sinha S, Castro D, Shakil S. Medical management of Heyde syndrome. *Cureus* 2021;13:e12551.
- 70 Taguchi T, Watanabe M, Watadani K, et al. A case of Heyde syndrome: resolution following aortic valve replacement. *Heart Surg Forum* 2014;17:E258–60.
- 71 Takahashi N, Tanabe K, Yoshitomi H, et al. Successful endoscopic clipping for bleeding from colonic angiodysplasia in a case of Heyde syndrome. *Med Sci Monit* 2010;16:Cs107–9.
- 72 Tariq MM, Ullah I, Khan MB. Heyde syndrome: a case report and review of literature. *The Stetho* 2020;1.
- 73 Testi W, Coratti F, Staffieri C, et al. Cryptogenetic intestinal angiodysplasia and elderly aortic stenosis: Heyde's syndrome? A case report. *Chir Ital* 2009;61:497–501.
- 74 Tsuchiya S, Matsumoto Y, Doman T, et al. Disappearance of angiodysplasia following transcatheter aortic valve implantation in a patient with Heyde's syndrome: a case report and review of the literature. *J Atheroscler Thromb* 2020;27:271–7.
- 75 Uchida T, Hamasaki A, Ohba E, et al. Life-Threatening subdural hematoma after aortic valve replacement in a patient with Heyde syndrome: a case report. *J Cardiothorac Surg* 2017;12:65.
- 76 Valle FH, Júnior FP, Bergoli LCC. Gastrointestinal Bleeding due to Angiodysplasia in a Patient with Severe Aortic Stenosis: Heyde's Syndrome. *Revista Brasileira de Cardiologia Invasiva* 2013;21:288–90.
- 77 Warkentin TE, Moore JC, Morgan DG. Gastrointestinal angiodysplasia and aortic stenosis. *N Engl J Med Overseas Ed* 2002;347:858–9.
- 78 Tribouilloy C, Rusinaru D, Bohbot Y, et al. How should very severe aortic stenosis be defined in asymptomatic individuals? *J Am Heart Assoc* 2019;8:e011724.
- 79 Lenti MV, Pasina L, Cococcia S, et al. Mortality rate and risk factors for gastrointestinal bleeding in elderly patients. *Eur J Intern Med* 2019;61:54–61.
- 80 Yachimski PS, Friedman LS. Gastrointestinal bleeding in the elderly. *Nat Clin Pract Gastroenterol Hepatol* 2008;5:80–93.
- 81 Toyofuku M, Taniguchi T, Morimoto T, et al. Sex Differences in Severe Aortic Stenosis - Clinical Presentation and Mortality. *Circ J* 2017;81:1213–21.
- 82 Chalasani N, Cotsonis G, Wilcox CM. Upper gastrointestinal bleeding in patients with chronic renal failure: role of vascular ectasia. *Am J Gastroenterol* 1996;91:2329–32.
- 83 Sami SS, Al-Araji SA, Ragnunath K. Review article: gastrointestinal angiodysplasia - pathogenesis, diagnosis and management. *Aliment Pharmacol Ther* 2014;39:15–34.
- 84 Massyn MW, Khan SA. Heyde syndrome: a common diagnosis in older patients with severe aortic stenosis. *Age Ageing* 2009;38:267–70.
- 85 Vincentelli A, Susen S, Le Tourneau T, et al. Acquired von Willebrand syndrome in aortic stenosis. *N Engl J Med Overseas Ed* 2003;349:343–9.
- 86 Saltzman JR. Angiodysplasia of the gastrointestinal tract. In: Friedman LS, Travis AC, eds. *UpToDate*. Waltham, MA, 2021.