

# Presigmoid Transpetrosal Approach for Superficial Temporal Artery to Distal Posterior Cerebral Artery Bypass and Trapping of Aneurysm

Gregory P. Lekovic, MD,

PhD \*

Yinn Cher Ooi, MD<sup>†</sup>

Reza Jahan, MD<sup>‡</sup>

\*Division of Neurosurgery, House Institute, Los Angeles, California; <sup>†</sup>Department of Neurosurgery, University of California, Los Angeles, Los Angeles, California; <sup>‡</sup>Department of Radiology, University of California, Los Angeles, Los Angeles, California

## Correspondence:

Gregory P. Lekovic, MD, PhD,  
Division of Neurosurgery,  
House Institute,  
2100 W Third St,  
Los Angeles, CA 90057, USA.  
Email: [glekovic@houseclinic.com](mailto:glekovic@houseclinic.com)

Received, May 9, 2020.

Accepted, September 27, 2020.

Published Online, January 12, 2021.

© Congress of Neurological Surgeons 2021.

This is an Open Access article distributed under the terms of the Creative Commons Attribution-NonCommercial-NoDerivs licence (<http://creativecommons.org/licenses/by-nc-nd/4.0/>), which permits non-commercial reproduction and distribution of the work, in any medium, provided the original work is not altered or transformed in any way, and that the work is properly cited. For commercial re-use, please contact [journals.permissions@oup.com](mailto:journals.permissions@oup.com)

**BACKGROUND AND IMPORTANCE:** Aneurysms of the posterior cerebral artery (PCA) are uncommon, estimated at less than 1% of all cerebral aneurysms, and less than half occur distal to the P1/2 junction. Unfortunately, the conventional bypass approach for PCA aneurysms—primarily occipital artery to distal PCA cortical branches—has a history of unsatisfying results.

**CLINICAL PRESENTATION:** A 42-yr-old female presented with Fisher 3 Hunt-Hess 2 subarachnoid hemorrhage secondary to ruptured distal PCA aneurysm. She was initially evaluated by the endovascular service, but due to recent subarachnoid hemorrhage, endovascular treatment with flow diversion and/or vessel sacrifice was felt to be relatively contraindicated and the patient was referred for surgical evaluation for possible bypass. The patient subsequently underwent surgery for trapping of aneurysm and concomitant superficial artery to distal PCA bypass.

**CONCLUSION:** A novel approach for the treatment of a ruptured distal PCA aneurysm is described, consisting of posterior transpetrosal exposure and division of the tentorium with superficial temporal artery to P3 bypass.

**KEY WORDS:** Extracranial-intracranial artery bypass, Posterior cerebral artery aneurysm, Subarachnoid hemorrhage, Superficial temporal artery

*Operative Neurosurgery* 20:E234–E238, 2021

DOI: 10.1093/ons/opaa424

**D**istal aneurysms of the posterior cerebral artery (PCA) are rare lesions. Conventional approaches to these aneurysms include open or endovascular vessel sacrifice, with or without revascularization. Occipital artery (OA) to distal PCA bypass is a technically difficult operation with a relatively low rate of success. A new approach to these aneurysms is described consisting of presigmoid transpetrosal exposure and superficial temporal artery (STA) to distal (PCA) bypass.

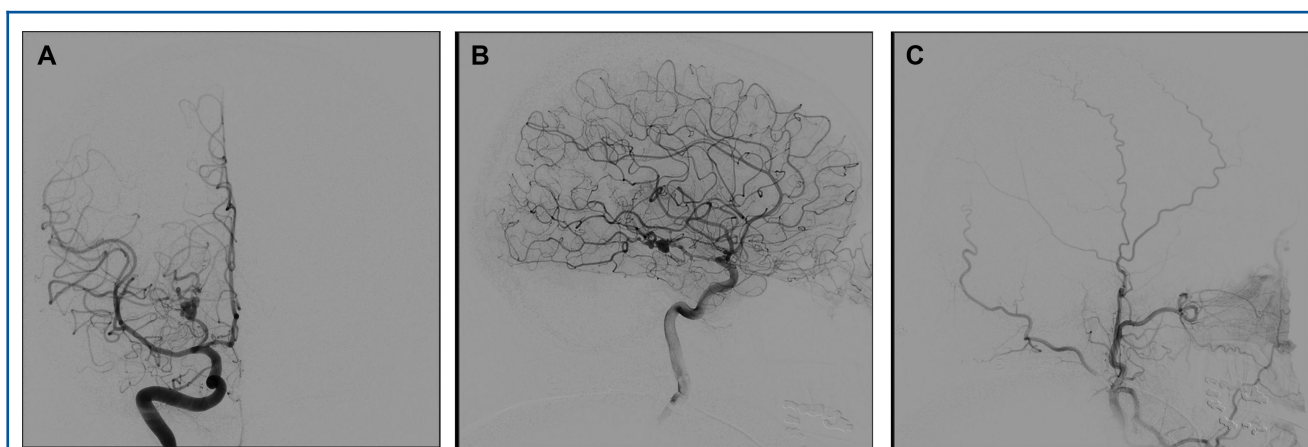
## CLINICAL PRESENTATION

A 42-yr-old right-handed female presented with diffuse subarachnoid hemorrhage (SAH) to an outside hospital; subsequent angiography

was performed showing a fusiform dissecting pseudoaneurysm of the PCA. The patient was transferred to our institution on postbleed day 6. The patient complained of headache without lateralizing or focal neurological deficits. She was evaluated by the endovascular service (R.J.); endovascular treatment including flow diversion was felt to be high risk due to the need for dual antiplatelet therapy in the setting of SAH. Preoperative angiography was reviewed, demonstrating a fetal configuration of the PCA with a fusiform aneurysm of the P2 segment; selective external carotid views confirmed the presence of a suitable donor STA (Figure 1). Craniotomy for the trapping of the aneurysm and STA-PCA was recommended.

Institutional Review Board (IRB)/ethics committee approval and patient consent statement: This study was performed in accordance with institutional IRB policies and the Committee on Publication Ethics (COPE) standards for reporting of case reports. Consent for publication has been obtained from the patient.

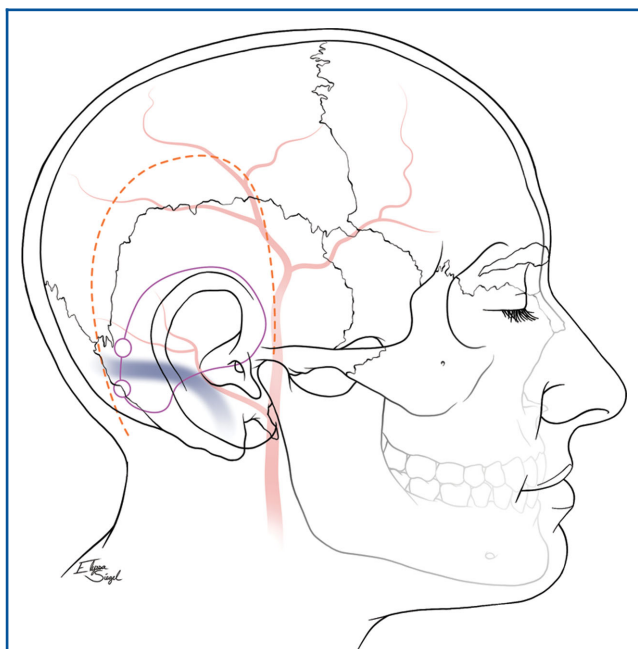
**ABBREVIATIONS:** BTO, balloon test occlusion; COPE, Committee on Publication Ethics; CSF, cerebrospinal fluid; IRB, Institutional Review Board; OA, occipital artery; PCA, posterior cerebral artery; SAH, subarachnoid hemorrhage; STA, superficial temporal artery



**FIGURE 1.** Preoperative anteroposterior **A** and lateral **B** digital subtraction angiography demonstrates a fetal configuration of the PCA with a fusiform aneurysm of the P2 segment; selective external carotid views confirmed the presence of a suitable donor STA for bypass **C**.

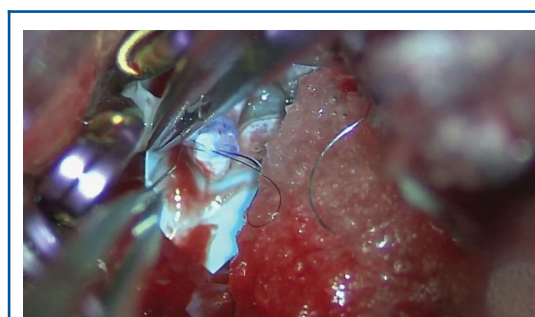
## Surgery

The patient was positioned supine and the STA was mapped on the scalp with a Doppler probe to 12 cm above the zygoma. A horseshoe incision was made beginning at the mastoid tip and extending over the STA (Figure 2). The STA was skeletonized, transected, and a temporarily clipped while the craniotomy was performed.

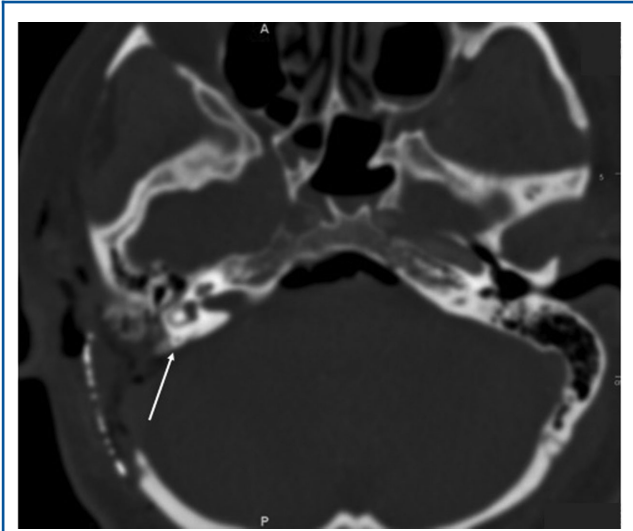


**FIGURE 2.** Artist's illustration of the horseshoe incision extending from the mastoid tip behind the ear and extending in continuity to the course of the STA anteriorly.

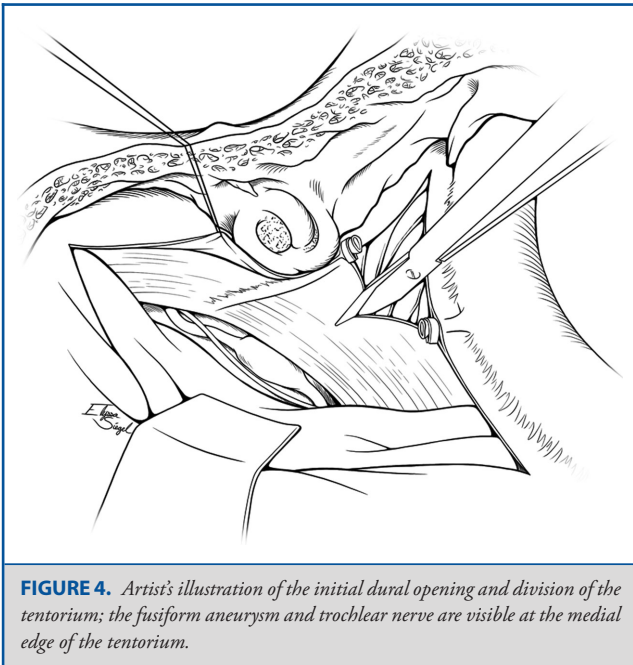
A rectangle middle fossa craniotomy was performed centered two-thirds posterior to the external auditory canal. A posterior petrosectomy was performed with a combination of cutting and diamond burs exposing the dura of Trautmann's triangle, presigmoid dura, and sinodural angle (see Video). Violation of the otic capsule was avoided by recognition of the operculum of the endolymphatic sac, which serves as a landmark for the posterior semicircular canal (Figure 3). The tentorium was divided after protection of the trochlear nerve (Figure 4). The aneurysm, distal bifurcation of the PCA to the posterior temporal and P3 segments, and the proximal PCA were identified. After temporary clipping, the STA bypass was performed, with an interrupted 10-0 suture on the far end of the bypass and a running 10-0 on the near side (Figure 5). Patency was confirmed with Doppler ultrasound, and fluorescent video-angiography. In addition to the PCA aneurysm, an abnormal vessel (likely a duplicated PCA) was identified, with a saccular aneurysm located at the origin of this vessel and the ICA, which was clipped. The bony defect was



**VIDEO.** Surgical video demonstrating retrolabyrinthine transtentorial exposure, STA-PCA bypass, and trapping of aneurysm.



**FIGURE 3.** Axial computed tomography showing the extent of posterior petrosal drill-out and relative position of posterior semicircular canal (arrow).

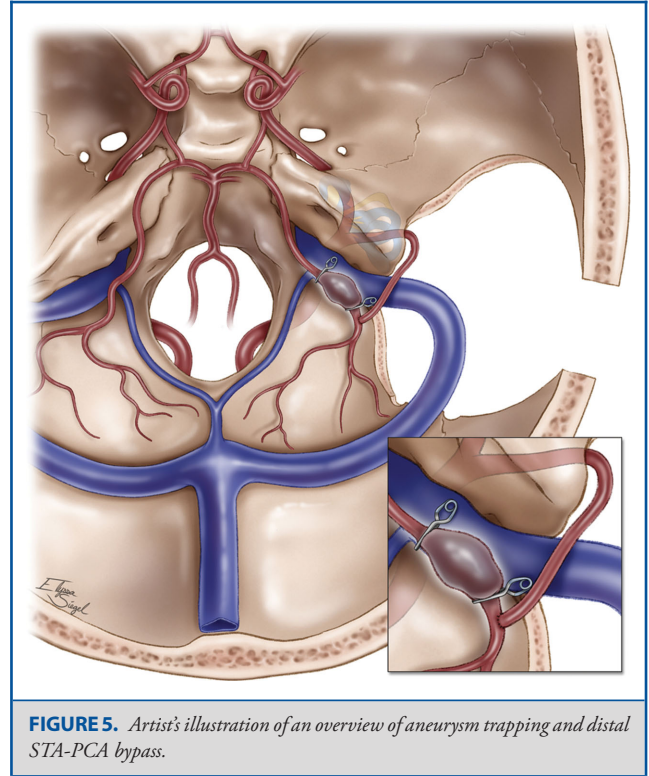


**FIGURE 4.** Artist's illustration of the initial dural opening and division of the tentorium; the fusiform aneurysm and trochlear nerve are visible at the medial edge of the tentorium.

filled with collagen onlay graft and fibrin glue and covered with a titanium mesh. A lumbar drain was placed to mitigate the risk of cerebrospinal fluid (CSF) leak.

### Postoperative Course

The patient was extubated after obtaining a postoperative angiogram (Figure 6). She was noted to have a new third nerve paresis but was otherwise neurologically intact. She was started



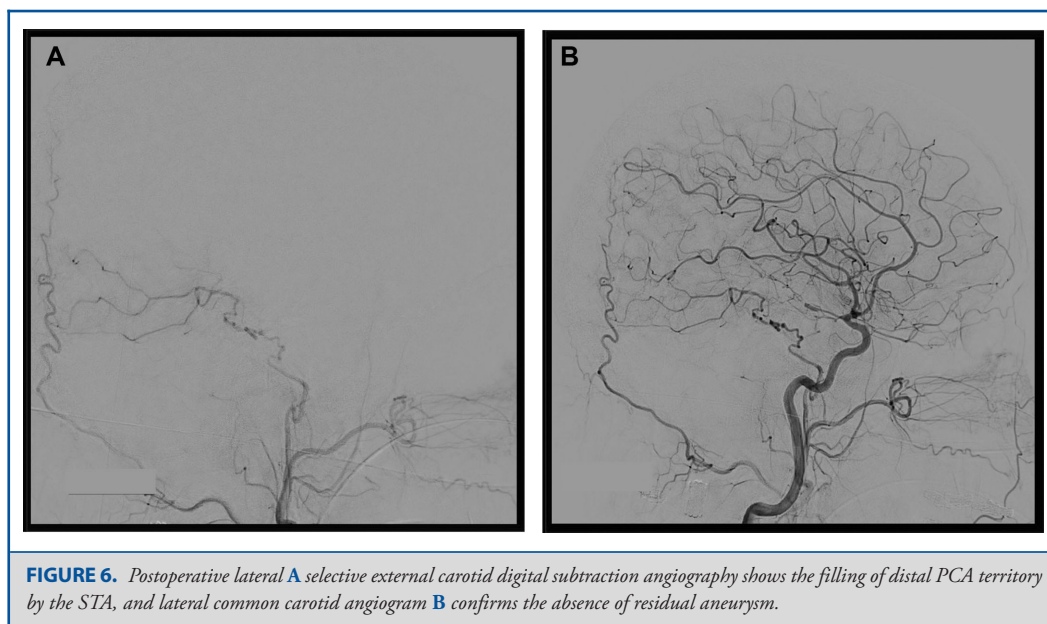
**FIGURE 5.** Artist's illustration of an overview of aneurysm trapping and distal STA-PCA bypass.

on aspirin 325 mg daily. Lumbar drainage was discontinued on postoperative day 4, and she was discharged on postoperative day 6. On 3-mo follow-up, the patient was neurologically intact with resolution of her third nerve palsy and with intact visual fields, and she remains neurologically intact with no evidence of stroke at 12-mo follow-up.

### DISCUSSION

Aneurysms of the PCA are uncommon, estimated at less than 1% of all cerebral aneurysms, and less than half occur distal to the P1/2 junction.<sup>1</sup> The treatment of these lesions remains controversial and requires multidisciplinary management.<sup>2-4</sup> Endovascular vessel sacrifice, with or without OA to distal PCA bypass, has been the mainstay approach to these aneurysms described in the literature,<sup>2,4-7</sup> although other approaches, including flow diversion,<sup>8</sup> aneurysmorrhaphy and clipping,<sup>9</sup> and in Situ SCA-PCA bypass,<sup>10</sup> have been described.

Hallacq et al<sup>7</sup> reported a series of 10 P2 segment aneurysms all treated with endovascular PCA occlusion without ischemic complications, which they attributed to the rich collateral supply to the distal PCA. However, a significant visual field deficit may occur in up to 17% of cases,<sup>11</sup> and the risk of disabling or life-threatening complications, though rare, is not negligible.<sup>5</sup> Hence, revascularization following vessel sacrifice ought to be considered when possible. Conventional bypass approaches for PCA aneurysms—primarily OA to distal PCA cortical



**FIGURE 6.** Postoperative lateral **A** selective external carotid digital subtraction angiography shows the filling of distal PCA territory by the STA, and lateral common carotid angiogram **B** confirms the absence of residual aneurysm.

branches—have a history of unsatisfying results. Chang et al<sup>12</sup> reported a 53% failure rate in 14 patients undergoing OA-PCA bypass for PCA aneurysms, the largest series in the literature. Bypass was associated with a high risk of complication and worse outcomes compared to patients not undergoing bypass, leading the authors to recommend against routine revascularization of these aneurysms prior to vessel sacrifice. Because of the risk of complications, Chang et al<sup>12</sup> advocate for balloon test occlusion (BTO) to determine whether bypass is indicated. However, the predictive value of BTO for PCA aneurysms is not established, and postoperative stroke has been reported even in the presence of a successful distal occipital to cortical PCA branch.<sup>13</sup>

Cadaveric studies have examined the feasibility of the presigmoid and subtemporal corridors for distal PCA bypasses,<sup>14,15</sup> and the retrolabyrinthine approach has previously been described in 3 patients for STA to SCA bypass.<sup>16</sup>

Kawashima et al<sup>17</sup> have recently described STA to distal PCA (P3) bypass in 3 patients using a standard subtemporal approach. We believe that the presigmoid transpetrosal approach utilized in the present case has several advantages over a subtemporal approach, including a shallower approach to the ambient cistern making the anastomosis less difficult, reduced risk of kinking of the STA by the tentorium, and no need for the resection of fusiform gyrus in order to expose the aneurysm. These benefits come at the cost of postauricular exposure and transpetrosal drill-out.

## CONCLUSION

Our approach decreases the technical hurdle of performing STA-PCA bypass; however, the exposure requires familiarity with

skull-base anatomy and may incur an increased risk of approach-related complications such as CSF leak, hearing loss, and facial nerve injury. Familiarity with skull base approaches such as the presigmoid transpetrosal approach described here is valuable for vascular neurosurgeons.

## Funding

This study did not receive any funding or financial support.

## Disclosures

The authors have no personal, financial, or institutional interest in any of the drugs, materials, or devices described in this article.

## REFERENCES

- Goehre F, Jahromi BR, Hernesniemi J, et al. Characteristics of posterior cerebral artery aneurysms: an angiographic analysis of 93 aneurysms in 81 patients. *Neurosurgery*. 2014;75(2):134-144.
- Nussbaum ES, Kallmes KM, Lässig JP, Goddard JK, Madison MT, Nussbaum LA. Cerebral revascularization for the management of complex intracranial aneurysms: a single-center experience. published online: October 1, 2018 *J Neurosurg*. (doi:10.3171/2018.4.JNS172752).
- Ponce FA, Albuquerque FC, McDougall CG, Han PP, Zabramski JM, Spetzler RF. Combined endovascular and microsurgical management of giant and complex unruptured aneurysms. *Neurosurg Focus*. 2004;17(5):E11.
- Sanai N, Tarapore P, Lee AC, Lawton MT. The current role of microsurgery for posterior circulation aneurysms: a selective approach in the endovascular era. *Neurosurgery*. 2008;62(6):1236-1249.
- Vishteh AG, Smith KA, McDougall CG, Spetzler RF. Distal posterior cerebral artery revascularization in multimodality management of complex peripheral posterior cerebral artery aneurysms: technical case report. *Neurosurgery*. 1998;43(1):166-170.
- Kazumata K, Yokoyama Y, Sugiyama T, Asaoka K. Occipital-posterior cerebral artery bypass via the occipital interhemispheric approach. *Surg Neurol Int*. 2013;4:90.
- Hallacq P, Piotin M, Moret J. Endovascular occlusion of the posterior cerebral artery for the treatment of P2 segment aneurysms:

- retrospective review of a 10-year series. *Am J Neuroradiol.* 2002;23(7):1128-1136.
8. Bender MT, Zarrin DA, Campos JK, et al. Tiny pipes: 67 cases of flow diversion for aneurysms in distal vessels measuring less than 2.0 mm. *World Neurosurg.* 2019;127:e193-e201.
  9. O'Connor KP, Strickland AE, Ernst GL, Milton CK, Cheema AA, Bohnstedt BN. Embolization and open decompression of a giant aneurysm involving the P2 segment of the posterior cerebral artery. *World Neurosurg.* 2020;133:172.
  10. Tanahashi K, Araki Y, Uda K, et al. Posterior cerebral artery reconstruction by in-situ bypass with superior cerebellar artery via occipital transtentorial approach. *World Neurosurg.* 2019;126:24-29.
  11. Drake CG, Hernesniemi J, Peerless SJ, eds. *Surgery of Vertebrobasilar Aneurysms: London Ontario Experience on 1,767 Patients.* New York, NY: Springer-Verlag; 1996.
  12. Chang SW, Abla AA, Kakarla UK, et al. Treatment of distal posterior cerebral artery aneurysms: a critical appraisal of the occipital artery-to-posterior cerebral artery bypass. *Neurosurgery.* 2010;67(1):16-25.
  13. Britz GW, Zomorodi A, Powers CJ. Distal posterior cerebral artery revascularization for a fusiform PCA aneurysm: a lesson learned. *Asian J Neurosurg.* 2017;12(2):273-275.
  14. Dai K, Song Z, Gao Y, Zheng J, Liu Z. Occipital artery to upper posterior circulation bypass through the presigmoid approach in revascularization of the posterior circulation: an anatomical study. *J Clin Neurosci.* 2019;63:209-212.
  15. Zador Z, Lu DC, Arnold CM, Lawton MT. Deep bypasses to the distal posterior circulation: anatomical and clinical comparison of pretemporal and subtemporal approaches. *Neurosurgery.* 2010;66(1):92-100.
  16. Ito M, Kinoshita A, Takemoto O, Kohmura E, Hayakawa T. Superficial temporal artery to superior cerebellar artery anastomosis via the presigmoid retrolabyrinthine transtentorial approach. *Surg Neurol.* 1995;43(4):360-362.
  17. Kawashima A, Andrade-Barazarte H, Jahromi BR, et al. Superficial temporal artery: distal posterior cerebral artery bypass through the subtemporal approach: technical note and pilot surgical cases. *Oper Neurosurg.* 2017;13(3):309-316.