

# Efficacy of Combined Treatment with Intense Pulsed Light and Erbium Fractional Laser in Striae Gravidarum

Yi Wang, Yong Song

Department of Plastic Surgery, Fujian Maternity and Child Health Hospital, Fuzhou, Fujian, 350000, People's Republic of China

Correspondence: Yong Song, Department of Plastic Surgery, Fujian Maternity and Child Health Hospital, No. 18, Daoshan Road, Gulou District, Fuzhou, Fujian, 350000, People's Republic of China, Tel +86-0591-87514834, Email Yongsong1985@163.com

**Purpose:** Laser and intense pulsed light (IPL) treatments are preferred over invasive procedures due to less pain. This study looked at the efficacy and safety of IPL and Erbium fractional laser for patients with striae gravidarum (SG).

**Patients and Methods:** All 60 patients with SG were successfully enrolled in the study. IPL treatment was followed by Erbium fractional laser (wavelength 2940 nm) treatment at 4-week intervals for a total of three treatments. SG elasticity was assessed with a SEM575 custom instrument and patients were scored for SG span with an Antera 3D multifunctional skin imaging analyzer. A 3D skin impact system was used to assess patients' epidermal thickness. A visual analog scale (VAS) was used to assess patients' pain scores during the treatment period. Improvement in stretch marks was assessed with the Global Aesthetic Improvement Scale (GAIS). The occurrence of adverse events was recorded at a follow-up of 3 months. Patient satisfaction with the outcome of the treatment was also recorded.

**Results:** Area of stretch marks decreased from  $7.89 \pm 0.49 \text{ cm}^2$  pre-treatment to  $4.94 \pm 1.16 \text{ cm}^2$  post-treatment ( $P < 0.001$ ). The grayness values and atrophy of stretch marks were reduced after treatment. Furthermore, skin elasticity and thickness at the lesions of patients increased significantly after the treatment ( $P < 0.001$ ), while the width of the stretch marks significantly decreased ( $P < 0.001$ ). The VAS score was  $5.45 \pm 1.31$ , the incidence of adverse events was 25%, and patient satisfaction with the efficacy was 96.67%.

**Conclusion:** IPL combined with Erbium fractional laser improves the area and atrophy of SG, lightens the color, and increases the elasticity and thickness of the skin, with high treatment safety and remarkable clinical results.

**Keywords:** IPL, striae gravidarum, erbium fractional laser

## Introduction

Striae gravidarum (SG), also known as stretch marks, is a common skin problem that affects 55–90% of the women.<sup>1</sup> Tension and hormonal changes in the abdominal wall during pregnancy lead to rupture and separation of collagen elastic fibers in abdominal skin or thighs or breasts, initially as erythematous to purplish red itchy streaks,<sup>2</sup> which over time become hypopigmented, atrophic, permanent, scar-like strips (white streaks).<sup>3</sup> Although postpartum ruptured fibers slowly recover and SG subsides slightly, it cannot be restored to its original state without treatment. SG does not cause physical dysfunction, but it can permanently affect physical appearance and cause serious psychological burden, and mental stress to pregnant women, and reduce their quality of life. Therefore, the occurrence and treatment of SG have been the focus of current medical research.

Topical drugs and devices are now commonly used in clinical practice to reduce the severity of SG. However, most drugs are ineffective and have side effects. Instrumental treatment is relatively convenient and safe and has developed as the main method of SG.<sup>4</sup> Intense pulsed light (IPL) is a common method for repairing scars and melasma in clinical practice.<sup>5,6</sup> In SG, IPL has been shown to stimulate fibroblast activation, accompanied by new collagen synthesis and

extracellular matrix production to improve the length and width of SG. However, the limitations and effectiveness of a single treatment have led to unsatisfactory satisfaction with the treatment.

Erbium fractional laser (Erbium fractional-doped yttrium aluminum garnet (Er:YAG) laser treatment) with a wavelength of 2940 nm is a new type of laser treatment. It is important for localized scleroderma,<sup>7</sup> facial acne scars,<sup>8</sup> and skin tightening.<sup>9</sup> Based on an ablation laser, it uses the principle of fractional photothermal action to produce multiple light spots to act on the skin. The depth, width, and density of the treatment site through light spots stimulate the regeneration of superficial skin collagen fibers, effectively helping the skin to heal. It does not cause excessive thermal damage to the surrounding tissue of the skin injury. IPL in combination with Erbium fractional laser has been successfully used for the treatment of melanocytic nevus,<sup>10</sup> skin rejuvenation,<sup>11</sup> and scar prevention.<sup>12</sup> However, the potential role of IPL and fractional Er:YAG lasers in stretch marks is unknown.

In this study, we will analyze the effect of combined IPL and fractional Er:YAG laser for SG treatment to provide a theoretical basis for clinical treatment.

## Materials and Methods

### Participants in This Research

This study was a pre-post test and self-controlled clinical study that recruited 60 female SG patients who underwent consultation at our hospital from January 2018 to December 2020. Inclusion criteria were as follows: 1) meeting the diagnostic criteria of abdominal SG and with symmetrical white SG in the abdomen and 2) SG duration was more than 6 months postpartum. In addition, this study excluded 1) patients with skin diseases such as dermatitis and acne; 2) patients who had been treated for SG; 3) those who had taken immunosuppressive drugs or suffered from disease affecting wound healing; and 4) pregnant or lactating patients were excluded from this study. The general clinical information of SG patients was recorded in Table 1.

The study was conducted following the 1964 Declaration of Helsinki and its and its later amendments or comparable ethical standards. Approval was obtained from the Medical Ethics Committee of Fujian Maternity and Child Health Hospital, and patients were informed of the risks and obligations associated with this experiment and informed consent was obtained before treatment.

### Experimental Procedure

Patients were treated at 4-week intervals for a total of 3 treatments. The results of the patient's previous and last treatment were recorded. SG patients were anesthetized with 1.5 g/cm<sup>2</sup> of lidocaine cream applied uniformly to the skin 40 min before treatment, and surface anesthesia was applied. Then, the skin was cleaned and disinfected twice with alcohol wipes, and the treatment was performed after the alcohol had dried.

IPL wavelength was set to 590–1200 nm, pulse type was a double pulse, width is 4.0 ms, the delay is 35 ms, and capacity density is set in the range of 20–25 J/cm<sup>2</sup>. Erbium fractional laser treatment with parameters' wavelength of 2940 nm, exfoliation 150–200 um, 0–1 level coagulation, coverage of 11%, energy parameters set to 800–1200 mJ/cm<sup>2</sup>

**Table 1** The Baseline Data of Study Objects

Parameters	Stretch Gravidarum Patients (n = 60)
Age (years)	27.8 ± 2.7
Height (cm)	164.1 ± 6.2
Pre-pregnancy BMI (kg/m <sup>2</sup> )	21.41 ± 1.90
Post-pregnancy BMI (kg/m <sup>2</sup> )	26.99 ± 1.42
Weight increase (kg)	17.59 ± 4.95
Disease duration (months)	24.3 ± 10.2
First production, n (%)	44 (73.33)

**Abbreviation:** BMI, body mass index.

for depressed areas, scan repeated 3 times. After IPL treatment, stretch marks were then treated with Erbium fractional laser.

## Overall Assessment of Stretch Marks

Three non-participating dermatologists evaluated the overall condition of the patients' stretch marks before and after 3 treatments, with a total score of 0–4. Among them, 0 scored as normal skin; 1 scored as light stretch marks; 2 scored as moderate stretch marks; 3 scored as heavy stretch marks; 4 scored as severe stretch marks.

## Stretch Mark Areas and Grayscale Values

With the patient lying down, the camera's automatic sharpening, blurring, noise cancellation, and other filtering functions were turned off, and a ruler with the gray card was placed next to the target area to be photographed. The camera lens is placed directly above the shooting area, the lens plane is parallel to the target area, and the shooting distance is about 60 cm so that the stretch marks are presented after accurate focusing. The white balance was then corrected with a gray card in Photoshop software and the area of the stretch marks was measured using the scale on the ruler.

Afterward, the photograph was brought closer to 10 cm and the fluorescent light was isolated using only light, where 0 was the blackest, 255 was the whitest, and the gray value = the gray value of the lesion - the gray value of the normal part. The smaller the difference, the lighter the white stretch marks and the more aesthetically pleasing they are.

## Degree of Atrophy Assessment

Three non-participating dermatologists rated the degree of atrophy before treatment and at the last time of treatment based on photographs, with a total score of 0–4. Among them, 0 was classified as no atrophy; 1 was classified as white visible atrophy with slight tactile sensation; 2 was mild atrophy, fine lines visible in shape; 3 was classified as lusterless and obvious atrophy; 4 was lusterless and had obvious deep sunken stripes within the stripes.

## Skin Elasticity, Stretch Mark Width Measurement, and Epidermal Thickness

Before and after the last treatment, the skin elasticity of the patient's stretch marks was measured using a skin cutometer SEM575, where the closer the score to 1, the better the skin elasticity. What's more, the Antera 3D Multifunctional Skin imaging analyzer was used to detect the width of the patient's stretch marks, and the average value of three measurements was taken. Before and after the last treatment, the epidermal thickness was measured using a 3D skin CT impact analysis system, and the average values of the three measurements were counted.

## Assessment of Pain Levels and Adverse Effects

Patients scored the level of pain for each treatment session on a visual analog scale (VAS). The total score was 0–10, with 0 being no pain and 10 being the most pain. Adverse events such as blistering, erythema, pruritus, hyperpigmentation, and scarring during the treatment and 3-month follow-up period were recorded by the physician and the patient.

## The Overall Clinical Improvement Assessment

Overall improvement in patients' stretch marks was assessed according to the Global Aesthetic Improvement Scale (GAIS). Three dermatologists who did not participate in the treatment compared pre- and post-treatment photographs of patients to assess their improvement. Where 0 scored worse; 1 scored no changes (validity <25%); 2 scored improved (validity 25–50%); 3 scored much improved (validity 51–75%); and 4 scored very much improved (validity 76–100%).

## Patients Satisfaction Ratings

Patient satisfaction with treatment and outcome during follow-up was assessed using a 5-point scale: 0 classified as unsatisfied; 1 classified as slightly satisfied; 2 classified as generally satisfied; 3 classified as satisfied; 4 classified as very satisfied.

## Statistical Analysis

The clinical data were statistically analyzed using SPSS as well as GraphPad Prism 6.0 software. The data related to pre-treatment and post-treatment were performed by paired *t*-test, and all statistical analyses were performed by two-tailed *t*-test, with  $P < 0.05$  being statistically significant. Kappa statistics was used to compute the measure of agreement among three independent investigators, and all the kappa value was 0.81–1.0 indicating almost perfect agreement.

## Results

### Subject Demographics

Sixty SG subjects completed all courses of treatment, and their demographic characteristics are summarized in Table 1, with a mean age of  $27.8 \pm 2.7$  years, duration of disease of  $24.3 \pm 10.2$  months, and mean weight gain of  $17.59 \pm 4.95$  kg.

### IPL Combined with Erbium Fractional Laser Improves the Overall Condition and Grayness of Stretch Marks

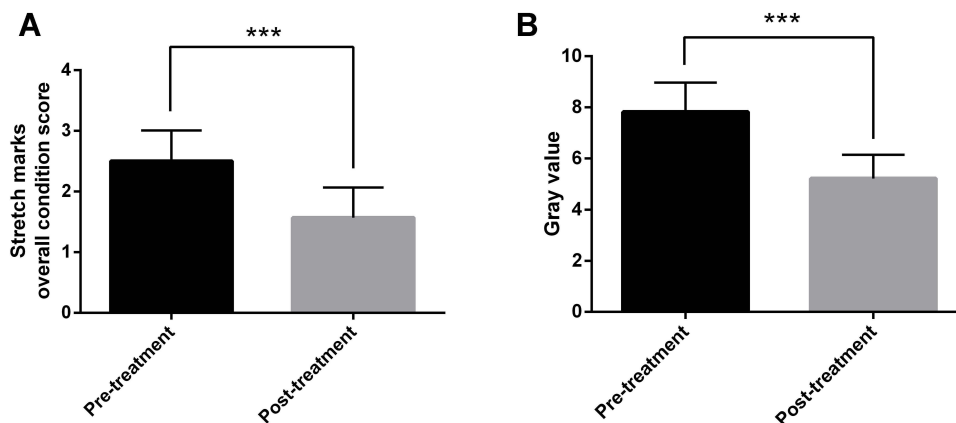
The overall effectiveness of IPL combined with Erbium fractional laser for stretch marks was evaluated for the first time. Overall assessment score of stretch marks decreased from  $2.5 \pm 0.50$  pre-treatment to  $1.57 \pm 0.49$  post-treatment ( $P < 0.001$ , Figure 1A), and the subjective GAIS score of  $3.15 \pm 0.68$  also confirmed that the combination treatment improved the aesthetics of stretch marks (Table 2). More importantly, the gray value of stretch marks was decreased from  $7.82 \pm 1.15$  pre-treatment to  $5.22 \pm 0.93$  post-treatment, suggesting a decline and aesthetic enhancement of stretch marks ( $P < 0.001$ , Figure 1B).

### Stretch Mark Area and Atrophy Were Significantly Suppressed

The area of stretch marks after IPL combined with Erbium fractional laser treatment was evaluated. Compared with the pre-treatment of  $7.89 \pm 0.66$  cm<sup>2</sup>, the area of stretch marks was reduced to  $4.94 \pm 1.16$  cm<sup>2</sup> after combined treatment ( $P < 0.001$ , Figure 2A). Additionally, the combination of IPL and Erbium fractional laser reduced the pre-treatment atrophy score from  $2.30 \pm 1.21$  to  $0.85 \pm 0.76$  ( $P < 0.001$ , Figure 2B).

### Improvement of Skin Elasticity, Thickness, and Width of Stretch Marks

After treatment, the patient's skin elasticity was  $0.87 \pm 0.34$  mm thicker than before treatment  $0.79 \pm 0.04$  mm ( $P < 0.001$ , Figure 3A). The maximum stretch mark width pre-treatment was reduced from  $4.73 \pm 1.24$  mm to  $2.78 \pm 1.04$  mm ( $P < 0.001$ , Figure 3B). Skin thickness was also evaluated before and after treatment, and as shown in Figure 3C, the results confirmed that the skin thickness was  $28.75 \pm 0.48$  μm before treatment and  $31.09 \pm 14.3$  μm, an increase in skin thickness of  $2.34 \pm 1.54$  μm ( $P < 0.05$ ).



**Figure 1** Overall improvement of IPL combined with Erbium fractional laser: (A). Subjective overall improvement score of stretch marks. (B). Change in grayscale values of stretch marks after treatment. \*\*\* $P < 0.001$  vs post-treatment.

**Table 2** GAIS Scores

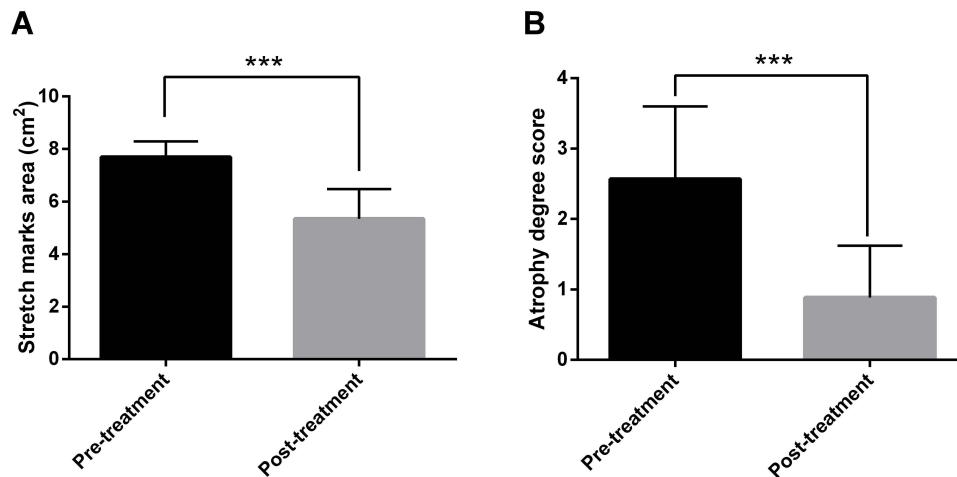
Parameters	Values
GAIS	
Very much improved (5 points)	2 (3.33)
Much improved (4 points)	13 (21.67)
Improved (3 points)	37 (61.67)
Unchanged (2 points)	8 (13.33)
Worsened (1 point)	0 (0.00)
GAIS scores	3.15 ± 0.68

**Note:** Values are number with percentage or mean ± SD, where appropriate.

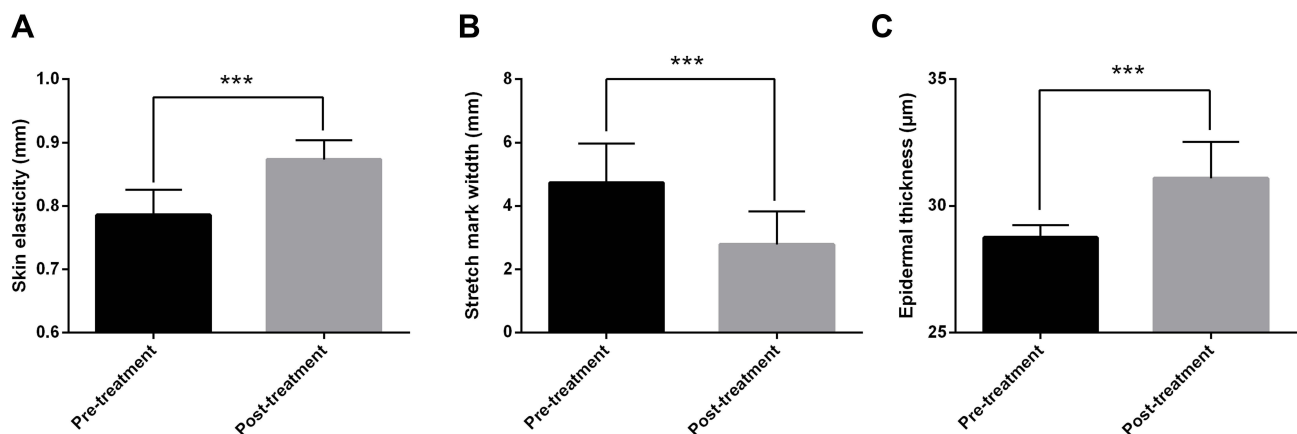
**Abbreviation:** GAIS, Global Aesthetic Improvement Scale.

## Patient's VAS Scores, Adverse Events, and Satisfaction Scores After Treatment

The VAS score of SG patients during treatment was  $5.45 \pm 1.31$  for 10 patients with local itching, 2 patients with short-term pigmentation, and 3 patients with redness in the treatment area, but all of them could recover after 2–3 days, and the incidence of adverse reactions was 25%. Finally, patient satisfaction after the combined treatment was 96.67% (Table 3).



**Figure 2** Assessment of the area and degree of atrophy of stretch marks before and after treatment. (A). IPL combined with Erbium fractional laser treatment significantly reduced the area of stretch marks in subjects. (B). Assessment of stretch mark atrophy score by combined treatment. \*\*\* $P < 0.001$  vs post-treatment.



**Figure 3** Skin elasticity, thickness, and width of stretch marks were assessed. (A). Skin elasticity was assessed pre-treatment and post-treatment. (B). Thickness of the skin was evaluated before and after the last treatment. (C). Width of stretch marks was assessed pre-treatment and post-treatment. \*\*\* $P < 0.001$  vs post-treatment.

**Table 3** VAS Score, Adverse Reaction, Satisfaction After IPL Combined with Erbium Fractional Laser Treatment

Parameters	Values
VAS score	5.45 ± 1.31
Adverse reaction	15 (25)
Local itching	10 (16.67)
Short-term pigmentation	2 (3.33)
Redness	3 (5.00)
Satisfaction	58 (96.67)
Unsatisfied (0 point)	2 (3.33)
Slightly satisfied (1 point)	4 (6.67)
Generally satisfied (2 points)	8 (13.33)
Satisfied (3 points)	25 (48.33)
Very satisfied (4 points)	21 (35.00)
Satisfaction scores	3.32 ± 0.65

**Notes:** Values are numbers with percentage or mean ± SD.

**Abbreviation:** VAS, visual analog scale.

## Discussion

Topical medications and instrumental treatments are commonly used for stretch marks, but the long-term medications and potential side effects have generated widespread interest in device treatments and have become the primary method of stretch mark treatment. However, the current instruments alone can also have different disadvantages. For example, photonic pigment rejuvenators improve their skin color by emitting UA photons of different energy intensities but carry the risk of pigment shedding and therefore require maintenance treatment.<sup>13</sup> The radiofrequency treatment instrument heats and cools the skin to remodel collagen, but the treatment time is longer to achieve better results.<sup>2</sup>

Recently, fractional laser combined with light therapy has attracted special attention. For example, scar treatment,<sup>12</sup> facial rejuvenation,<sup>14</sup> swelling lines,<sup>15</sup> and hyperplastic scars<sup>16</sup> significantly out good results. IPL in phototherapy is a non-ablative optical treatment technology that allows the integration of different spectra, selective photothermal effects, and biological effects through a set of pulsed light consisting of broad-spectrum intense light. In stretch marks, Bedewi and Khalafawy found that IPL treats stretch marks by stimulating dermal fibroblasts, which are stimulated to promote protein expression and collagen production with few side effects and potential therapeutic effects.<sup>17</sup> Al-Dhalimi and Abo Nasyria found that treatment with IPL at 650 nm and 590 nm once a week for five consecutive sessions resulted in significant improvement in stretch marks.<sup>18</sup> However, several studies have confirmed that, compared to fractional laser treatments, while IPL provides significant improvements in the length and width of stretch marks, the results are not significant when compared to patient satisfaction.<sup>15</sup>

A fractional laser optimizes the intense light source using a fractional array. This effectively avoids thermal damage to the surrounding skin tissue, while its unique cooling technology effectively reduces thermal damage from the light.<sup>19</sup> However, it activates keratinocytes through thermal stimulation to promote collagen proliferation and repair rearrangement, thus improving skin texture and beautifying scarring. The fractional CO<sub>2</sub> laser acts on the treatment area through the photothermal reaction principle and has a good repair effect and large energy, but lacks good selectivity, which is easy to cause thermal damage to the normal tissue in the treatment area and has large adverse reactions.

The Erbium fractional laser is a new fractional laser with a wavelength of 2790 nm. The water absorption of this laser is based between the erbium laser and the CO<sub>2</sub> laser, which have the characteristics of significant efficacy of CO<sub>2</sub> laser but also have the characteristics of mild side effects like the erbium laser.<sup>20</sup> Previous studies have shown that it can precisely vaporize scar tissue, stimulate superficial skin collagen fiber regeneration, and help skin healing without excessive thermal damage to the tissue surrounding the skin injury.<sup>8,21</sup> The Erbium fractional laser has both fractional and exfoliative modes. The fractional model of scar treatment not only stimulates collagen rearrangement but also

destroys sebaceous glands and normalizes the skin of the scar, reducing post-treatment adverse effects.<sup>22</sup> While collagen production may be increased through increased expression of FGF, VEGF, and elevated type I and III collagen, increased extracellular matrix, and collagen synthesis that outpaces degradation. IPL uses low energy and low density connected intense pulsed photo irradiation, which is selective in treatment and can decompose color spots without destroying normal skin, but it causes reversible thermal damage to collagen and the recovery effect is slow. Both IPL and Erbium Yag energy-based pathophysiological alterations work through photo thermolysis. Patients with abdominal stretch marks have a change in skin color and varying degrees of atrophy. The goal of treatment is to reduce the area of atrophy and restore the original firmness and elasticity while restoring the normal color of the skin.<sup>23</sup>

In the current study, we combined IPL with Erbium fractional laser to treat patients with stretch marks and confirmed that the combined treatment significantly improved the overall condition of the stretch marks, lightened the color of the stretch marks, reduced the area of the stretch marks, and inhibited the atrophy score of the stretch marks, and improved the aesthetic appearance. The fractional laser has a precisely controllable grinding depth and is more suitable for treating superficial scarring than the commonly used CO<sub>2</sub> laser.<sup>24</sup> In addition, patients with jaundice have more pigmentation at the epidermal base, and different ablative procedures have a high incidence of pigmentation due to high damage. In our study, it was confirmed that IPL combined with Erbium fractional laser resulted in a greater improvement in pigmentation. What's more, we objectively examined the elasticity and thickness of the patient's skin and the width of the stretch marks afterward. The results of the study confirmed an increase in skin elasticity and thickness, as well as a reduction in the width of the stretch marks compared to the pre-treatment period. Stretch marks patients have less pain during treatment, less incidence of adverse events, and higher patient satisfaction with the results. Additionally, topical administration of aloe vera or almond oil was effective in relieving local redness and swelling, scar softening cream relieves local itching, and striae Gravidarum, a mixed mushroom tyrosinase inhibitor, was effective in reducing hyperpigmentation in patients with post-treatment adverse reactions.

This study does have several limitations that need to be considered when interpreting the findings. Firstly, changes in stretch mark elasticity and reduction in gestational atrophic scarring should be tested at each visit so that the exact time of showing efficacy is clearly understood. The limitations of this preliminary study were not designed promptly and therefore will be further explored in depth in subsequent expansion and mechanistic studies. Furthermore, the failure to expose any stripe as a control for comparison with the intervention due to the treatment and study protocol is also a limitation in this study.

## Conclusion

In summary, it was confirmed in this study that the combination of Erbium fractional laser and IPL treatment for stretch marks can significantly improve the degree of atrophy, increase elasticity, and facilitate the degree of healing of the lesions, which is a safe and effective treatment for stretch marks and worthy of clinical promotion.

## Disclosure

The authors report no conflicts of interest in this work.

## References

1. Matyashov T, Pardo E, Rotem R, et al. The association between striae gravidarum and perineal lacerations during labor. *PLoS One*. 2022;17(3):e0265149. doi:10.1371/journal.pone.0265149
2. Dai H, Liu Y, Zhu Y, Yu Y, Meng L. Study on the methodology of striae gravidarum severity evaluation. *Biomed Eng Online*. 2021;20(1):109. doi:10.1186/s12938-021-00945-w
3. Karhade K, Lawlor M, Chubb H, Johnson TRB, Voorhees JJ, Wang F. Negative perceptions and emotional impact of striae gravidarum among pregnant women. *Int J Womens Dermatol*. 2021;7(5PartB):685–691. doi:10.1016/j.ijwd.2021.10.015
4. Tang Z, Wen S, Liu T, Yu A, Li Y. Comparative study of treatment for striae alba stage striae gravidarum: 1565-nm non-ablative fractional laser versus fractional microneedle radiofrequency. *Lasers Med Sci*. 2021;36(9):1823–1830. doi:10.1007/s10103-020-03203-y
5. Adel S, Serri A, Abd El-Raheem T. Study of autologous platelet-rich-plasma versus its combination with intense pulsed light in treatment of melasma. *Dermatol Ther*. 2021;34(4):e15008. doi:10.1111/dth.15008
6. Iranmanesh B, Khalili M, Mohammadi S, Amiri R, Aflatoonian M. The efficacy of energy-based devices combination therapy for melasma. *Dermatol Ther*. 2021;34(3):e14927. doi:10.1111/dth.14927

7. Szczepanik-Kulak P, Michalska-Jakubus M, Krasowska D. Laser therapy for the treatment of morphea: a systematic review of literature. *J Clin Med*. 2021;10:15. doi:10.3390/jcm10153409
8. Chen L, Wang Y, Jiang L, Fang J, Ren J. Comparison of 2940 nm Er: YAG laser treatment in the microlaser peel, fractional ablative laser, or combined modes for the treatment of concave acne scars. *Medicine*. 2021;100(28):e26642. doi:10.1097/MD.00000000000026642
9. Vas K, Besenyi Z, Urban S, et al. Efficacy and safety of long pulse 1064 and 2940 nm lasers in noninvasive lipolysis and skin tightening. *J Biophotonics*. 2019;12(9):e201900083. doi:10.1002/jbio.201900083
10. Lee JM, Kim IH, Rhyu HJ, Ryu HJ. Combined intense pulsed light and Er: YAG laser treatment of congenital melanocytic nevus. *J Cosmet Laser Ther*. 2015;17(3):162–164. doi:10.3109/14764172.2014.1003244
11. Tao L, Wu J, Qian H, et al. Intense pulsed light, near infrared pulsed light, and fractional laser combination therapy for skin rejuvenation in Asian subjects: a prospective multi-center study in China. *Lasers Med Sci*. 2015;30(7):1977–1983. doi:10.1007/s10103-015-1792-8
12. Kim JC, Kang SY, Kim HO, Park CW, Kwon O, Chung BY. Efficacy of combined treatment with intense pulsed light and fractional erbium: yAG laser in scar prevention: a randomized split wound trial. *Dermatol Ther*. 2021;34(5):e15061. doi:10.1111/dth.15061
13. Seirafianpour F, Sodagar S, Mozafarpoor S, et al. Systematic review of single and combined treatments for different types of striae: a comparison of striae treatments. *J Eur Acad Dermatol Venereol*. 2021;35(11):2185–2198. doi:10.1111/jdv.17374
14. Nistico SP, Silvestri M, Zingoni T, Tamburi F, Bennardo L, Cannarozzo G. Combination of fractional CO2 laser and rhodamine-intense pulsed light in facial rejuvenation: a randomized controlled trial. *Photobiomodul Photomed Laser Surg*. 2021;39(2):113–117. doi:10.1089/photob.2020.4876
15. El Taieb MA, Ibrahim AK. Fractional CO2 laser versus intense pulsed light in treating striae distensae. *Indian J Dermatol*. 2016;61(2):174–180. doi:10.4103/0019-5154.177774
16. Daoud AA, Gianatasio C, Rudnick A, Michael M, Waibel J. Efficacy of Combined Intense Pulsed Light (IPL) with fractional CO2-laser ablation in the treatment of large hypertrophic scars: a prospective, randomized control trial. *Lasers Surg Med*. 2019;51(8):678–685. doi:10.1002/lsm.23092
17. Bedewi AE, Khalafawy GE. The use of synchrotron infrared microspectroscopy to demonstrate the effect of intense pulsed light on dermal fibroblasts. *J Cosmet Laser Ther*. 2013;15(6):305–309. doi:10.3109/14764172.2013.769271
18. Al-Dhalimi MA, Abo Nasyria AA. A comparative study of the effectiveness of intense pulsed light wavelengths (650 nm vs 590 nm) in the treatment of striae distensae. *J Cosmet Laser Ther*. 2013;15(3):120–125. doi:10.3109/14764172.2012.748200
19. Zhang Z, Chen J, Huang J, Wo Y, Zhang Y, Chen X. Experimental study of 5-fluorouracil encapsulated ethosomes combined with CO2 fractional laser to treat hypertrophic scar. *Nanoscale Res Lett*. 2018;13(1):26. doi:10.1186/s11671-017-2425-x
20. Muruppel AM, Pai BSJ, Bhat S, Parker S, Lynch E. Laser-assisted depigmentation—an introspection of the science, techniques, and perceptions. *Dent J*. 2020;8:3.
21. Madni TD, Lu K, Nakonezny PA, et al. Treating hypertrophic burn scar with 2940-nm Er:YAG laser fractional ablation improves scar characteristics as measured by noninvasive technology. *J Burn Care Res*. 2019;40(4):416–421. doi:10.1093/jbcr/irz056
22. El-Taieb MA, Ibrahim HM, Hegazy EM, Ibrahim AK, Gamal AM, Nada EA. Fractional erbium-YAG laser and platelet-rich plasma as single or combined treatment for atrophic acne scars: a randomized clinical trial. *Dermatol Ther*. 2019;9(4):707–717. doi:10.1007/s13555-019-00318-1
23. Oakley AM, Patel BC. Stretch Marks. In: *StatPearls*. Treasure Island (FL): StatPearls Publishing; 2022.
24. Bayne K, Fornwalt BE, Jonda CF, Cash AD. Successful novel treatment of granuloma faciale using CO2 Emulated Er:YAG laser ablation. *Plast Reconstr Surg Glob Open*. 2021;9(10):e3847. doi:10.1097/GOX.0000000000003847

## Clinical, Cosmetic and Investigational Dermatology

Dovepress

### Publish your work in this journal

Clinical, Cosmetic and Investigational Dermatology is an international, peer-reviewed, open access, online journal that focuses on the latest clinical and experimental research in all aspects of skin disease and cosmetic interventions. This journal is indexed on CAS. The manuscript management system is completely online and includes a very quick and fair peer-review system, which is all easy to use. Visit <http://www.dovepress.com/testimonials.php> to read real quotes from published authors.

Submit your manuscript here: <https://www.dovepress.com/clinical-cosmetic-and-investigational-dermatology-journal>