

CASE REPORT

Mandibular arteriovenous malformation: A rare life-threatening condition depicted on multidetector CT angiography

Amit Nandan Dhar Dwivedi, Anubha Pandey, Ishan Kumar, Arjit Agarwal

Department of Radiodiagnosis and Imaging, Institute of Medical Sciences, Banaras Hindu University, Varanasi, Uttar Pradesh, India

Address for correspondence:

*Dr. Amit Nandan Dhar Dwivedi,
Departments of Radiodiagnosis and Imaging,
Institute of Medical Sciences,
Banaras Hindu University, Varanasi - 221 005,
Uttar Pradesh, India.
E-mail: amitnandan21@yahoo.com*

ABSTRACT

Arteriovenous malformation (AVM) of the mandible is a rare and potentially life-threatening condition which can lead to massive hemorrhage. The following is a description where a large mandibular AVM presented with torrential bleeding following tooth extraction for caries. An orthopantomogram (OPG) was performed which was suggestive of aneurysmal bone cyst or ameloblastoma. A computed tomography (CT) angiography revealed a large mandibular AVM with submandibular extension. It is important for both clinicians and radiologist to be aware of this type of lesion that can have life-threatening complications. It is important to define the anatomical location and the feeder vessels of the entity in detail preoperatively. This communication highlights the common differential and use of multidetector CT (MDCT) angiography along with other imaging modalities to prevent a fatal hemorrhage and arrive at a correct diagnosis.

Key words: Computed tomography angiography, mandibular arteriovenous malformation, radiolucent lytic lesion

INTRODUCTION

Arteriovenous malformations (AVMs) occur as a result of errors in vascular morphogenesis present at birth. These grow proportionately with age,^[1,2] and manifest at any time during life due to an event like trauma, surgery, infection, etc.^[3]

Mandibular AVMs are uncommon and potentially life-threatening vascular malformations.^[4-6] Young female patients are predominantly affected. They are frequently high-flow vascular malformations.^[7] Clinically, they may present with minor gingival bleeding, dental loosening, lower lip numbness, facial deformity, malocclusion and sometimes hemorrhagic shock following extraction of teeth.^[8-10] The radiographic appearances of these lesions are variable, ranging from a small radiolucency to markedly obvious osseous erosion of the alveolus with apparently floating teeth. Computed tomography (CT) scan and magnetic resonance imaging (MRI) are helpful imaging tools to assess the extent

of the lesion into the bone, soft tissue and major vessels. We report a case of a 10-year-old female with an AVM of the left half of mandibular ramus with extension into submandibular region.

CASE REPORT

A 10-year-old female patient presented at Emergency Room of our institute with massive hemorrhage apparently from left side of mouth following tooth extraction for caries. Hemorrhage was controlled by packing the mandible and subsequent blood transfusion. The patient had no history of previous medications, blood transfusions, bleeding diathesis or hospitalization. Systemic examination was unremarkable. No obvious facial asymmetry was noted [Figure 1]. The patient was advised an orthopantomogram (OPG) which was suggestive of a large expansile radiolucent lesion with soap bubble appearance in left ramus and angle of mandible extending up to molar area [Figure 2]. Suspecting a possible aneurysmal bone cyst or ameloblastoma, a detail noncontrast CT (NCCT) followed by contrast study and CT angiography was performed. The NCCT showed a large expansile lytic lesion with cortical thinning and destruction involving the left ramus of mandible [Figure 3]. Contrast study showed an enhancing lesion with abnormal tuft of tortuous, dilated feeding vessels at the site of lesion [Figure 4]. The lesion

Access this article online

Quick Response Code:



Website:
www.jomfp.in

DOI:
10.4103/0973-029X.131930



Figure 1: Clinical photograph of the patient did not reveal any facial asymmetry

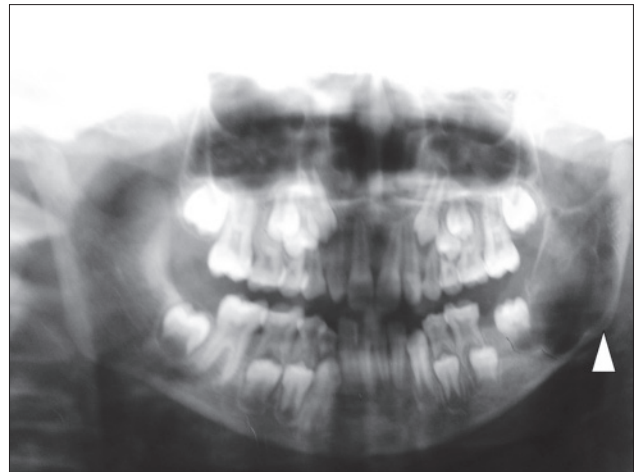


Figure 2: Orthopantomogram showing radiolucent lesion involving left mandibular ramus (white arrow head) with fine septations and soap bubble appearance

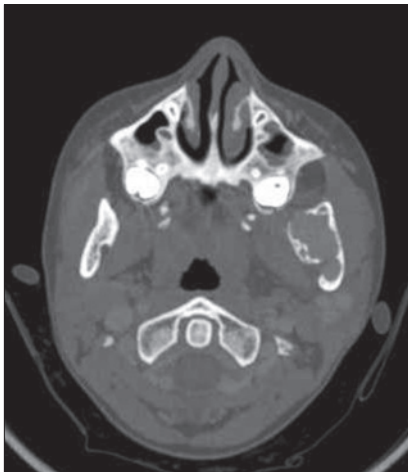


Figure 3: Noncontrast bone window settings showing expansile lytic lesion with cortical thinning involving the left mandibular ramus

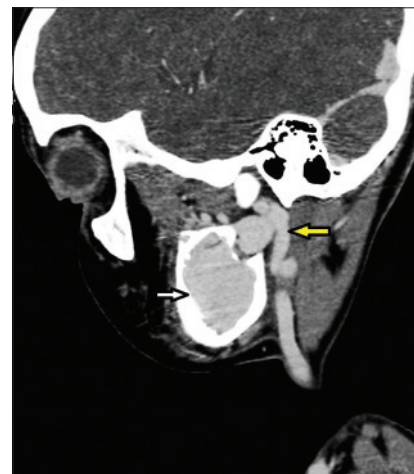


Figure 4: Sagittal reconstructed computed tomography image showing tortuous arterial feeders (yellow arrow) from left external carotid artery supplying the enhancing mandibular arteriovenous malformation (AVM; white arrow)

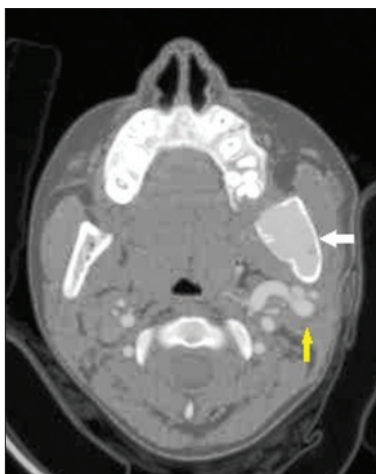

Figure 5: CT angiography axial image showing arterial feeders (yellow arrow) from external carotid and tortuous venous channels associated with enhancing AVM (white arrow)

was seen extending into left masticator space. On CT angiography, multiple arterial feeders to the lesion were seen originating from left external carotid artery with venous drainage into left external jugular vein [Figure 5]. Final diagnosis of left mandibular AVM was made.

DISCUSSION

Approximately 51% of vascular malformations occur in the head and neck region and the male-to-female ratio is 1:1.5.^[11] Extracranial AVMs of the head and neck are high-flow lesions and among the most serious of the vascular malformations because they are difficult to diagnose, treat and cure. The detection rate of AVM in the general population based on prospective data from the New York Islands study is approximately 1.34 per 100,000 persons.^[12] Death occurs in 10-15% of patients who have hemorrhage and morbidity of various degrees occurs in approximately 50%.^[13] Multiple imaging modalities should be used to evaluate characteristics of AVMs such as size, flow velocity, flow direction, relation to the surrounding structures and lesional contents.^[14] There are no pathognomonic radiographic features to distinguish AVMs on plain radiographs. They may appear as bone erosions, sclerotic changes, periosteal reactions or a cyst-like radiolucent lesions.

lesion. A sunburst effect, created by spicules radiating from the center, is often present.^[14] The radiographic differential diagnosis of these lesions includes ameloblastoma, ameloblastic fibroma, odontogenic myxoma, central giant cell granuloma and metastatic malignant tumors.^[10] Before performing a biopsy or surgery in a radiographically suspected case of ameloblastoma or aneurysmal bone cyst, especially in children, clinician should advise a contrast CT or MRI to rule out the possibility of an AVM to avoid sudden massive hemorrhage from the lesion and mortality and morbidity associated with it. Contrast-enhanced CT can be useful in assessing the AVMs. The drawbacks of CT are considerable exposure to ionizing radiation and limited information about blood flow.^[14] Angiography is currently the gold standard diagnostic aid for determination of location and flow characteristics of vascular lesions. Angiography is useful to determine blood vessels supplying blood to the lesion, the relative venous outflow characteristics and the presence or absence of arteriovenous shunts.^[11] Superselective arteriography remains an essential tool in the identification of an AVM and contributory vessels.^[15] Superselective angiography is an invasive procedure and not available everywhere. CT scanning and MRI are sufficient in most cases to clarify the extent of the lesion, bone erosion and involvement of major vessels, feeder artery and draining vein. It is also invaluable if superselective arteriography and embolization of main nutrient artery is planned.^[16] Due to the size and extent of the lesion in this patient and potential danger of hemorrhage, surgical intervention was advised as a choice of treatment after obtaining proximal and distal vascular control by transfemoral embolization. The patient's attendants refused any invasive procedure like arteriography and embolization and could not be convinced for any surgical intervention.

CONCLUSION

A radiograph showing lytic lesion resembling aneurysmal bone cyst or ameloblastoma in mandible in a child with history of gingival bleeding and no significant past history should raise a suspicion of mandibular AVM. The clinician should be aware of mandibular AVM before performing a biopsy, which may lead to torrential hemorrhage and even death of the patient. A preliminary CT angiography has an advantage of providing bony details along with status of feeder vessels of the lesion which is a prerequisite for surgery or endovascular intervention. Therefore, angiography remains the gold standard diagnostic aid in management of AVM.

REFERENCES

1. Waner M, Suen JY. Management of congenital vascular lesions of the head and neck. *Oncology (Williston Park)* 1995;9:989-94.
2. Higuera S, Gordley K, Metry DW, Stal S. Management of hemangioma and pediatric vascular malformations. *J Craniofac Surg* 2006;17:783-9.
3. Fathi M, Manafi A, Ghenaati H, Mohebbi H. Large arteriovenous high flow mandibular, malformation with exsanguinating dental socket haemorrhage: A case report. *J Craniomaxillofac Surg* 1997;25:228-31.
4. Anderson JH, Grissius RJ, McKean TW. Arteriovenous malformation of the mandible. *Oral Surg Oral Med Oral Pathol* 1981;52:118-25.
5. Lamberg MA, Tasanen A, Jääskeläinen J. Fatality from central hemangioma of the mandible. *J Oral Surg* 1979;37:578-84.
6. Jackson IT, Shaw K. Tumor of the craniofacial skeleton, including jaws. In: McCarthy JG, editor. *Plastic Surgery*. 1st edition. Philadelphia: WB Saunders; 1990.p. 3352-408.
7. Larsen PE, Peterson LJ. A systemic approach to management of high-flow vascular malformations of the mandible. *J Oral Maxillofac Surg* 1993;51:62-9.
8. Rodesch G, Soupre V, Vazquez MP, Alvarez H, Lasjaunias P. Arteriovenous malformations of the dental arcades: The place of endovascular therapy: Results in 12 cases are presented. *J Craniomaxillofac Surg* 1998;26:306-13.
9. Han MH, Seong SO, Kim HD, Chang KH, Yeon KM, Han MC. Craniofacial arteriovenous malformation: Preoperative embolization with direct puncture and injection of n-butyl cyanoacrylate. *Radiology* 1999;211:661-6.
10. Mohammadi H, Said-al-Naief NA, Heffez LB. Arteriovenous malformation of the mandible: Report of a case with a note on the differential diagnosis. *Oral Surg Oral Med Oral Pathol Oral Radiol Endod* 1997;84:286-9.
11. Nekooei S, Hosseini M, Nazemi S, Talaei-Khoei M. Embolisation of arteriovenous malformation of the maxilla. *Dentomaxillofac Radiol* 2006;35:451-5.
12. Stapf C, Mast H, Sciacca RR, Berenstein A, Nelson PK, Gobin YP, *et al.*, New York Islands AVM Study Collaborators. The New York Islands AVM Study: Design, study progress, and initial results. *Stroke* 2003;34:e29-33.
13. Weston-Schumacher H, Marshall R: Arteriovenous Malformations. *emedicine* 2010. Available from: <http://emedicine.medscape.com/article/1160167-overview> [Last accessed on Feb 2013].
14. Hyodoh H, Hori M, Akiba H, Tamakawa M, Hyodoh K, Hareyama M. Peripheral vascular malformations: Imaging, treatment approaches, and therapeutic issues. *Radiographics* 2005;25:S159-71.
15. van den Akker HP, Kuiper L, Peeters FL. Embolization of an arteriovenous malformation of the mandible. *J Oral Maxillofac Surg* 1987;45:255-60.
16. Johnson LM, Cook H, Friedlander A. Central arteriovenous malformations of the maxillofacial skeleton: Case report. *J Oral Maxillofac Surg* 1991;49:759-63.

How to cite this article: Dwivedi AD, Pandey A, Kumar I, Agarwal A. Mandibular arteriovenous malformation: A rare life-threatening condition depicted on multidetector CT angiography. *J Oral Maxillofac Pathol* 2014;18:111-3.

Source of Support: Nil. **Conflict of Interest:** None declared.