

# The Marriage of Sartorius and Tensor Fasciae Latae in Treating Vascular Prosthetic Graft Infections

Simone N. Zoepke, MBChB\*  
Louis de Weerd, MD, PhD†‡

**Background:** Vascular prosthetic graft infection in the groin is associated with high morbidity and mortality. This article presents a case series on the use of 2 flaps in the treatment of this condition.

**Methods:** Five patients, mean age 65 years (range, 49–74 years), with significant comorbidity were treated for an exposed and infected vascular prosthetic graft in the groin with a combination of sartorius muscle (SM) flap and tensor fascia lata (TFL) myocutaneous flap after debridement and start of microbiologic culture-guided antibiotic treatment. The SM flap was used to cover the exposed graft. To obtain stable wound coverage, the SM and remaining groin defect were closed with a pedicle TFL flap.

**Results:** All flaps survived, with only 1 TFL flap suffering a small tip necrosis. All patients obtained stable wound coverage. Donor-site morbidity was minimal. During the follow-up, mean 46 months (range, 15–79 months), 1 patient had a recurrence after 15 months due to a kink in the elongated prosthetic graft that protruded through the skin alongside the SM and TFL flaps.

**Conclusions:** The combination of SM and TFL flaps could be a new treatment option for patients who have an exposed and infected vascular prosthetic graft in the groin. This flap combination could also be used as a prophylactic procedure for those patients with a high risk to develop such a serious complication. (*Plast Reconstr Surg Glob Open* 2017;5:e1274; doi: 10.1097/GOX.0000000000001274; Published online 20 April 2017.)

## INTRODUCTION

Vascular prosthetic graft infections (VPGIs) are well known for their serious implications in limb salvage rate, patient mortality, and health-care costs.<sup>1–4</sup> The incidence of such infections ranges from 1% to 6%, statistics unchanged over the past 15 years.<sup>5–8</sup> The most common site for VPGI is the groin, most likely due to the high commensal and pathologic bacterial load within the immediate vicinity to the perineum and the close proximity of the prostheses to the skin and lymphatic vessels at risk of transection during surgery.<sup>1,9</sup> Vascular prosthetics implanted

in this area have been associated with a mortality rate of as high as 25%,<sup>10</sup> and recurrence of infection occurs in up to 35% of patients, even those subjected to extensive debridement and muscle flap transposition.<sup>11</sup>

At present, a number of accepted treatment options are used to manage an infected groin wound with an exposed vascular prosthetic graft. Traditional radical interventions focusing on the removal of the graft, extensive debridement, and vascular reconstructions are all procedures associated with mortality rates of 10–60% and limb loss as great as 80%.<sup>2,3,11,12</sup> There is a growing use of prosthesis-sparing interventions advocated, albeit in specific patients, namely systemic and local antibiotic infiltration, catheter irrigation and drainage, muscle flap transposition, and negative wound pressure therapy (NWPT), in variable combinations with one another.<sup>1,10,13–16</sup> Although NWPT has shown to be a valuable treatment option, there are situations where stable wound coverage cannot be obtained with such a modality alone. In a case report from 1979, Hill et al.<sup>17</sup> used a combination of sartorius muscle (SM) flap and tensor fascia lata (TFL) musculocutaneous

From the \*University of Pretoria, Pretoria, South Africa; †Department of Plastic and Reconstructive Surgery, University Hospital of North Norway, Tromsø, Norway; and ‡Medical Imaging Research Group, Department of Clinical Medicine, UiT The Arctic University of Norway, Tromsø, Norway.

Received for publication November 29, 2016; accepted February 1, 2017.

Copyright © 2017 The Authors. Published by Wolters Kluwer Health, Inc. on behalf of The American Society of Plastic Surgeons. This is an open-access article distributed under the terms of the Creative Commons Attribution-Non Commercial-No Derivatives License 4.0 (CCBY-NC-ND), where it is permissible to download and share the work provided it is properly cited. The work cannot be changed in any way or used commercially without permission from the journal.

DOI: 10.1097/GOX.0000000000001274

**Disclosure:** The authors have no financial interest to declare in relation to the content of this article. The Article Processing Charge was funded by a grant from the publication fund of UiT The Arctic University of Norway.

flap to cover the femoral vessels and close a groin wound after tumor resection. To our knowledge, there are no publications that report on this flap combination in the treatment of groin infections following arterial revascularization procedures. With their rich vascularity, muscle flaps enhance wound healing and assist in the elimination of residual infection.<sup>18</sup> In contrast to fasciocutaneous flaps, muscle flaps easily fill dead space. The SM flap transposition is a well-established technique used in the treatment of VPGI in the groin.<sup>1,3,4</sup> One of the drawbacks of the SM flap is its relative small volume. The SM flap may therefore be insufficient to provide stable wound coverage of a large remaining groin defect. The TFL flap transposition is a well-established technique for the closure of groin defects but not for the coverage of an infected and exposed vascular prosthetic graft.

In this article, we report our experience with the combination of a SM flap and TFL flap in the treatment of an infected and exposed vascular prosthetic graft with a large groin defect.

### MATERIALS AND METHODS

This study reports on 5 patients with an infected groin wound and exposed vascular prosthetic graft. Patient data are summarized in Table 1. All patients were classified according to the American Association of Anesthesiologists (ASA) as ASA III and had surgical histories including several operations involving debridement. Antibiotic treatment was based on wound cultures taken at the time of debridement. Three patients had also received NPWT using the Vacuum-assisted Closure System (VAC, KCI Medical, San Antonio, Tex.). Patients were referred to the Department of Plastic Surgery as it was unlikely to obtain stable wound coverage over the prosthetic graft with standard procedures.

#### Preoperative Planning

With the patient in the supine position, a line was drawn from the anterior superior iliac spine (ASIS) to the lateral aspect of the patella. The vascular pedicle supplying the TFL flap, the transverse branch of the lateral circumflex femoral artery, can be found 8–10 cm below the ASIS on this line and was identified using hand-held Doppler. The size of the flap must be of an adequate width and length to allow a tension-free closure of the groin defect after transposition. However, the cutaneous distal one-third of the TFL flap has an unreliable perfusion, a

fact that must be taken into account when planning the size of the flap.

#### Surgical Procedure

Under general anesthesia and with the patient in supine position, wound debridement was performed and cultures for microbiology were taken. The SM was identified and released from the ASIS, keeping a part of the tendon still attached to the muscle. The muscle was mobilized distally until it allowed for transposition without tension over the exposed vascular graft being careful to rotate in on its medial border to preserve its pedicle blood supply. A vacuum drain was placed over the vascular graft. The muscle and its fascia were sutured to the tissue surrounding the vascular graft with resorbable sutures. The TFL flap was harvested in a subfascial plane from distal to proximal and the pedicle was identified. The skin bridge between the groin defect and TFL donor site was incised to allow the TFL flap to be transposed over the SM and to close the remaining groin defect. The wound was closed in layers over a suction drain. NPWT was used during the first 5 postoperative days to stabilize the lateral suture line following transposition of the TFL flap.

### RESULTS

In all 5 patients, mean age 65 years (range, 49–74 years), the combined flap procedure resulted in stable wound coverage. The mean follow-up was 46 months (range, 15–79 months), with only 1 patient (case 2) having a recurrence at 15 months. Only 1 patient (case 3) had a small tip necrosis of the TFL flap that could be treated with a wound revision in local anesthesia.

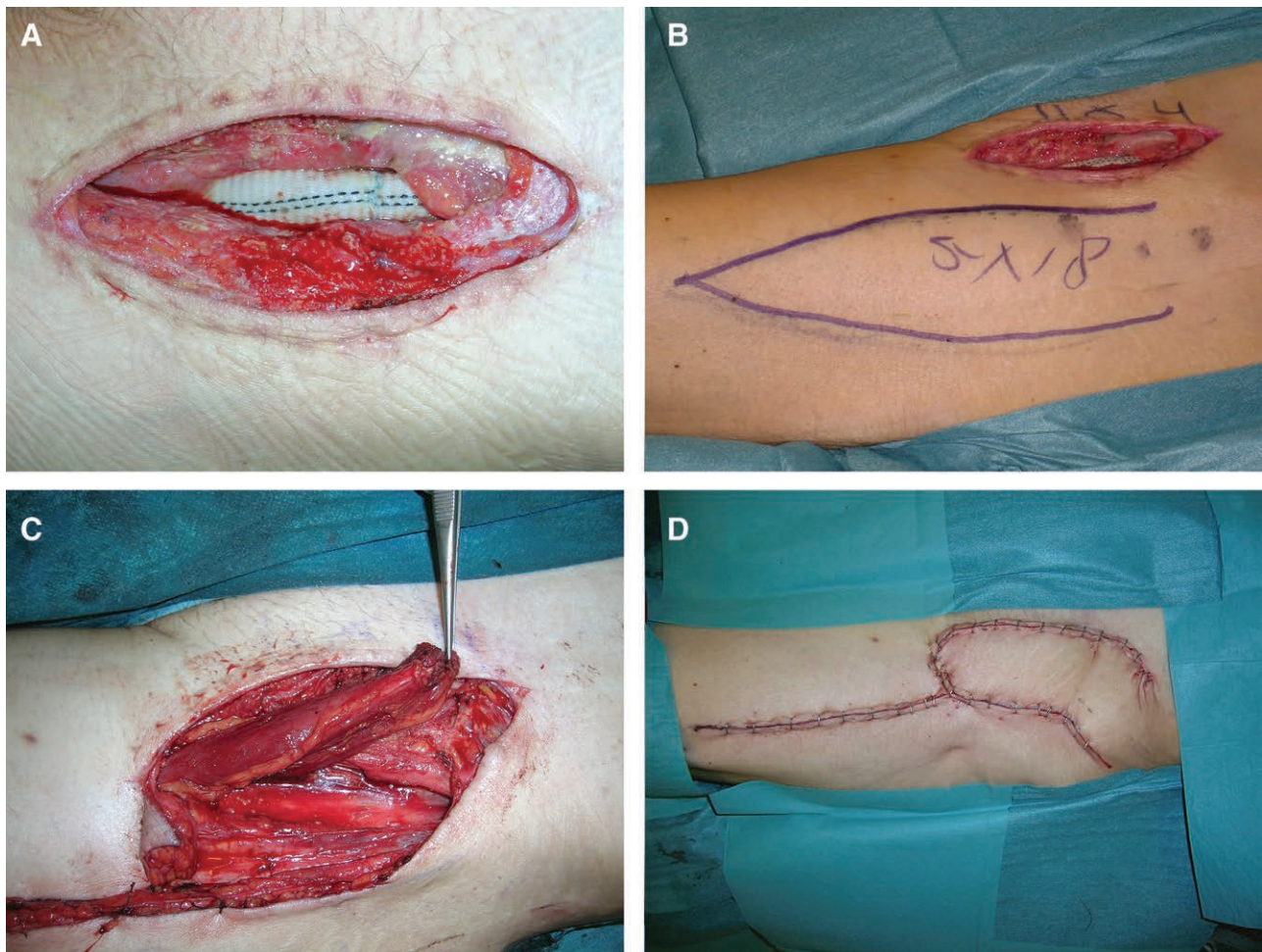
#### Case Presentation (Case 1)

A 49-year-old man with a history of arteriosclerosis, claudicatio intermittens, and cardiac transplantation had been operated on with an aorta bifemoral bypass. Six weeks after the bypass procedure, he developed an occlusion of the graft in the right groin. After an embolectomy, the wound was treated with VAC system for 7 days. The patient was referred to the Department of Plastic Surgery to obtain stable coverage over the exposed vascular prosthetic graft (Fig. 1A). Wound cultures revealed *Candida albicans*. In this immune-suppressed patient, a TFL flap of 18×5 cm was designed to obtain stable wound coverage of the groin wound and to contribute to lymphatic drainage of the groin region (Fig. 1B). Initially, the skin defect measured 11×4 cm and after debridement 12×8 cm. Transpo-

**Table 1. Patient Data**

Patient	Age (y)	Sex	ASA	Smoker (Yes/No)	MB	Graft	Vascular Surgery	NPWT (d)	Follow-up (mo)	Result
1	49	M	III	Y	CA	Dacron	ABF bypass	7	79	Good
2	74	M	III	Y	SE	Dacron	IF bypass	0	15	Recurrence
3	66	M	III	Y	CA	Goretex	AFF bypass	0	33	Good
4	61	F	III	Y	SA/SE	Goretex	FF crossover	6	58	Good
5	73	F	III	Y	SA/SC	Dacron	ABF bypass	6	43	Good

ASA, American Association of Anesthesiologists; ABF, aorto-bifemoral bypass; AFF, aorto-femoro-femoral; BMI, body mass index, kg/m<sup>2</sup>; CA, *Candida albicans*; FF, femoro-femoral; IF, iliaco-femoral; MB, microbiology; SA, *Staphylococcus aureus*; SE, *S. epidermis*; SC, *Streptococcus*.



**Fig. 1.** A, Exposed graft prosthesis. B, TFL flap design. C, SM flap transposition. D, End result.

sition of the SM over the graft (Fig. 1C) was followed by a TFL transposition (Fig. 1D). During the 79 months follow-up, there were no signs of wound problems in the groin.

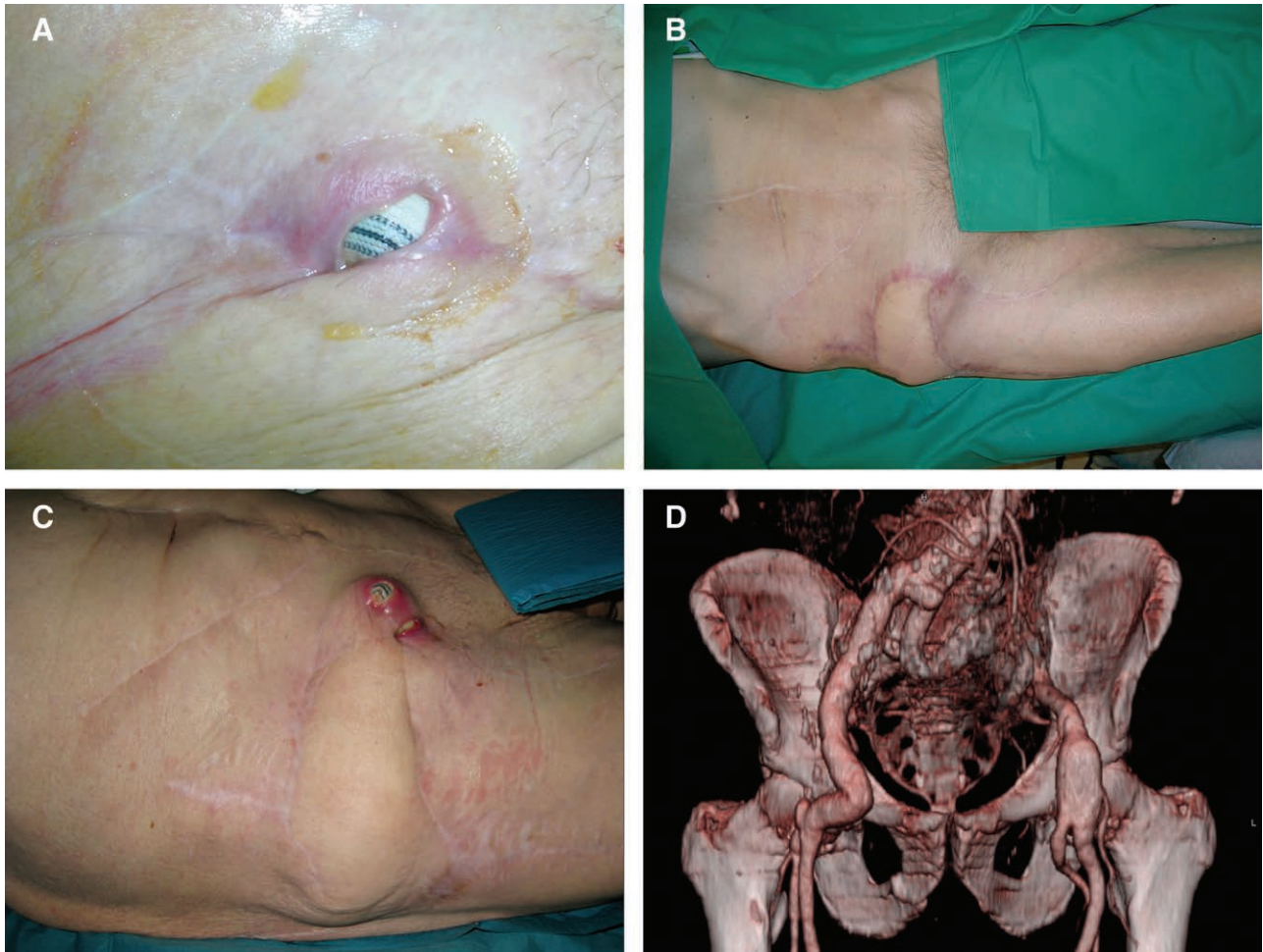
#### Case Presentation (Case 2)

A 73-year-old male, with a history of chronic obstructive lung disease and surgery for an abdominal aneurysm, developed a wound in the right groin with an infected and exposed Dacron graft after a bypass operation for an aneurysm in the iliac communis artery (Fig. 2A). Following debridement, the vascular graft was covered with a combined SM flap and TFL flap (Fig. 2B). After 15 months, he was readmitted, presenting with the graft protruding alongside the SM and TFL flap through the skin (Fig. 2C). Clinical examination and CT scan investigation revealed a kink in the elongated graft directed toward the skin (Fig. 2D). The vascular graft was shortened, and both the SM and TFL flap could be used again for coverage. However, after 4 months, the graft had to be removed due to a new recurrence. A bypass from the left internal iliac artery to the right superficial and deep femoral artery was successfully created and both the SM and TFL flaps were again used to cover the arterial reconstruction in the groin. The patient died after 4 years from bacterial pneumonia.

#### DISCUSSION

With an increasing number of vascular graft procedures being performed each year, the incidence of prosthetic graft infections has remained 1–6%,<sup>1,5–8</sup> with some series reporting incidences closer to 5–10%.<sup>5</sup>

One of the newest modalities in graft preserving interventions is the use of NWPT. Its noninvasive nature makes it a reasonable therapeutic option to consider before more drastic measures are attempted.<sup>10,11,15,19,20</sup> It has been reported that the use of NWPT without the utilization of muscle flap transposition has resulted in a success rate of 75%.<sup>21</sup> There is, however, controversy with regard to the effects of NWPT that must be noted. Mouës et al.<sup>21</sup> and Weed et al.<sup>22</sup> found that bacterial count was not significantly affected with the use of NWPT; this results in direct contrast with the series by Pinocy et al.<sup>10</sup> and Morikwas et al.<sup>23</sup> Despite these inconsistencies, it must be said that without the use of antimicrobials, NWPT has a similar effect on bacterial load as conventional therapies.<sup>18</sup> There have been a few drawbacks reported related to NWPT. Kotsis and Lioupis<sup>19</sup> and Demaria et al.<sup>24</sup> noted a case of deep vein thrombosis at the application site that required treatment with anticoagulants and discontinua-



**Fig. 2.** A, Protrusion of the prosthesis through the skin. B, Result at 10 months after reconstruction. C, Recurrence at 15 months. D, Computer tomography scan with kink in prosthesis.

tion of NWPT. In the presence of an exposed anastomosis, there have been reports of disrupted sutures, eroded vasculature, and arterial bleeding<sup>25,26</sup>; however, Mayer et al.<sup>27</sup> reported on the use of NWPT directly adjacent to the prosthesis without resulting in complications and with a 100% success rate and no recurrent infection. Svensson et al.<sup>15</sup> reported a higher risk of amputation and death in persistent VPGI managed with NWPT. Generally, hospital admission time is increased in those with NWPT devices and the numerous operations to change the device repeatedly exposing patients to detrimental results like bleeding and reinfection. Although numerous series have advocated the use of NWPT in place of other modalities under certain circumstances,<sup>10,11,18,26</sup> there are times when such an approach fails and other therapies must be sought.<sup>11,28</sup>

In 3 of our 5 patients, NWPT was used. The defects following NWPT in these patients were too large to be closed by secondary intention. Wide undermining would have caused impaired circulation of the skin flaps and an unacceptable high risk of wound rupture at a suture line positioned right over the prosthetic graft. However, we observed that NWPT had reduced the complex 3-dimensionality of the wounds. The wound surfaces became more

uniform, which allowed for a better contact with a well-vascularized flap surface area. In the other 2 patients, the exposed vascular prosthetic graft was positioned at skin level and was surrounded by skin and subcutaneous tissue of inferior quality. In all 5 patients, a muscle flap transposition was required to obtain stable wound coverage over the exposed vascular prosthesis. However, the remaining wound defects were too large to be closed by skin approximation, even after undermining. Coverage of the remaining defect with a skin graft has a significant disadvantage as a skin graft is far less elastic and stable compared with normal skin, which adapts easily to the movements in the groin.

The use of a variety of different muscle flaps has been advocated in a number of publications.<sup>1,3,4,12-14,17,29-31</sup> The advantages of muscle flaps are numerous and include increased blood supply to the operated area, bringing with it oxygen, nutrients, leukocytes, and systemic antibiotics.<sup>4</sup> The dead space left after extensive debridement of necrotic tissue can be filled by the patient's own tissue, reducing the risk for potential complications and recurrent infections.<sup>30</sup> In the groin, a number of muscle flaps have been described for the purpose of filling inguinal defects and covering the exposed vascular graft. The SM

flap is the most common muscle flap used due to its accessibility, retention of its shape, and ease of transposition.<sup>32</sup> Although many advocate its use, there is some hesitancy associated with its use in conjunction with vasculopathy of the superficial femoral artery.<sup>24</sup> There are conflicting data with regard to the muscle's arterial supply; Mathes and Nahai<sup>33</sup> defined it as a type 4 segmental circulatory pattern dependent on the superficial femoral artery, in comparison to Ramasastry et al.<sup>34</sup> who described its primary blood supply from the circumflex femoral vessels of the deep femoral artery. Those who support the notion of a type 4 segmental supply remain cautious using the muscle in circumstances where the superficial femoral vessel is compromised. However, in a study by Töpel et al.,<sup>13</sup> a sample group of 53 patients with 56 SM flap transpositions were observed for flap viability, 23 of which had patent superficial femoral arteries and 33 were occluded. The deep femoral artery was classified as patent in all 56 cases. After an average follow-up time of 6.4 months, 54 viable flaps were documented. Much like Ramasastry et al.,<sup>34</sup> Töpel et al.<sup>13</sup> proposed that the patency of the superior femoral artery has little to do with flap viability, provided the deep femoral artery remains open and undiseased. In all the 5 of our patients, a viable SM flap could be harvested.

A con of using the SM in isolation is its size and inability to fill larger groin defects.<sup>12</sup> With this problem in mind, the use of the TFL muscle flap can be used in conjunction to provide a second layer of tissue overlying the defect. The TFL muscle originates lateral to the SM on the anterolateral aspect of the iliac crest. It derives its blood supply from the lateral circumflex nutrient artery, well documented for its reliability and consistency.<sup>35–37</sup> Traditionally, the flap is used for abdominal and trochanteric defects,<sup>38–41</sup> and generally its use is associated with little donor-site morbidity and loss of function. It is reported that the “safe dimensions” for the flap extends from the pedicle artery to 8–10 cm above the knee and should be no wider than 15 cm<sup>29,42</sup>; however, Saito et al.<sup>43</sup> required skin grafts to primarily close all 9 donor sites in their study, despite the flap being less than 10 cm in some of their patients. In our own study, all donor sites were primarily closed without the need of skin grafts. Generally, if the flap is less than 9 cm wide, the donor site can be closed directly without the use of a skin graft. Kim et al.<sup>39</sup> reported on their use of the TFL in coverage of large trochanteric pressure sores. A limitation identified in their study was the instability of the T junction where the middle of the TFL flap met the donor site. Aslan et al.<sup>44</sup> reported similar findings. In an attempt to avoid wound dehiscence, all 5 patients in our study were treated with NPWT postoperatively to allow splinting of the surgical site at the points of inadvertent tension. The TFL flap has been criticized for its bulkiness and short vascular pedicle, 2 characteristics we use to our advantage.<sup>35,36</sup> Like the SM flap, the TFL flap is in close proximity to the groin and thus a shorter pedicle flap needing minimal rotation can be used, thus reducing risk of nerve and pedicle impingement and allowing for primary closure without tension or dog-ear formation. The combination of SM and TFL flaps has several advantages. The SM flap provides coverage of the prosthetic

graft with well-vascularized tissue, whereas the TFL flap provides a tension-free and stable wound coverage of the groin defect over the SM flap. The TFL flap has a strong supporting fascial layer, and the elastic skin of the flap tolerates the mobility in the groin far better than a skin graft over the SM flap. Another possible advantage of the TFL flap could be its contribution on lymphatic drainage. Slavin et al.<sup>45</sup> showed in an experimental animal model how muscle transposition restored lymphatic continuity and could be used to prevent the development of lymphedema. In a series of case reports, Parrett et al.<sup>46</sup> successfully used the contralateral musculocutaneous rectus abdominis flap to treat lower extremity lymphedema. Shermak et al.<sup>2</sup> reported on the resolution of lymphoceles after arterial bypass surgery using different muscle flaps, although no TFL flap was used. Microscopic examination of a biopsy specimen of a healed gracilis muscle flap taken 1 year after surgery revealed a histological result consistent with multiple lymphatic channels. The TFL flap in our case series could also serve as a conduit for lymph flow through the groin. The cutaneous pedicle to the TFL flap was left intact to optimize lymph flow through the dermal lymphatics.

There are a kaleidoscope of complications associated with groin wounds such as cellulitis, hematomas, lymphorrhea, sepsis, and amputation, especially in those with comorbidities like diabetes, obesity, smoking history, and prosthetic graft reconstruction. With this in mind, it is reasonable to consider preempting such health implications and thus saving time and capital and reducing morbidity and the need for secondary flap transpositions. In the report by Fischer et al.,<sup>47</sup> 68 prophylactic muscle flap procedures were performed in 53 patients before complications arose and were compared with the rate of complications in 195 open vascular groin surgeries in 178 patients. The results, although limited by possible selection bias and lack of a selection algorithm and randomized trial, reaped significant information regarding the procedure. It was found that the risk of complications increased 3.5 times in patients having reoperative surgery without prophylactic flaps, and those undergoing reoperation with a prosthesis implant had an increase of 7 times. Similarly, May et al.<sup>48</sup> built on Fischer's data by qualifying that the early use of muscle flap coverage for exposed infected vascular grafts improved the rate of graft salvage, with the sartorius being described as the best option in prophylactic procedures. Lastly, Saito et al.<sup>43</sup> described their experience with 3 patients in their series subjected to wide tumor excision in the vicinity of the femoral vessels requiring vascular grafting. A combined TFL pedicle flap was used to recreate the soft tissue and skin over the vessels. Two of the patients died, 1 on the day following the operation from causes unknown and one 20 months after the operation due to tumor recurrence and femoral occlusion complicated by sepsis. The third patient was followed up 30 months later with no reported infection. With these cases in mind, the prophylactic use of the combination of SM and TFL flaps could be a valuable option in patients with high risk for wound complications following an arterial revascularization procedure.

## CONCLUSIONS

Our study has some limitations due to its small number of patients, its retrospective character, and lack of a comparative group. Because of the small size, our results are indicative and should be interpreted within the context of this limitation. On the other hand, our group of patients was a selected group with considerable comorbidity and was characterized by having a complex defect in the groin with an infected and exposed vascular prosthetic graft. Our small series has a mean follow-up of 45 months, with only 1 recurrence after 15 months. The SM and TFL flaps could be used again at the reoperation. A larger assessment of the combined use of the sartorius and TFL muscle flaps is needed to expand on our ideas and build a more solid argument for their use in the clearance of infection and healing of vascular graft operation sites.

Louis de Weerd, MD, PhD

Department of Plastic and Reconstructive Surgery  
Sykehusveien 38  
University Hospital North Norway  
9038 Tromsø, Norway  
E-mail: louis.deweerd@unn.no

## STATEMENT OF CONFORMITY

*This study was conducted in compliance with the recognized international standards and the principles of the Declaration of Helsinki. The information in this article has not been published elsewhere in any form.*

## REFERENCES

- Williams IM, Milling MA, Shandall AA. Vascularised muscular flaps and arterial graft infection in the groin. *Eur J Vasc Endovasc Surg.* 2003;25:390–395.
- Shermak MA, Yee K, Wong L, et al. Surgical management of groin lymphatic complications after arterial bypass surgery. *Plast Reconstr Surg.* 2005;115:1954–1962.
- Armstrong PA, Back MR, Bandyk DF, et al. Selective application of sartorius muscle flaps and aggressive staged surgical debridement can influence long-term outcomes of complex prosthetic graft infections. *J Vasc Surg.* 2007;46:71–78.
- Petrasek PF, Kalman PG, Martin RD. Sartorius myoplasty for deep groin wounds following vascular reconstruction. *Am J Surg.* 1990;160:175–178.
- Bandyk DF. Vascular surgical site infection: risk factors and preventive measures. *Semin Vasc Surg.* 2008;21:119–123.
- Hicks RC, Greenhalgh RM. The pathogenesis of vascular graft infection. *Eur J Vasc Endovasc Surg.* 1997;14 Suppl A:5–9.
- Antonios VS, Noel AA, Steckelberg JM, et al. Prosthetic vascular graft infection: a risk factor analysis using a case-control study. *J Infect.* 2006;53:49–55.
- Tatterton MR, Homer-Vanniasinkam S. Infections in vascular surgery. *Injury.* 2011;42 Suppl 5:S35–S41.
- Szilagyi DE, Smith RF, Elliott JP, et al. Infection in arterial reconstruction with synthetic grafts. *Ann Surg.* 1972;176:321–333.
- Pinocoy J, Albes JM, Wicke C, et al. Treatment of periprosthetic soft tissue infection of the groin following vascular surgical procedures by means of a polyvinyl alcohol-vacuum sponge system. *Wound Repair Regen.* 2003;11:104–109.
- Dosluoglu HH, Schimpf DK, Schultz R, et al. Preservation of infected and exposed vascular grafts using vacuum assisted closure without muscle flap coverage. *J Vasc Surg.* 2005;42:989–992.
- Landry GJ, Carlson JR, Liem TK, et al. The sartorius muscle flap: an important adjunct for complicated femoral wounds involving vascular grafts. *Am J Surg.* 2009;197:655–659; discussion 659.
- Töpel I, Betz T, Uhl C, et al. The impact of superficial femoral artery (SFA) occlusion on the outcome of proximal sartorius muscle transposition flaps in vascular surgery patients. *J Vasc Surg.* 2011;53:1014–1019.
- Seify H, Moyer HR, Jones GE, et al. The role of muscle flaps in wound salvage after vascular graft infections: the Emory experience. *Plast Reconstr Surg.* 2006;117:1325–1333.
- Svensson S, Monsen C, Kölbl T, et al. Predictors for outcome after vacuum assisted closure therapy of peri-vascular surgical site infections in the groin. *Eur J Vasc Endovasc Surg.* 2008;36:84–89.
- Mayer D, Hasse B, Koelliker J, et al. Long-term results of vascular graft and artery preserving treatment with negative pressure wound therapy in Szilagyi grade III infections justify a paradigm shift. *Ann Surg.* 2011;254:754–759; discussion 760.
- Hill HL, Hester R, Nahai F. Covering large groin defects with the tensor fascia lata musculocutaneous flap. *Br J Plast Surg.* 1979;32:12–14.
- Mathes SJ, Feng LJ, Hunt TK. Coverage of the infected wound. *Ann Surg.* 1983;198:420–429.
- Kotsis T, Lioupis C. Use of vacuum assisted closure in vascular graft infection confined to the groin. *Acta Chir Belg.* 2007;107:37–44.
- Calligaro KD, Veith FJ, Sales CM, et al. Comparison of muscle flaps and delayed secondary intention wound healing for infected lower extremity arterial grafts. *Ann Vasc Surg.* 1994;8:31–37.
- Mouës CM, Vos MC, van den Bemd CJ, et al. Bacterial load in relation to vacuum-assisted closure wound therapy: a prospective randomized trial. *Wound Repair Regen.* 2004;12:11–17.
- Weed T, Ratliff C, Drake DB. Quantifying bacterial bioburden during negative pressure wound therapy: does the wound VAC enhance bacterial clearance? *Ann Plast Surg.* 2004;52:276–279; discussion 279.
- Morykwas MJ, Argenta LC, Shelton-Brown EI, et al. Vacuum assisted closure: a new method for wound control and treatment: animal studies and basic foundation. *Ann Plast Surg.* 1997;38:553–562.
- Demaria RG, Giovannini UM, Téot L, et al. Topical negative pressure therapy. A very useful new method to treat severe infected vascular approaches in the groin. *J Cardiovasc Surg (Torino).* 2003;44:757–761.
- White RA, Miki RA, Kazmier P, et al. Vacuum-assisted closure complicated by erosion and hemorrhage of the anterior tibial artery. *J Orthop Trauma.* 2005;19:56–59.
- Dosluoglu HH, Loghmanee C, Lall P, et al. Management of early (<30 day) vascular groin infections using vacuum-assisted closure alone without muscle flap coverage in a consecutive patient series. *J Vasc Surg.* 2010;51:1160–1166.
- Mayer DO, Enzler M, Inderbitzi R, et al. Vacuum-assisted closure system with direct contact to native arteries and/or vascular grafts to improve the outcome of perivascular infection (abstract). Available at <http://www.veithsymposium.org/veithpdf2005/87.pdf>. Accessed 2016 January 12.
- Lesser T. Rectus femoris and sartorius muscle flap for graft infection in the groin. *J Vasc Med Surg.* 2015;S1:005.
- Rifaat MA, Abdel Gawad WS. The use of tensor fascia lata pedicled flap in reconstructing full thickness abdominal wall defects and groin defects following tumor ablation. *J Egypt Natl Canc Inst.* 2005;17:139–148.
- Graham RG, Omotoso PO, Hudson DA. The effectiveness of muscle flaps for the treatment of prosthetic graft sepsis. *Plast Reconstr Surg.* 2002;109:108–113; discussion 114.
- Illig KA, Alkon JE, Smith A, et al. Rotational muscle flap closure for acute groin wound infections following vascular surgery. *Ann Vasc Surg.* 2004;18:661–668.

32. Morasch MD, Sam AD 2nd, Kibbe MR, et al. Early results with use of gracilis muscle flap coverage of infected groin wounds after vascular surgery. *J Vasc Surg.* 2004;39:1277–1283.
33. Mathes SJ, Nahai F. *Reconstructive Surgery: Principles, Anatomy and Techniques.* New York: Churchill Livingstone Inc; 1997.
34. Ramasastry SS, Liang MD, Hurwitz DJ. Surgical management of difficult wounds of the groin. *Surg Gynecol Obstet.* 1989;169:418–422.
35. Kim JT, Kim YH, Naidu S. Perfecting the design of the gluteus maximus perforator-based island flap for coverage of buttock defects. *Plast Reconstr Surg.* 2010;125:1744–1751.
36. Koshima I, Urushibara K, Inagawa K, et al. Free tensor fasciae latae perforator flap for the reconstruction of defects in the extremities. *Plast Reconstr Surg.* 2001;107:1759–1765.
37. Coskunfirat OK, Ozkan O. Free tensor fascia lata perforator flap as a backup procedure for head and neck reconstruction. *Ann Plast Surg.* 2006;57:159–163.
38. Lv Y, Cao D, Guo F, et al. Abdominal wall reconstruction using a combination of free tensor fasciae lata and anterolateral thigh myocutaneous flap: a prospective study in 16 patients. *Am J Surg.* 2015;210:365–373.
39. Kim YH, Kim SW, Kim JT, et al. Tensor fascia lata flap versus tensor fascia lata perforator-based island flap for the coverage of extensive trochanteric pressure sores. *Ann Plast Surg.* 2013;70:684–690.
40. DeFazio MV, Economides JM, Felder JM 3rd, et al. The U-shaped tensor fasciae latae musculocutaneous flap for coverage of trochanteric defects: simplified design to minimize donor-site morbidity. *Plast Reconstr Surg.* 2015;136:288e–90e.
41. Han BL, Choi HJ. Free-style dual plane recycling tensor fascia lata musculocutaneous perforator flap for reconstruction of recurrent trochanteric defects. *Int J Low Extrem Wounds.* 2014;13:72–75.
42. Safak T, Klebuc MJ, Keçik A, et al. The subcutaneous pedicle tensor fascia lata flap. *Plast Reconstr Surg.* 1996;97:765–774.
43. Saito A, Minakawa H, Saito N, et al. Clinical experience using a tensor fascia lata flap in oncology patients. *Surg Today.* 2014;44:1438–1442.
44. Aslan G, Tuncali D, Bingul F, et al. The “duck” modification of the tensor fascia lata flap. *Ann Plast Surg.* 2005;54:637–639.
45. Slavin SA, Van den Abbeele AD, Losken A, et al. Return of lymphatic function after flap transfer for acute lymphedema. *Ann Surg.* 1999;229:421–427.
46. Parrett BM, Sepic J, Pribaz JJ. The contralateral rectus abdominis musculocutaneous flap for treatment of lower extremity lymphedema. *Ann Plast Surg.* 2009;62:75–79.
47. Fischer JP, Nelson JA, Mirzabeigi MN, et al. Prophylactic muscle flaps in vascular surgery. *J Vasc Surg.* 2012;55:1081–1086.
48. May BL, Zelenski NA, Daluvoy SV, et al. Salvage of exposed groin vascular grafts with early intervention using local muscle flaps. *Plast Reconstr Surg Glob Open.* 2015;3:e514.