

# Subtotal Nasal Reconstruction after Traumatic Avulsion

Christopher L. Kalmar, MD, MBA\*; Phuong D. Nguyen, MD†; Jesse A. Taylor, MD\*

## INTRODUCTION

Each year, patients in the U.S. suffer nearly 4.5 million dog bites nationwide.<sup>1</sup> Dog bites can result in puncture wounds, lacerations, and avulsions<sup>2</sup> (Fig. 1). Tissue pressure inflicted by dog bites can reach up to 100 kg per square centimeter,<sup>3</sup> which also imparts crush injuries that continue to demarcate after the injury. Facial dog bites most commonly affect the upper lip, cheek, nose, and lower lip.<sup>4</sup> The nasal tip is most frequently injured, followed by the dorsum and nasal root.<sup>5</sup>

Dog bites to the nose often involve multiple subunits.<sup>6</sup> Burget and Menick championed the subunit principle,<sup>7</sup> but the authors have recently challenged this concept with exceptionally large dog bites.<sup>8</sup> Full-thickness nasal defects can be challenging, given the importance of appropriately reconstructing the trilaminar architecture of the nose to include mucosal lining, osseo-cartilaginous structural support, and cutaneous coverage<sup>9,10</sup> (Fig. 2). Given the uncommon presentation of these injuries, there are no clear guidelines for the management of traumatic nasal amputations.<sup>6,9,11</sup>

## TIMING

Timing of repair is somewhat controversial, but most recent literature advocates for immediate reconstruction when possible.<sup>12</sup> There are several authors who utilized the paramedian forehead flap immediately after nose injuries with successful results.<sup>11,13,14</sup> However, this approach must be qualified and is only applicable to non-complicated wounds.<sup>12</sup> If there is extensive soft tissue injury, evolving soft tissue ischemia, or gross contamination, it may be preferable to delay reconstruction until there is a more definitive understanding of the defect.<sup>12</sup>

## PREOPERATIVE MARKING

Design of the paramedian forehead flap began with Doppler identification of the supratrochlear pedicle, which became the center of a 17-mm wide proximal

portion of the flap. (See Video [online], which displays the authors' technique for nasal reconstruction after traumatic injury; Exhibit A). Aluminum foil template for the subtotal nose defect was used to stencil the flap dimensions, and the decision regarding which side of the forehead to utilize was based on minimizing the arc of rotation of the flap pedicle. (See Video Exhibit B [online].)

## INTRANASAL LINING

Nasal lining is arguably the most technically important yet underappreciated aspect of nasal reconstruction.<sup>9</sup> Nasal lining can be achieved by advancing residual nasal vestibular lining, turnover flaps, septal rotation flaps, and free flaps. We elected to use a radial forearm flap in this case because of the large size of the defect, lack of sufficient intra-nasal mucosal lining flaps, and multiple scarred surrounding soft tissues. The radial forearm free flap

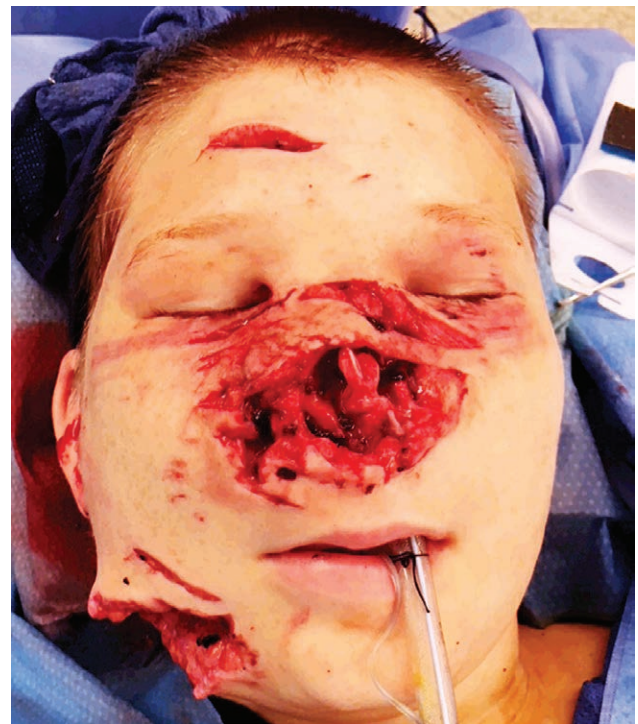

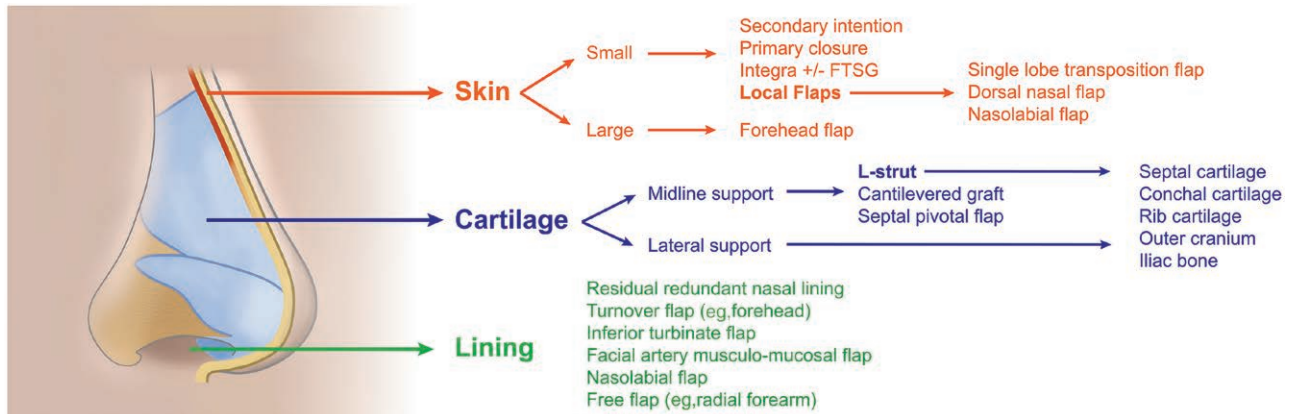
Fig. 1. Preoperative demonstration of nasal avulsion after dog bite.

From the \*Children's Hospital of Philadelphia, Philadelphia, Pa.; and †Division of Plastic Surgery, University of Texas, Houston, Tex. Received for publication September 17, 2020; accepted September 17, 2020.

Copyright © 2020 The Authors. Published by Wolters Kluwer Health, Inc. on behalf of The American Society of Plastic Surgeons. This is an open-access article distributed under the terms of the Creative Commons Attribution-Non Commercial-No Derivatives License 4.0 (CCBY-NC-ND), where it is permissible to download and share the work provided it is properly cited. The work cannot be changed in any way or used commercially without permission from the journal. *Plast Reconstr Surg Glob Open* 2020;8:e3239; doi: 10.1097/GOX.0000000000003239; Published online 24 November 2020.

**Disclosure:** The authors have no financial or nonfinancial conflicts of interest to disclose.

Related Digital Media are available in the full-text version of the article on [www.PRSGlobalOpen.com](http://www.PRSGlobalOpen.com).



**Fig. 2.** Diagram illustrating the reconstructive options after traumatic nasal avulsion.

utilized a folding pattern similar to that popularized by Menick,<sup>15</sup> with a resorbable poly-l-lactic acid plate for support of the dorsum and skin graft of the under-surface of the flap. Nasal stents were utilized until definitive external nasal reconstruction.

After 4 months, this flap was thinned by removing the deep (now superficial) aspects of the flap, relying on local ingrowth of vasculature to support the remaining nasal lining. (See Video Exhibit C [online].) Tunnels were made to osseous elements of the midface to inset the cartilaginous pyramid of the nose. (See Video Exhibit D [online].)

### CARTILAGE SCAFFOLD

The thoracic cage is one of the most abundant donor sites for cartilage and bone. Cartilage reconstruction can be achieved with composite grafts from the auricle to provide lining and cartilage at the ala,<sup>3</sup> but a larger reconstruction of the dorsum necessitates septal or costal cartilage harvest. Many surgeons elect to delay cartilage reconstruction, given the theoretical risk of contaminating the graft.<sup>6,11</sup> This will result in temporary nasal valve collapse, necessitating the use of nasal conformers until definitive structural reconstruction can be safely performed.<sup>11</sup> Currently, there is no conclusive evidence for whether acute cartilage grafts can be safely implemented during the first stage.<sup>11</sup> Given the extent of injury and contamination, we elected to delay extensive cartilage grafting until we were able to achieve a cleaner wound area and maturation of the radial forearm free flap.

In this case, the cartilaginous portion of the right 6th and 7th ribs was harvested. (See Video Exhibit E [online].) Valsalva maneuver did not demonstrate evidence of pneumothorax, and thus a layered closure of the chest was performed. We temporarily left this incision open in the subcutaneous plane for potential banking of unused bits of cartilage, so that these could be utilized during future revisions. In this case, we elected to include an L-shaped graft extending from the nasofrontal junction to the anterior nasal spine, bilateral alar battens, and a thick Sheen tip graft. The cartilage grafts were designed and carved on a backtable and then

sewn to the nasal and maxillary soft tissues. (See Video Exhibit F [online].) The forehead flap was then ready to be designed, harvested, and sewn into position over the cartilaginous construct.

### CUTANEOUS COVERAGE

The team recognized pre-operatively that the degree of soft tissue destruction was asymmetric with regard to the cheeks. Thus, the surgery began by reconstructing the medial aspect of the left cheek subunit by a rotation-advancement flap that was fixated in a supero-medial position, thereby obliterating the defect in the medial cheek. (See Video Exhibit G [online].)

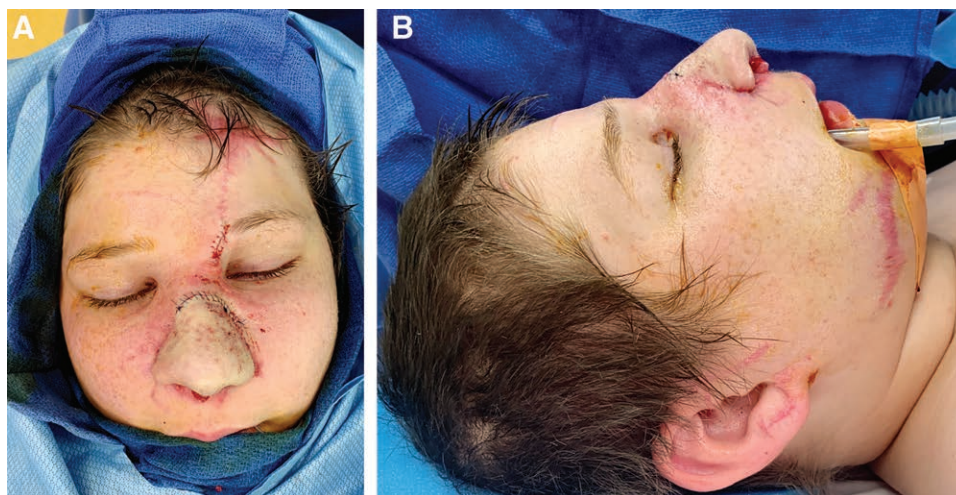Forehead flaps are ideal, given their superb color and texture match with nasal skin, low infection risk, and low rate of complications.<sup>14,16</sup> Downsides of the forehead flap are the need for additional thinning in a subsequent procedure,<sup>9,17</sup> and the need for pedicle separation at a separate stage.<sup>6,8,9</sup>

The paramedian forehead flap from the left side of the forehead was then cut. (See Video Exhibit H [online].) The distal third of the flap was dissected free in the subcutaneous plane, the middle third of the flap was dissected free in the submuscular plane, and the proximal third was dissected free in the subperiosteal plane. The forehead flap was then rotated and sewn into position. (See Video Exhibit I [online].) The forehead was undermined in the subcutaneous plane and underwent a layered closure. (See Video Exhibit J [online].)

Three weeks after the initial forehead flap reconstruction, the patient underwent a secondary thinning procedure. Four weeks after that stage, the pedicle was divided and inset (Fig. 3).

### CONCLUSIONS

This multimedia demonstration highlights key technical details for nasal reconstruction. In the setting of significant contamination and evolving ischemia, nasal avulsion can be conservatively managed with staged procedures to safely and reliably achieve successful restoration of structure and function.



**Fig. 3.** Postoperative demonstration after the course of reconstructive procedures. (A) Frontal view. (B) Right lateral view.

*Jesse A. Taylor, MD*

Division of Plastic and Reconstructive Surgery  
Children's Hospital of Philadelphia  
3401 Civic Center Blvd  
Philadelphia, PA 19104  
E-mail: jataylor@gmail.com

### ACKNOWLEDGMENT

*Institutional Review Board approval was not required for this case series.*

### PATIENT CONSENT

*Consent from the parent was obtained for publication of identifiable patient information.*

### REFERENCES

- Weiss HB, Friedman DI, Coben JH. Incidence of dog bite injuries treated in emergency departments. *JAMA*. 1998;279:51–53.
- Yadav AK, Jaisani MR, Pradhan L, et al. Animal inflicted maxillofacial injuries: treatment modalities and our experience. *J Maxillofac Oral Surg*. 2017;16:356–364.
- Goldman A, Wollina U. Dog bite injury – alar repair with composite graft. *Wien Med Wochenschr*. 2018;168:261–264.
- Piccart F, Dormaar JT, Coropciuc R, et al. Dog bite injuries in the head and neck region: a 20-year review. *Craniofacial Trauma Reconstr*. 2019;12:199–204.
- Stucker FJ, Hoasjoe DK. Soft tissue trauma over the nose. *Facial Plast Surg*. 1992;8:233–241.
- Cerne JW, Rock AN, Smith SW, et al. A novel approach for treating nasal dog bite injury. *Ear Nose Throat J*. 2019;98:76–77.
- Burget GC, Menick FJ. The subunit principle in nasal reconstruction. *Plast Reconstr Surg*. 1985;76:239–247.
- Senturk E, Dagistanli N, Calim OF, et al. Nasal reconstruction following a dog bite. *J Craniofac Surg*. 2019;30:2233–2235.
- Cantarella G, Mazzola RF, Pagani D. The fate of an amputated nose after replantation. *Am J Otolaryngol*. 2005;26:344–347.
- Tiengo C, Amabile A, Azzena B. The contribution of a dermal substitute in the three-layers reconstruction of a nose tip avulsion. *J Plast Reconstr Aesthet Surg*. 2012;65:114–117.
- Huang AH, Wong MS. Acute nasal reconstruction with forehead flap after dog bite. *Ann Plast Surg*. 2013;70:401–405.
- Ramachandra T, Ries WR. Management of nasal and perinasal soft tissue injuries. *Facial Plast Surg*. 2015;31:194–200.
- Ahmadi Moghadam M, Ahmadi Moghadam S. Use of forehead flap for nasal tip reconstruction after traumatic nasal amputation. *World J Plast Surg*. 2017;6:361–364.
- Shipkov H, Traikova N, Stefanova P, et al. The forehead flap for immediate reconstruction of the nose after bite injuries: indications, advantages, and disadvantages. *Ann Plast Surg*. 2014;73:358.
- Menick FJ, Salibian A. Microvascular repair of heminasal, subtotal, and total nasal defects with a folded radial forearm flap and a full-thickness forehead flap. *Plast Reconstr Surg*. 2011;127:637–651.
- Burget GC, Menick FJ. *Aesthetic Reconstruction of the Nose*. St Louis: Mosby; 1994.
- Pawar SS, Kim MM. Updates in forehead flap reconstruction of facial defects. *Curr Opin Otolaryngol Head Neck Surg*. 2013;21:384–388.