



Received: 2013.12.05
Accepted: 2014.02.05
Published: 2014.07.24

Authors' Contribution:

- A** Study Design
- B** Data Collection
- C** Statistical Analysis
- D** Data Interpretation
- E** Manuscript Preparation
- F** Literature Search
- G** Funds Collection

Nuclear Imaging of Amyloidosis

Wojciech Cytawa¹, Jacek Teodorczyk¹, Piotr Lass^{1,2}

¹ Department of Nuclear Medicine, Medical University of Gdańsk, Gdańsk, Poland

² Department of Molecular Spectroscopy, Institute of Experimental Physics, University of Gdańsk, Gdańsk, Poland

Author's address: Wojciech Cytawa, Department of Nuclear Medicine, Medical University of Gdańsk, Gdańsk, Poland,
e-mail: wcytawa@gumed.edu.pl

Summary

Amyloidosis is a clinical condition caused by deposition of various protein fibrils in extracellular space. The presented symptoms depend on the type of deposits and the organ or organs involved. The correct diagnosis is often difficult, due to lack of noninvasive imaging techniques and insufficiency of morphological imaging procedures delivered by radiology. We presented a list of potential radiopharmaceuticals that can be used in detecting various types of amyloidosis. ¹²³I-SAP proved to have high sensitivity in imaging of AA and AL amyloidosis in visceral organs. ^{99m}Tc-Aprotinin was found to be useful in detecting cardiac amyloidosis. A couple of classical radiotracers, such as ²⁰¹Tl, ¹²³I-mIBG, together with ¹¹¹In-antimyosin were also tested for accuracy in cardiac imaging, however the main problem was low specificity. Potential applicability was also found in case of some bone-seeking agents and other radiotracers, e.g. ⁶⁷Ga-citrate and ^{99m}Tc-penta-DMSA. High sensitivity and specificity was achieved with β 2-microglobulin labeled with ¹³¹I or ¹¹¹In. Among PET tracers, ¹¹C-PIB deserves more attention, because it may have an important role in diagnosing of AD in the near future. Further clinical studies are expected to take place, because noninvasive diagnosing and monitoring of amyloidosis is still a challenge.

Keywords: Nuclear Imaging • Scintigraphy • Amyloidosis

PDF file: <http://www.polradiol.com/abstract/index/idArt/890147>

Background

Amyloidosis is a disease characterised by deposition of protein fibrils in the extracellular space. The fibril deposits (amyloid) are composed of low-molecular-weight subunits of various serum proteins, which are improperly metabolised [1]. The term 'amyloid' is misleading, because the deposits were initially thought to be related to starch components [2]. Excessive accumulation of amyloid in a given tissue or organ is initially asymptomatic, but later on leads to progressive organ failure or death. Amyloidosis can be local (limited to one organ or one side of the body) or systemic (spread throughout the body), which is usually fatal [3].

Amyloidosis can be congenital or acquired, but it is always related to some precursor plasma protein which forms the fibril deposits. These plasma proteins belong to a wide group of various biochemical substances, often unrelated to each other, but determining the type of amyloidosis. Different kinds of amyloid deposits usually present affinity to certain organs. However, the patterns of pathological

accumulation in the body can be very diverse, resulting in various clinical manifestations of the disease. For example, the AL amyloidosis results from deposition of protein composed of monoclonal immunoglobulin light chains and in 26–50% is accompanied by cardiomyopathy. The AA type of amyloidosis, related to serum amyloid A protein (an acute-phase reactant) and associated with longstanding inflammatory disorders most often results in proteinuria and renal failure, and in less than 5% of patients it also leads to hepatomegaly, autonomic neuropathy or cardiomyopathy. Transthyretin is the precursor protein of ATTR amyloidosis, which can be hereditary or age-related, and frequently manifests with peripheral and autonomic neuropathy, renal failure or cardiomyopathy. Three types mentioned above comprise a group of major systemic amyloidosis. An example of localized amyloidosis may result from impaired clearance of β 2-microglobulin in patients chronically haemodialysed, with pathological deposits in bones and joints (A β 2M-type amyloidosis).

Other types of amyloidosis are presented in the Table 1.

Table 1. presenting various types of amyloidoses [3,4].

Type of amyloidosis	Precursor protein	Generalized (G)/localized (L)	Clinical manifestations
AL	Ig light chain	G, L	Various symptoms, cardiomyopathy in 26–50%
AA	Serum amyloid A	G, L	Proteinuria, renal failure, hepatomegaly, neuropathy, cardiomyopathy
ATTR	Transthyretin	G	Hereditary or age-related; neuropathy, cardiomyopathy, renal failure
A β 2M	β 2-microglobulin	G	Associated with chronic hemodialysis, pathological deposits in bones and joints
AH	Ig heavy chain	G, L	All kinds of manifestations
AApoAI	Apolipoprotein AI	G, L	Hereditary; neuropathy, nephropathy, aorta (local)
AApoAII	Apolipoprotein AII	G	Hereditary
AApoAIV	Apolipoprotein AIV	G	Sporadic, senile
AGel	Gelsolin	G	Hereditary
ACys	Cystatin C	G	Hereditary, cerebral hemorrhage
ALys	Lysozyme	G	Hereditary
AFib	Fibrinogen	G	Hereditary, renal failure
A β	A β precursor protein (A β PP)	L	Alzheimer's disease, ageing
ABri	ABriPP	G	British familial dementia
ADan	ADanPP	L	Danish familial dementia
ACal	Procalcitonin	L	Thyroid medullary cancer
AANF	Atrial natriuretic factor	L	Isolated atrial amyloid
AIAPP	Islet amyloid polypeptide	L	Islet of Langerhans, diabetes type II, insulinoma
APrP	Prion protein	L	Spongiform encephalopathies
AIns	Insulin	L	Iatrogenic
AMed	Lactadherin	L	Senile aortic (media)
AKer	Kerato-epithelin	L	Cornea, familial
ALac	Lactoferrin	L	Cornea
A	semenogelin	L	Seminal vesicle

Radiotracers Used for Imaging of Amyloid Deposits

Precise and early diagnosis of amyloidosis is necessary for effective treatment. Reliable diagnosis is provided only by histopathological examination, but it does not give information on the extent or progression of the disease. Nuclear imaging modalities, based on radiotracer accumulation within the sites of the disease play an important role in primary diagnosis and monitoring of illness [5]. There are two promising radiolabeled compounds, ^{123}I serum amyloid protein (SAP) and $^{99\text{m}}\text{Tc}$ -Aprotinin, and several other potential indicators, such as, $^{99\text{m}}\text{Tc}$ -phosphates or phosphonates, ^{123}I -mIBG, ^{201}Tl , ^{67}Ga -citrate, ^{111}In -antimyosin, $^{99\text{m}}\text{Tc}$ -penta-DMSA, ^{131}I - β 2 microglobulin, which present various affinity to amyloid deposits. They are discussed in more detail below.

^{123}I serum amyloid protein (SAP) – is a radiotracer composed of human serum amyloid P component labeled with radioactive ^{123}I (half-life 13.2 h, energy 159 keV). It was first proposed by Hawkins et al. [6,7]. SAP is identical to glycoprotein amyloid P, which is contained in all amyloid deposits [8,9]. It binds in a calcium-dependent manner to amyloid fibrils of all types [10]. A standard dose of ^{123}I -SAP is 100 μg of protein with 200 MBq of radioactivity. Imaging is performed 24 h after i.v. injection [11]. The ^{123}I -SAP is used for detection of amyloid in systemic AA, AL and ATTR amyloidosis with high sensitivity and specificity. It allows to determine the extent and distribution of amyloid, especially in big visceral organs, such as liver, spleen or kidneys, but has lower potential in the assessment of cardiac involvement (probably due to the lack of fenestrated endothelium in the myocardium) [8]. A great value of SAP scintigraphy is the

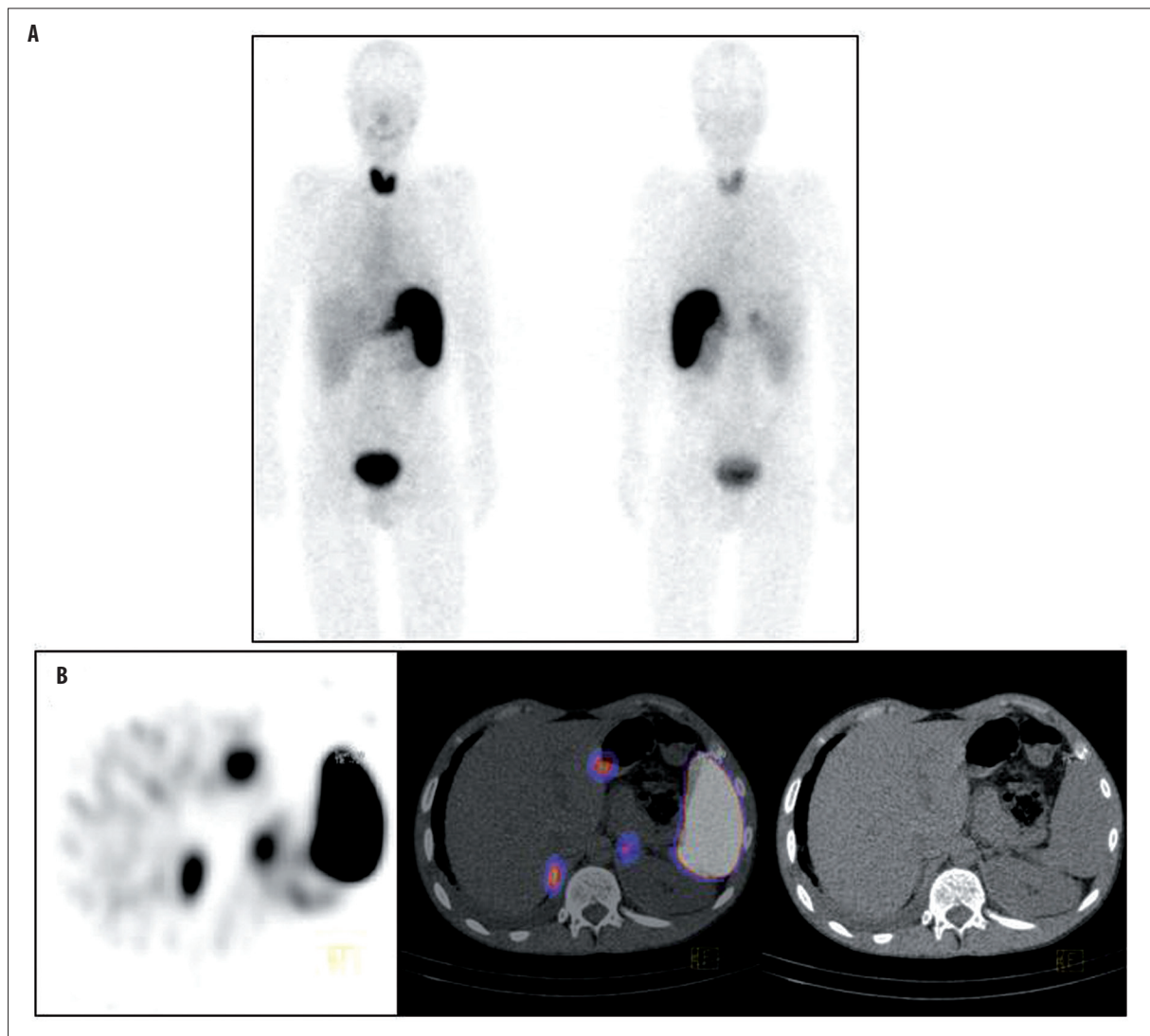


Figure 1. SAP scintigraphy showing pathologically increased uptake in spleen and adrenal glands ((A) – planar image, (B) – SPECT/CT). With permission of dr Andor Glaudemans from the Department of Nuclear Medicine & Molecular Imaging, University Medical Center Groningen, University of Groningen.

possibility to exclude systemic deposits in case of a localized disease. In a study of 219 patients with localized and systemic amyloidosis, Hazenberg reported a high 90% sensitivity of SAP scintigraphy in the detection of AA and AL amyloidosis and a lower, 48% sensitivity for detecting the ATTR type of the disease, while the overall specificity was 93% [8]. Hachulla [4] in a review article reported a 100% sensitivity when the scintigraphic analysis included the evaluation of 24h tracer retention in the body tissues.

Saile [11], who compared the 24h-retention of SAP in 15 patients with various types of amyloidosis with control group proved higher whole-body retention (47–87% vs. 44–67% in controls).

Although amyloidosis is always diagnosed on the basis of positive biopsy results, the advantage of nuclear imaging is its ability to noninvasively assess the extent of involvement (*whole-body* scintigraphy) and the lack of potential complications (bleeding or perforation, infection). The

drawback is that ^{123}I is expensive and not readily available (Figure 1).

The $^{99\text{m}}\text{Tc}$ -Aprotinin – aprotinin is a proteinase inhibitor and is normally used as an anti-coagulant drug in open-heart surgeries. Various protein inhibitors were confirmed to be present in amyloid deposits [4], which gave the researchers an opportunity to investigate possible binding of aprotinin to amyloid [12]. When labeled with technetium-99m, aprotinin forms a stable complex which accumulates in kidneys and liver after intravenous injections. It does not cross the blood-brain barrier in normal conditions [13]. Hence, $^{99\text{m}}\text{Tc}$ -Aprotinin is not dedicated for assessment of visceral organs and brain. On the other hand, it occurred to be valuable in imaging of myocardial amyloid. In a study by Han [5], all five patients (out of 35 examined) who had histologically confirmed heart amyloidosis showed positive uptake of $^{99\text{m}}\text{Tc}$ -Aprotinin in the myocardium (median heart-to-background ratio 2.0 vs. 1.1 in subjects without cardiac amyloid, $p=0.0004$).

Schaadt et al. [11] performed ^{99m}Tc -Aprotinin scintigraphy in 23 patients with confirmed or suspected amyloidosis, and found focal accumulations, mostly in organs such as lungs, pleura, liver, spleen, intestines, myocardium and tongue. A vast majority of lesions were histologically confirmed to contain amyloid deposits either during autopsy (3 patients) or in biopsy (the remaining 20 patients). The authors concluded that ^{99m}Tc -Aprotinin scintigraphy was fairly sensitive and specific diagnostic modality in patients with suspected amyloidosis.

The rest of the tracers present a wide range of specificity and sensitivity. Unfortunately, none of these tracers offer very high diagnostic accuracy, and thus tissue biopsies have to be performed to diagnose amyloidosis. The role of these tracers could be monitoring of disease progression/regression or assessment of disease spread in patients with established diagnosis and proven tracer accumulation especially where biopsy is problematic e.g. in the heart. Clinically relevant is to define amyloid chemical type, which can be performed with high accuracy with radioimmunochemical assays. Unfortunately, these radiotracers do not offer high accuracy in the determination of amyloid structural subtype and tissue sample is still indispensable.

Numerous papers have reported accumulation of bone-seeking tracers in tissues affected with amyloidosis, which was initially reported in 1977 [14]. The biochemical character of this affinity is not fully understood and most frequently it is explained with increased calcium content in amyloidotic deposits.

Several phosphonate- and phosphate-based radiotracers (e.g. ^{99m}Tc -PYP, ^{99m}Tc -MDP, ^{99m}Tc -HMDF, ^{99m}Tc -DPD) were tested and presented a broad spectrum of diagnostic performance. In the study by Falk et al., performed with the use of ^{99m}Tc -pyrophosphate, the result was positive in 9 of 11 patients with advanced amyloid cardiomyopathy, but only in 2 of 9 patients with biopsy-proven initial stage of the disease [15]. Lee et al. studied both ^{99m}Tc -PYP and ^{99m}Tc -MDP. The ^{99m}Tc -PYP scan was positive in all 7 patients, but only 4 patients presented ^{99m}Tc -MDP uptake [16]. Disappointing results were shown by Eriksson et al. [17] – only 4 of 12 patients with echocardiographic features of amyloidosis revealed increased ^{99m}Tc -PYP uptake. The results obtained by Tanaka et al. were equally discouraging – ^{99m}Tc -PYP uptake in only 4 of 12 patients with biopsy-proven cardiac amyloidosis [18]. More promising results were presented by Perugini et al. [19] – by scanning with the use of ^{99m}Tc -DPD and ^{99m}Tc -MDP they were able to differentiate ATTR vs. AL type of amyloidosis.

Many authors have reported a decreased uptake of Iodine-mIBG radiotracer in the amyloid-affected myocardium. This was initially described by Nakata et al. in 1995 [20]. Metaiodobenzylguanidine (mIBG) is structurally similar to noradrenalin and is taken up in presynaptic neural endings of the sympathetic system. Imaging of amyloidosis with mIBG radiotracer is indirect and based on sympathetic nerve destruction in amyloidosis.

Tanaka et al. performed mIBG scanning in 12 patients with familial amyloid polyneuropathy with biopsy-proven

heart involvement. All patients demonstrated reduced radiotracer uptake (8 patients presented no heart uptake, 4 presented a deeply reduced uptake) [17]. Authors concluded that mIBG heart scintigraphy has potential to early detect amyloidotic changes in the myocardium. In the study by Dealahaye et al., all 17 patients with familial amyloid polyneuropathy demonstrated decreased heart uptake of ^{123}I -mIBG and the level of uptake decrease correlated with clinical severity of polyneuropathy [21].

Perfusion in amyloid cardiomyopathy was studied with the use of ^{201}Tl by Kobayashi et al. Perfusion remained almost unchanged, and deficits were seen only in bigger amyloid depositions [22]. Wechalekar et al. studied perfusion with ^{99m}Tc -Sestamibi and demonstrated no perfusion changes in amyloidosis [23]. Kodama et al. demonstrated increased ^{201}Tl washout in amyloid cardiomyopathy group [24].

^{67}Ga -citrate is a frequently utilized radiotracer having high affinity to inflammatory and neoplastic processes. The mechanism of gallium accumulation in target tissues is not fully understood. Its uptake is proportional to the density of transferrin receptors [25]. Reports on gallium citrate uptake in amyloid cardiomyopathy were published first by Brown et al. in 1979 [26], which was later confirmed by Montes et al. [27] and Li et al. [28]. It seems that gallium citrate does not play essential role in the discussed group of patients.

^{111}In -antimyosin is a radiotracer with affinity to the injured myocardium. Its uptake is nonspecific and is present in many cardiological conditions such as infarction, inflammation, myocardopathy, heart transplant complication, drug toxicity [29]. In a study by Lekakis et al. all seven patients with heart amyloidosis demonstrated increased uptake of ^{111}In -antimyosin compared to control group [30].

^{99m}Tc -penta-DMSA is a radiotracer with affinity to several neoplastic diseases e.g. medullary thyroid cancer. Its uptake in AL amyloidosis was described by Ohta et al. [31] and Kobayashi et al. [22]. Disadvantage of ^{99m}Tc -penta-DMSA is its relatively high blood-pool concentration making the assessment of tissue uptake difficult, which was minimized by delayed image registration after 24h post injection and described by Arbab et al. [32].

β_2 -microglobulin ($\beta_2\text{M}$) is a precursor protein of $\text{A}\beta_2\text{M}$ type of amyloidosis in patients chronically hemodialysed with involvement of joints. Radiolabeling of β_2 -microglobulin enabled specific scintigraphic detection of amyloid present in this particular type of amyloidosis. It was first performed by Floege in 1989 [33]. The isotope used was ^{131}I and $\beta_2\text{M}$ was extracted from uremic hemofiltrate. The radiotracer is accumulated directly in amyloid deposits [32]. A disadvantage of ^{131}I -labeled radiotracer was poor spatial resolution, which made imaging of small joints problematic and increased the radiation dose due to unnecessary $\beta(-)$ radiation [34]. In 2000, Schaeffer combined $\beta_2\text{M}$ with gamma emitter ^{111}In [35]. The registered images had a significantly better quality as compared with previously utilized radiotracers. To prevent a potential transmission of infection, "natural" blood-extracted $\beta_2\text{M}$ was substituted

by a recombinant one with good results [35]. Sensitivity of ^{131}I - β2M scan is better than the one achieved in combined radiological and clinical detection methods, specificity was high – the radiotracer was not present in inflammatory changes in joints and in short-term hemodialysis patients [36]. Disadvantage of β2M radionuclide imaging is inability to use it in patients with preserved residual renal function because of fast filtration of the radiotracer [37].

PET tracers

There is a question of incorporation of ^{18}F -FDG-PET into the diagnostics of pulmonary amyloidosis. The role of ^{18}F -FDG-PET in metabolic assessment of pulmonary nodules is well known [38]. Yadav et al. [39] described a case of a patient suffering from pulmonary amyloidosis who presented with intense uptake of ^{18}F -fluorodeoxyglucose in one dominant pulmonary nodule, with a lack of uptake in the remaining nodules. The authors, however, explained that ^{18}F -FDG is a nonspecific tracer for amyloid deposits. At the same time, positive focal accumulation of labeled glucose for a suspected malignancy should always be verified with microscopic examination if curative treatment is concerned.

Promising results were obtained by Klunk et al. [40] and Rabinovici et al. [41] in the imaging of beta-amyloid with ^{11}C Pittsburgh compound-B (PIB) in Alzheimer's disease. In the study by Klunk et al. who compared 16 patients with AD (Alzheimer's disease) and 9 healthy patients, the retention of PIB was statistically higher in the areas which contained large amounts of amyloid deposits (frontal cortex:

1.94-fold, $p=0.0001$, parietal cortex: 1.71-fold, $p=0.0002$, temporal cortex: 1.52-fold, $p=0.002$, occipital cortex: 1.54-fold, $p=0.002$, striatum: 1.76-fold, $p=0.0001$). In the study by Rabinovici et al. [40] all the 7 patients with AD had a positive uptake of PIB. However, among patients with FTD (frontotemporal dementia) 4 out of 12 results were also positive, which means that ^{11}C -PIB PET helps to discriminate AD from other types of neurodegeneration, but still a pathological correlation is needed.

Conclusions

Amyloidosis is a clinical condition which is difficult to diagnose and monitor, due to the lack of specific and non-invasive methods. Nuclear imaging brings hope to this field of medicine, since it allows to functionally detect amyloid deposits. Nuclear scans present many advantages, such as quick assessment of disease extent owing to *whole-body* scintigraphy, ability to monitor the progression or regression of illness, and very low invasiveness (apart from a small dose of ionising radiation). A few valuable radiotracers, such as ^{123}I -SAP, $^{99\text{m}}\text{Tc}$ -Aprotinin or ^{11}C -PIB dedicated for imaging of amyloidosis were already initially tested and the results are promising, which means that their role will probably be established in clinical practice in the near future. Certainly, some of the commonly available, "everyday" radiopharmaceuticals, for example bone-seeking tracers, could be more involved in the monitoring of the disease in cases with confirmed uptake. Nevertheless, further clinical studies are required to find new specific radiotracers which will allow to precisely detect, diagnose and monitor this troublesome and diverse clinical condition called amyloidosis.

References:

- Schaadt BK, Hendel HW, Gimsing P et al: $^{99\text{m}}\text{Tc}$ -aprotinin scintigraphy in amyloidosis. *J Nucl Med*, 2003; 44: 177–83
- Aterman K. A historical note on the iodine-sulphuric acid reaction of amyloid. *Histochemistry*, 1976; 49(2): 131–43
- Glaudemans AW, Slart RH, Zeebregts CJ et al: Nuclear imaging in cardiac amyloidosis. *Eur J Nucl Med Mol Imaging*, 2009; 36: 702–14.
- Hachulla E, Grateau G: Diagnostic tools for amyloidosis. *Joint Bone Spine*, 2002; 69: 538–45
- Han S, Chong V, Murray T et al: Preliminary experience of $^{99\text{m}}\text{Tc}$ -Aprotinin scintigraphy in amyloidosis. *Eur J Haematol*, 2007; 79(6): 494–500
- Hawkins PN, Myers MJ, Lavender JP et al: Diagnostic radionuclide imaging of amyloid: biological targeting by circulating human serum amyloid P component. *Lancet*, 1988; 1: 1413–18
- Hawkins PN, Wootton R, Pepys MB: Metabolic studies of radioiodinated serum amyloid P component in normal subjects patients with systemic amyloidosis. *J Clin Invest*, 1990; 86: 1862–69
- Hazenbergh BP, van Rijswijk MH, Piers DA et al: Diagnostic performance of ^{123}I -labeled serum amyloid P component scintigraphy in patients with amyloidosis. *Am J Med*, 2006; 119: 355. E15–24
- Hazenbergh BP, van Rijswijk MH, Lub-de Hooge MN et al: Diagnostic performance and prognostic value of extravascular retention of ^{123}I -labeled serum amyloid P component in systemic amyloidosis. *J Nucl Med*, 2007; 48: 865–72
- Pepys MB, Booth DR, Hutchinson WL et al: Amyloid P component. A critical review. *Amyloid-International Journal of Experimental and Clinical Investigation*, 1997; 4: 274–95
- Saile R, Deveaux M, Hachulla E et al: Iodine-123-labelled serum amyloid P component scintigraphy in amyloidosis. *Eur J Nucl Med*, 1993; 20(2): 130–37
- Aprile C, Marinone G, Saponaro R et al: Cardiac and pleuropulmonary AL amyloid imaging with technetium-99m labelled aprotinin. *Eur J Nucl Med*, 1995; 22: 1393–401
- Dollery C: Aprotinin. In: Dollery C (ed.), *Therapeutic Drugs*. 2nd ed. Churchill Livingstone, Edinburgh, 1999
- Kula RW, Engel WK, Line BR: Scanning for soft-tissue amyloid. *Lancet*, 1977; 1(8002): 92–93
- Falk RH, Lee VW, Rubinow A et al: Sensitivity of technetium-99m-pyrophosphate scintigraphy in diagnosing cardiac amyloidosis. *Am J Cardiol*, 1983; 51(5): 826–30
- Lee VW, Caldarone AG, Falk RH et al: Amyloidosis of heart and liver: comparison of Tc-99m pyrophosphate and Tc-99m methylene diphosphonate for detection. *Radiology*, 1983; 148(1): 239–42
- Eriksson P, Backman C, Bjerle P et al: Non-invasive assessment of the presence and severity of cardiac amyloidosis. A study in familial amyloidosis with polyneuropathy by cross sectional echocardiography and technetium-99m pyrophosphate scintigraphy. *Br Heart J*, 1984; 52(3): 321–26
- Tanaka M, Hongo M, Kinoshita O et al: Iodine-123 metaiodobenzylguanidine scintigraphic assessment of myocardial sympathetic innervation in patients with familial amyloid polyneuropathy. *J Am Coll Cardiol*, 1997; 29(1): 168–74
- Perugini E, Guidalotti PL, Salvi F et al: Noninvasive etiologic diagnosis of cardiac amyloidosis using $^{99\text{m}}\text{Tc}$ -3,3-diphosphono-1,2-propanodicarboxylic acid scintigraphy. *J Am Coll Cardiol*, 2005; 46(6): 1076–84
- Nakata T, Shimamoto K, Yonekura S et al: Cardiac sympathetic denervation in transthyretin-related familial amyloidotic polyneuropathy: detection with iodine-123-MIBG. *J Nucl Med*, 1995; 36(6): 1040–42

21. Delahaye N, Dinanian S, Slama MS et al: Cardiac sympathetic denervation in familial amyloid polyneuropathy assessed by iodine-123 metaiodobenzylguanidine scintigraphy and heart rate variability. *Eur J Nucl Med*, 1999; 26(4): 416–24
22. Kobayashi T, Sekiya M, Fujiwara Y et al: A patient with cardiac amyloidosis presenting a rapid increase in technetium-99mhydroxymethylene diphosphonate accumulation. *Ann Nucl Med*, 1993; 7(4): 273–76
23. Wechalekar K, Ng FS, Poole-Wilson PA et al: Cardiac amyloidosis diagnosed incidentally by bone scintigraphy. *J Nucl Cardiol*, 2007; 14(5): 750–53
24. Kodama K, Hamada M, Kuwahara T et al: Rest-redistribution thallium-201 myocardial scintigraphic study in cardiac amyloidosis. *Int J Card Imaging*, 1999; 15(5): 371–78
25. Bernstein LR. Mechanisms of therapeutic activity for gallium. *Pharm Rev*, 1998; 50(4): 665–82
26. Braun SD, Lisbona R, Novales-Diaz JA et al: Myocardial uptake of ^{99m}Tc-phosphate tracer in amyloidosis. *Clin Nucl Med*, 1979; 4(6): 244–45
27. Montes J, López L, Chamorro JL et al: Cardiac gallium uptake in amyloidosis. *Eur J Nucl Med*, 1984; 9: 438
28. Li CK, Rabinovitch MA, Juni JE et al: Scintigraphic characterization of amyloid cardiomyopathy. *Clin Nucl Med*, 1985; 10: 156–59
29. Carrió I, Berná L, Ballester M et al: Indium-111 antimyosin scintigraphy to assess myocardial damage in patients with suspected myocarditis and cardiac rejection. *J Nucl Med*, 1988; 29: 1893–900
30. Lekakis J, Dimopoulos M, Nanas J et al: Antimyosin scintigraphy for detection of cardiac amyloidosis. *Am J Cardiol*, 1997; 80: 963–65
31. Ohta H, Endo K, Kanoh T et al: Technetium-99m (V) DMSA uptake in amyloidosis. *J Nucl Med*, 1989; 30: 2049–52
32. Arbab AS, Koizumi K, Toyama K et al: Scan findings of various myocardial SPECT agents in a case of amyloid polyneuropathy with suspected myocardial involvement. *Ann Nucl Med*, 1997; 11: 139–41
33. Floege J, Nonnast-Daniel B, Gielow P et al: Specific imaging of dialysis-related amyloid deposits using ¹³¹I-beta-2-microglobulin. *Nephron*, 1989; 51: 444–47
34. Floege J, Schäffer J, Koch KM: Scintigraphic methods to detect beta2-microglobulin associated amyloidosis (Abeta2-microglobulin amyloidosis). *Nephrol Dial Transplant*, 2001; 16: 12–16
35. Schäffer J, Burchert W, Floege J et al: Recombinant versus natural human ¹¹¹In-beta2-microglobulin for scintigraphic detection of Abeta2m amyloid in dialysis patients. *Kidney Int*, 2000; 58: 873–80
36. Floege J, Burchert W, Brandis A et al: Imaging of dialysis-related amyloid (AB-amyloid) deposits with ¹³¹I-beta 2-microglobulin. *Kidney Int*, 1990; 38: 1169–76
37. Floege J, Bartsch A, Schulze M et al: Clearance and synthesis rates of beta 2-microglobulin in patients undergoing hemodialysis and in normal subjects. *J Lab Clin Med*, 1991; 118: 153–65
38. Gould MK, Maclean CC, Kuschner WG et al: Accuracy of positron emission tomography for diagnosis of pulmonary nodules and mass lesions: a meta-analysis. *JAMA*, 2001; 285: 914–24
39. Yadav S, Sharma S, Gilfillan I. Unusual positron emission tomography findings in pulmonary amyloidosis: a case report. *J Cardiothorac Surg*, 2006; 1: 32
40. Klunk WE, Engler H, Nordberg A et al: Imaging brain amyloid in Alzheimer's disease with Pittsburgh Compound-B. *Ann Neurol*, 2004; 55: 306–19
41. Rabinovici GD, Furst AJ, O'Neil JP et al: ¹¹C-PIB PET imaging in Alzheimer disease and frontotemporal lobar degeneration. *Neurology*, 2007; 68: 1205–12