

## Case Report

# A Case Report of Dysosteosclerosis Observed from the Prenatal Period

Kisho Kobayashi<sup>1, 2</sup>, Yusuke Goto<sup>1, 2</sup>, Hiroaki Kise<sup>1, 2</sup>, Hiroaki Kanai<sup>1, 2</sup>, Koji Kodera<sup>1, 2</sup>, Gen Nishimura<sup>3</sup>, Kenji Ohyama<sup>1</sup>, Kanji Sugita<sup>1</sup>, and Takayuki Komai<sup>1, 2</sup>

<sup>1</sup>Department of Pediatrics, University of Yamanashi, Yamanashi, Japan

<sup>2</sup>Department of Pediatrics, Yamanashi Prefectural Central Hospital, Yamanashi, Japan

<sup>3</sup>Department of Radiology, Tokyo Metropolitan Children's Medical Center, Tokyo, Japan

**Abstract.** Dysosteosclerosis is a sclerosing bone dysplasia with skeletal changes resembling those of osteopetrosis. The disorder is associated with dental anomalies and occasionally mental retardation. Because of the rarity and phenotypic diversity of dysosteosclerosis, it remains unsolved whether or not the disorder is heterogeneous. We report here on an affected boy associated with brain calcification and epilepsy with developmental delay. Prenatal ultrasound revealed ventriculomegaly, and brain CT in the neonatal period showed periventricular calcifications. At 13 mo of age, he presented with generalized convulsion with developmental delay. Metaphyseal sclerosis, metaphyseal undermodeling, and oval-shaped vertebral bodies on skeletal survey warranted a diagnosis of dysosteosclerosis. Retrospective review of radiographs as a neonate showed metaphyseal radiolucency, but not metaphyseal sclerosis. Since then, neither the bone changes nor neurological symptom has progressively worsened up to 4 yr of age. Thus, it is thought that the clinical and radiological manifestations of the sclerotic disorder become obvious during infancy. Brain calcification of prenatal onset may be an essential syndromic constituent of the disorder.

**Key words:** dysosteosclerosis, metaphyseal sclerosis, congenital bone disease, periventricular calcification

---

## Introduction

Dysosteosclerosis (MIM224300) is a rare sclerosing bone dysplasia characterized by metaphyseal osteosclerosis and metaphyseal undermodeling with a tendency toward fractures. Sclerosis at the skull base leads to cranial nerve

compression resulting in certain manifestations, such as blindness and facial paralysis. Dental anomalies commonly occur, and mental retardation occasionally does. The skeletal changes in this disorder resemble those of osteopetrosis. However, the presence of platyspondyly in dysosteosclerosis helps differentiate it from osteopetrosis. Dysosteosclerosis, unlike osteopetrosis, does not show bone marrow dysfunction and sclerotic changes of the diaphyses. Despite the relatively long term since the first report by Spranger *et al.* in 1968 (1), additional reports remain limited in number.

---

Received: January 21, 2010

Accepted: April 22, 2010

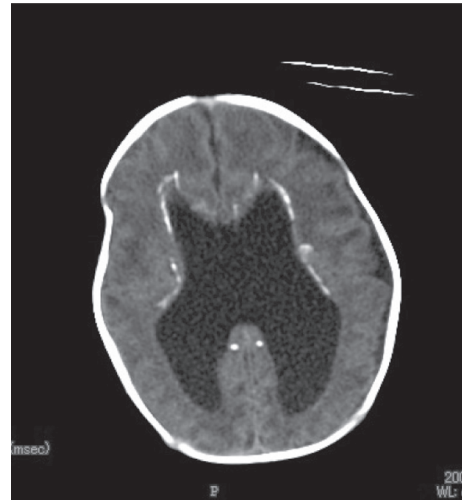Correspondence: Dr. Kisho Kobayashi, Department of Pediatrics, University of Yamanashi, 1110 Shimokato, Chuo City, Yamanashi 409-3898, Japan  
E-mail: kisyouk@yamanashi.ac.jp

Thus, the thorough clinical and radiological courses have not been sufficiently established. Inheritance of the disease is considered to be mostly autosomal recessive, while an X-linked pedigree is also proposed. Genetic heterogeneity of the disorder remains unsolved, as does the pathogenesis. We report here on an affected Japanese boy whom we have been able to follow up from the prenatal period to 4 yr of age.

### Case Report

The boy was born primiparity at 31 wk of gestation by cesarean section owing to progressive enlargement of the lateral ventricles on fetal ultrasound examinations. His parents were both 31 yr old at the time, healthy and not consanguineous. The father was 175 cm in height, and the mother 155 cm. There was no family history of bone or metabolic diseases. Birth weight was 2,286 g (+3.5SD), length was 45.0 cm (+1.8SD), and head circumference was 34.8 cm (+3.8SD). The titers of antibodies for TORCH infections were all negative. Postnatal respiratory distress required surfactant supplementation and mechanical ventilation for 5 d. In the neonatal period, no congenital anomaly was noticed except for a large head circumference. Short extremities were also not noticed, although his arm span was not recorded. Brain CT demonstrated periventricular calcifications with symmetrical enlargement of the lateral ventricles (Fig. 1). Examinations of auditory brain stem response and visual evoked potentials in the neonatal period were both normal.

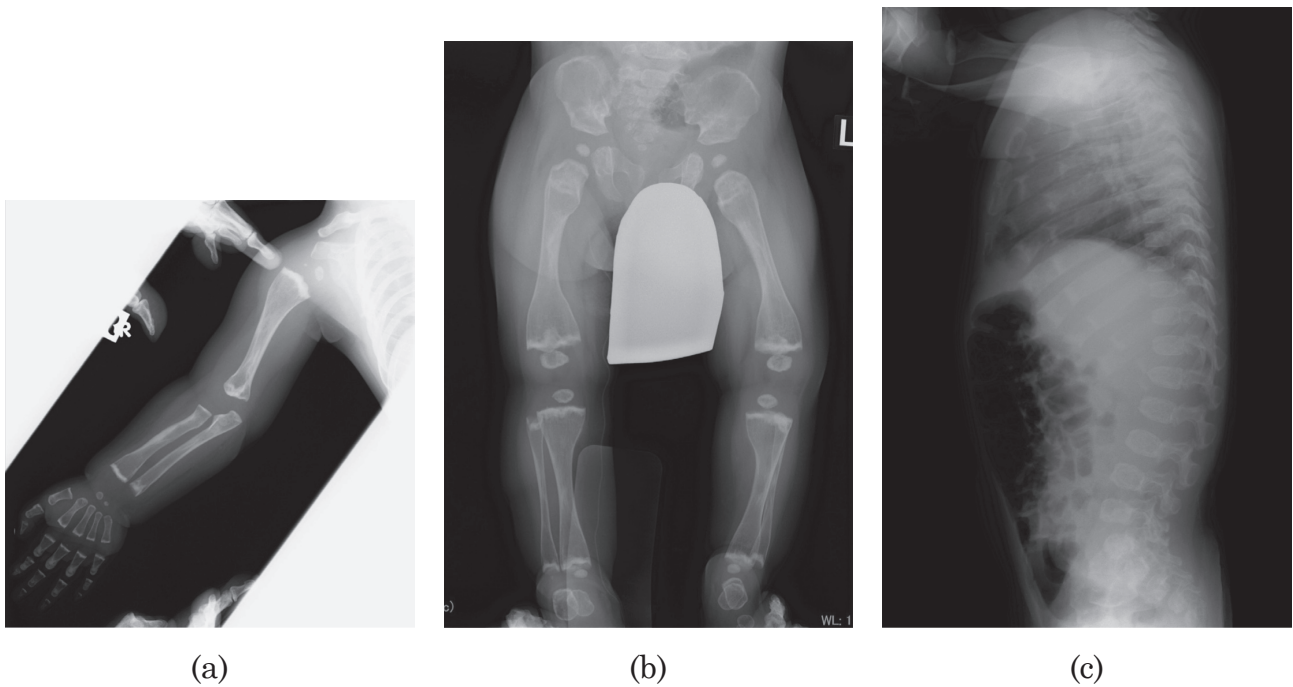
At 13 mo of age, he presented with generalized convulsion and unconsciousness with respiratory failure, which were promptly alleviated with intensive convulsion and respiratory care. The deciduous teeth were reported to have erupted at 6 mo of age. At 13 mo of age, his body length was 74 cm (-0.7SD), weight was 9 kg (mean) and arm span was 68 cm. On physical examination, he showed frontal bossing, saddle nose, small, yellowish upper deciduous teeth (Fig. 4) and



**Fig. 1** Brain CT as a neonate. Symmetrical calcifications in the periventricular area and ventricular enlargement were found. Calcifications in the corpus callosum and pyramidal tract were also found in the other slices.

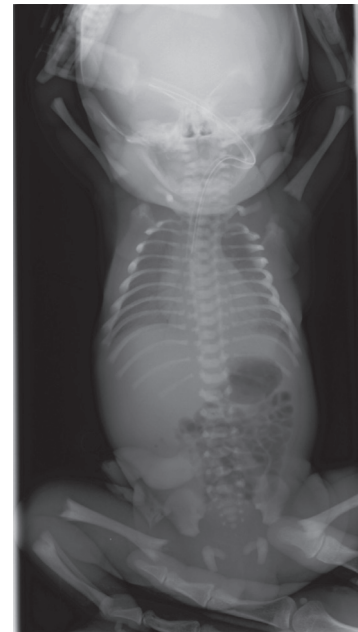prominent lower ribs without rachitic rosary, but no deformities or bowings of the extremities. His nails were unremarkable. No skin rashes were found. His head was steady, but he was unable to sit alone. Laboratory examinations were not contributory (Table 1). A chest radiograph revealed wide, irregular osteosclerosis at the anterior ends of the ribs. Skeletal survey showed metaphyseal sclerosis and metaphyseal undermodeling of the long and short tubular bones and oval-shaped, somewhat flattened vertebral bodies, which warranted a diagnosis of dysosteosclerosis (Fig. 2). Retrospective review of radiographs as a neonate exhibited metaphyseal radiolucency, but not metaphyseal sclerosis (Fig. 3). Brain CT did show no significant interval changes as compared with that in the neonatal period. Polyspikes and waves dominantly in the right hemisphere were recorded on an electroencephalogram. He was diagnosed as having epilepsy and has since been treated with valproic acid.

The hypoplastic upper deciduous teeth were



**Fig. 2** Skeletal radiographs of the right arm and hand (a), lower extremities (b) and bodies of vertebrae and costae (c) at 13 mo of age. All the ends of long and short bones revealed metaphyseal sclerosis and metaphyseal remodeling. The vertebral bodies showed deformities with irregular surfaces.

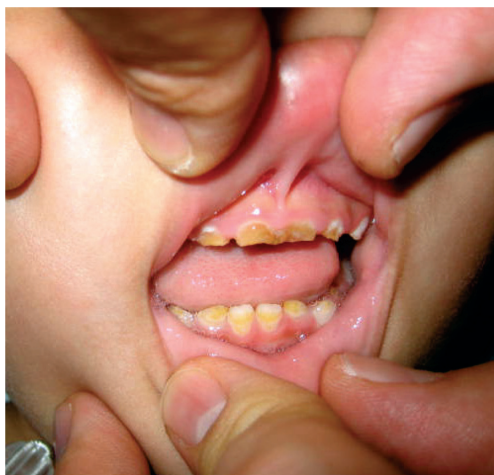vulnerable to caries, leading to extraction at 3 yr of age. By contrast, the lower deciduous teeth were all normal in size without caries. Ophthalmologic examination at 3 yr of age excluded optic nerve atrophy, and his hearing ability was normal based on clinical criteria. He watched his favorite TV programs from a few meters away at that time. He pointed at a character in a picture book. He spoke, but not in sentences. At three years of age, his developmental level was equivalent to one year according to Enjoji's analytical developmental test. Motor development was delayed. He was able to stand unaided but unable to walk at 4 yr of age. The skeletal changes at 4 yr of age were essentially the same as those at 13 mo of age, other than more conspicuous metaphyseal undermodeling and mild bowing of the long bones (data not shown).



**Fig. 3** Radiograph on birthday. Metaphyseal radiolucency, but no sclerotic change, was shown in the neonatal period.

**Table 1** Laboratory data at the age of 14 mo

Blood gas analysis
pH 7.422, PCO <sub>2</sub> 32.2 mmHg, HCO <sub>3</sub> 20.5 mmol/l, Base Excess -3.1 mmol/l
Serum analysis
Na 139 mEq/l (135–146), K 5.0 mEq/l (3.4–4.8), Cl 104 mEq/l (99–108), Ca 10.0 mg/dl (8.9–10.4), IP 4.9 mg/dl (3.3–5.5), Mg 2.1 mg/dl (1.7–2.4), AST 49 IU/l (10–32), ALT 16 IU/l (2–31), ALP 443 IU/l, Lactate 10.8 mg/dl (3.3–17.0), PTH-intact 14 pg/ml (8.3–76.1), Bone-specific alkaline phosphatase 54.9 U/l, Calcitonin 37 pg/ml, 1,25(OH) <sub>2</sub> Vitamin D 98.2 pg/ml (20.0–70.0), Tartrate-resistant acid phosphatase 23.1 IU/l (adult reference range 8.1–18.7)
Amino acid analysis, all within normal limits
Urine analysis
Ca 0.8 mg/dl, IP 13.8 mg/dl, Cr 7.2 mg/dl, Deoxyypyridinoline 36.4 nmol/mmolCr
Amino acid analysis, all within normal limits



**Fig. 4** Deciduous teeth at 2 yr of age. The color of the upper teeth was more yellow than that of the lower teeth, and the upper teeth were more hypoplastic than the lower teeth. Subsequently, all the upper teeth were extracted by 3 yr of age, but the lower teeth appeared to be normal.

## Discussion

We described a sporadic case with dysosteosclerosis followed up from the prenatal period to 4 yr of age. There have been 3 reported

cases in Japan, and about 20 patients have been reported in the world. The hallmarks of the present boy included periventricular calcification and ventriculomegaly of prenatal onset, developmental delay with convulsion, and hypoplastic upper deciduous teeth, as well as the typical skeletal changes that manifested at 13 mo of age. It is unclear when the sclerotic bone change started, as no examination of radiographs was performed until 13 mo of age. Interestingly, radiographs in the neonatal period showed metaphyseal radiolucency but not metaphyseal sclerosis.

In fact, dysosteosclerosis is a multi-system disorder involving the bone, teeth and central nervous system. Metaphyseal sclerosis and metaphyseal undermodeling with bone fragility in the disorder resembles those of osteopetrosis. Therefore, it is tempting to assume that dysfunction of osteoclasts is responsible for the pathogenesis of the disorder, as for osteopetrosis. However, dysosteosclerosis, unlike osteopetrosis, is associated with platyspondyly. Moreover, the present boy exhibited metaphyseal radiolucency (metaphyseal dysplasia) in the neonatal period. Hematological findings in the previously reported patients with dysosteosclerosis do not show bone marrow dysfunction unlike osteopetrosis. Thus,

we assume that the disease-causing gene in the disorder plays a role not only in bone remodeling/modeling but also in endochondral bone formation. However, analyses of currently available bone biochemical markers in the present child did not help to give any clues to the pathogenesis. A candidate gene for this disease has not been proposed; moreover, the hereditary pattern is not consistent in some previous reports. The levels of markers for osteoblasts and osteoclasts at 13 mo of age did not indicate dysfunction of them, although these markers might only have been altered in his fetal and infantile periods.

Chitayat *et al.* (2) reported an affected child with brain calcification and developmental delay that are similar to those in the present boy. Senar *et al.* (3) reported another affected child who showed retarded myelination of the white matter identified on MRI, but the child did not exhibit ventriculomegaly or calcifications. Mental retardation is relatively common in dysosteosclerosis. A case report of three cases by Elcioglu *et al.* (4) presents metaphyseal dysplasia with delayed neurological development. These cases appear to be severe, but they all present neurological abnormalities such as ventriculomegaly, cerebral infarction and hemiplegia. The enzyme activity of carbonic anhydrase II in case 1, one of the responsible factors for osteopetrosis, was evaluated, but it was within normal limits. As exemplified by the present boy and previously reported children, however, developmental delay in dysosteosclerosis is attributable to static encephalopathy rather than a neurodegenerative condition.

We consider that the mechanism of periventricular calcifications occurs in a manner similar to that of metaphyseal calcifications however, the rate of maturation in each tissue may be different. Therefore, the brain lesions were remarkable in the neonatal period. The present boy had less calcified metaphyses than metaphyseal sclerosis as a neonate, suggesting the responsible factor(s) may act with regard to

sclerotic bone change in a postnatal period, although the pathophysiological mechanism of the less calcified metaphyses remains to be elucidated. The radiographs at 13 mo of age show narrow diaphyses of long bones, which appear to have grown in the prenatal period. Intracranial calcifications in dysosteosclerosis are superficially similar to those of TORCH infection, particularly prenatal vasculopathy in CMV infection. There are some reports indicating that certain bone-specific proteins are expressed in the vascular wall (5, 6). Furthermore, whether dysosteosclerosis is etiologically related to other sclerosing bone dysplasias with CNS abnormalities, such as osteosclerotic metaphyseal dysplasia (7) and infantile osteopetrosis and neuronal storage disease (MIM 600329), is an interesting but yet unsolved issue.

Sclerosing bone dysplasias are commonly associated with abnormal dentition and enamel hypoplasia, which are mostly attributed to abnormal absorption of the dental cusp and secondarily impaired equilibrium of calcium and phosphate. However, the dental abnormalities in dysosteosclerosis are more complicated. Oncag *et al.* (8) reported hypoplastic teeth in dysosteosclerosis, which resembles the dental findings in the present patient. They described that the enamel and dentin of extracted teeth were pathologically hypercalcified with small enamel prisms. In the present case, the findings of teeth abnormalities were similar, but the cause of the difference in the present case between the upper and lower teeth appearances has not been clarified. The enamel matrix is comprised of amelogenin, enamelin, ameloblastin and some other proteins including type 1 collagen. It is known that enamel matrix derivative modulates the number of osteoclasts expressing tartrate-resistant acid phosphatase in a mouse model (9), suggesting a possibility of involvement of osteoclasts in the prenatal and infantile periods, although serum and urine markers for bone reabsorption did not indicate this at 13 mo of age. Dysregulation of calcium or phosphorus is

unlikely based on the laboratory data of the present case.

In conclusion, we described a sporadic case of dysosteosclerosis that has been followed up since the prenatal period. The prenatal manifestation in the present case raises a suspicion of impaired endochondral ossification and intracerebral vasculopathy in this disorder.

### References

1. Spranger JW, Albrecht C, Rohwedder HJ, Wiedemann H-R. Die dysosteosklerose: eine sonderform der generalisierten osteosklerose. *Fortschr Roentgenstr* 1968;109:504–12.
2. Chitayat D, Silver K, Azouz EM. Skeletal dysplasia, intracerebral calcifications, optic atrophy, hearing impairment, and mental retardation: nosology of dysosteosclerosis. *Am J Med Genet* 1992;43:517–23.
3. Sener RN, Yalman O, Cetingul N, Tutuncuoglu S, Kavakli K, Ustun EE. Dysosteosclerosis: clinicoradiologic findings including brain MRI. *Comput Med Imaging Graph* 1997;21:355–7.
4. Elcioglu NH, Vellodi A, Hall CM. Dysosteosclerosis: a case report of three new cases and evolution of the radiological findings. *J Med Genet* 2002;39:603–7.
5. Shanahan CM, Cary NR, Metcalfe JC, Weissberg PL. High expression of genes for calcification-regulating protein in human atherosclerotic plaques. *J Clin Invest* 1994;93:2393–402.
6. Bini A, Mann KG, Kudryk BJ, Schoen FJ. Noncollagenous bone matrix proteins, calcification, and thrombosis in carotid artery atherosclerosis. *Arterioscler Thromb Vasc Biol* 1999;19:1852–61.
7. Nishimura G, Kozlowski K. Osteosclerotic metaphyseal dysplasia. *Pediatr Radiol* 1993;23:450–2.
8. Oncag O, Ozkinay FF, Eronat C. Dysosteosclerosis: a case with unique dental findings and SEM evaluation of a hypoplastic tooth. *J Clin Pediatr Dent* 1999;23:347–52.
9. Otsuka T, Kasai H, Yamaguchi K, Nishihara T. Enamel matrix derivative promotes osteoclast cell formation by RANKL production in mouse marrow cultures. *J Dent* 2005;33:749–55.