



Studies on the potential protective effect of cinnamon against bisphenol A- and octylphenol-induced oxidative stress in male albino rats

Ashraf M. Morgan^{a,*}, Salah S. El-Ballal^b, Badre E. El-Bialy^c,
Nermeen B. EL-Borai^c

^a Toxicology and Forensic Medicine Department, Faculty of Veterinary Medicine, Cairo University, Egypt

^b Pathology Department, Faculty of Veterinary Medicine, El-Sadat City University, Egypt

^c Forensic Medicine & Toxicology Department, Faculty of Veterinary Medicine, El-Sadat City University, Egypt

ARTICLE INFO

Article history:

Received 7 March 2014

Received in revised form 13 April 2014

Accepted 14 April 2014

Available online 9 May 2014

Chemical compounds studied in this article:

Bisphenol A (PubChem CID: 6623)

Octylphenol (PubChem CID: 62530)

Cinnamon cassia bark extract (PubChem
CID: 6850775)

Keywords:

Bisphenol-A

BPA

Octylphenol

OP

Cinnamon

MDA

GSH

CAT

Rats

ABSTRACT

Among the numerous chemicals discharged into the surrounding environment, bisphenol A (BPA) and octylphenol (OP) have been shown to increase oxidative stress in body by disturbing the prooxidant/antioxidant balance of cells. Cinnamon aqueous extract (CAE) is a natural product rich in polyphenolic compounds that have antioxidant activity. This study was designed to investigate the protective efficacy of CAE against oxidative disorders induced by BPA and OP in male albino rats. Animals were divided into 6 groups (10 rats each) and treated orally, 3 times weekly for 50 days. Group 1: control vehicle (olive oil); group 2 (25 mg BPA/kg b.wt./day); group 3 (25 mg OP/kg b.wt./day); group 4 (200 mg CAE/kg b.wt./day); group 5 (CAE 2 h before BPA administration); and group 6 (CAE 2 h before OP administration). BPA- and OP-exposed groups showed insignificant elevation in the final body weight; weight gains and significant reduction only in the relative kidneys weight. Also, BPA and OP exposure resulted in significant increase in serum urea, creatinine and kidney, brain, testicular malondialdehyde (MDA) levels. Significant reduction in tissues reduced glutathione (GSH) contents; catalase (CAT) and superoxide dismutase (SOD) activities were also recorded in BPA and OP exposed animals compared to the control vehicle group. Pretreatment with CAE 2 h either before BPA or OP administration ameliorated the BPA- and OP-induced body weight; weight gains and relative organs weight changes and biochemical adverse effects. CAE pretreatment also protected against the recorded pathological changes in kidney, brain and testis. In conclusion, CAE could ameliorate the oxidative toxic effects of BPA and OP indicating its protective antioxidant effect.

© 2014 The Authors. Published by Elsevier Ireland Ltd. This is an open access article under the CC BY-NC-ND license (<http://creativecommons.org/licenses/by-nc-nd/3.0/>).

1. Introduction

Environmental pollution with hazardous chemicals and metals can arise from natural as well as anthropogenic

sources; many of them cause oxidative stress. Oxidative stress has long been linked with pathogenesis of various diseases in humans. It takes place due to unregulated production of free radicals or reactive oxygen/nitrogen species. Reactive oxygen species (ROS) are cytotoxic agents that lead to damage of nucleic acid bases, lipids and proteins, thereby leading to cell death [6,43].

* Corresponding author. Tel.: +20 1003067323.

E-mail address: Ashrafmorgan550@yahoo.com (A.M. Morgan).

Bisphenol A (BPA) and octylphenol (OP) are endocrine disrupting chemicals (EDCs) that are of scientific interest due to their widespread use and ubiquitous exposures. Beside their endocrine disrupting effect [28,34,56] they are also known to induce oxidative stress [2,3,25,26].

BPA is the building block of polycarbonate plastics, a hard plastic used to make numerous consumer products, including most baby and water bottles. Its final product includes adhesives, coatings, paints and building materials [57]. BPA waste may enter the environment during handling, loading and unloading, heating or releases. BPA can enter the human body through reusable baby bottles [8], food packing materials [27], liquid of canned vegetables [10] and dental sealants [41].

OP is one of the final degradation products of alkylphenol polyethoxylates (APEOs), which are nonionic surfactants used as intermediates or as additives for a wide range of industrial products and processes [19,47]. OPs are used as tackifiers in tire rubber, in recovery of oil in offshore processes, and in printing inks, pesticide formulations (as a dispersant), water based paints, textile auxiliaries, and emulsion polymerization processes [37]. These are generally discharged in large quantities to aquatic environments either directly from untreated effluent or indirectly from sewage treatment plants [33]. Exposure to OPs may occur through ingestion of contaminated foods (e.g. fish) and drinking contaminated water. It may occur also from contact with some personal care products and detergents [12].

Generation of free radicals and antioxidant capacity of the body have been observed to be modulated by environmental, physiological and nutritional factors [31,44]. For example, physiological factors such as aging, alteration of body mass index and obesity and life style confounding factors such as smoking, drinking and high calorie diet have enhancing effect on oxidative stress and suppressive effect on antioxidants [44,48,49].

Natural plant-derived antioxidants are in high demand than synthetic antioxidants because of their potential in health promotion, disease prevention, and their improved safety and consumer acceptability [20,54].

Cinnamon is one of the most widely used plants in herbal medicines with diverse bioactive effects. It is obtained from the inner bark of several trees from the genus *Cinnamomum*. The used species in this study, *Cinnamomum aromaticum* (*C. cassia* or Chinese cinnamon) is an ever green tall tree with thick leathery leaves and yellow flowers [35].

Su et al. [58] indicated that cinnamon may serve as potential dietary source of natural antioxidants for improving human nutrition and health. It is rich in natural polyphenolic compound. Polyphenols act as reactive oxygen and nitrogen species scavengers, redox-active transition metal chelators and enzyme modulators [45].

Previous studies reported that cinnamon stimulates the increase of antioxidant enzymes activities, including SOD and CAT in rat's liver and heart [15,24].

The present study was designed to assess the potential protective effect of *Cinnamomum cassia* aqueous extract against bisphenol A- and octylphenol-induced oxidative stress in the kidney, brain and testis of male albino rats.

2. Materials and methods

2.1. Animals

A total of 60 adult male albino rats weighing between 120 and 150 g were used in this study. They were obtained from the AL-Zyade Experimental Animals Production Center, Giza, Egypt. All animals were housed in polypropylene cages with mesh wire tops in well ventilated room and provided with balanced ration and clean water *ad libitum*. They were kept under observation for two weeks before the beginning of experiments for atmospheric and handling accommodation.

2.2. Chemicals

Bisphenol A (CAS No. 80-05-7; purity of 97%) and 4-Tert-octylphenol (CAS No. 140-66-9; purity of 97%) were purchased from Sigma–Aldrich Company, Germany. Chemicals were dissolved in olive oil (vehicle).

C. cassia bark was purchased from Harraz market, EL-Azhar, Cairo, Egypt. It was identified and authenticated in Botany Department, Faculty of Science, Cairo University.

Diagnostic kits for assaying serum urea and creatinine levels; MDA, GSH levels and CAT, SOD activities in renal, brain and testicular tissue homogenates were purchased from the Biodiagnostic Company, Dokki, Giza, Egypt.

2.3. Preparation of cinnamon aqueous extract (CAE)

The *C. cassia* aqueous extract (CAE) was prepared from the air dried powdered cinnamon bark according to Azab et al. [4]. The aqueous extract was freshly prepared by soaking 10 g of the grinded bark in 100 ml distilled water at 90 °C for 2 h followed by filtration. The filtrate was then dehydrated in oven at 80 °C overnight. The resulting dark reddish brown dry extract was weighed and the dry yield was then calculated.

2.4. Experimental design and animal grouping

Sixty male albino rats were weighed and divided into six equal groups; all were treated orally three times a week for 50 days [25,26].

Group 1: control vehicle (olive oil); group 2 (25 mg BPA/kg b.wt./day); group 3 (25 mg OP/kg b.wt./day); group 4 (200 mg CAE/kg b.wt./day); group 5 (CAE 2 h before BPA administration) and group 6 (CAE 2 h before OP administration). BPA and OP dose was selected according to that previously used by Aydogan et al. [2,3] and Korkmaz et al. [25,26]. However, CAE was given orally at 200 mg/kg/day according to Kim et al. [24] and Azab et al. [4].

2.5. Collection of serum and tissue samples

At the end of the experiment, the animals were fasted overnight and weighed then anaesthetized and sacrificed for samples collection. Blood samples were collected without anticoagulant and centrifuged at 3000 rpm for 15 min for serum separation.

Table 1

Effects of BPA and OP exposure alone and 2 h after CAE administration on the final body weight (g); weight gains (g) and relative organ weights (%) of control and treated rats.

Parameters Groups	Initial b.wt.	Final b.wt.	Weight gains	Relative kidneys weight	Relative brain weight	Relative testes weight
Group 1 (control vehicle)	185 ± 4.159	256 ± 11.570	71 ± 7.932	0.649 ± 0.010	0.678 ± 0.034	1.107 ± 0.026
Group 2 (BPA)	189 ± 7.495	270 ± 9.599	81 ± 4.765	0.580 ± 0.023 ^a	0.605 ± 0.026	1.041 ± 0.035
Group 3 (OP)	189 ± 5.026	264 ± 10.529	75 ± 4.691	0.594 ± 0.017 ^a	0.624 ± 0.016	1.057 ± 0.043
Group 4 (CAE)	186 ± 5.987	260 ± 10.046	74 ± 5.711	0.600 ± 0.019	0.625 ± 0.035	1.017 ± 0.039
Group 5 (CAE + BPA)	187 ± 3.564	253 ± 4.174	66 ± 1.550	0.614 ± 0.017	0.633 ± 0.016	1.130 ± 0.026
Group 6 (CAE + OP)	175 ± 7.227	241 ± 16.667	66 ± 9.976	0.631 ± 0.019	0.672 ± 0.045	1.173 ± 0.080

Values are presented as mean ± S.E. (n = 10 animals/group).

^a Significantly different from group 1 at P < 0.05.

Kidneys, brain and testes of each rat were collected and divided into two parts, one part stored at -20 °C for tissue biochemical investigations while the other part was kept in 10% formalin for the histopathological examination.

2.6. Estimation of kidney functions

Serum urea and creatinine levels were measured using the colorimetric method of Fawcett and Soctt [18] and Schirmeister et al. [50], respectively.

2.7. Estimation of tissues lipid peroxidation product, MDA levels

MDA was determined in kidneys, brain and testes tissue homogenates according to the procedure described by Ohkawa et al. [39].

2.8. Estimation of tissues antioxidant parameters

GSH concentration, CAT and SOD activities were determined in Kidneys, brain and testes tissue homogenates according to Beutler et al. [7], Aebi [1] and Nishikimi et al. [38], respectively.

2.9. Histopathological examination

Kidney, brain and testes tissue samples intended for the histopathological investigations were fixed in 10% neutral formalin, prepared and stained according to Bancroft et al. [5].

2.10. Statistical analysis

Values are presented as mean ± standard error (SE). Statistical significance of toxic oxidative effects of BPA and OP on kidneys, brain and testes and the protective effect of CAE were determined by one way ANOVA according to Snedecor and Cochran [55]. All statistical analyses were performed using SPSS (Statistical package for Social Sciences) Version 16 released on 2007.

3. Results

3.1. Effects on the final body weight, weight gain and relative organ weights

Oral administration of BPA (group 2) or OP (group 3) induced insignificant elevation in the final body weight;

weight gains with significant reduction in the relative kidneys weight. However, brain and testes relative weights were insignificantly reduced compared to the control vehicle group (group 1). Oral administration of CAE 2 h before BPA (group 5) and OP (group 6) exposure induced insignificant decrease in the final body weight; weight gains compared to the BPA- (group 2) and OP- (group 3) exposed groups, respectively. However, the relative kidneys, brain and testes weights were insignificantly increased as revealed in Table 1.

3.2. Effects on the biochemical parameters

3.2.1. Effects on kidney function (serum urea and creatinine levels)

The recorded nephrotoxic alterations in Table 2 revealed that oral administration of BPA (group 2) or OP (group 3) induced significant elevation in serum urea and creatinine levels compared to control vehicle group. CAE pretreatment 2 h before BPA (group 5) or OP (group 6) administration ameliorated their nephrotoxic effects as indicated by significant reduction in serum urea and creatinine levels compared to the BPA- (group 2) and OP- (group 3) treated groups, respectively.

3.2.2. Effects on the tissues lipid peroxidation product, MDA

The obtained results (Table 3) revealed that kidney, brain and testes MDA levels were significantly increased in BPA- (group 2) and OP- (group 3) treated groups compared to the control vehicle group. Oral administration of CAE 2 h before BPA or OP exposure, induced significant decrease in MDA levels in these organs compared to the

Table 2

Effects of BPA and OP exposure alone and 2 h after CAE administration on serum urea and creatinine levels (mg/dl) of control and treated rats.

Parameters Groups	Urea	Creatinine
Group 1 (control vehicle)	32.80 ± 0.65	1.61 ± 0.05
Group 2 (BPA)	36.50 ± 0.97 ^a	1.81 ± 0.02 ^a
Group 3 (OP)	35.60 ± 0.87 ^a	1.76 ± 0.03 ^a
Group 4 (CAE)	28.50 ± 0.87	1.57 ± 0.04
Group 5 (CAE + BPA)	27.10 ± 0.78 ^b	1.60 ± 0.05 ^b
Group 6 (CAE + OP)	27.30 ± 0.99 ^c	1.53 ± 0.06 ^c

Values are presented as mean ± S.E. (n = 10 animals/group).

^a Significantly different from group 1 at P < 0.05.

^b Significantly different from group 2 at P < 0.05.

^c Significantly different from group 3 at P < 0.05.

Table 3

Effects of BPA and OP exposure alone and 2 h after CAE administration on MDA levels in kidney, brain and testicular tissues of control and treated rats.

Groups	MDA (nmol/g)		
	Kidney	Brain	Testis
Group 1 (control vehicle)	47.08 ± 0.94	43.52 ± 0.51	44.68 ± 0.61
Group 2 (BPA)	50.20 ± 0.77 ^a	46.44 ± 0.83 ^a	47.16 ± 0.53 ^a
Group 3 (OP)	49.90 ± 0.63 ^a	46.22 ± 0.58 ^a	47.60 ± 0.72 ^a
Group 4 (CAE)	48.26 ± 0.95	44.56 ± 0.75	43.94 ± 0.73
Group 5 (CAE + BPA)	47.42 ± 0.57 ^b	42.08 ± 0.56 ^b	44.08 ± 0.50 ^b
Group 6 (CAE + OP)	47.24 ± 0.78 ^c	41.46 ± 0.42 ^c	43.76 ± 0.91 ^c

Values are presented as mean ± S.E. (n = 10 animals/group).

^a Significantly different from group 1 at $P < 0.05$.

^b Significantly different from group 2 at $P < 0.05$.

^c Significantly different from group 3 at $P < 0.05$.

BPA- and OP-treated groups, respectively and became as that of control.

3.2.3. Effects on tissues antioxidant defense system

Significant reduction in kidney, brain and testicular GSH concentrations, CAT and SOD activities of BPA- (group 2) and OP- (group 3) exposed animals was observed on comparison with the control vehicle group. CAE pretreatment 2 h before BPA (group 5) or OP (group 6) administration ameliorated these effects and kept kidney, brain and testicular GSH concentrations and CAT, SOD activities within normal range compared to control vehicle group (Tables 4 and 5).

In all the investigated parameters, CAE alone-treated group showed insignificant changes compared to the control one.

3.2.4. Effects on histological structures of the investigated organs

BPA and OP oral administration alone at 25 mg/kg/day (three times/week for 50 days each) induced histopathological changes in the kidneys, brain and testis of exposed rats. However, CAE pretreatment (200 mg/kg/day, orally, three times/week for 50 days) 2 h before BPA and OP exposure ameliorated these alterations by variable degrees (Figs. 1–3).

Table 5

Effects of BPA and OP exposure alone and 2 h after CAE administration on CAT and SOD activities (U/g tissue) in kidney, brain and testicular tissues of control and treated rats.

Enzyme	CAT			SOD		
	Kidney	Brain	Testis	Kidney	Brain	Testis
Group 1 (control vehicle)	3.403 ± 0.046	1.556 ± 0.033	1.517 ± 0.055	616.0 ± 4.81	684.8 ± 4.15	695.4 ± 3.72
Group 2 (BPA)	2.845 ± 0.217 ^a	1.417 ± 0.023 ^a	1.318 ± 0.044 ^a	544.8 ± 4.86 ^a	635.0 ± 4.14 ^a	678.6 ± 4.12 ^a
Group 3 (OP)	2.927 ± 0.024 ^a	1.428 ± 0.036 ^a	1.335 ± 0.012 ^a	564.0 ± 4.18 ^a	669.4 ± 3.92 ^a	683.4 ± 3.54 ^a
Group 4 (CAE)	3.602 ± 0.042	1.575 ± 0.035	1.516 ± 0.059	630.8 ± 4.04	724.4 ± 5.83	712.6 ± 4.02
Group 5 (CAE + BPA)	3.488 ± 0.033 ^b	1.599 ± 0.067 ^b	1.446 ± 0.030 ^b	562.4 ± 3.86 ^b	728.8 ± 3.40 ^b	732.0 ± 4.09 ^b
Group 6 (CAE + OP)	3.395 ± 0.025 ^c	1.587 ± 0.043 ^c	1.469 ± 0.038 ^c	581.2 ± 3.97 ^c	744.8 ± 3.68 ^c	743.6 ± 3.98 ^c

Values are presented as mean ± S.E. (n = 10 animals/group).

^a Significantly different from group 1 at $P < 0.05$.

^b Significantly different from group 2 at $P < 0.05$.

^c Significantly different from group 3 at $P < 0.05$.

Table 4

Effects of BPA and OP exposure alone and 2 h after CAE administration on GSH concentrations in kidney, brain and testicular tissues of control and treated rats.

Groups	GSH (mg/g)		
	Kidney	Brain	Testis
Group 1 (control vehicle)	46.40 ± 1.17	27.62 ± 0.75	37.30 ± 0.73
Group 2 (BPA)	40.72 ± 1.38 ^a	24.92 ± 0.34 ^a	34.16 ± 0.58 ^a
Group 3 (OP)	41.12 ± 1.11 ^a	25.10 ± 0.42 ^a	34.46 ± 0.81 ^a
Group 4 (CAE)	47.56 ± 0.91	28.48 ± 1.15	37.66 ± 0.71
Group 5 (CAE + BPA)	45.26 ± 1.24 ^b	29.54 ± 1.27 ^b	38.44 ± 0.62 ^b
Group 6 (CAE + OP)	46.10 ± 0.88 ^c	30.14 ± 0.81 ^c	38.56 ± 0.93 ^c

Values are presented as mean ± S.E. (n = 10 animals/group).

^a Significantly different from group 1 at $P < 0.05$.

^b Significantly different from group 2 at $P < 0.05$.

^c Significantly different from group 3 at $P < 0.05$.

3.2.4.1. Effects on the kidney. The recorded renal histopathological alterations induced by BPA and OP exposure alone and the ameliorating effect of CAE pretreatment 2 h prior their administration are shown in Fig. 1.

Kidney of olive oil-treated rats (group 1) showed normal renal glomeruli and tubules with slight congestion. The kidney sections of BPA-exposed rats (group 2) showed glomerular congestion and hypercellularity; cloudy swelling in proximal convoluted tubules (PCT) with obstructed lumen and intertubular congestion. Similarly, the kidney of OP-exposed rats (group 3) showed glomerular congestion, hemorrhage and hypercellularity, cloudy swelling in proximal convoluted and collecting renal tubules.

Kidney of CAE-treated rats (group 4) showed more or less normal renal glomeruli and tubules with slight congestion.

Pretreatment with CAE 2 h before BPA (group 5) or OP (group 6) intoxication ameliorated most of the observed changes in renal morphology. This was represented by slight glomerular congestion and hypercellularity with more or less normal renal tubules in the CAE + BPA-treated group. The same protective effect of CAE was observed in CAE + OP-treated rats but without hypercellularity.

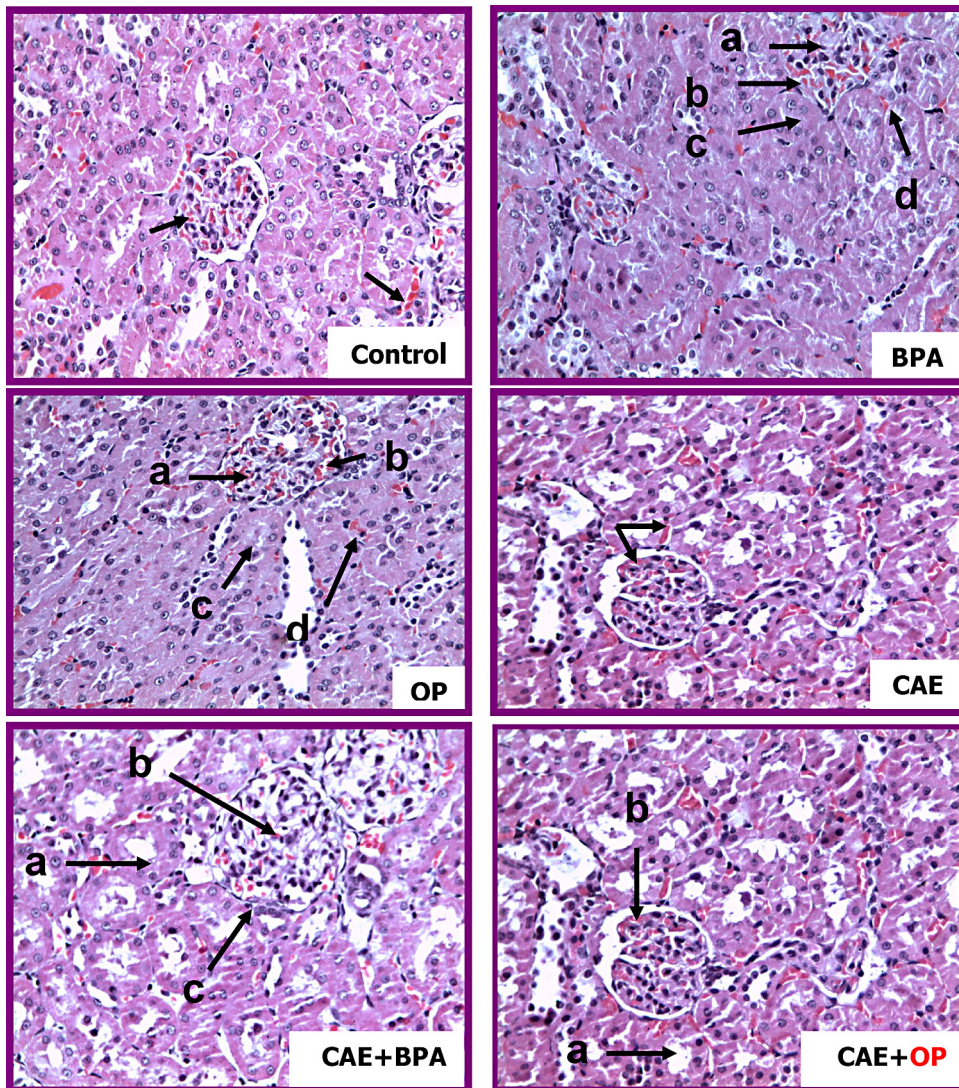


Fig. 1. Kidney photomicrographs of: I. olive oil-treated (control vehicle) rat showing more or less normal renal cortex with slight congestion (arrows) (H&E, X 40). II. A bisphenol-A (BPA)-intoxicated rat showing glomerular congestion (a) and hypercellularity (b), cloudy swelling in proximal convoluted tubules (PCT) with obstructed lumen (c) and intertubular congestion (d) (H&E, X 40). III. An octyl phenol (OP)-intoxicated rat showing glomerular congestion (a), hemorrhage (b) and hypercellularity (c), cloudy swelling (d) in proximal convoluted and collecting renal tubules (H&E, X 40). IV. A cinnamon aqueous extract (CAE)-treated rat showing more or less normal tissue (renal cortex) with slight congestion (arrows) (H&E, X 40). V. A rat pretreated with CAE 2 h before BPA administration showing normal proximal convoluted and collecting tubules (a) with slight glomerular congestion (b) and hypercellularity (c) (H&E, X 40). VI. A rat pretreated with cinnamon 2 h before OP administration showing normal proximal convoluted and collecting tubules (a) with slight glomerular congestion (b) without hypercellularity (H&E, X 40).

3.2.4.2. *Effects on the brain.* BPA- and OP-induced brain oxidative damage and the protective effect of CAE pretreatment 2 h prior their administration are shown in Fig. 2.

Normal cerebellum and white matter were observed in the brain of the olive oil-exposed animals. The obtained photomicrographs from brain of BPA-exposed rats showed central chromatolysis in neuron, pyknosis, perineuronal satellitosis and neuronophagia in mid brain (motor area). Brain sections of OP-exposed rats showed chromatolysis, pyknosis, perineuronal microgliosis and neuronophagia.

CAE-treated rat's brain showed more or less normal cerebellum and white matter.

Pretreatment with CAE 2 h before BPA or OP intoxication protected against BPA- and OP-induced brain morphological alterations that was indicated by the recorded more or less normal brain cerebellum and white matter of the CAE + BPA-treated animals and of the CAE + OP-treated ones.

3.2.4.3. *Effects on the testes.* The observed testicular histopathological alterations induced by BPA and OP exposure alone and the ameliorating effect of CAE pretreatment 2 h prior their administration are shown in Fig. 3.

Photomicrograph of testis of olive oil-treated rats showed more or less normal seminiferous tubules.

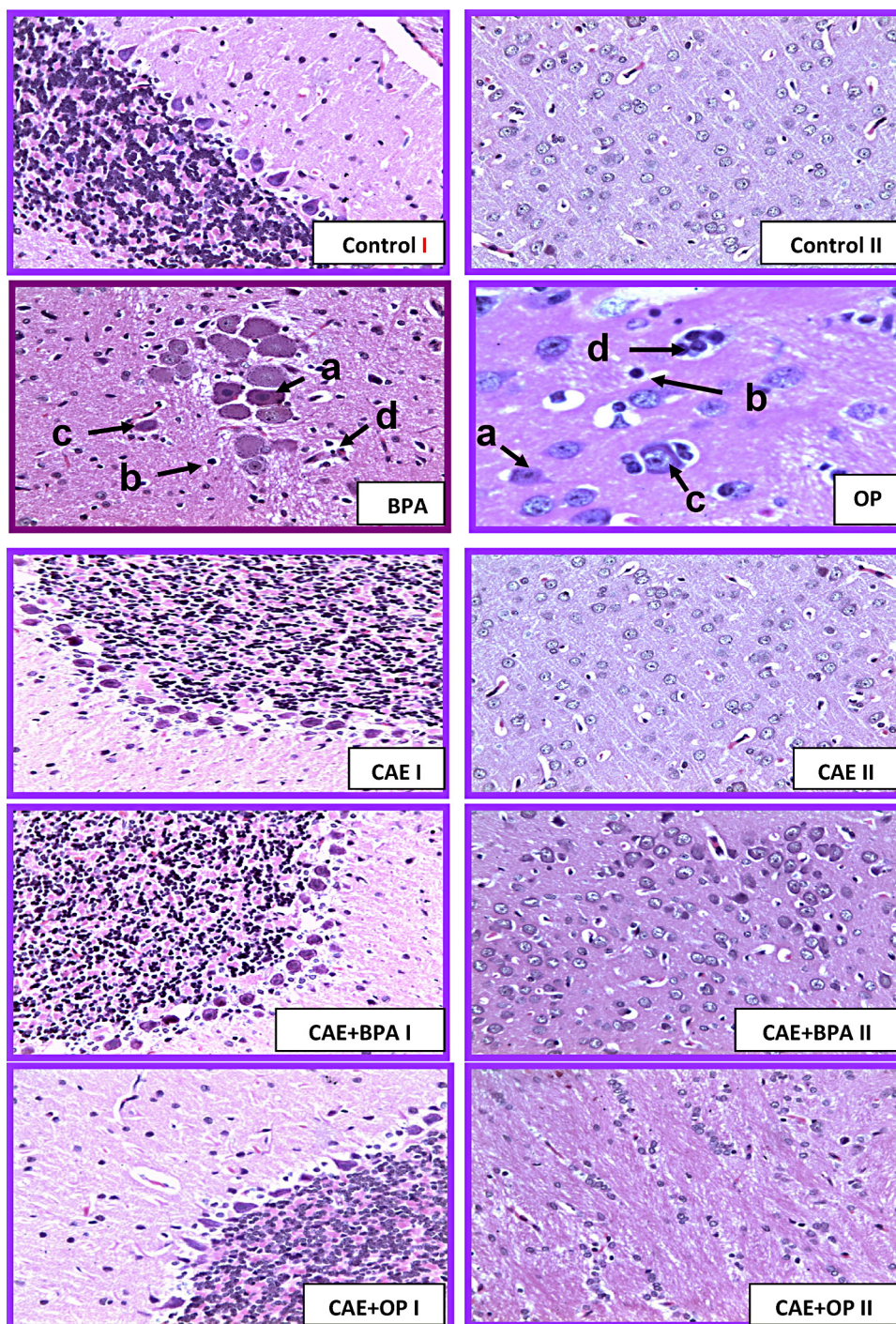


Fig. 2. Brain photomicrographs of: I. an olive oil-treated rat showing more or less normal cerebellum (I) and white matter (II) (H&E, X 40). II. A bisphenol-A (BPA)-intoxicated rat showing central chromatolysis in neuron (a), pyknosis (b), perineuronal satellitosis (c) and neuronophagia (d) in mid brain (motor area) (H&E, X 100). III. An octyl phenol (OP)-intoxicated rat showing chromatolysis (a), pyknosis (b), perineuronal microgliosis (c) and neuronophagia (d) (H&E, X 100). IV. A cinnamon aqueous extract (CAE)-treated rat showing more or less normal cerebellum (I) and white matter (II) (H&E, X 40). V. A rat pretreated with CAE 2 h before BPA administration showing more or less normal cerebellum (I) and white matter (II) (H&E, X 40). VI. A rat pretreated with cinnamon 2 h before OP administration showing more or less normal cerebellum (I) and white matter (II) (H&E, X 40).

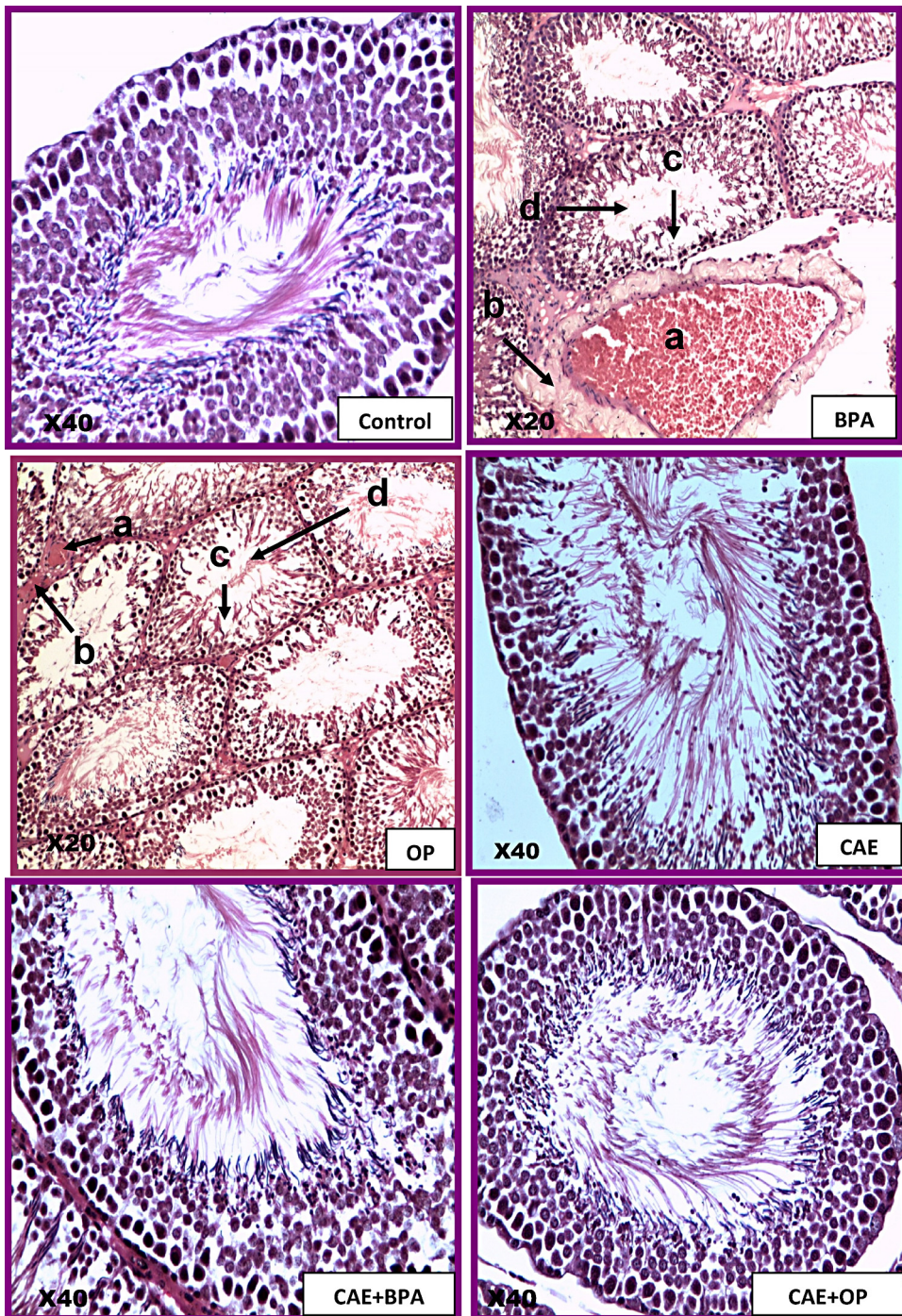


Fig. 3. Testis photomicrographs of: I. an olive oil-treated rat showing normal histological structures (H&E, X 40). II. A bisphenol-A (BPA)-intoxicated rat showing hyperemia (a), perivascular edema (b), testicular degeneration (c) and cellular debris in the lumen (d) (H&E, X 20). III. An octyl phenol (OP)-intoxicated rat showing hyperemia (a), perivascular edema (b), testicular degeneration (c) and cellular debris in the lumen (d) (H&E, X 20). IV. A cinnamon aqueous extract (CAE) treated rat showing normal histological structures (H&E, X 40). V. A rat pretreated with CAE 2 h before BPA administration showing normal histological structures (H&E, X 40). VI. A rat pretreated with cinnamon 2 h before OP administration showing normal histological structures (H&E, X 40).

However, testes of BPA-treated rats showed hyperemia, perivascular edema, testicular degeneration and cellular debris in the lumen. Also, testis of OP-treated rats showed hyperemia, perivascular edema and testicular degeneration.

CAE-treated rat's testis showed normal seminiferous tubules.

CAE+BPA-treated rats showed more or less normal seminiferous tubules. Similarly, normal seminiferous tubules were also seen in CAE + OP-treated animals.

4. Discussion

Exposure to several chemicals and environmental contaminants has been reported to increase oxidative stress in body by disturbing the prooxidant/antioxidant balance of cells [2,22]. BPA and OP were previously reported to induce oxidative damage in several tissues [2,3,25,26].

It is widely accepted that antioxidants may delay or inhibit the oxidation of lipids or other molecules by inhibiting the initiation, or propagation of oxidizing chain reactions [61]. These involve absorption and neutralization of free radicals, quenching singlet and triplet oxygen, and decomposing peroxides [42].

Considerable attention has recently been focused on some nutritional factors such as polyphenols that could counteract oxidative damages and therefore be beneficial through their antioxidant properties [32,45]. Among plants that contain polyphenols is cinnamon that may be of special interest, since cinnamon and CAE has been documented to be *in vitro* and *in vivo* antioxidant [4,30] and [17].

In consistent with our results, various investigators reported that BPA or OP exposure of rats and mice resulted in insignificant difference in final b.wt., weight gain, relative brain and testes weights [2,9,23,25,59,62–65] but significant decrease in relative kidneys weight was observed [66]. On the contrary, significant changes in body weight, weight gain and relative organs weight were reported by others [46,59,67–69]. These discrepancies in weight changes may be related to the differences in doses, routes, duration, and time of exposure; rat and mice strains, sex and nature of food.

The recorded insignificant increase in body weight could be attributed to the ability of BPA to stimulate the accumulation of triacylglycerol in 3T3-L1 preadipocytes [70,71]; to affect gene expression in fatty tissues [72] and genes involved in metabolic syndrome [73] and to hypothyroidism [74] that resulted in weight gain, enhancement of glucose transport in adipocytes [75].

Several animal studies showed that over-stimulation of the estrogen receptor- α (ER α) in pancreatic β -cells by estrogen or BPA produced an excessive insulin signaling in the liver, endothelium and in fat, thus potentially leading to obesity, glucose intolerance, and dyslipidemia [76–79].

Bisphenol A and OP administration has been reported to cause an increase in the thiobarbituric acid reactive substances (TBARS) levels in the kidneys, brain and testes of male rats [2,3,26]. Kabuto et al. [80] attributed the underdevelopment of the kidneys, brain, and testes to the increased levels of TBARS in BPA-exposed mice. This may explain

the recorded decrease in relative kidneys, brain and testes weights.

The reduction in body weights with CAE pretreatment may be resulted from its ability to decrease fat mass percent [81]. Also, the increased relative kidneys, brain and testes weights may be referred to its antioxidant properties and the reduction of TBARS levels in these organs [4,15].

In coincidence with our results, Suberg et al. [82] and Saleh [83] recorded increased serum urea and creatinine levels after BPA or OP oral administration. On contrary, Til et al. [66] recorded decreased creatinine levels in male rats at and above 500 mg/kg BPA.

The elevated urea and creatinine levels recorded in our results may be resulted from the observed BPA- and OP-induced peroxidative effects that were confirmed by the photographed renal histopathological alterations. Also, BPA- and OP have been reported to induce hyperglycemia that may result in kidney damage and renal dysfunction and consequently greatly increased serum urea, creatinine and uric acid [84,85].

The nephroprotective effects of cinnamon were previously recorded by El-Yamani [85] who observed decreased serum urea and creatinine levels in diabetic rats treated with cinnamon.

In the present study, BPA and OP administration resulted in lipid peroxidation in kidney, brain and testicular tissues that was represented by the significantly increased MDA levels and reduced GSH concentrations and CAT; SOD activities. However, CAE pre-treatment ameliorated these oxidative effects.

BPA and OP exposure caused oxidative stress by disturbing the balance between ROS and antioxidant defenses system in kidney, brain and testis of rats [2,3,26,86] and mice administered BPA throughout the embryonic/fetal life and during infancy [80].

BPA has been shown to be decomposed to many kinds of metabolites including BPA radical by a reaction with radical oxygen [87]. Several evidences indicated that BPA exerts potent oxidant activity in various tissues *via* ROS production which results in inhibition of antioxidant enzymes; increased H₂O₂ and lipid peroxidation products, LPO [9,13,14,23,88].

The present study confirmed the previously recorded antioxidant effect of cinnamon *in vitro* [52] and *in vivo* [17] that was indicated by decreased MDA levels and increased antioxidant enzymes activities. Murcia et al. [36] found that cinnamon extract exhibited protective capacity against irradiation-induced LPO in liposomes, and quenched hydroxyl radicals (OH^{*}) and H₂O₂. The protective action of cinnamon extract against radiation-induced oxidative and inflammatory damages was attributed to its suppressive effect on ROS generation. This is due to its phenolic and flavonoids contents, in addition to modification of gene expression by inhibiting nuclear factor-kappa B (NF-Kb) activation [4]. Polyphenols act as reactive oxygen and nitrogen species scavengers, redox-active transition metal chelators and enzyme modulators [45]. The high reactivity of the hydroxyl substituent of flavonoids with the number of hydroxyl groups on the B-ring being correlates with ROS scavenging capability [11,21,51].

5. Conclusion

In conclusion, the results of this study revealed that oral BPA and OP administration induced adverse oxidative effects on the exposed animals as evidenced by the recorded abnormalities in the investigated biochemical parameters. In addition, there were histopathological alterations in the investigated organs. Pretreatment with CAE provided a protective antioxidant role against such adverse effects.

Conflict of interest

The authors declare that they have no conflict of interest.

References

- [1] H. Aebi, Catalase *in vitro*, *Methods Enzymol.* 105 (1984) 121–126.
- [2] M. Aydogan, A. Korkmaz, N. Barlas, D. Kolankaya, The effect of vitamin C on bisphenol A, nonylphenol and octylphenol induced brain damages of male rats, *Toxicology* 249 (2008) 35–39.
- [3] M. Aydogan, A. Korkmaz, N. Barlas, D. Kolankaya, Pro-oxidant effect of vitamin C coadministration with bisphenol A, nonylphenol, and octylphenol on the reproductive tract of male rats, *Drug Chem. Toxicol.* 33 (2) (2010) 193–203.
- [4] K.S. Azab, A.H.A. Mostafa, E.M.M. Ali, M.A.S. Abdel-Aziz, Cinnamon extract ameliorates ionizing radiation-induced cellular injury in rats, *Ecotoxicol. Environ. Saf.* 74 (2011) 2324–2329.
- [5] D. Bancroft, A. Stevens, R. Turner, *Theory and Practice of Histological Techniques*, 4th ed., Churchill Livingstone, Edinburgh, London, Melbourne, 1996.
- [6] K.J. Barnham, C.L. Masters, A.I. Bush, Neurodegenerative diseases and oxidative stress, *Nat. Rev. Drug Discov.* 3 (2004) 205–214.
- [7] E. Beutler, O. Duron, B.M. Kelly, Improved method for the determination of blood glutathione, *J. Lab. Clin. Med.* 61 (1963) 882–888.
- [8] J.E. Biles, T.P. McNeal, T.H. Begley, H.C. Hollifield, Determination of bisphenol A in reusable polycarbonate food-contact plastics and migration to food-simulating liquids, *J. Agric. Food Chem.* 45 (9) (1997) 3541–3544.
- [9] V. Bindhumol, K.C. Chitra, P.P. Mathur, Bisphenol A induces reactive oxygen species generation in the liver of male rats, *Toxicology* 188 (2003) 117–124.
- [10] J.A. Brotons, M.F. Olea-Serrano, V.M. Villalobos, V. Pedraza, N. Olea, Xenoestrogens released from lacquer coatings in food cans, *Environ. Health Perspect.* 103 (1995) 608–612.
- [11] S. Burda, W. Oleszek, Antioxidant and antiradical activities of flavonoids, *J. Agric. Food Chem.* 49 (2001) 2774–2779.
- [12] A.M. Calafat, X. Ye, L.Y. Wong, J.A. Reidy, L.L. Needham, Exposure of the US population to bisphenol A and 4-tertiary-octylphenol: 2003–2004, *Environ. Health Perspect.* 116 (1) (2008) 39–44.
- [13] K.C. Chitra, C. Latchoumycandane, P.P. Mathur, Induction of oxidative stress by bisphenol A in the epididymal sperm of rats, *Toxicology* 185 (1–2) (2003) 119–127.
- [14] K.C. Chitra, K.R. Rao, P.P. Mathur, Effect of bisphenol A and co-administration of bisphenol A and vitamin C on epididymis of adult rats: a histopathological and biochemical study, *Asian J. Androl.* 5 (2003) 203–208.
- [15] J.N. Dhuley, Anti-oxidant effects of cinnamon (*Cinnamomum verum*) bark and greater cardamom (*Amomum subulatum*) seeds in rats fed high fat diet, *Indian J. Exp. Biol.* 37 (1999) 238–242.
- [17] A. Eidi, P. Mortazavi, M. Bazargan, J. Zaringhalam, Hepatoprotective activity of cinnamon ethanolic extract against CCl₄-induced liver injury in rats, *EXCLI J.* 11 (2012) 495–507.
- [18] J.K. Fawcett, J.E. Socc, A rapid and precise method for the determination of urea, *J. Clin. Pathol.* 13 (1960) 156–159.
- [19] K. Guenther, V. Heinke, B. Thiele, E. Kleist, H. Prast, T. Raecker, Endocrine disrupting nonylphenols are ubiquitous in food, *Environ. Sci. Technol.* 36 (8) (2002) 1676–1680.
- [20] I. Gulcin, Antioxidant activity of caffeic acid (3,4-dihydroxycinnamic acid), *Toxicology* 217 (2006) 213–220.
- [21] K.E. Heim, A.R. Tagliaferro, D.J. Bobilya, Flavonoid antioxidants: chemistry, metabolism and structure–activity relationships, *J. Nutr. Biochem.* 10 (2002) 572–584.
- [22] Y.S. Ho, J.L. Magnenat, M. Gargano, J. Cao, The nature of antioxidant defense mechanisms: a lesson from transgenic studies, *Environ. Health Perspect.* 106 (5) (1998) 1219–1228.
- [23] H. Kabuto, S. Hasuike, N. Minagawa, T. Shishibori, Effects of bisphenol A on the metabolisms of active oxygen species in mouse tissues, *Environ. Res.* 93 (1) (2003) 31–35.
- [24] S.H. Kim, S.H. Hyun, S.Y. Choung, Antioxidative effects of *Cinnamomum cassia* and *rhodiola rosea* extracts in liver of diabetic mice, *Biofactor* 26 (2006) 209–219.
- [25] A. Korkmaz, M. Aydogan, D. Kolankaya, N. Barlas, Influence of vitamin C on bisphenol A, nonylphenol and octylphenol induced oxidative damages in liver of male rats, *Food Chem. Toxicol.* 48 (10) (2010) 2865–2871.
- [26] A. Korkmaz, M. Aydogan, D. Kolankaya, N. Barlas, Vitamin C coadministration augments bisphenol A, nonylphenol, and octylphenol induced oxidative damage on kidney of rats, *Environ. Toxicol.* 26 (4) (2011) 325–337.
- [27] A.V. Krishnan, P. Staris, S.F. Permut, L. Tokes, D. Feldman, Bisphenol-A: an estrogenic substance is released from polycarbonate flasks during autoclaving, *Endocrinology* 132 (6) (1993) 2279–2286.
- [28] S.C. Laws, S.A. Carey, J.M. Ferrell, G.J. Bodman, R.L. Cooper, Estrogenic activity of octylphenol, nonylphenol, bisphenol A and methoxychlor in rats, *Toxicol. Sci.* 54 (1) (2000) 154–167.
- [30] C.C. Lin, S.J. Wu, C.H. Chang, L.T. Ng, Antioxidant activity of *Cinnamomum cassia*, *Phytother. Res.* 17 (7) (2003) 726–730.
- [31] M. Lopez-Torres, R. Gredilla, A. Sanz, G. Barja, Influence of aging and longterm caloric restriction on oxygen radical generation and oxidative DNA damage in rat liver mitochondria, *Free Radic. Biol. Med.* 32 (2002) 882–889.
- [32] W. Luczaj, E. Zapora, M. Szczepanski, K. Wnuczko, E. Skrzydlewska, Polyphenols action against oxidative stress formation in endothelial cells, *Acta. Pol. Pharm.* 66 (6) (2009) 617–624.
- [33] R.J. Maguire, Review of the persistence of nonylphenol and nonylphenol ethoxylates in aquatic environments, *Water Qual. Res. J. Can.* 34 (1999) 37–78.
- [34] J.A. McLachlan, K.S. Korach, Symposium on Estrogens in the Environment III, *Environ Health Perspect.* 103 (7) (1995) 3–4.
- [35] B. Mukerji, *The Indian Pharmaceutical Codex. vol. 1. Indigenous drugs*, Council of Scientific and Industrial Research, India, 1953, pp. 255–260.
- [36] M.A. Murcia, I. Egea, F. Romojaro, P. Parras, A.M. Jimenez, M. Martinez-Tome, Antioxidant evaluation in dessert spices compared with common food additives. Influence of irradiation procedure, *J. Agric. Food Chem.* 52 (2004) 1872–1881.
- [37] A.C. Nimrod, W.H. Benson, Environmental estrogenic effects of alkylphenol ethoxylates, *Crit. Rev. Toxicol.* 69 (1996) 335–364.
- [38] M. Nishikimi, N.A. Roa, K. Yagi, The occurrence of superoxide anion in the reaction of reduced phenazine methosulfate and molecular oxygen, *Biochem. Biophys. Res. Commun.* 46 (1972) 849–854.
- [39] H. Ohkawa, N. Ohishi, K. Yagi, Assay for lipid peroxides in animal tissues by thiobarbituric acid reaction, *Anal. Biochem.* 95 (1979) 351–358.
- [41] N. Olea, R. Pulgar, P. Perez, F. Olea-Serrano, A. Rivas, A. Novillo-Fertrell, V. Pedraza, A.M. Soto, C. Sonnenschein, Estrogenicity of resin-based composites and sealants used in dentistry, *Environ. Health Perspect.* 104 (1996) 298–305.
- [42] T. Osawa, Novel natural antioxidants for utilization in food and biological systems, in: I. Uritani, V.V. Garcia, E.M. Mendoza (Eds.), *Postharvest Biochemistry of Plant Food-Materials in the Tropics*, Japan Scientific Societies Press, Tokyo, Japan, 1994, pp. 241–251.
- [43] G. Perry, A. Nunomura, S.L. Siedlak, P.L.R. Harris, X. Zhu, R.J. Castellani, G. Aliev, M.A. Smith, Oxidant and antioxidant responses in Alzheimer disease, *Recent Res. Dev. Biophys. Biochem.* 1 (2001) 35–41.
- [44] T.P.K. Reddy, K.R. Kanala, A.E. de Dios, J.M. Cantu Garza, Age-related correlation between antioxidant enzymes and DNA damage with smoking and body mass index, *J. Gerontol. A Biol. Sci. Med. Sci.* 63 (2008) 360–364.
- [45] C.A. Rice-Evans, N.J. Miller, G. Papanga, Antioxidant properties of phenolic compounds, *Trends Plant Sci.* 2 (1997) 152–159.
- [46] B.S. Rubin, M.K. Murray, D.A. Damassa, J.C. King, A.M. Soto, Perinatal exposure to low doses of bisphenol A affects body weight, patterns of estrous cyclicity, and plasma LH levels, *Environ. Health Perspect.* 109 (2001) 675–680.
- [47] I. Saito, A. Onuki, H. Seto, Indoor air pollution by alkylphenols in Tokyo, *Indoor Air* 14 (5) (2004) 325–332.

- [48] M. Sancho-Tello, M. Muriach, J. Barcia, F. Bosch-Morell, J.M. Genovés, S. Johnsen-Soriano, B. Romero, I. Almansa, M. Díaz-Llopis, S. García-Delpech, J. Romá, F.J. Romero, Chronic alcohol feeding induces biochemical, histological, and functional alterations in rat retina, *Alcohol Alcohol.* 43 (2008) 254–260.
- [49] T. Sasaki, K. Unno, S. Tahara, A. Shimada, Y. Chiba, M. Hoshino, T. Kaneko, Age-related increase of superoxide generation in the brains of mammals and birds, *Aging Cell* 4 (2008) 459–469.
- [50] J. Schirmeister, Determination of creatinine level, *Dtsch. Med. Wschr.* 89 (1964) 1940–1947.
- [51] A. Sekher, T.S. Pannala-Chan, P.J. O'Brien, C.A. Rice-Evans, Flavonoid B-ring chemistry and antioxidant activity: fast reaction kinetics, *Biochem. Biophys. Res. Commun.* 282 (2001) 116–118.
- [52] S. Shobana, K.A. Naidu, Antioxidant activity of selected Indian spices, *Prostaglandins Leukot. Essent. Fatty Acids* 62 (2000) 107–110.
- [54] M. Skerget, P. Kotnik, M. Hadolin, A.R. Hras, M. Simonic, Z. Knez, Phenols, proanthocyanidins, flavones and flavonols in some plant materials and their antioxidant activities, *Food Chem.* 89 (2005) 191–198.
- [55] G.W. Snedecor, W.G. Cochran, *Statistical Methods*, 17th ed., The Iowa State University Press, Ames, IA, 1987, pp. 221–222.
- [56] A.M. Soto, C. Sonnenschein, K.L. Chung, M.F. Fernandez, N. Olea, F.O. Serrano, The E-SCREEN assay as a tool to identify estrogens: an update on estrogenic environmental pollutants, *Environ Health Perspect.* 103 (7) (1995) 113–122.
- [57] C.A. Staples, P.B. Dome, G.M. Klecka, S.T. Oblock, L.R. Harris, A review of the environmental fate, effects, and exposures of bisphenol A, *Chemosphere* 36 (10) (1998) 2149–2173.
- [58] L. Su, J.J. Yin, D. Charles, K. Zhou, J. Moore, L. Yu, Total phenolic contents, chelating capacities, and radical-scavenging properties of black peppercorn, nutmeg, rosehip, cinnamon and oregano leaf, *Food Chem.* 100 (2007) 990–997.
- [59] O. Takahashi, S. Oishi, Testicular toxicity of dietary 2, 2-bis(4-hydroxyphenyl) propane (bisphenol A) in F344 rats, *Arch. Toxicol.* 75 (2001) 42–51.
- [61] Y. Velioglu, G. Mazza, L. Gao, B. Oomah, Antioxidant activity and total phenolics in selected fruits, vegetables, and grain products, *J. Agric. Food Chem.* 46 (10) (1998) 4113–4117.
- [62] C.B. Herath, W. Jin, G. Watanabe, K. Arai, A.K. Suzuki, K. Taya, Adverse effects of environmental toxicants, octylphenol and bisphenol A, on male reproductive functions in pubertal rats, *Endocrine* 25 (2004) 163–172.
- [63] H. Kawaguchi, Y. Umekita, H. Yoshida, Effects of 4-n-Octylphenol on the induction of Mammary Tumors Induced by 7,12-Dimethylbenz[a]anthracene in Rats, *Vet. Pathol.* 46 (2) (2009) 334–342.
- [64] S.K. Sahambi, A. Pelland, G.M. Cooke, T. Schrader, R. Tardif, M. Charbonneau, K. Krishnan, S. Haddad, D.G. Cyr, P.J. Devine, Oral p-tert-octylphenol exposures induce minimal toxic or estrogenic effects in adult female Sprague-Dawley rats, *J. Toxicol. Environ. Health, Part A* 73 (9) (2010) 607–622.
- [65] S. Jain, C.H. Mahendra Kumar, U.D. Suranagi, P.K. Mediratta, Protective effect of N-acetylcysteine on bisphenol A-induced cognitive dysfunction and oxidative stress in rats, *Food Chem. Toxicol.* 49 (2011) 1404–1409.
- [66] H.P. Tii, W.G. Roverts, R.B. Beems, Sub-chronic (90 day) oral toxicity study with diphenylolpropane (DPP) in rats, Unpublished report No. R 6229, TNO, The Netherlands, 1978.
- [67] Q. Bian, J. Qian, L. Xu, J. Chen, L. Song, X. Wang, The toxic effect of 4-tert-octylphenol on the reproductive system of male rat, *Food Chem. Toxicol.* 44 (2006) 1355–1361.
- [68] J. Miyawaki, K. Sakayama, H. Kato, H. Yamamoto, H. Masuno, Perinatal and postnatal exposure to bisphenol A increases adipose tissue mass and serum cholesterol level in mice, *J. Atheroscler Thromb.* 14 (5) (2007) 245–252.
- [69] L.A. Humadi, The Toxic Effects following Gestational and Lactational Exposure of Rats to 4-tert-octylphenol on the Subsequent Development of the Vas Deferens Tissue, *Am-Euras. J. Toxicol. Sci.* 3 (3) (2011) 161–171.
- [70] H. Masuno, J. Iwanami, T. Kidani, K. Sakayama, K. Honda, Bisphenol A accelerates terminal differentiation of 3T3-L1 cells into adipocytes through the phosphatidylinositol 3-kinase pathway, *Toxicol. Sci.* 84 (2005) 319–327.
- [71] K. Wada, H. Sakamoto, K. Nishikawa, S. Sakuma, A. Nakajima, Y. Fujimoto, Y. Kamisaki, Life style-related diseases of the digestive system: endocrine disruptors stimulate lipid accumulation in target cells related to metabolic syndrome, *J. Pharmacol. Sci.* 105 (2007) 133–137.
- [72] E. Somm, V.M. Schwitzgebel, A. Toulotte, C.R. Cederroth, C. Combescure, S. Nef, M.L. Aubert, P.S. Huppi, Perinatal exposure to bisphenol A alters early adipogenesis in the rat, *Environ. Health Perspect.* 117 (2009) 1549–1555.
- [73] A. Marmugi, S. Ducheix, F. Lasserre, A. Polizzi, A. Paris, N. Priymenko, J. Bertrand-Michel, T. Pineau, H. Guillou, P.G. Martin, L. Mselli-Lakhal, Low doses of bisphenol A induce gene expression related to lipid synthesis and trigger triglyceride accumulation in adult mouse liver, *Hepatology* 55 (2) (2012) 395–407.
- [74] K. Moriyama, T. Tagami, T. Akamizu, T. Usui, M. Saijo, N. Kanamoto, Y. Hataya, A. Shimatsu, H. Kuzuya, K. Nakao, Thyroid hormone action is disrupted by Bisphenol A as an antagonist, *J. Clin. Endocrinol. Metab.* 87 (11) (2002) 5185–5190.
- [75] K. Sakurai, M. Kawazuma, T. Adachi, T. Harigaya, Y. Saito, N. Hashimoto, C. Mori, Bisphenol, A affects glucose transport in mouse 3T3-F442A adipocytes, *Br. J. Pharmacol.* 141 (2) (2004) 209–214.
- [76] P. Alonso-Magdalena, S. Morimoto, C. Ripoll, E. Fuentes, A. Nadal, The estrogenic effect of bisphenol A disrupts pancreatic β -cell function *in vivo* and induces insulin resistance, *Environ. Health Perspect.* 114 (1) (2006) 106–112.
- [77] P. Alonso-Magdalena, A.B. Ropero, M.P. Carrera, C.R. Cederroth, M. Baquie, B.R. Gauthier, S. Nef, E. Stefani, A. Nadal, Pancreatic insulin content regulation by the estrogen receptor ER α , *PLoS One* 3 (4) (2008) e2069.
- [78] A.B. Ropero, P. Alonso-Magdalena, E. Garcia-Garcia, C. Ripoll, E. Fuentes, A. Nadal, Bisphenol-A disruption of the endocrine pancreas and blood glucose homeostasis, *Int. J. Androl.* 31 (2) (2008) 194–200.
- [79] A. Nadal, P. Alonso-Magdalena, S. Sorian, I. Quesada, A.B. Ropero, The pancreatic- β -cell as a target of estrogens and xenoestrogens: implications for blood glucose homeostasis and diabetes, *Mol. Cell Endocrinol.* 304 (1–2) (2009) 63–68.
- [80] H. Kabuto, M. Amakawa, T. Shishibori, Exposure to bisphenol A during embryonic/fetal life and infancy increases oxidative injury and causes underdevelopment of the brain and testis in mice, *Life Sci.* 74 (24) (2004) 2931–2940.
- [81] T.N. Ziegenfuss, J.E. Hofheins, R.W. Mendel, J. Landis, R.A. Anderson, Effects of a water-soluble cinnamon extract on body composition and features of the metabolic syndrome in pre-diabetic men and women, *J. Int. Soc. Sports Nutr.* 3 (2006) 45–53.
- [82] H. Suberg, E. Loser, G. Kaliner, *Subchronic toxicologische Untersuchungen an Ratten*, Bayer AG, Institut für Toxikologie, 1982, pp. 10733.
- [83] E.M. Saleh, Antioxidant effect of aqueous extract of propolis on hepatotoxicity induced by octylphenol in male rats, *Acta. Toxicol. Argent.* 20 (2) (2012) 68–81.
- [84] A.A.E. Mansour, Robable Benefic of some leaves of tumor plants as remedy for hypercholesterolemic and hyperglycemic rats, Faculty of Home Economics, Minufiya University, 2009, M.Sc. Thesis.
- [85] M.A.S. EL-Yamani, Cinnamon, cardamom and ginger impacts as evaluated on hyperglycemic rats, vol. 20, *Research of Specific Education Mansoura University*, 2011, pp. 664–679.
- [86] M. Chen, B. Xu, W. Ji, S. Qiao, N. Hu, Y. Hu, Y. Wu, L. Qiu, R. Zhang, Y. Wang, S. Wang, Z. Zhou, Y. Xia, Y. Wang, Bisphenol A alters n-6 fatty acid composition and decreases antioxidant enzyme levels in rat testes: A LC-QTOF-based metabolomics study, *PLoS ONE* 7 (9) (2012) e44754.
- [87] J. Sajiki, Decomposition of bisphenol A by radical oxygen, *Environ. Int.* 27 (2001) 315–320.
- [88] T. Obata, S. Kubota, Formation of hydroxyl radicals by environmental estrogen-like chemicals in rat striatum, *Neurosci. Lett.* 296 (1) (2000) 41–44.