

## CLINICAL FEATURES SERIES

### Medical Grand Rounds: Refractory Hypertension and Renal Insufficiency in a Patient with Renal Artery Stenosis

Stephen J. Huot, Leslie M. Scoutt and George H. Meier III

*Yale Vascular Center and Yale-New Haven Hospital, New Haven, Connecticut*

(Received October 17, 1996)

---

The following case was presented at Medical Grand Rounds at the Yale-New Haven Hospital and the Yale School of Medicine by Stephen J. Huot, Assistant Professor of Medicine (Nephrology) with accompanying discussion of diagnostic ultrasound studies by Dr. Leslie Scoutt, Associate Professor of Diagnostic Radiology, and discussion of surgical management by Dr. George Meier, Associate Professor of Surgery.

---

#### INTRODUCTION

*Dr. Stephen J. Huot:*

The clinical features, natural history, diagnosis and management of renal artery stenosis in patients with hypertension and renal insufficiency will be illustrated by discussion of a patient evaluated at the Yale Vascular Center. Dr. Leslie Scoutt, Department of Diagnostic Imaging, will discuss the utility of renal doppler ultrasound studies for diagnosing renal artery stenosis and review the findings in this patient. Dr. George Meier, Department of Surgery, will discuss surgical approaches and management of patients with complex vascular disease manifested by renal artery stenosis and renal insufficiency.

#### CASE PRESENTATION

The patient is a 72 year old white woman who presented in July 1995 with refractory hypertension and progressive renal insufficiency. Her clinical course is outlined in Figure 1. She was first diagnosed with high blood pressure in 1970 which had been successfully controlled with medication until September 1994. At that time, her blood pressure became poorly controlled, requiring several changes in her medications. Her blood pressure remained elevated despite these changes. She stated that she was compliant with her medications, was not taking any over-the-counter drugs such as non-steroidal anti-inflammatory agents or decongestants, and that her weight had been stable with no change in her physical activity level.

In January 1995, four months after the documented worsening of blood pressure control, the patient was admitted to her local hospital in New York with unstable angina and ruled in for a non-Q-wave myocardial infarction. Echocardiogram revealed anterior and inferior hypokinesis with an estimated ejection fraction of 38 percent. There was both tricuspid and mitral regurgitation. On the second hospital day, despite treatment with aspirin,

---

*<sup>a</sup>To whom all correspondence should be addressed:* Stephen J. Huot, Department of Internal Medicine, Yale University School of Medicine, 87 LMP, 333 Cedar Street, New Haven, CT 06520-8033. Tel: 203-785-7249; FAX: (203) 785-7258; email: stephen\_huot@qm.yale.edu.

*<sup>b</sup>Abbreviations:* RAS, renal artery stenosis; PSV, peak systolic velocity; AI, acceleration index; RI, resistive index; ESP, early systolic peak; AT, acceleration time; RAR, renal-aortic ratio; RVH, renovascular hypertension; CRS, captopril renal scan; ATN, acute tubular necrosis.

intravenous nitroglycerin and intravenous heparin, she developed recurrent chest pain with anterior-lateral electrocardiogram changes and was transferred to Yale-New Haven Hospital (YNHH) for cardiac catheterization. Upon arrival at YNHH, the patient was noted to have renal insufficiency with a blood urea nitrogen (BUN) of 38 mg/dl and a serum creatinine of 3.0 mg/dl. She was also found to have congestive heart failure which was successfully treated with diuretic agents.

A cardiac angiogram performed on the third hospital day revealed an ulcerated, proximal stenosis of 90 percent involving the left anterior descending coronary artery. The following day she underwent angioplasty of this lesion and placement of a Palmaz-Schatz stent. She did well clinically with respect to her cardiac disease with no recurrent chest pain or congestive heart failure.

Review of her medical records documented a serum creatinine in April 1994 of 1.4 mg/dl. When admitted to the hospital in New York in January 1995, her BUN and creatinine were 37 mg/dl and 2.8 mg/dl, respectively, which was attributed to pre-renal azotemia. Following cardiac catheterization her serum creatinine transiently peaked at 3.8 mg/dl, and decreased to 3.2 mg/dl by the time of discharge. Evaluation of her renal insufficiency included urinalyses that were negative for protein, a 24 hour urine collection with a calculated creatinine clearance of 35 ml/min, and a renal ultrasound examination which showed no hydronephrosis, increased echogenicity bilaterally and preserved kidney size (right kidney 10.1 cm, left kidney 12.6 cm). The transient increase in serum creatinine during this hospitalization was attributed to dye-induced acute tubular necrosis (ATN) associated with her catheterization. The etiology of her elevated creatinine prior to admission, however, was not clear.

The patient was discharged on January 24, 1995 and went home in stable condition with local follow-up in New York. Medications at discharge were dipyridamole, 75 mg three times daily; enteric coated aspirin, 325 mg once daily; warfarin, 2.5 mg daily; doxazosin, 5 mg daily; labetalol, 400 mg twice daily; cardidopa-levodopa, 50/200 and 25/100 each once daily; amantadine, 100 mg daily; selegiline, 2.5 mg daily; and prednisone, 7.5 mg daily. One month after discharge her coumadin and persantine were discontinued as planned.

In April 1995, two months after coronary angioplasty, the patient noticed bluish, mottled appearing lesions on her toes and feet bilaterally. She developed pitting edema that extended from her ankles to her thighs. Despite the addition of furosemide, 40 mg daily, the lesions and edema persisted. She was then referred to the Yale Vascular Center in June 1995. Pulse volume recordings of the lower extremities demonstrated adequate large vessel flow and the etiology of her lesions was believed to be embolic. Evaluation for focal cardiac or aortic sources of embolization with transesophageal echocardiogram and magnetic resonance imaging of the chest and abdomen were negative, although diffuse atherosclerotic disease was documented. Her blood pressure at this time was 190/114 mm Hg and her serum creatinine was 3.8 mg/dl. Because of her refractory hypertension and renal insufficiency, the diagnosis of renal artery stenosis was entertained. An evaluation was initiated that included a 24 h urine collection to quantify renal function and proteinuria, serologic and additional urine studies to rule out primary renal disease and a captopril renal scan (CRS), measuring renal uptake of radiolabeled captopril, as an initial evaluation for renal artery stenosis (RAS). Her furosemide and labetalol doses were increased to address her poor blood pressure control, and the patient was scheduled to return for follow-up.

She returned to the Vascular Center on August 4, 1995 reporting anorexia, fatigue and nausea. Her blood pressure was improved but still elevated at 178/100 mm Hg. Her serologic studies were unrevealing for any primary renal disease, such as lupus nephritis, vasculitis, etc. Her captopril renal scan showed no isotope uptake by the right kidney and normal perfusion and normal time to peak isotope activity in the left kidney. The report was

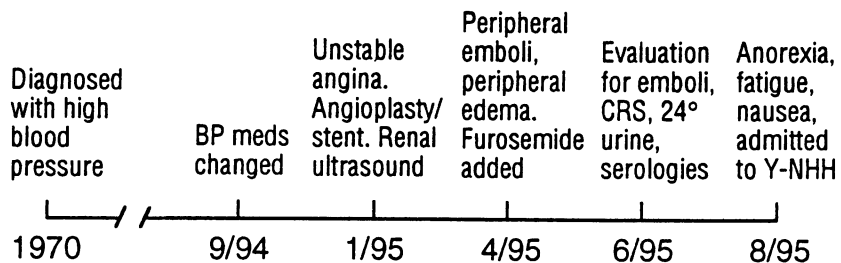
consistent with non-functioning right kidney and no scintigraphic evidence of renal artery stenosis on the left. Follow-up blood work obtained at this visit revealed significant worsening of renal function. BUN and creatinine were 102 mg/dl/ and 5.8 mg/dl, respectively. Calculated creatinine clearance was only 8 ml/min and 24 h urinary protein excretion was 580 mg. Despite the negative CRS, renal artery stenosis was still considered a possible diagnosis for this patient because of the her clinical course.

The patient was therefore admitted to YNHH for treatment of worsening renal function, hypertension management and further evaluation for possible renal artery stenosis or other etiology of progressive renal failure with atheroembolic disease being of significant concern.

Her past medical history included Parkinson's disease for seven years with good symptom control and polymyalgia rheumatica for one year treated with prednisone, 2.5 mg daily. She had a twenty pack-year smoking history but stopped smoking thirty years ago, did not drink alcohol and had retired from pediatric nursing two years earlier. She denied any history of elevated cholesterol, or diabetes, or family history of cardiovascular, cerebrovascular, or renal disease.

On physical examination, the blood pressure was 178/100 mm Hg lying down with a pulse of 60 beats per minute. The fundoscopic exam showed no exudate, hemorrhage or papilledema. There was no jugular venous distention. The lungs were clear. There was a normal S1 and S2 on cardiac exam with a grade II/VI systolic murmur heard along the left lower sternal border. There was no pericardial rub. The abdomen had normal bowel sounds, no organomegaly and no anterior abdominal or flank bruits. Examination of the extremities revealed bilateral 1-plus ankle edema, warm feet with good capillary refill and a mottled bluish hue to all toes. There were several small necrotic lesions on three of the toes distally. Vascular exam revealed intact pulses throughout with no bruits. Neurologic exam was notable for a slight intention tremor of the hands and a slight slowing of speech but otherwise was nonfocal.

SCr (mg/dl)	—	3	—	3.8	5.8
BP (mm/Hg)	180/100	168/90	—	190/114	178/100



SCr = Serum Creatinine  
 BP = Blood Pressure

Figure 1. Clinical course of the patient.

## DISCUSSION

In summary, our patient is a 72 year old woman with long-standing hypertension that over the preceding nine months became difficult to control. This occurred during a time when she developed progressive renal failure, coronary artery disease requiring angioplasty and stent placement, and embolic arterial disease of the lower extremities. Evaluation for primary renal disease showed no evidence of this. Captopril renal scan showed non-function of the right kidney and no scintigraphic evidence of renal artery stenosis on the left. A renal ultrasound examination done in January 1995 documented echogenic kidneys, no hydronephrosis and preserved renal size. Creatinine clearance was now only 8 ml/minute and the patient would likely require chronic dialysis in the near future unless a reversible process could be identified and treated.

Our two leading diagnoses were 1) renal artery stenosis causing renovascular hypertension (RVH) and renal failure due to ischemia, or 2) renal failure due to atheroembolic disease of the kidneys with subsequent exacerbation of hypertension. There were several important clinical questions that needed to be addressed to determine the most appropriate way to evaluate this patient. These were (a) given the likely etiology of her worsening renal function and refractory hypertension, is the process reversible? (b) what is the safest diagnostic approach to determine if this patient has renal artery stenosis given her degree of renal insufficiency, history of embolic disease, and co-morbid illness? and (c) if a stenotic lesion is identified that could be surgically approached, what is the likelihood of improvement in renal function and/or blood pressure control and what revascularization procedure would be most appropriate?

Relevant to answering these questions is an understanding of the prevalence, natural history, and clinical characteristics of patients with RAS and RVH.

*Prevalence.* Data from autopsy series, studies of patients undergoing aortograms, and studies of patients referred for cardiac catheterization show a prevalence of RAS that ranges from 29 percent to 60 percent. None of these represent an "unselected" patient population and therefore undoubtedly overestimate the prevalence of RAS in the general population. Interestingly, the prevalence of bilateral disease among patients with renal artery stenosis is quite high as illustrated in Table 1. The incidence of bilateral disease reported in the 5 studies presented in this table range from 27 percent to 66 percent of patients with arteriographically documented RAS [1-8].

**Table 1. Natural history of atherosclerotic renovascular disease: reports of serial angiograms [5]**

Reference	Months of follow-up	Number	Percent with † progression	Percent with total occlusion‡
Wollenweber 1968	12-88	30	70	NA
Meaney 1968	6-120	39	36	8
Dean 1981	6-102	35	29	11
Schreiber 1984	12- >60	85	44	16
Tollefson 1991	15-180	48	71	15
Total		237	49	14

† Progression of disease includes worsening of already stenosed renal artery or development of contralateral renal artery stenosis; ‡ Total occlusion of a single stenosed renal artery. NA = Not Available.

*Natural History.* A small number of studies have looked at the natural history of renal artery stenosis. Two of the most important ones are summarized here. In 1981, Dean and colleagues reported the results of a prospective study in which patients with "surgically correctable" RAS were randomized to receive either medical or surgical therapy for treatment of hypertension (Table 1) [6]. Forty-one patients were randomized to the medical treatment group. Thirty five of these 41 had a follow-up angiogram from 6 to 102 months after initial screening (mean, 28 months). Twelve percent progressed to complete occlusion of the original lesion by 12 months and another 17 percent developed contralateral stenosis. Blood pressure control did not correlate with likelihood of progression. Morbidity and overall mortality were not reported and no comparison was made with the group randomized to surgery.

In 1984 Schreiber and colleagues reported a retrospective study which included 85 hypertensive patients with atherosclerotic RAS who had follow-up arteriograms from 6 to 84 months after their initial study [7]. Thirty seven of the 85 patients (44 percent) showed progression of the original lesion including 14 (16 percent of patients overall) who progressed to total occlusion. Progression to occlusion occurred more frequently and more rapidly in patients with a greater degree of stenosis at baseline. As in the Dean study, blood pressure control did not correlate with progression and only 54 percent of the patients with occlusion had an increase in serum creatinine. Of note, 70 percent of the patients with progression had a decrease in renal size. Decrease in renal size has also been reported in a number of other studies to correlate with progression of renal artery stenosis.

*Clinical Characteristics.* The clinical characteristics associated with RAS are advanced age, history of tobacco use, and documented vascular disease such as a history of claudication or angina, or presence of a bruit on physical examination. Documented vascular disease is the clinical characteristic that correlates most closely with presence of RAS. It does not, however, predict functional status of a stenosis. Racial differences in prevalence of RAS are controversial. Early studies reported a very low prevalence of RAS and RVH in black hypertensive patients. However, more recent studies refute this premise. For example, a study reported by Svetky et al. in 1991 used arteriograms to evaluate sixty seven black and ninety seven white hypertensive patients with clinical characteristics consistent with the possible diagnosis of RAS [9]. Twenty-seven percent of the white hypertensives and 20 percent of the black hypertensives had RAS (no significant difference). Half of the patients in each group had RVH in that blood pressure control improved with revascularization. Additional studies have reported similar results. Therefore, although RAS may be slightly more prevalent in white hypertensives, it is also common in black hypertensives.

The patient we are discussing today had advanced age, history of tobacco use, and documented vascular disease. We thought it likely that she had renal artery stenosis and possibly renovascular hypertension. Given the prevalence and natural history of RAS, we also thought it possible that she had developed bilateral disease and that this was the cause of her deterioration in renal function.

*Diagnosis.* There are two categories of diagnostic tests available to help determine whether or not patients have RAS and RVH. These include functional studies and a variety of imaging modalities (Table 2).

Of the functional studies, plasma renin assays vary significantly with sodium intake, volume status, cardiac output and even position. Blood pressure response to pharmacologic agents such as angiotensin-converting enzyme inhibitors is dependent on volume status and co-morbid conditions and is also not reliable [3, 10]. CRSs are commonly used at YNH and will be discussed in greater detail.

**Table 2. Diagnostic tests for renal artery stenosis**

---

FUNCTIONAL STUDIES
Captopril Renal Scans
Plasma Renin Assay
Blood Pressure Response to Pharmacologic Agents
IMAGING MODALITIES
Arteriography
Digital Subtraction Arteriography
Magnetic Resonance Arteriography
CO <sub>2</sub> Arteriography
Doppler Ultrasound
Spiral CT

---

CRS were initially validated in patients over age 55 with poorly controlled or refractory hypertension who had a history of tobacco use and evidence of vascular disease [11]. In this group, the test was 91 percent sensitive and 94 percent specific for identifying patients with atherosclerotic RAS. In addition, the presence of captopril-induced changes on the renal scan correlated with a high likelihood of improved blood pressure response to revascularization (15 of 18 patients revascularized improved). Patients who had RAS and a negative CRS were less likely to respond to revascularization with an improvement in blood pressure control (3 of 18 patients improved,  $p = .0004$ ). The test is therefore often used to identify patients with RAS who are most likely to benefit with improved blood pressure following revascularization. However, the test has not been validated in normotensive patients with renal insufficiency and it is less sensitive for identifying hypertensive patients with RAS in the setting of bilateral renal artery stenosis, stenosis in patients with a single functioning kidney, or in patients with severe renal insufficiency [12].

These issues were of concern in the interpretation of our patient's study. She had severe renal insufficiency and her CRS showed a nonfunctioning right kidney. Physiologically this is equivalent to trying to identify stenosis in a patient with a solitary kidney. Utility of the test in this setting is therefore limited. Given her presentation and the presence of clinical characteristics consistent with RAS, we felt it likely that she had the disease despite a negative CRS and decided to proceed with imaging studies. Choosing the appropriate imaging study in this particular patient, however, was not straightforward because of her history of artheroembolic disease, congestive heart failure, and renal insufficiency.

There are six imaging modalities available to visualize the renal arteries (Table 2). Each has limitations and benefits. Conventional arteriography is considered the "gold standard." Contrast induced nephropathy and atheroembolism from arterial puncture and cannulation of the renal arteries pose significant risks in patients with renal insufficiency and diffuse vascular disease as was the case in our patient [3, 13, 14]. The presence of an anatomic lesion on arteriogram also does not necessarily mean the patient has renovascular hypertension or that the stenosis is the cause of renal insufficiency if present. Our initial focus therefore was to try to rule out RAS with non-invasive or with less invasive imaging procedures rather than proceed directly with a renal arteriogram.

With intravenous digital subtraction angiography, computer enhancement provides an improved image of the renal arteries after injection of contrast. While avoiding

manipulation of the aorta and renal arteries, the results are technically limited by obesity, movement, and presence of bowel gas and it still requires the administration of contrast dye. Intra-arterial digital subtraction angiography provides higher quality images but offers minimal advantage over conventional arteriography in that it requires intra-arterial injection of contrast, though often with a lower volume of dye [13, 15].

Magnetic resonance arteriography is an evolving technology that holds great promise as a non-invasive arterial imaging technique [16]. Presently, respiratory artifact, peristalsis, tortuous vessels, calcification of atheromatous lesions, and turbulent flow are limiting factors. The procedure is still experimental at many institutions and requires validation with conventional arteriography. In addition, current magnetic resonance arteriography does not provide high resolution imaging of the celiac axis and its branches which are frequently used in revascularization procedures for patients with complex vascular disease. This technique is also not sensitive for identifying stenoses in smaller accessory vessels or in branch vessels.

Carbon dioxide arteriography has been developed as a non-contrast imaging alternative to conventional arteriography [17]. Advantages are that CO<sub>2</sub> is nonallergenic, is not nephrotoxic and is considerably less expensive than contrast dye. Presently, the technique is limited in that it requires intra-arterial injection, has considerable variability in quality due to bowel gas and peristalsis, and there is difficulty with the CO<sub>2</sub> injection systems. It is an alternative for patients with known contrast dye allergy but is not suitable for routine imaging of patients with suspected renal artery stenosis.

Doppler ultrasound is the imaging modality we chose to pursue initially. Although current Doppler ultrasound technology has limitations, the procedure is non-invasive and poses no risk to the patient. We reasoned that if the study were of high technical quality and demonstrated patent renal arteries, we could avoid contrast administration. Also, given the association of decreasing renal size with progression of renal artery stenosis, we were interested in reassessing the current size of this patient's kidneys [15, 18].

Dr. Leslie Scoutt from the Diagnostic Imaging Department will address the use and limitations of doppler ultrasound for diagnosing RAS and review the findings in this patient.

*Dr. Leslie Scoutt:*

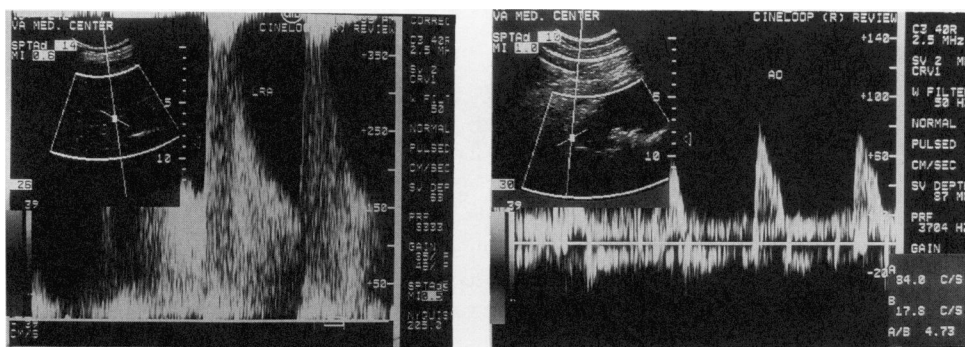
As discussed by Dr. Huot, angiography remains the radiographic gold standard for the diagnosis of RAS. However, as also discussed, angiography is a suboptimal screening modality, is expensive, invasive, potentially nephrotoxic, and there is risk of atheroembolism.

Doppler ultrasound, a safe, noninvasive, and relatively inexpensive technique, provides both physiologic and anatomic data and has been explored since the 1980s as a method of screening patients for RAS. Most ultrasound studies consider that an obstructing lesion must reduce the arterial diameter by  $\geq 60$  percent to be hemodynamically significant and diagnostic of RAS. There are two techniques for diagnosing RAS by Doppler ultrasound, both of which were applied to the patient we are discussing.

The first technique requires visualization of the entire main renal artery to search for a focal area of increased peak systolic velocity (PSV) and post-stenotic turbulence at the anatomic site of a stenosis. The second technique requires demonstration of a decrease in the rate of systolic acceleration within parenchymal renal arteries distal to a stenosis.

PSV increases focally at the anatomic site of a hemodynamically significant stenosis. Most authors consider a PSV  $> 180$  cm/sec to be highly suggestive of RAS [19, 20]. As noted above, to diagnose RAS by this ultrasound technique, post-stenotic turbulence should be present as well. Because PSV can vary with cardiac output, the ratio of peak

systolic velocity of the main renal artery is compared to peak systolic velocity of the abdominal aorta (renal-aortic ratio: RAR). Studies have shown that an RAR > 3.5 has a sensitivity of 84-91 percent and a specificity of 95-98 percent for the diagnosis of RAS (Figure 2) [21-23].

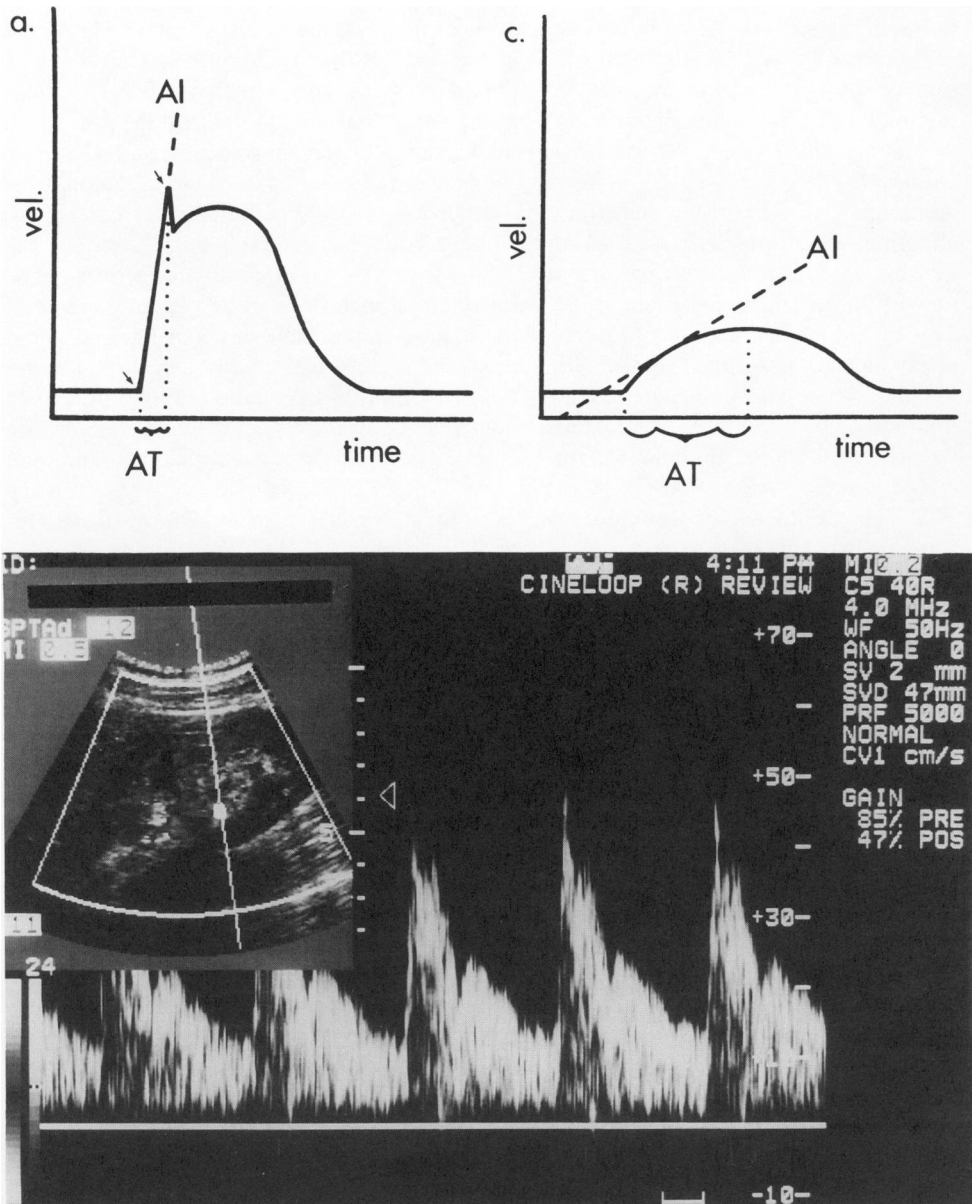


**Figure 2.** (a) Doppler interrogation of the origin of the left renal artery reveals marked elevation of peak systolic velocity (PSV) > 350 cm/sec while (b) PSV in the aorta is 84 cm/sec yielding an RAR of over 4. These findings are consistent with a high-grade renal artery stenosis of the left main renal artery.

However, there are many limitations to this technique. The examination is technically difficult, requiring a great deal of expertise with examination times of up to 1-2 h. Even in expert hands, visualization of the entire main renal artery may be impossible in 30-40 percent of patients due to obesity, overlying bowel gas, and aortic calcifications. In addition, the course of the renal arteries is generally tortuous such that the angle of insonation is often suboptimal (> 60 percent) leading to overestimation of velocity. The deep location of the renal arteries, transmitted cardiac/aortic pulsations, as well as respiratory variation may make Doppler sampling difficult. Furthermore, accessory renal arteries, which may occur in 14-24 percent of patients, are rarely detected by color or pulse Doppler examination [24]. Nor would it be likely that stenoses in smaller branch vessels could be detected by this technique. In addition, inadvertent sampling of collateral vessels have also resulted in false-negative examinations in patients with renal artery occlusions [21-23].

The second Doppler ultrasound technique for diagnosing RAS involves measuring the rate of systolic acceleration in renal parenchymal arteries which has been reported to decrease distal to a hemodynamically significant stenosis. In fact, the decrease in systolic acceleration becomes more pronounced as blood proceeds distal to the stenosis [25, 26]. Hence, the rate of systolic acceleration may be measured within the renal sinus or parenchyma. Such measurements may be accomplished in virtually all patients, thereby eliminating many of the technical as well as theoretical problems with the previously described approach for diagnosing RAS. The explanation for this phenomenon is quite complex and is, in part, attributable to a decrease in perfusion pressure distal to a hemodynamically significant stenosis. Vessel compliance, peripheral resistance, vessel length and diameter as well as the number of distal vessels all effect the rate of systolic acceleration. In general, a decrease in vessel compliance will increase pulsatility or the rate of systolic acceleration and attenuate potential *tardus parvus* effects (see below) caused by



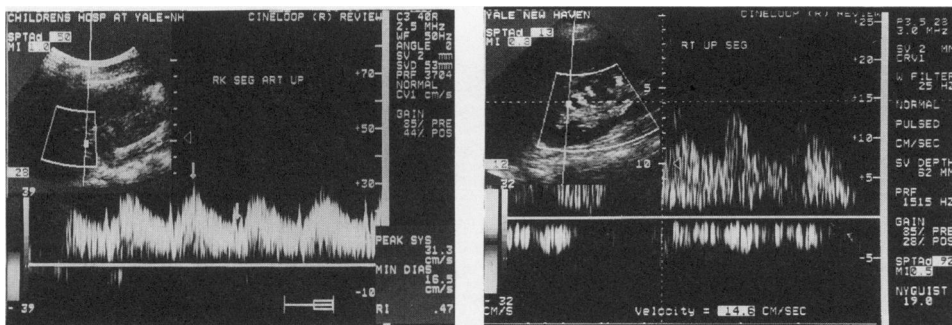


**Figure 3. (a) Diagram of the waveform of the normal renal artery.** The acceleration index (AI) is the slope of the line in  $m/sec^2$  from the onset of systole to the early systole peak complex (ESP) (arrows). The acceleration time (AT) is the time in seconds from the onset of systole to the ESP. **(b) Normal parenchymal renal arterial waveform.** There is continuous forward diastolic flow as the normal renal vascular tree has a low peripheral vascular resistance. The normal RI should be less than 0.7. Note the steep, almost vertical slope of the AI and short AT indicating a rapid rate of systolic acceleration. **(c) Diagram of the *tardus parvus* waveform.** Note rounding and flattening of the systolic peak. The AI is more horizontal, i.e. decreased, and the AT is prolonged. These findings are indicative of a delay in the rate of systolic acceleration and are consistent with a hemodynamically significant renal artery stenosis. (Reprinted with permission from Raven Press).

systolic acceleration and attenuate potential *tardus parvus* effects (see below) caused by an upstream stenosis [25, 26].

The rate of systolic acceleration may be evaluated by calculating the acceleration index, acceleration time, or by visual analysis of the renal artery waveform. Stavros et al. [27] defined the acceleration index (AI) as the slope of the line from the onset of systole to the early systolic peak complex (ESP) in meters per second squared and the acceleration time (AT) as the time in seconds from the onset of systole to the ESP (Figure 3a). In their study, an  $AI < 3.0 \text{ m/s}^2$  was 85 percent accurate, 89 percent sensitive, and 83 percent specific for diagnosing RAS (> 60 percent diameter reduction). An  $AT \geq 0.07$  seconds had an accuracy of 89 percent, sensitivity of 78 percent, and a specificity of 94 percent. An abnormal waveform, defined as loss of the ESP or rounding/flattening of the systolic peak, the so-called *tardus parvus* waveform, (Figure 3b) was even more reliable with an accuracy of 96 percent, a sensitivity of 95 percent, and a specificity of 97 percent (Figure 4). This technique can be used to monitor the results of percutaneous transluminal angioplasty as well as surgical revascularization as the renal waveform should normalize following a successful procedure (Figure 4). Rene et al. [28] have reported that premedication with captopril makes this test more sensitive. Schwerk et al. [29] have also demonstrated that the RI of intraparenchymal renal arteries will decrease in patients with moderate to severe RAS.

While this Doppler technique can be adequately performed in almost all patients, some theoretical issues remain unresolved. The technique is more sensitive for diagnosing severe rather than moderate RAS [27, 28]. Lesions within branch vessels or accessory renal arteries may still be missed, although sampling in multiple areas within the kidney (upper, middle and lower poles) will reduce this possibility. Nonetheless, collateral blood flow around a high grade stenosis or occlusion may still obscure the diagnosis of RAS [20]. More importantly, other systemic factors may affect the rate of systolic acceleration, making this test less sensitive and specific in certain patient populations. For example, in children, a proximal lesion such as an abdominal co-arcuation or aortic narrowing due to William's syndrome may also cause a decrease in systolic acceleration, thereby mimicking severe, bilateral RAS. Extrarenal factors such as aortic/mitral valvular disease, left ventricular dysfunction, or even cardiovascular medications such as preload



**Figure 4.** This patient had a high grade renal artery stenosis of the right renal artery. a) Note rounding and flattening of the systolic peak, the so-called *tardus parvus* waveform. The RI is also diminished at 0.47. b) Following successful surgical revascularization, the waveform has normalized. (Reprinted with permission from Raven Press).

and afterload reducers or myocardial contractility agents might affect systolic acceleration as well. Furthermore, arterial compliance decreases with age, hypertension, and diabetes. A decrease in arterial compliance will increase pulsatility (i.e., the rate of systolic acceleration) and attenuate any *tardus parvus* effect derived from an upstream stenosis. Such numerous, independent, criteria may explain why all authors have not found this technique to be equally as accurate in all populations [30].

*To review this patient's findings:*

In January 1995 a renal ultrasound without Doppler examination demonstrated that the right kidney measured 10.1 cm and the left kidney 12.6 cm. The 1.5 cm difference in renal size is a borderline finding suggestive of RAS on the right. A follow-up ultrasound with Doppler examination in August 1995 revealed that the right kidney measured 10.0 cm, while the left kidney measured only 10.9 cm. The apparent decrease in size over 9 months is suggestive of renal vascular disease.

Doppler ultrasound examination of this patient was inconclusive by either of the two techniques I have discussed. The left main renal artery could not be identified due to overlying bowel gas and there was some movement artifact due to her Parkinson's disease. No flow was seen in the right renal artery, but the ultrasonographer could not definitively discern if this was a real finding or a technical problem. Analysis of renal parenchymal waveforms was also inconclusive. Mild flattening of the systolic peak was noted bilaterally, more prominent on the right. However, these findings were not reproducible as the patient had trouble holding her breath and the waveform in the aorta also looked minimally abnormal. The RI's (resistive indices) for both kidneys were 1.0 which is not consistent with RAS (the RI is reported to be low or asymmetric in RAS) [29]. While this ultrasound examination was not diagnostic of RAS, several features were suggestive of RAS which could not be excluded on the basis of these findings. Given the high clinical suspicion of disease and loss of renal length we felt that RAS was still high on the differential diagnosis for this patient and it was decided that another imaging modality would be required.

The ultrasound studies in this patient demonstrate several of the pitfalls of this technique as previously described; the examination is technically difficult, and physical characters such as obesity, or as in this case, the inability to suspend respiration may make it impossible to obtain adequate Doppler tracings from the main renal arteries. Although not a discrete criterion, sonographers rely on the presence of asymmetry in Doppler tracings (PSV, RI, and appearance of waveforms) as a diagnostic clue. Obviously, when disease is bilateral one loses this ability. Furthermore, many systemic factors affect the rate of acceleration in the parenchymal renal arteries. In this case, decreased compliance due to age, atherosclerosis and long standing hypertension with increased peripheral vascular resistance, plus intrinsic medical renal disease (suggested by the abnormal RI of 1.0) might have contributed to blunting of the decrease in systolic acceleration or *tardus parvus* effect that one looks for with upstream bilateral stenoses.

*Dr. Huot:*

Given the clinical course, CRS, and ultrasound findings, we thought it possible that this patient had occlusion of the right renal artery and severe stenosis of the left renal artery. We therefore proceeded with an imaging modality that would provide adequate anatomic information upon which to base a decision for revascularization. We chose to obtain a spiral CT for this purpose. Dr. George Meier of the Department of Surgery will address the use of spiral CT for imaging renal arteries in patients with renal insufficiency and complex vascular disease.

*Dr. George Meier:*

As has been stated, the imaging of renal artery stenoses has two complicating factors which increase patient risk in the presence of renal insufficiency. First, all forms of iodinated contrast media are nephrotoxic, increasing the likelihood of acute renal failure. Second, in many patients with renovascular disease due to atherosclerosis, the aorta is often quite degenerate, increasing the risk of atheroembolism and its associated morbidity. In fact, in this patient both issues were dominant: not only did the patient have evidence of severe renal dysfunction, she had previously suffered spontaneous atheroembolism to her feet, presumably from an aortic source. Therefore, our initial efforts at diagnostic imaging focused on lowering the risk of imaging as much as possible, particularly relative to the irreversible damage of atheroembolism. As you have heard described, this patient underwent CRS and ultrasound before we decided to pursue more direct imaging of the renal vessels. We chose spiral (also called "helical") computed tomography scanning (CT) for this purpose.

Computed tomographic scanning has been widely available since the late 1970s and is an accepted technique for diagnostic evaluation. Early CT was based on segmental data sets, usually at 1 cm intervals. While this provided accurate cross-sectional reconstructions, the data were insufficient for sagittal or 3-dimensional reconstruction. What was necessary was a continuous data set over the area to be reconstructed, a requirement which is technically solved by spiral CT scanning. In this technique, the patient moves continuously through a scanner as it spins around his body. The helical slices can then be reconstructed into axial, longitudinal, or 3-D projections. A refinement of this technique is commonly referred as CT angiography. In this technique intravenous contrast medium is injected while the CT images are collected. The vessels can then be imaged in multiple ways. Perhaps the most common vessel-imaging technique is the shaded surface display. In this method, the surface of the intravenous contrast bolus is mapped and the interface between contrast and the surrounding tissue is reconstructed in three dimensions. The resultant image produces a luminal outline of the vessel in question, revealing stenoses and aneurysms alike [31].

A second common technique for imaging the vessels in CT angiography is the maximum intensity projection. In this technique, a composite "look-through" image is reconstructed. This image can be rotated in 360° and is particularly helpful when calcium in atherosclerotic plaque obscures luminal detail. In direct comparison using renal CT angiography, maximum intensity projections seem to be more sensitive at detecting stenoses than does shaded surface display [31].

The use of iodinated contrast medium is a requisite for conventional X-ray imaging of blood flow. Nevertheless, its use in the absence of arterial catheterization avoids potential atheroembolism as a complicating factor. This remains the fundamental advantage of CT angiography: the lack of intra-arterial catheterization not only prevents catheter-induced atheroembolism, it also allows the study to be virtually pain-free. The imaging requires only a few minutes for data-set capture, after which the analysis is performed on a post-processing workstation. Additionally, with three dimensional luminal reconstruction from the CT data set, anatomic details can be carefully defined and the area of stenosis can be evaluated fully.

In this patient, spiral CT angiography demonstrated bilateral disease, with diffuse disease in the right renal artery and an ostial stenosis of the left. Given the recent documented decrease in left renal size by ultrasound, our focus for renal function salvage centered on the left kidney.

*Dr. Huot:*

We now knew that our patient had bilateral renal artery stenosis, documented decrease in size of her left kidney and renal failure that would require dialysis in the very near future. In discussions with the patient and her family she stated a clear preference for revascularization over chronic dialysis. A cardiology assessment was obtained to determine cardiac surgical risk. The cardiologist's opinion following review of her clinical course, an echocardiogram and a persantine-thallium stress test, was that while her risk of perioperative myocardial infarction was increased due to her age and diffuse vascular disease, her cardiac function was stable and adequate to undergo surgical revascularization. In consultation with the patient and her team of physicians it was decided to proceed with surgical revascularization of the left kidney. Dr. Meier performed the surgery and he will now address the selection of specific operative procedures in patients with complex vascular disease, the potential benefits of revascularization for preservation of renal function, and the outcome in our patient.

*Dr. Meier:*

When confronted with new onset renal insufficiency in a patient with diffuse atherosclerotic disease, the challenges of operation are to minimize patient morbidity while providing maximum benefit. In this case, renal salvage was the foremost indication for renal revascularization. Given the risk of atheroembolism associated with angioplasty, particularly in view of the extent of this patient's disease, surgical intervention was chosen.

The common traditional approach to renal revascularization is aortorenal bypass. In this approach, the aorta is clamped, either partially or completely and a graft is placed from the aorta to the renal artery. The main difficulty with this approach is the risk of aortic cross-clamping. When the aorta is cross-clamped, afterload rises precipitously; when the aorta is unclamped, uncompensated hypotension can occur from the rapid afterload reduction, inducing cardiac ischemia. Also, clamping of the aorta can induce atheroembolism in patients such as this with diffuse atherosclerosis. For both reasons we wished to avoid aortic cross-clamping and therefore decided to pursue an "extra-anatomic" bypass procedure.

Extra-anatomic approaches to the renal artery were popularized in the mid-1980s and remain a very attractive alternative for these patients. In this operation, the hepatic or splenic artery is used for an inflow source for a graft to the renal artery. The fundamental advantage in this procedure is avoidance of the hemodynamic and physiologic consequences of aortic cross-clamping. This procedure is limited in patients with atherosclerosis of the celiac axis [32]. In this patient, the celiac axis had minimal disease and appeared appropriate for renal revascularization. Since we were primarily interested in renal functional salvage and not blood pressure control, we decided to revascularize the left kidney only and avoid the prolonged operative time that would be required to also revascularize the right kidney.

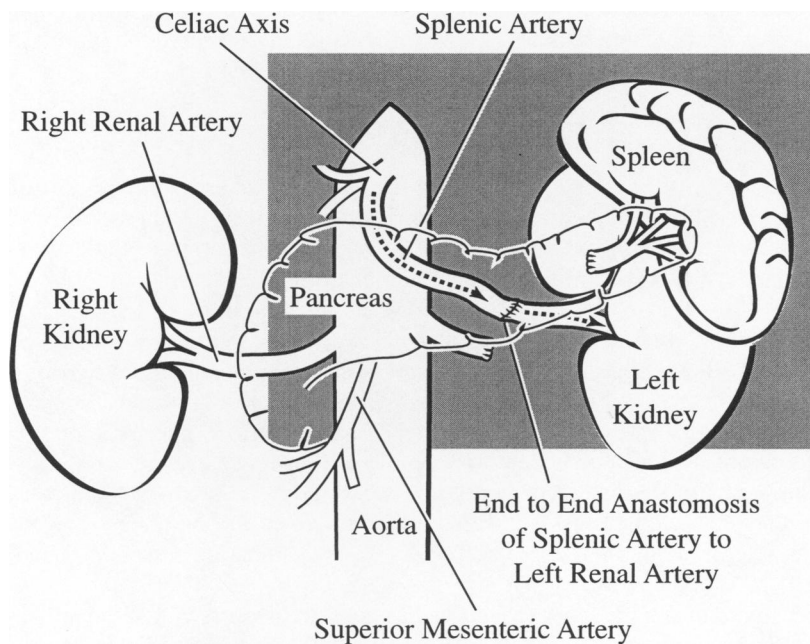
A standard splenorenal bypass was done by direct anastomosis of the splenic artery to the left renal artery (Figure 5). The spleen was not removed. Total operative time was approximately 2 h. Post-operatively, the patient did quite well with an increase in urine flow while still in the operating suite and subsequent improvement in renal function and in blood pressure control.

*Dr. Huot:*

As Dr. Meier stated, the patient did very well post operatively, both with regard to blood pressure control and recovery of renal function. Her blood pressure was better

controlled on one medication at discharge (amlodipine 2.5 mg once daily) than it had been on four medications at the time of admission. Her creatinine at discharge was 2.3 mg/dl and has remained at this level as of three weeks ago.

For completeness, I would like to comment briefly on the role of renal angioplasty as a revascularization alternative. Data on long term success of renal angioplasty are limited and are confounded by recent changes in angioplasty technique, including the use of stents. Angioplasty is the preferred technique for patients with fibromuscular disease when technically feasible. For patients with atherosclerotic disease success of the procedure is influenced by anatomic location and length of the stenosis. Angioplasty has been most successful when used for short non-ostial lesions and is also an alternative for ostial lesions with or without use of stents in patients with high surgical risk [33].



**Figure 5. Schematic drawing of spleno-renal bypass.**

### SUMMARY

Renal artery stenosis has become increasingly common as a cause of refractory hypertension and renal insufficiency. There is a high prevalence of bilateral disease and the lesions tend to progress over time. Newer, less invasive, imaging modalities such as doppler ultrasound, magnetic resonance angiography, and spiral CT scanning are evolving technologies in the diagnosis of renal artery stenosis. Advances in surgical technique, particularly the development of extra-anatomical procedures such as spleno-renal and hepato-renal bypass, have significantly lowered surgical morbidity and mortality and provides revascularization options for patients with complex vascular disease that would previously not have been considered because of their high surgical risk. Improvements in angioplasty technique and the use of stents are broadening the types of lesions that can be successfully approached with these techniques and may be particularly helpful for patients with more severe cardiac or cerebrovascular disease. The benefits of revascularization may be even greater for preservation of renal function than for control of blood pressure in properly selected patients.

It is difficult to predict which patients will benefit from surgical revascularization versus medical management of RAS. Knowledge of the progressive nature of RAS, the high prevalence of bilateral disease, and the clinical characteristics that correlate with progression (e.g., decreasing renal size) are helpful in guiding clinical decisions regarding intervention. Additional studies to determine the predictive value of non-invasive tests such as CRS, doppler ultrasound before and after administration of angiotensin converting enzyme inhibitors, and other tests, are needed to assist the clinician in identifying who will benefit most from revascularization both in terms of renal function and blood pressure control.

#### REFERENCES

1. Harding, M.B., Smith, L.R., Himmelstein, S.I., Harrison, K., Phillips, H.R., Schwab, S.J., Hermiller, J.B., Davidson, C.J., and Bashore, T.M. Renal artery stenosis: prevalence and associated risk factors in patients undergoing routine cardiac catheterization. *J. Am. Soc. Nephrol.* 2:1608-1616, 1992.
2. Holley, K.E., Hunt, J.C., Brown, A.L., Kincaid, O.W., and Sheps, S.G. Renal artery stenosis. *Am. J. Med.* 37:14-22, 1964.
3. Rimmer, J.M. and Gennari, F.J. Atherosclerotic renovascular disease and progressive renal failure. *Ann. Int. Med.* 118:712-719, 1993.
4. Wollenweber, J., Sheps, S.G., and Davis, G.D. Clinical course of atherosclerotic renovascular disease. *Am. J. Cardiol.* 21:60-71, 1968.
5. Meaney, T.F., Dustan, H.P., and McCormack, L.J. Natural history of renal arterial disease. *Radiol.* 91:881-887, 1968.
6. Dean, R.H., Kieffer, R.W., Smith, B.M., Oates, J.A., Nadeau, J.H.J., Hollifield, J.W., and DuPont, W.D. Renovascular hypertension: anatomic and renal function changes during drug therapy. *Arch. Surg.* 116:1408-1415, 1981.
7. Schreiber, M.J., Pohl, M.A., and Novick, A.C. The natural history of atherosclerotic and fibrous renal artery disease. *Urol. Clin. N. A.* 11:383-392, 1984.
8. Tollefson, D.F. and Ernst, C.B. Natural history of atherosclerotic renal artery stenosis associated with aortic disease. *J. Vasc. Surg.* 14:327-331, 1991.
9. Svetkey, L.P., Kadir, S., Dunnick, N.R., Smith, S.R., Dunham, C.B., Lambert, M., and Klotman, P.E. Similar prevalence of renovascular hypertension in selected blacks and whites. *Hypertension* 17:678-683, 1991.
10. Derkx, F.H. and Schalekamp, M.A. Renal artery stenosis and hypertension. *Lancet* 344:237-243, 1994.
11. Setaro, J.F., Sandler, M.C., Chen, C.C., Hoffer, P.B., Roer, D.M., Markowitz, Meier, G.H., Gusberg, R.J., and Black, H. Simplified captopril renography in diagnosis and treatment of renal artery stenosis. *Hypertension* 18:289-298, 1991.
12. Mann, S.J., Pickering, T.G., Sos, T.A., Uzzo, R.G., Sarkar, S., Friend, K., Rackson, M.D., and Laragh, J.H. Captopril renography in the diagnosis of renal artery stenosis: accuracy and limitations. *Am. J. Med.* 90:30-40, 1991.
13. Rudnick, M.R., Berns, J.S., Cohen, R.M., and Goldfarb, S. Nephrotoxic risks of renal angiography: Contrast media-associated nephrotoxicity and atheroembolism — a critical review. *Am. J. Kid. Dis.* 24:713-727, 1994.
14. Mailloux, L.U., Napolitano, B., Bellucci, A.G., Vernace, M., Wilkes, B.M., Mossey, R.T. Renal vascular disease causing end-stage renal disease, incidence, clinical correlates, and outcomes: a 20-year clinical experience. *Am. J. Kid. Dis.* 24:622-629, 1994.
15. Canzanella, V.J. and Textor, S.C. Noninvasive diagnosis of renovascular disease. *Mayo Clin. Proc.* 69:1172-1181, 1994.
16. Grist, T.M. Magnetic resonance angiography of renal artery stenosis. *Am. J. Kid. Dis.* 24:700-712, 1994.
17. Weaver, F.A., Pentecost, M.J., Yellin, A.E., Davis, S., and Finck, E. Clinical applications of carbon dioxide/digital subtraction arteriography. *J. Vasc. Surg.* 13:266-273, 1991.
18. Olin, J.E., Piedmonte, M.R., Young, J.R., DeAnna, S., Grubb, M., and Childs, B. The utility of duplex ultrasound scanning of the renal arteries for diagnosing significant renal artery stenosis. *Ann. Intern. Med.* 122:833-838, 1995.
19. Strandness, D.E. Jr. Duplex imaging for the detection of renal artery stenosis. *Am. J. Kid. Dis.* 24:674-678, 1994.

20. Stavros, T. and Harshfield, D. Renal Doppler, renal artery stenosis, and renovascular hypertension: direct and indirect duplex sonographic abnormalities in patients with renal artery stenosis. *Ultrasound Quart.* 12:217-263, 1994.
21. Kohler, T.R., Zierler, R.E., Martin, R.L., Nicholls, S.C., Bergelin, R.O., and Kazmers, A. Noninvasive diagnosis of renal artery stenosis by ultrasonic duplex scanning. *J. Vasc. Surg.* 4:450-456, 1986.
22. Taylor, D.C., Kettler, M.D., Moneta, G.L., Kohler, T.R., Kazmers, A., Beach, K.W., and Strandness, D.E. Duplex ultrasound scanning in the diagnosis of renal artery stenosis: a prospective evaluation. *J. Vasc. Surg.* 7:363-369, 1988.
23. Hansen, K.J., Tribble, R.W., Reavis, S.W., Canzanello, V.J., Craven, T.E., Plonk, G.W., Jr., and Dean, R.H. Renal duplex sonography: evaluation of clinical utility. *J. Vasc. Surg.* 12:227-236, 1990.
24. Berland, L.L., Koslin, D.B., Routh, W.D., and Keller, F.S. Renal artery stenosis: prospective evaluation of diagnosis with color duplex US compared with angiography. *Work in progress. Radiol.* 174:421-423, 1990.
25. Bude, R.O., Rubin, J.M., Platt, J.F., Fechner, K.P., and Adler, R.S. Pulsus tardus: its cause and potential limitations in detection of arterial stenosis. *Radiol.* 190:779-784, 1994.
26. Bude, R.O., and Rubin, J. M. Detection of renal artery stenosis with Doppler sonography: it is more complicated than originally thought. *Radiol.* 196:612-613, 1995.
27. Stavros, A.T., Parker, S.H., Yakes, W.F., Chantelouis, A.E., Burke, B.J., Meyers, P.R., Schenk, J.J. Segmental stenosis of the renal artery: pattern recognition of tardus and parvus abnormalities with duplex sonography. *Radiol.* 184:487-492, 1992.
28. Rene, P.C., Oliva, V.L., Bui, B.T., Froment, D., Harel, C., Nicolet, V., Courteau, M., Carignan, L. Renal artery stenosis: evaluation of Doppler US after inhibition of angiotensin-converting enzyme with Captopril. *Radiol.* 196:675-679, 1995.
29. Schwerk, W.B., Restrepo, I.K., Stellwaag, M., Klose, K.J., and Schade-Brittinger, C. Renal artery stenosis: grading with image-directed Doppler US evaluation of renal resistive index. *Radiol.* 190:785-790, 1994.
30. Kliewer, M.A., Tupler, R.H., Carroll, B.A., Paine, S.S., Kriegshauser, J.S., Hertzberg, B.S., and Svetkey, L.P. Renal artery stenosis: analysis of Doppler waveform parameters and tardus-parvus pattern. *Radiol.* 189:779-787, 1993.
31. Rubin, G. D., Dake, M.D., Napel, S., Jeffrey, R.B., Jr., McDonnell, C.H., Sommer, F. G., Wexler, L., and Williams, D.M. Spiral CT of renal artery stenosis: comparison of three-dimensional rendering techniques. *Radiol.* 190:181-189, 1994.
32. Fergany, A., Kolettis, P., and Novick, A.C. The contemporary role of extra-anatomical surgical renal revascularization in patients with atherosclerotic renal artery disease. *J. Urol.* 153:1798-1801.
33. Sos, T. A. Angioplasty for the treatment of azotemia and renovascular hypertension in atherosclerotic renal artery disease. *Circul.* 83(Supplement I):162-166, 1991.