

Research

Open Access

Endometrial response to IVF hormonal manipulation: Comparative analysis of menopausal, down regulated and natural cycles

Susan M Adams*¹, Vera Terry², Margot J Hosie³, Nalini Gayer⁴ and Christopher R Murphy¹

Address: ¹Department of Anatomy and Histology, University of Sydney, Sydney, NSW 2006, Australia, ²Department of Medical Education, University of Sydney, Sydney, NSW 2006, Australia, ³School of Anatomical Sciences, University of Witswatersrand, Parktown 2193, Johannesburg, South Africa and ⁴Department of Obstetrics and Gynaecology, University of Sydney, NSW, 2006, Australia

Email: Susan M Adams* - susan@anatomy.usyd.edu.au; Vera Terry - verat@med.usyd.edu.au; Margot J Hosie - hosiemj@anatomy.wits.ac.za; Nalini Gayer - nalinigayer@hotmail.com; Christopher R Murphy - histology@anatomy.usyd.edu.au

* Corresponding author

Published: 30 April 2004

Received: 22 December 2003

Reproductive Biology and Endocrinology 2004, 2:21

Accepted: 30 April 2004

This article is available from: <http://www.rbej.com/content/2/1/21>

© 2004 Adams et al; licensee BioMed Central Ltd. This is an Open Access article: verbatim copying and redistribution of this article are permitted in all media for any purpose, provided this notice is preserved along with the article's original URL.

Abstract

Background: Uterine luminal epithelial cell response to different hormonal strategies was examined to determine commonality when an endometrium attains a receptive, stimulated, morphological profile that may lead to successful implantation.

Methods: Endometrial biopsies from 3 cohorts of patients were compared. The tissue samples taken from these patients were categorized into 8 different groups according to their baseline and the hormone regime used.

Results: Pre-treatment natural cycle tissue was variable in appearance. Downregulation with a GnRH analogue tissue appeared menopausal in character. HRT after downregulation resulted in tissue uniformity. HRT in menopause resulted in a 'lush' epithelial surface. HST in the natural cycle improved the morphology with significant difference in secretion between the two regimes examined.

Conclusions: Down regulation plus HRT standardized surface appearance but tissue response is significantly different from the natural cycle, natural cycle plus HRT or menopause plus HRT. HRT in menopause reinstates tissue to a state similar to a natural cycle but significantly different from a natural cycle plus HST. HST with a natural cycle is similar to tissue from the natural cycle but significant differences reflect the influence of the particular hormones present (at any point) within the cycle.

Background

Successful reproduction in any species relies on a large number of interactions occurring at molecular, biochemical and morphological levels in the uterus. Changes in the uterine epithelium in preparation for implantation are characterised by a proliferation of cells, their differentiation, and alterations to the topography and composition

of the apical plasma membrane in particular. Cells reach their maximum growth and sensitivity to the blastocyst at the time of implantation. This period of maximum sensitivity is referred to as the *receptive* phase and has a limited duration or window of time – the 'nidation window'. Uteri outside this phase of receptivity not only resist attachment by the blastocyst [1,2] but in many species are

actively embryotoxic [3]. Thus, the uterus can be thought of as a primarily hostile environment where successful implantation and pregnancy are reliant on the precise coordination of events that change the receptivity of the uterus [4-6].

In 2000, assisted conception treatments accounted for almost 2% of all births in Australia and New Zealand, and although the number of births is steadily increasing, the pregnancy rates using IVF and other assisted reproductive technologies still remain unsatisfactorily low [7]. One factor that may impact on the successful outcome of these technologies is that a majority of the women seeking assisted conception treatment were aged 30 to 39 years, with 16.6% being aged 40 years or more [8].

With advancing age and/or a declining hormonal profile, concomitant with a decline in oocyte quality [9,10], the endometrium undergoes gradual involution from proliferative to inactive, eventually becoming atrophic (senescent) [11,12]. Perhaps the term 'aging' should be placed in context: once steroidal output from the ovary is reduced, there is a corresponding decrease in uterine morphological characteristics until the uterine epithelium becomes atrophic. However, these changes can be reversed and the morphological characteristics of an intact and functional epithelium can be reinstated with exogenous hormone supplementation therapy (HST) [13]. Thus 'aging' is a term that can be used to describe any uterus that is in a hormonally deprived condition.

In IVF programs for women with or without functioning ovaries, the endometrium is prepared artificially using exogenous hormones in a manner that seeks to imitate the natural cycle in preparation for embryo transfer (ET). If a pregnancy develops, exogenous E_2 and P_4 supplementation are continued until placental production of P_4 is well established [14]. The administration of P_4 before implantation and increasing the P_4 dose longer into pregnancy, has provided a method for correcting hormonal imbalance and enabling a successful pregnancy to be sustained [15,16,11,17].

Observations on the normal morphological changes of the uterine epithelium using light and electron microscopy have demonstrated that astute hormonal mimicking of the natural cycle is not necessary for endometrial preparation for implantation. Sequential 'same dose' E_2 and P_4 regimes (rather than incremental dose regimes) can be implemented without dose variation throughout the cycle [18-23]. The follicular phase of the natural cycle can be manipulated to shorten or extend the length of the cycle beyond its physiological limits (primarily for the synchronization of donor oocyte cycles with endometrial receptivity in the recipient). Proliferative endometrium under

these conditions has been shown to tolerate follicular phase durations from as short as 5 to as long as 100 days prior to the administration of P_4 [24,9,21,25,18,26,27]. However, other studies have suggested that the receptivity of the endometrium, as assessed by pregnancy rate, is best preserved when the follicular phase is kept between 12 and 19 days [22,23]. Short follicular phases (<11 days) have been shown to have an adverse effect on clinical outcome by presenting with early pregnancy loss [28,20,29].

Administration of exogenous E_2 and P_4 has also been found to have a threshold effect. Once a minimum threshold level of these hormones is attained, no further morphological endometrial responsiveness is observed [18,29-31]. However, supraphysiological doses of P_4 have been found to enhance luteal phase endometrial morphology [24,17], while withholding E_2 during the luteal phase has been found to have no adverse affect on endometrial development, maturation or receptivity [30,25,32,13].

Regardless of the effects of exogenous hormones, from any of the several strategies either as adjunctive, replacement or supplemental, the morphological integrity of the endometrium remains the same [33]. There is however, consistent evidence of out-of-phase endometria when HST is used. The appearance and maturity of uterodomes (pinopods) in addition to the temporal appearance or disappearance of a series of other morphological and histological characteristics [34,60] suggests that the priming of the 'window of receptivity' could be advanced or retarded [35,36].

Uterodomes (apical cellular protrusions) which have been found to occur at or just prior to the time of implantation have become useful biomarkers in clinical medicine for determining the hormonal condition, and therefore, state of receptivity of the uterus [4,17,37,38,35,36,39,40,42,42,43,60]. In a 28 day natural cycle, uterodomes have been found to appear on D20-21, in controlled ovarian hyperstimulation cycles they appear on D19-20 and in hormone controlled cycles on D21-22 [44,39]. These variable 'windows of receptivity' are another factor that could significantly affect the outcome of assisted reproduction techniques.

Although the cyclical changes that occur as a response to E_2 and P_4 exposure can be monitored on a daily basis by hormonal blood serum levels and ultrasound observations, it is the uterine biopsy that allows fine morphological assessment of the uterine epithelial ultrastructure. Scanning electron microscopy (SEM), used to sequentially date the endometrium, has confirmed the surface cellular changes observed with transmission electron microscopy (TEM) and further elucidated important details about

topographical features such as the cilia, microvilli, cell number, ratio, size and shape [37,41,45-48].

Visualization of the uterine epithelium, utilizing uterine biopsy and SEM, allows accurate endometrial dating, interpretation of morphological characteristics and the hormonal status of the epithelium to be assessed. Repeat endometrial biopsy further allows fine tuning of the exogenous hormone administration regime to optimize uterine receptivity, and hopefully, to maximize implantation [17].

The patient samples used in this comparative study are representative of several different IVF, HRT or HST treatment regimes and endometrial outcomes. There have been successful pregnancies for some. Data from menopausal patients represents a unique model for studying the interaction of exogenously administered E_2 and P_4 and endometrial morphology, without the confounding influence of endogenous ovarian steroid production. This data provides an indication of the responsiveness that might be expected from an under-stimulated endometrium in the presence of exogenous ovarian hormones.

The present study analyses the epithelial response to several hormonal strategies used in IVF settings and provides an insight into the response of the uterine epithelium to those strategies using repeat uterine biopsy, SEM and a series of accepted morphological markers to characterize tissue responsiveness.

Methods

Patient selection and treatment regimes

The present study analyses the morphological appearance of endometrial biopsies obtained from 4 groups of patients on an outpatient basis using the Gynoscan (Organon, Aust. Pty.), Novak curette and sedation. The biopsy was taken from the fundus, 2 cm down on the anterior-fundal wall of the uterus. All patients gave informed consent and research was conducted according to NH&MRC National Statement on Ethical Conduct in Research Involving Humans <http://www.health.gov.au/nhmrc/publications/humans/contents.htm>.

Figure 1 represents the treatment regimes and indicates the timelines for biopsy.

The groups were organized as follows:

Natural Cycle Control Patients

This group was further subdivided to determine whether time between stimulation regimes had an effect on the responsiveness of uterine tissue.

Group 1 – Natural Cycle Control (no HST for 3 months)

Ten patients between 28–41 years (mean age 34.3 years), attending an IVF clinic, who were not anovulatory, had taken no hormone supplementation, and had not undergone stimulation in the previous 3 months were included in this group. These women volunteered to have a uterine assessment for 1 cycle prior to their treatment cycle for ET and underwent one uterine biopsy 4 days after LH surge, as determined by blood serum hormone sample – D18 (D4P) on the assumption that, on a 28 day natural cycle, the secretory epithelium would be equivalent to that of 4 days of progesterone effects. Patients from this group went on to participate in the downregulation study (Groups 3 and 4).

Group 2 – Natural Cycle Control (previous HST)

Twenty-three infertile women between the ages 28 – 43.5 (mean age 34.7 years), having cryopreserved embryos from previous in vitro fertilization attempts, were recruited to take part in the study. Four women did not complete the study for individual reasons leaving 19 women in the final analyses. Each participant was diagnosed with one or more of the following: 12 with tubal factor, 4 with endometriosis, 7 with male factor, 2 with PCOD, 1 with bi-cornate uterus and 1 idiopathic infertility.

These women volunteered to have a uterine assessment for 1 cycle prior to their treatment. Biopsies were taken on D19 (D5P). Patients from this group went on to participate in the short and long follicular cycle study (Groups 7 and 8)

Groups 3 – Down-Regulation, and Group 4 – Down-regulation plus HRT

The 10 patients, 28–41 years (mean age 34.3 years), attending an IVF clinic who had more than 4 frozen embryos from previous ET attempts, were commenced on Synarel (nafarelin acetate) (Searle, Monsanto, Sydney), a GnRH agonist for pituitary suppression, prior to exogenous E_2 and P_4 replacement. Synarel was delivered in measured micronised doses of 200 mcg per nasal puff. Each patient underwent 2 consecutive treatment cycles.

Treatment Regime

- Synarel given as 2 intranasal puffs twice daily was commenced on Day 1 of cycle 1 and continued daily for 2 cycles. Two patients in this group underwent a uterine biopsy on D19 of this downregulation cycle (Group 3).
- Estigyn (ethinylestradiol, Glaxo, Wellcome, Australia) 50 mcg/day was commenced on Day 1 of the second cycle and continued throughout the cycle.

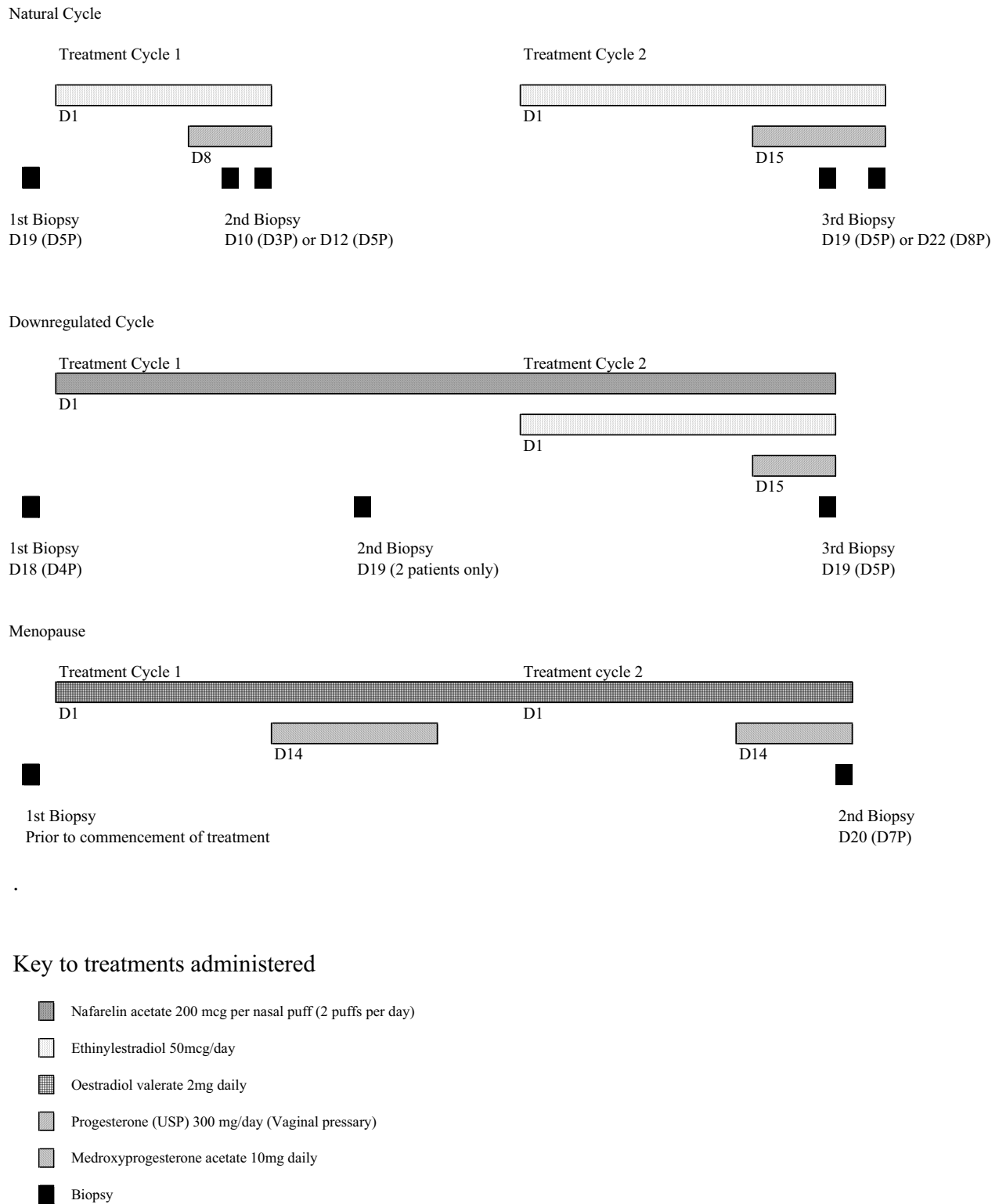


Figure 1
Representation of the treatment timelines, regimes used and biopsy days.

- Sequential progesterone (USP) 300 mg/day, as vaginal pessaries, was commenced on Day 15 of the second cycle.
- Uterine biopsy was taken 4 days later – D19 (D5P) (Group 4).

Group 5 – Menopause Control, and Group 6 – Menopause plus HRT
This group was originally composed of 27 patients (age range 47–59 years; mean age 55 years) with samples from 18 patients being used in the final analyses. Nine patients were eliminated from the study due to stenosis of the cervical os making uterine biopsy unfeasible. All patients had amenorrhoea for at least six months prior to biopsy, a FSH level in the postmenopausal range and had taken no HRT 6 months prior to the study. Each patient had two biopsies. The first biopsy was taken prior to the commencement of HRT and was used as a baseline against which to compare subsequent findings. Patients were within a second sequential HRT treatment cycle when the subsequent biopsy was taken at D20 = 6 days P. However, 2 biopsies were taken on D19 (5 days P) and one on D23 (9 days P) of the cycles.

Treatment Regime

- Progynova (oestradiol valerate, Schering, FRG) 2 mg daily
- Sequential Provera (Medroxyprogesterone acetate, Pharmacia and Upjohn, Sydney) 10 mg daily starting D 14 after E₂ commencement, taken for 12 days.
- Regime was repeated for a 2nd cycle.
- 15 uterine biopsy were taken D20 of the 2nd cycle = D6P; 2 biopsies were taken D19 of the 2nd cycle (D5P) and 1 on D23 (D9P) of the 2nd cycle.

Groups 7 – Natural cycle plus HST: short follicular phase Group 8 – Natural cycle plus HST: long follicular phase

The 19 infertile women remaining in the Natural Cycle Control (previous HST) cohort went on to undergo a short follicular phase cycle followed sequentially by a long follicular phase cycle. Serum FSH, LH, oestradiol and progesterone were measured on the first day of each P treatment ie: D8 or D15. Seven patients within this cohort became pregnant in the following consecutive ET cycle using the long follicle phase protocol [13].

Group 7 – Treatment Regime 1 – Short Follicular Phase

- Estigyn (ethinylestradiol) 50 mcg/day was commenced on Day 1 of the first treatment cycle and continued throughout the cycle.

- Sequential progesterone (USP) 300 mg/day, as vaginal pessaries, was commenced on D8 of the first treatment cycle.
- Uterine biopsy was taken 3 or 5 days later; D10 (D3P), or D12 (D5P).

Group 8 – Treatment Regime 2 – Long Follicular Phase

- Estigyn (ethinylestradiol) 50 mcg/day was commenced on Day 1 of the second treatment cycle and continued throughout the cycle.
- Sequential progesterone (USP) 300 mg/day, as vaginal pessaries, was commenced on D15 of the second treatment cycle.
- Uterine biopsy was taken 5 or 8 days later; D19 (D5P) or D22 (D8P).

Tissue preparation for Scanning Electron Microscopy (SEM)

Uterine biopsies were immediately rinsed in 0.1 M PO₄ buffer, pH 7.4, (PB), fixed in 2.5% Glutaraldehyde (EM Grade; TAAB, UK) in PB for 1.5 hours and rinsed with PB prior to further processing.

After initial fixation, the tissue was cut into 3 mm pieces and post fixed in aqueous 2% Osmium Tetroxide (OsO₄) (Johnson Matthey, Materials Technology U.K.) for one hour. Tissue was then rinsed in distilled water, dehydrated through graded ethanols 50–100% with a final wash in absolute alcohol for critical point drying in liquid CO₂ (Baltec). Dried tissue was mounted onto aluminium stubs, edged with conductive silver dag, sputter coated to 20 nm with platinum/gold in a planar magnetron sputter coater and viewed using a Philips Scanning Electron Microscope (SEM) 505 operating at 20 keV.

Data collection

Image collection was by digital capture at the SEM level of observation, using a standard series of magnifications: X525, X1050, X2100, X4200 and X8400.

Morphological analysis of tissue

Table 1 shows the 20 SEM epithelial characteristics and their descriptions used in the morphological assessment of the uterine biopsies [46,49,47,50,48,17]. These observational markers were scored as follows:

0 = Nil, absent

1 = some, few, barely present, low, small

2 = moderate, average

Table 1: Twenty epithelial characteristics and their descriptions used to evaluate uterine biopsies using SEM

Epithelial Characteristics – Graded 0–3	
1. Epithelial abundance – the amount of epithelium found within the sample	11. Cell separation – at times cells are observed to be separate rather than tightly clustered together
2. Tissue heterogeneity – the variability of tissue surfaces within the sample	12. Denuded apices – cell surfaces are devoid of surface modifications such as microvilli, cilia (excluding uterodomes)
3. Cell heterogeneity – the variability of the appearance of the cell types within each field	13. Flattened cells – degree to which cells display a flattened topography
4. Gland abundance – the relative number of glands observed within each field	14. Deflated cells – whether cell apices appear to have collapsed or withered
5. Gland opening – the types of gland opening, whether wide, raised, narrow	15. Apical protrusion – the degree to which the cell surface protrudes into the lumen of the uterus
6. Cilia groups – the relative number of ciliated cells clustered together	16. Uterodomes – shape (see Uterodome Assessment)
7. Single cilium – presence of these indicate a senescent or atrophying epithelium	17. Uterodomes – abundance (see Uterodome Assessment)
8. Microvilli height – the relative length of microvilli, from short and blebbed to long	18. Cell borders – may be obvious or deeply recessed between cells
9. Microvilli density – relative number of microvilli per cell, from few to many	19. Secretion – the presence of secretory product within the field or on cell surfaces
10. Apical membrane defects – include observation of porosity and degeneration	20. Plicae – are microvillous folds or ridges on the cell surfaces

3 = abundant, large, wide, high

Uterodome assessment

Abundance

Uterodomes were graded according to the criteria set down by Nikas and Pyschoyos, [36] such that their abundance (number) was scored in three grades: *abundant*, *moderate* or *few*, depending on the percentage of the endometrial surface occupied by uterodomes (>50%, 20–50%, and 20%, respectively).

Shape

Uterodome shape, denoting the stage of cell maturity, was graded such that three developmental stages were scored: *developing*, *fully developed* and *regressing* [39].

Statistics

Data analyses were performed using SPSS v.10 (SPSS Inc, Chicago, Illinois, US) statistical programme. The non-parametric Wilcoxon Mann-Whitney Test was used to compare groups. The Wilcoxon Mann-Whitney Test is used to test the null hypothesis that two populations have identical distribution functions and does not require the assumption that the differences between the two samples are normally distributed. In this study, where the normality assumption is questionable, the Wilcoxon Mann-Whitney Test is used in place of the two sample t-test. A confidence level of $P =$ or < 0.05 was used to determine significant difference between groups.

Results

Natural Cycle Control – Groups 1 and 2

Due to the innate intra- and inter-patient variability of the samples, the morphological analysis from the 2 patient cohorts have been combined into a single natural cycle control group referred to as Group 1. The term 'normal' is used lightly in this study as tissue was derived from patients attending a fertility clinic.

Morphological analysis

Group 1 – Combined Natural Cycle Control

In general there was a moderate to abundant amount of epithelium, however, the response within and between patients, with regard to the morphological characteristics, was variable.

Several patients were observed to have a well stimulated secretory epithelium consistent with Day 4P or 5P, displaying developing or fully developed uterodomes (Figure 2a). In contrast, a number of samples showed epithelium that was suboptimal and representative of early proliferative epithelium (Figure 2b). Microvillous cells were flat and sparsely covered with low, blebbed microvilli. Ciliated cells were infrequent and the cilia low and numerically reduced. In some cases these out of phase epithelia displayed large pleiomorphic cells, raised cell borders and exhibited poor ciliation.

In addition to inter-patient variability, several samples demonstrated an intra-patient variable response with large areas of tissue heterogeneity. Tissue appearance varied from areas of small polygonally shaped microvillous cells with well developed microvilli, cell protrusion and secretory droplets, to areas of flattened or protruding epithelium with obvious cell borders between large pleiomorphic cells (Figure 2c).

Glands also varied in number and appearance. Samples observed displayed glands that were moderately abundant with large, gaping openings; glands that were raised on circular hillocks with slit like openings (Figure 3a); or glands that were flat with circular openings (Figure 3b).

The results indicated that patients not displaying uterodomes on Day 4P or 5P of presumed P_4 exposure also had an epithelium that was found to be suboptimal or retarded in hormonal response.

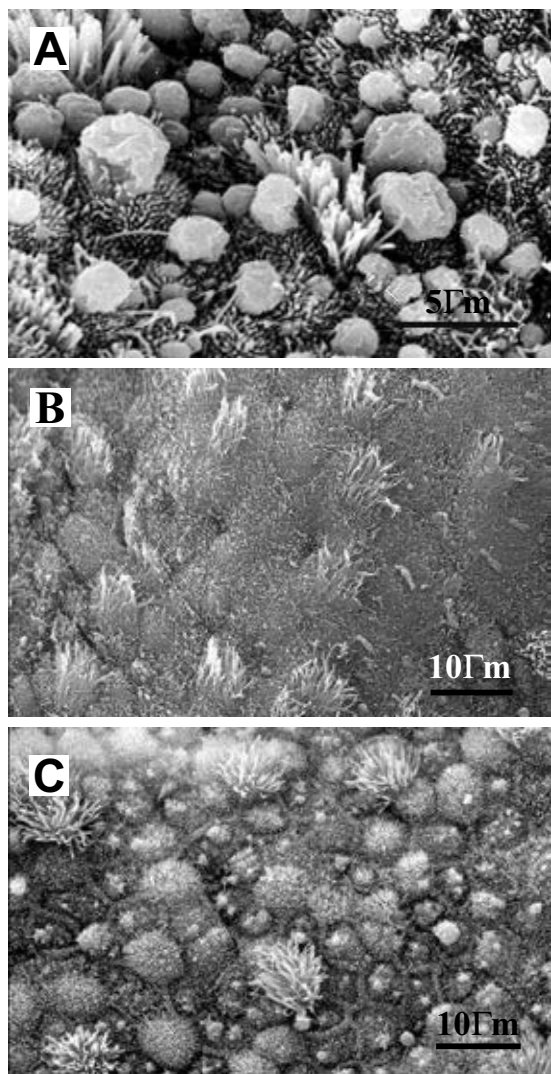


Figure 2
SEM of uterine epithelium at D4P from different women during a natural cycle. **(A)** Several patients showed a well stimulated, secretory epithelium consistent with Day 4P or 5P, displaying developing or fully developed uterodomes. Scale bar = 5 μ m. **(B)** In contrast some patients showed an epithelium that was suboptimal and representative of early proliferative epithelium. Microvillous cells were flat and sparsely covered with low, blebbed microvilli. Ciliated cells are infrequent and the cilia low and numerically reduced. Scale bar = 10 μ m. **(C)** Tissue appearance varied from areas of small polygonally shaped microvillous cells with well developed microvilli, cell protrusion and secretory droplets, to areas of flattened or protruding epithelium with obvious cell borders between large pleiomorphic cells. Scale bar = 10 μ m.

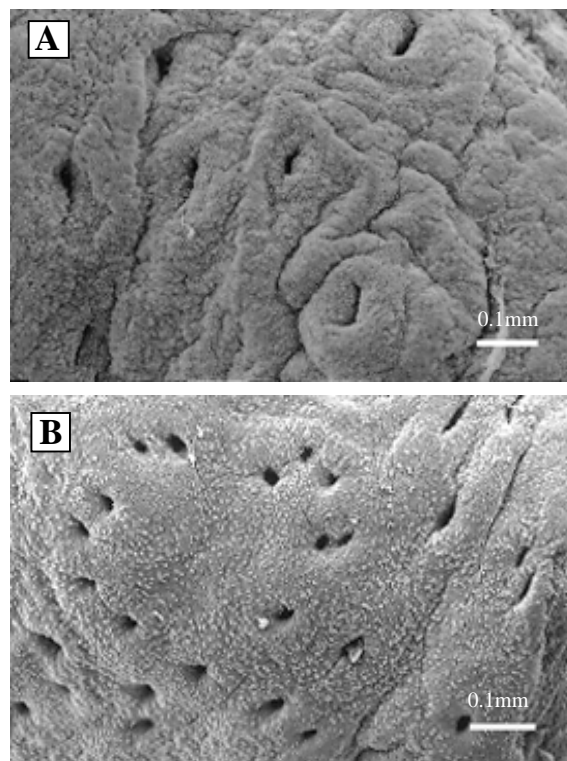


Figure 3
SEM at D4P showing gland variability between samples from women during a natural cycle. **(A)** The glands are raised on circular hillocks with large, slit-like openings and demonstrates an out-of-phase glandular appearance indicative of E_2 stimulation alone or insufficient P_4 exposure. Scale bar = 0.1 mm. **(B)** Epithelium of normal appearance displaying numerous flattened glands with small, rounded openings. Scale bar = 0.1 mm.

Group 3 – Down-regulation only

Unfortunately only 2 patients within the cohort had a biopsy taken within the first downregulation treatment cycle where only a GnRH agonist was administered.

Observations of morphological characteristics indicated an epithelium that was unstimulated, flat and displayed a topography similar to that observed in post menopausal uteri of Group 5. Epithelial surface was flattened with cells displaying raised cell borders. There was evidence of cell separation, cell loss and apical membrane defects, such as cell porosity, (Figure 4a). Glands with large openings were also observed.




Figure 4

SEM of tissue from a patient undergoing downregulation (Group 3). **(A)** The epithelial response to pituitary down-regulation with GnRH is similar to that of an unstimulated epithelium. The microvillous cells are undemarcated and flat with sparsely distributed low or blebbed microvilli. Apical cell membrane is exposed (asterisk), apical defects (AP) and cell porosity (CP) apparent. Groups of cilia are still apparent but cilia number is reduced exposing bulging cellular apices (arrows). Scale bar = 5 µm. **(B)** The epithelial response in the same patient as **(A)** after pituitary down-regulation followed by HRT. A well stimulated, mature secretory phase morphology suggestive of D5P was observed. Mid to long, dense microvilli were observed on protruding cells, and there was an abundance of well ciliated cells, secretory droplets and fully developed uterodomes (U). Scale bar = 5 µm.

Group 4 – Downregulation plus HRT

A similar tissue response to treatment was observed in all samples. The epithelium taken at Day 5P was representative of a mid-secretory phase epithelium. Mid to long dense microvilli were observed on protruding cells, and there was an abundance of well ciliated cells, secretory

droplets and fully developed uterodomes. The presence of developing or fully developed uterodomes indicated a progestogenic influence on the tissue (Figure 4b).

Group 5 – Menopause Control

Although the grading of the morphological characteristics was variable between patients, trends were observed in the samples examined.

Overall, epithelial tissue was difficult to find, with tissue heterogeneity being pronounced. The heterogeneity was observed as abutment between areas of different epithelial architecture and an inconsistency in cell size and shape (Figure 5a). Epithelial surface was usually flattened, with cells often displaying raised cell borders; a few to moderate number of glands with large openings were observed. Cell separation, cell loss and apical membrane defects, such as cell porosity, (Figure 5b) were a frequent occurrence. Denuded or bald cells were also frequently observed.

Ciliated cells were only observed in 50% of the biopsies examined, and when present, were short, sparse and displayed splayed tips. Singular cilia (Figure 5c) were also a common feature of the tissue.

Microvillous cells were thinly populated with very low, blebbed microvilli, with some of the samples examined exhibiting the fusion of the low microvilli to form flattened ridges (plicae).

No Uterodomes were observed in any of the samples.

Group 6 – Menopause plus HRT

Three of the samples examined showed a slight to no difference from pre-treatment biopsy.

Of the remaining samples, tissue was more uniform in appearance than observed in the pre-treatment biopsies. Epithelium was abundant and cellular heterogeneity was less obvious. There was no change in gland number but openings were round and generally small. No cell separation, cell loss or apical membrane defects were observed. Apical cell protrusion was prevalent (Figure 6a) with only some areas displaying a flattened epithelium. Ciliated cells were moderately abundant with dense, long cilia. A reduced incidence of single cilia was also observed.

Microvillous cells were uniformly small and polygonally shaped, covered with dense microvilli that varied in length.

Developing or fully developed uterodomes were observed in a majority of the samples (Figure 6b). Secretory droplets were moderately abundant.

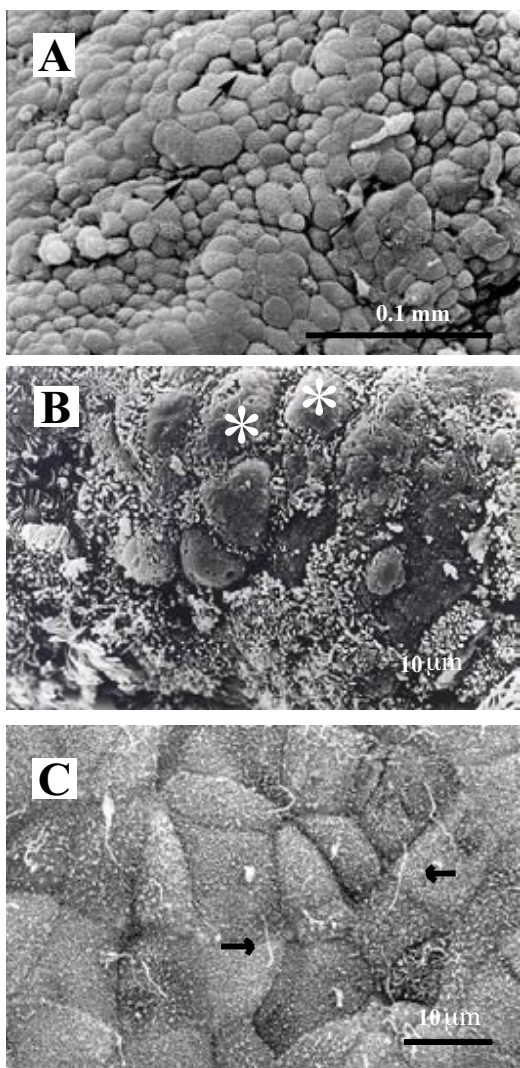


Figure 5

SEM of postmenopausal tissue. **(A)** Tissue heterogeneity is pronounced with inconsistencies in cell size and shape. Arrows denote cell separation. Scale bar = 0.1 mm. **(B)** Microvillous cells are sparsely covered with very low or blebbed microvilli. Denuded or bald cells (asterisk) are frequently seen. Scale bar = 10 μm. **(C)** Atrophic epithelium displays flat, pleiomorphic cells with obvious cell borders and single cilium (arrows). Scale bar = 10 μm.

Groups 7 and 8 – Natural plus HST – Short follicular and Long Follicular phase

The results of morphological examination of the two groups has been combined to reflect the changes that occurred as a result of HST.




Figure 6

SEM of postmenopausal tissue after HRT. **(A)** Microvillous cells are uniformly small and polygonally shaped, covered with dense microvilli and showing apical cell protrusion. Ciliated cells (c) are numerous. Scale bar = 10 μm. **(B)** Fully developed uterodomes (u) were observed in most patients at biopsy D6P. Scale bar = 10 μm.

Overall both regimes, whether 7 or 14 days of E₂ before the commencement of P₄, resulted in an improvement in the appearance and amount of epithelium when compared to Group 1, but little difference in uterodome development between the cycles was observed. Of interest is the finding that when uterodomes were observed to be fully developed at Day 5P on a short E₂ treatment cycle, they were also found to be fully developed at Day 8P on a long E₂ treatment cycle. In patient samples that did not follow this trend, fully developed uterodomes on Day 5P of a short E₂ treatment cycle, went on to exhibit clumping of swollen microvillous tips (potentially a hyperoestrogenic effect) on protruding cells on Day 8P of a long E₂ treatment cycle. This suggests that the longer E₂ treatment resulted in hyperoestrogenisation or in a shift of the nidation window.

Table 2: Statistical Analysis of morphological characteristics between Groups showing significant differences and median scores.

	Epithelial abundance	Tissue inhomogeneity	Cell inhomogeneity	Gland abundance	Gland opening	Cilia groups	Single cilium	Microvilli height	Microvilli density	Apical membrane defects	Cell separation	Denudded apices	Flattened cells	Deflated cells	Apical protrusion	Uterodome shape	Uterodome abundance	Cell borders	Secretion	Plicae
group 1 vs group 4	SD (2.5,3)		SD (2.5,1)			SD (2,3)			SD (2.5,3)					SD (0,0)	SD (2,3)			SD (0,1)	SD (2.5,2)	
group 1 vs group 5	SD (2.5,1)					SD (2,0.5)	SD (0,0.5)	SD (2,1)	SD (2,1)	SD (0,1)	SD (0,0.5)	SD (0,2)	SD (0,2)	SD (0,1)	SD (2,0)	SD (1,0)	SD (1,0)	SD (1,2)	SD (2,0)	SD (0,0.5)
group 1 vs group 6							SD (0,0.5)						SD (0,1)	SD (0,0)		SD (1,3)				
group 1 vs group 7								SD (2,1)							SD (2,1)					
group 1 vs group 8											SD (0,0)	SD (0,0)							SD (2,1)	
group 3 vs group 5	SD (3,1)					SD (2,0.5)														
group 4 vs group 5	SD (3,1)	SD (1,2.5)		SD (2,1.5)	SD (1,3)	SD (3,0.5)	SD (0,0.5)	SD (2,1)	SD (3,1)	SD (0,1)	SD (0,0.5)	SD (0,2)	SD (0,2)	SD (0,1)	SD (3,0)	SD (1,0)	SD (2,0)	SD (0,2)	SD (2.5,0)	SD (0,0.5)
group 4 vs group 6	SD (3,3)					SD (3,2)	SD (0,0.5)		SD (3,2)				SD (0,1)		SD (3,2)				SD (2,2)	
group 4 vs group 7			SD (1,2)					SD (2,1)	SD (3,2)					SD (0,0)	SD (3,1)			SD (0,1)	SD (2.5,2)	SD (0.5,0)
group 4 vs group 8			SD (1,3)			SD (3,2)		SD (2,1)	SD (3,1)					SD (0,0)	SD (3,1)		SD (2,1)	SD (0,1)	SD (2.5,1)	
group 5 vs group 6	SD (1,3)	SD (2.5,2)			SD (3,1.5)	SD (0.5,2)		SD (1,2)	SD (1,2)	SD (1,2)	SD (0.5,0)	SD (2,1)	SD (2,1)	SD (1,0)	SD (0,2)	SD (0.3)	SD (0.2)	SD (2,0)	SD (0.2)	
group 5 vs group 7	SD (1,3)			SD (1,2)	SD (3,1.5)	SD (0.5,0)	SD (0.5,0)			SD (0.5,0)	SD (0.5,0)	SD (2,0)	SD (2,0)	SD (1,0)	SD (0,1)	SD (0,1)	SD (0,1)	SD (2,1)	SD (0,2)	
group 5 vs group 8	SD (1,3)		SD (1.5,3)	SD (1,2)	SD (3,2)	SD (0.5,0)	SD (1,3)			SD (0.5,0)	SD (0.5,0)	SD (2,0)	SD (2,0)	SD (1,0)	SD (0,1)	SD (0,1)	SD (0,1)	SD (2,1)	SD (0,1)	
group 6 vs group 7							SD (0.5,0)	SD (2,1)	SD (2,2)			SD (0,0)	SD (1,0)	SD (0,0)	SD (2,1)					
group 6 vs group 8		SD (1.5,3)					SD (0.5,0)		SD (2,1)			SD (0,0)	SD (1,0)	SD (0,0)					SD (2,1)	
group 7 vs group 8																			SD (2,1)	

SD = significant difference at P ≤ 0.05 Median score of groups is shown in brackets (group a, group b) Key to the Groups used in the Analysis Group 1 Control – natural cycle (Combined) Group 3 Downregulation Group 4 Downregulation plus HRT Group 5 Menopause Control Group 6 Menopause plus HRT Group 7 Natural plus HST – Day 5P Group 8 Natural plus HST – Day 8P

Of the four patients that were biopsied on Day 3P of the short E₂ treatment cycle, two displayed normally stimulated endometria with pinopods and two exhibited impoverished epithelia with sparse cell populations, cellular erosion and cell disjunction.

Although the two hormonal regimes did not show differential changes in the morphology of the secretory epithelium, there was an increase in pinopod abundance in samples that had displayed few in the natural cycle prior to HST. Where epithelium was well presented in the natural cycle, no further beneficial effect was observed with the addition of HST.

Statistical analysis

Table 2 represents the significant difference between the groups in the final analysis (P ≤ 0.05).

Preliminary analysis

Preliminary analysis of the morphological characteristics provided a basis for the assumptions upon which the final statistical analysis was based.

Groups 1 and 2 – Natural Cycle Control

Preliminary analysis indicated that the 2 groups significantly differed in microvilli density and apical protrusion. Group 1 had a median score of 2.5 and Group 2 a median score of 1 for microvilli density, and 3 and 1 respectively for apical protrusion (Table 3). Due to the innate morphological inter-patient variability of the observed tissue, it was decided that the groups would be combined into a single natural cycle control group, Group 1 for the Final analysis that follows.

Group 7 and Group 8 – short and long follicular phase

Preliminary analysis indicated that Group 7 significantly differed from group 8 in terms of cell heterogeneity only. Group 7 had a median score of 2 and Group 8 a median score of 3 (data not shown). In considering the response of all characteristics it was decided to redefine the two groups by biopsy Day P rather than retain grouping according to the length of E₂ prior to P₄ commencement. Data was regrouped in terms of biopsy Day 5P (Group 7) and Day 8P (Group 8). Tissue from biopsy Day 3P was not included in the analysis. On reanalysis, using the Day P as a grouping factor, the groups were found to significantly differ in secretion only (Table 2) with Group 7 having a

Table 3: Group median values and score range for the morphological characteristics used in the final analysis.

		Epithelial abundance	Tissue heterogeneity	Cell heterogeneity	Gland abundance	Gland opening	Cilia groups	Single cilium	Microvilli height	Microvilli density	Apical membrane defects	Cell separation	Denuded apices	Flattened cells	Deflated cells	Apical protrusion	Uterodome shape	Uterodome abundance	Cell borders	Secretion	Plicae
Group 1	Median	3	2	2	2	2	2	0	2	2	0	0	0	0	0	2	1	1	1	2	0
Combined	Minimum	1	1	1	0	0	0	0	1	1	0	0	0	0	0	0	0	0	0	0	0
n = 25	Maximum	3	3	3	3	3	3	0	3	3	1	1	1	2	1	3	3	3	2	3	2
(Group 1)	Median	2.5	2.5	2	2	2	2	0	2	2.5	0	0	0	0	0	3	1	1.5	0	2	0
n = 10	Minimum	1	1	1	1	1	1	0	1	1	0	0	0	0	0	1	0	0	0	1	0
	Maximum	3	3	3	2	3	3	0	3	3	1	1	1	2	1	3	3	3	2	3	1
(Group 2)	Median	3	1	2	1	1	2	0	1	1	0	0	0	0	0	1	1	1	1	2	0
n = 15	Minimum	1	1	1	0	0	0	0	1	1	0	0	0	0	0	0	0	0	0	0	0
	Maximum	3	3	3	3	3	3	0	3	3	1	1	1	1	0	3	3	3	1	3	2
Group 3	Median	3	2	3	1	2	2	0	1	1	2	0	3	3	0	1	0	0	3	0	2
n = 2	Minimum	3	2	3	1	2	2	0	1	1	2	0	3	3	0	1	0	0	3	0	2
	Maximum	3	2	3	1	2	2	0	1	1	2	0	3	3	0	1	0	0	3	0	2
Group 4	Median	3	1	1	2	1	3	0	2	3	0	0	0	0	0	3	1	2	0	2.5	0
n = 10	Minimum	3	1	0	1	1	2	0	2	2	0	0	0	0	0	3	0	0	0	2	0
	Maximum	3	2	2	2	2	3	0	3	3	0	0	1	1	1	3	3	3	0	3	0
Group 5	Median	1	2.5	1.5	1	3	0.5	0.5	1	1	1	0.5	2	2	1	0	0	0	2	0	0.5
n = 18	Minimum	1	1	1	0	0	0	0	1	1	0	0	0	0	0	0	0	0	0	0	0
	Maximum	3	3	3	2	3	2	2	2	3	2	1	3	3	2	1	0	0	3	1	2
Group 6	Median	3	2	1.5	2	1.5	2	0.5	2	2	0	0	0	1	0	2	3	2	0	2	0
n = 18	Minimum	2	1	1	0	0	1	0	1	1	0	0	0	0	0	0	0	0	0	0	0
	Maximum	3	3	3	3	2	3	1	3	3	1	1	2	2	1	3	3	3	2	3	2
Group 7	Median	3	2	2	2	1	2	0	1	2	0	0	0	0	0	1	1	1	1	2	0
n = 18	Minimum	1	1	1	1	1	0	0	1	1	0	0	0	0	0	0	0	0	0	0	0
	Maximum	3	3	3	3	3	3	0	2	3	1	1	1	1	0	2	2	3	1	3	2
Group 8	Median	3	1	3	2	2	2	0	1	1	0	0	0	0	0	1	1	1	1	1	0
n = 13	Minimum	1	1	1	0	0	0	0	0	1	0	0	0	0	0	0	0	0	0	0	0
	Maximum	3	3	3	3	3	3	0	3	3	0	0	0	0	0	3	3	3	1	2	2

Group 1 Combined Control – natural cycle (Combined groups 1 and 2) Group 3 Downregulation Group 4 Downregulation plus HRT Group 5 Menopause Control Group 6 Menopause plus HRT Group 7 Natural plus HST – Day 5P Group 8 Natural plus HST – Day 8P Key: Groups in () indicate values prior to combination for final analysis

median score of 2 and Group 8 a median score of 1 (Table 3)

Group 3 – Downregulation vs Group 5 – Menopausal Control
 Due to the small sample size, results for this group were included for interest only. Of note was the similarity of tissue from these 2 patients to that of tissue obtained from menopausal patients. The groups differed significantly only in terms of epithelial abundance and cilia groups (Table 2), with a median score of 3 (Group3) and 1 (Group 5) for epithelial abundance, and 2 (Group 3) and 0.5 (Group 5) for cilia groups (Table 3).

Final Analysis

Natural versus Hormone replacement

Natural Control Combined (Group 1), Downregulation plus HRT (Group 4), Menopause plus HRT (Group 6) Natural plus HST D5P (Group 7) and Natural plus HST D8P (Group 8)

Group 1 vs Group 4: From Table 2, analysis indicated that Group 1 and Group 4 differed significantly in 8 of the morphological characteristics observed. These differences in the characteristics suggest a retardation of the uterine phase in Downregulation plus HRT when compared to tissue from patients on a natural cycle.

Group 1 vs Group 6: Although responding to hormonal priming, menopausal tissue (Group 6) differed significantly from Group 1 tissue in the presence of single cilium, flattened cells, deflated cells and uterodome shape. The results indicate that menopausal tissue was advanced in terms of uterodome shape, suggestive of an epithelium that had passed the prime nidation window.

Group 1 vs Group 7 and Group 8: There was little significant difference between the Groups (Table 2). Group 7 differed from Group 1 in terms of microvilli height and apical protrusion. Group 8 significantly differed from Group 1 in denuded apices and flattened cells, with a greater score range being seen in Group 1 (Table 3), and in the amount of secretion.

Downregulation plus HRT vs Natural plus HST
Downregulation plus HRT (Group 4), Natural plus HST D5P (Group 7) and Natural plus HST D8P (Group 8)

Group 4 vs Group 7 and Group 8: These groups were significantly different in 7 of the same characteristics (Table 2). Group 4 additionally differed significantly to Group 7 in the presence of plicae. Group 4 differed significantly to Group 8 in another 2 characteristics, cilia groups and uterodome abundance. The trend suggests that downregula-

tion prior to HRT results in greater tissue stimulation, in terms of morphological characteristic development, as observed by a consistently higher median score for Group 4 in the characteristics that were significantly different.

Menopausal Control vs Natural Cycle, HRT and HST Menopausal (Group 5), Natural (Group 1), Downregulation plus HRT (Group 4), Menopause plus HRT (Group 6), Natural plus HST D5P (Group 7) and Natural plus HST D8P (Group 8)

As expected of hormone depleted tissues, Group 5 differed significantly to all other hormone exposed groups in a majority of the morphological characteristics observed (Table 2).

Menopause plus HRT versus Downregulation plus HRT and Natural plus HST Menopause plus HRT (group 6), Downregulation plus HRT (Group 4), Natural plus HST D5P (Group 7) and Natural plus HST D8P (Group 8)

Group 4 vs Group 6: Surprisingly these groups differed significantly in a number of the morphological features observed (Table 2). The presence of single cilium indicated that evidence of senescence remained in the menopausal tissue even after HRT. Overall, the tissue that had been downregulated prior to HRT demonstrated an enhanced response to HRT in comparison to menopausal tissue (Tables 2 and 3).

Group 6 vs Group 7 and Group 8: Both natural HST treatment groups differed significantly from the menopause plus HRT group in the presence of single cilium, microvilli density, denuded apices, flattened cells and deflated cells (Table 2). Group 8 displayed more cell heterogeneity but less secretion than Group 6 (Tables 2 and 3). Group 7 differed significantly from Group 6 in having a lower median score in microvilli height and apical protrusion (Table 2). Results indicate that tissue from a natural cycle has a retarded response to HST in comparison to menopausal tissue response to HRT.

Summary

Overall, when considering all natural cycle and HRT or HST manipulated cycles, secretion was consistently significantly different between Groups 1, 4, 6 and Group 8, with Group 8 having a lower median score.

Discussion

The variable morphological response of the endometrium to endogenous hormones in the naturally cycling patients reflects either a unique physiological response to hormones at the target tissue, or an insufficiency in the amount of endogenous hormones at the level of the uter-

ine epithelium, or both. Problems associated with the endogenous hormone response, coupled with the variability observed in the response of women with no ovarian function to exogenous E_2 and P_4 , [5,51,6,52,53] highlights the need to optimize both the dose and timing of hormone replacement regimes and where possible, to tailor regimes to suit individual patients [17].

Tissue samples examined from the naturally cycling patients consistently displayed epithelial tissue, a heterogeneity of cellular morphology and a variable morphological response to endogenous hormones. Having previous failed ET attempts, observations of endometrial variability in these patients indicates the importance of attaining a mature 'in-phase' endometrium if implantation is to proceed.

In general, uterodomes appear after D5 of P_4 stimulation [35] and the fact that several patients displayed developing uterodomes prior to this time (D3P) indicated that they would have been fully developed by D5P. However, the presence of fully developed uterodomes on D3P would have placed these patients into the 'patient variability' group where an out-of-phase epithelium can occur with a temporal span of up to 5 days [39].

The presence of large exposed glands in some of the patients suggested an epithelium under the influence of E_2 alone or insufficiently stimulated by P_4 , thus out-of-phase and indicative of late proliferative endometrium. Other indicators included areas of tissue displaying large, pleomorphic cells with raised cell borders.

The observation of patients, within the naturally cycling control group, with a hyperplastic (over proliferative/hyperoestrogenic) [46,47] endometrium demonstrated the often unsuspected endometrial variability in naturally cycling women, adding weight to the argument in support of uterine biopsy and SEM for direct visualisation of endometrial morphology.

Patients recruited into the downregulation cohort displayed a more uniform tissue response to the HRT that followed. The two patients that had biopsies taken after pituitary down-regulation but prior to HRT, indicated that an unstimulated, flat epithelium, resembling the unstimulated epithelium of the postmenopausal uterus, can be seen in ovulating women, and that HRT in a consecutive cycle can restore that epithelium to a mature functional state. It was interesting to note however, that statistical analysis of the morphological characteristics indicated that HRT after downregulation was significantly different from the natural cycle in a number of characteristics. The median score of downregulation plus HRT showed that

exogenous hormones had a greater tissue effect than that found with exposure to endogenous hormones.

The D5P biopsy taken from these downregulated patients following hormone stimulation, displayed developing and fully developed uterodomes. As uterodomes are known to occur after 5–7 days of P_4 (in a natural cycle) [55,43] this appearance of uterodomes indicates that the HRT regime given was sufficient to stimulate a previously downregulated, flattened uterine epithelium. All patients had a similar morphological response, with a well stimulated epithelium representative of the mid secretory phase. The presence of developing uterodomes was suggestive of a *receptive* (or *pre receptive*) state, which under a progestogenic influence, is indicative of the maturing epithelium required for successful blastocyst implantation. Patients that displayed developing uterodomes at D5P could have gone on to develop them later in the cycle, or may have benefited from HRT dose manipulation.

The variability of tissue observed from menopausal patients can be explained by the climacteric process. During the climacteric period there is a physiological decline in ovarian function, a consequential fall in the secretion of both E_2 and P_4 , and an endometrium that eventually becomes atrophic. Since that atrophic state represents the preserved or 'petrified' cycle that existed when the menopause started, it may have several forms. If the last menstrual cycle was ovulatory and ended with a regular menstrual flow, then a 'simple' atrophy will develop. However, if the last cycle or cycles were anovulatory, or if the proliferative phases were irregular, then the 'petrified' state of the last proliferative phase will be observed [56].

A dramatic improvement from the menopausal baseline of the 20 epithelial characteristics chosen for the study was observed after 2 cycles of HRT. The baseline biopsies showed only scant areas of an unstimulated epithelium covering the stroma [57]. After HRT, there was an abundance of epithelium which was observed to be similar to that of the mid secretory stage, D19-22, of a functionally receptive epithelium [47]. The microvillous cells were small and uniformly polygonal in shape, had apical cell protrusion and were covered with dense, medium to long microvilli. There was no evidence of cell defect or separation as found in the baseline biopsy. Ciliated cells were moderate to abundant and cilia were tall, upright and covering the entire cell surface [58]. Uterodomes were found fully developed in 10 patients, developing in 3 and absent in 5.

Of the 5 patients with no uterodomes, 3 patients showed little morphological response to HRT indicating that the hormone dose was insufficient to stimulate the

epithelium, rather than an inability of the epithelium to respond.

Since patient variability is known to occur with a temporal 5 day 'out-of-phase' period [55], it is probable that the 24–48 hour window for their appearance either preceded the biopsy date (where biopsy date was D23) or was yet to occur. Since there is no information as to how many cycles of HRT are required before a maximum epithelial response is achieved, it is possible, from the findings of this study, that severely atrophic endometria may need more than 2 months HRT before achieving a standard epithelial response [59].

Statistical analysis showed that tissue from menopausal patients after HRT differed significantly from natural cycle control patients in 4 of the characteristics observed. However, menopause after HRT differed significantly from downregulation after HRT in 7 of the characteristics observed. When considered with regard to the median scores, the tissue response to HRT after downregulation seems more advanced, with menopausal tissue retaining some of its pre-stimulation characteristics, such as single cilium, less dense microvilli and flattened cells.

Manipulation of the follicular phase in naturally cycling patients did not interfere with the morphological integrity of the secretory epithelium as observed by SEM. Our results also demonstrated that uterodome appearance, abundance and shape did not appear to be compromised by utilizing a short follicular phase cycle.

Seven pregnancies which resulted from this part of the study were achieved using the long follicular phase regime with 5 days of P_4 in patients who were assessed by previous biopsy to have optimal epithelium with this regime [13]. Perhaps premature P_4 , after a short cycle of E_2 , may accelerate the closure of the nidation window and compromise the chances of successful implantation [41,42]. This is also indicated by a significant difference in secretion, with tissue from the long follicular cycle being less secretory than that from the short follicular cycle (Table 2).

The function of uterodomes in humans is still unknown but their appearance at, or just prior to the time of implantation suggests they are necessary for the functionality of the secretory epithelium if implantation and pregnancy are to progress. While pregnancies were achieved with ET on D19 (D5P) of a long follicular phase cycle, fully developed uterodomes were observed on both D10 (D3P) and D12 (D5P) of the short follicular phase cycle. This finding again highlights the potential benefit of repeat biopsies to fine tune individual hormonal priming and the role that P_4 plays in determining endometrial receptivity.

In artificial cycles maintained with exogenous hormones, uterodomes have been shown to occur around D22 (D8 P) [34], suggesting that the window of receptivity in artificial cycles, induced by HRT, can be postponed [34,36,39]. Studies where sequential sampling was performed during the same cycle of natural or artificial cycles (non ovarian stimulated), the timing of uterodome appearance was found to vary up to 5 days between women [55]. This individual variability could explain our observation of fully developed uterodomes on both days 3 and 5 of P₄ in the same patient, although not in the same cycle. However, we did not observe an abundance of uterodomes on day 22 (D8P) [55]. In contrast, previous work has shown that uterodome appearance is dependant on P₄ in a study on naturally cycling women where exogenous E₂ was not supplemented [13].

Exogenous hormone adjusted cycles may require several treatment cycles before synchronisation of morphological events occurs in patients having functional ovaries. There is also the possibility of a cumulative affect from both sources of hormones. All naturally cycling patients that took part in the HST study displayed uterodomes in one or more of the 3 cycles examined (natural cycle, short follicular phase, or long follicular phase). Where the patient had an understimulated epithelium in the natural control cycle, exogenous hormones in subsequent cycles restored the morphological characteristics of the endometrium but did not necessarily result in the formation of uterodomes. Where the morphology of the secretory epithelia appeared normal in the natural cycle no further enhancement was noted during the following HST cycles, supporting the findings of Martel *et al.*, [47] and Nikas *et al.*, [39]. However, a subsequent cycle of HST did not always preserve the integrity of a secretory epithelium when observed in the natural control cycle. This supports the notion of a possible 'threshold' effect where the number of hormonal treatment cycles prior to ET may impinge on morphological integrity and impact on implantation outcome.

In summary, the only significant difference observed between the length of the follicular cycle ie: between 7 or 14 days of E₂ therapy was the level of secretion. Where uterodomes were observed on D3 or D5 of P₄ exposure they were absent by D8P suggesting that their appearance at or just prior to the time of implantation is necessary for the functional integrity of the endometrium if pregnancy is to progress. Baseline biopsies and manipulation of the secretory epithelium until uterodomes are observed is thus a useful tool for timing ET transfer.

Conclusions

The findings of this study suggest that pituitary down regulation of IVF patients with GnRH agonists prior to HRT

may assist in standardising epithelial surface appearance when compared to the variability observed during a natural control cycle. However, the tissue response is significantly different from the response observed in natural or menopausal tissue after HST or HRT. HRT on a post-menopausal endometrium or down-regulation followed by a controlled hormonal regime in IVF patients may serve to optimise endometrial priming in preparation for embryo transfer but close observation of morphological characteristics is required to maximize the potential outcome of these hormone treatment regimes. HST in a natural cycle has little significant effect on the morphological characteristics of a well stimulated epithelium but may be beneficial in timing the appearance of uterodomes. It also demonstrates that manipulation of the follicular phase is possible, that the appearance of uterodomes is dependent on P₄ exposure, and that maintaining the follicular phase length (14 days) may have beneficial effects on pregnancy outcomes by normalizing an otherwise variable tissue response.

Authors' contributions

Each author has contributed to the research and ultimate findings produced by this study. All authors have read and approved the final manuscript.

Acknowledgements

The authors wish to acknowledge the statistical assistance of Dr Kuo-Chin Huang, MD, PhD, a Visiting Scholar with the Human Nutrition Unit, University of Sydney; Attending Physician, Department of Family Medicine, National Taiwan University Hospital; Clinical Assistant Professor, National Taiwan University College of Medicine

References

1. Ljungkvist I: **Attachment reaction of rat uterine luminal epithelium. I. Gross and fine structure of the endometrium or the spayed, virgin rat.** *Acta Soc Med Upsal* 1971, **76**:91-109.
2. Ljungkvist I, Nilsson O: **Blastocyst-endometrial contact and pantamine blue reaction during normal implantation in the rat.** *J Endocrinol* 1974, **60**:149-154.
3. Murphy CR: **The plasma membrane of uterine epithelial cells: structure and histochemistry.** *Prog Histochem Cytochem* 1993, **27**:1-66.
4. Murphy CR, Rogers PA, Leeton J, Hosie M, Beaton L, Macpherson A: **Surface ultrastructure of uterine epithelial cells in women with premature ovarian failure following steroid hormone replacement.** *Acta Anat (Basel)* 1987, **130**:348-350.
5. Rogers P, Murphy C, Cameron I, Leeton J, Hosie M, Beaton L, Macpherson A: **Uterine receptivity in women receiving steroid replacement therapy for premature ovarian failure: ultrastructural and endocrinological parameters.** *Hum Reprod* 1989, **4**:349-354.
6. Murphy CR, Rogers PA, Kovacs G, Hales J, Hosie M, Beaton L: **Early valuation of postmenopausal hormonal steroid therapy by scanning electron microscopy of the uterine epithelium.** *Acta Anat* 1990, **138**:364-366.
7. Dean JH, Sullivan EA: **Assisted conception Australia and New Zealand 2000 and 2001.** *Australian Institute of Health and Welfare National Perinatal Statistics Unit (Assisted Conception Series No. 7) AIHW Cat. No. PER 22.* Sydney 2003.
8. Jansen RPS: **The effect of female age on the likelihood of a live birth from one in-vitro fertilisation treatment.** *Med J Aust* 2003, **178**:258-261.

9. Navot D, Drews MR, Bergh PA, Guzman I, Karstaedt A, Scott RT Jr, Garrisi GJ, Hofmann GE: **Age-related decline in female fertility is not due to diminished capacity of the uterus to sustain embryo implantation.** *Fertil Steril* 1994, **61**:97-101.
10. Jansen RPS: **Older Ovaries; ageing and reproduction.** *Med J Aust* 1995, **162**:623-624.
11. Cano F, Simon C, Remohi J, Pellicer A: **Effect of aging on the female reproductive system: evidence for a role of uterine senescence in the decline in female fecundity.** *Fertil Steril* 1995, **64**:584-589.
12. Pellicer A, Simon C, Remohi J: **Effects of aging on the female reproductive system.** *Hum Reprod* 1995, **10**(Suppl 2):77-83.
13. Adams SM, Gayer N, Terry V, Murphy CR: **Manipulation of the follicular phase: Uterodomes and pregnancy – is there a correlation?** *BMC Pregnancy and Childbirth* 2001, **1**:2 [<http://www.biomedcentral.com/1471-2393/1/2>].
14. Rebar RV: **Premature ovarian failure.** In *Biology and Pathobiology* Edited by: Lobo RA, Kelsey R, Marcus R. Academic Press, San Diego; 2000.
15. Meldrum DR: **Female reproductive aging – ovarian and uterine factors.** *Fertil Steril* 1993, **59**:1-5.
16. Borini A, Bafaro G, Violini F, Bianchi L, Casadio V, Flamigni C: **Pregnancies in postmenopausal women over 50 years old in an oocyte donation program.** *Fertil Steril* 1995, **63**:258-261.
17. Adams SM, Murphy CR: **A successful pregnancy following SEM fine tuning of hormonal priming.** *BMC Pregnancy and Childbirth* 2001, **1**:3 [<http://www.biomedcentral.com/1471-2393/1/3>].
18. Serhal PF, Craft IL: **Ovum donation – a simplified approach.** *Fertil Steril* 1987, **48**:265-269.
19. Serhal PF, Craft IL: **Oocyte donation in 61 patients.** *Lancet* 1989, **1**:1185-1187.
20. Navot D, Bergh PA, Williams M, Garrisi GJ, Guzman I, Sandler B, Fox J, Schreiner-Engel P, Hofmann GE, Grunfeld L: **An insight into early reproductive processes through the in vivo model of ovum donation.** *J Clin Endocrinol Metab* 1991, **72**:408-414.
21. Younis JS, Mordel N, Ligoletzky G, Lewin A, Schenker JG, Laufer N: **The effect of a prolonged artificial follicular phase on endometrial development in an oocyte donation program.** *J In Vitro Fert Embryo Transf* 1991, **8**:84-88.
22. Younis JS, Mordel N, Lewin A, Simon A, Schenker JG, Laufer N: **Artificial endometrial preparation for oocyte donation: the effect of estrogen stimulation on clinical outcome.** *J Assist Reprod Genet* 1992, **9**:222-117.
23. Shapiro H, Cowell C, Casper RF: **The use of vaginal ultrasound for monitoring endometrial preparation in a donor oocyte program.** *Fertil Steril* 1993, **59**:1055-1058.
24. Navot D, Anderson TL, Drosch K, Scott RT, Kreiner D, Rosenwaks Z: **Hormonal manipulation of endometrial maturation.** *J Clin Endocrinol Metab* 1989, **68**:801-807.
25. Younis JS, Ezra Y, Sherman Y, Simon A, Schenker JG, Laufer N: **The effect of estradiol depletion during the luteal phase on endometrial development.** *Fertil Steril* 1994, **62**:103-107.
26. Remohi J, Gutierrez A, Cano F, Ruiz A, Simon C, Pellicer A: **Long oestradiol replacement in an oocyte donation programme.** *Hum Reprod* 1995, **10**:1387-1391.
27. Yaron Y, Amit A, Mani A, Yovel I, Kogosowski A, Peyser MR, David MP, Lessing JB: **Uterine preparation with estrogen for oocyte donation: assessing the effect of treatment duration on pregnancy rates.** *Fertil Steril* 1995, **63**:1284-1286.
28. Rodriguez-Rigau LJ, Shenoi PN, Smith KD, Steinberger E: **The relationship between the lengths of the follicular and luteal phases of the menstrual cycle and the fertility potential of the female.** *Fertil Steril* 1983, **39**:856-857.
29. de Ziegler D, Cornet C, Bergeron C, Hazout A, Bouchard P, Frydman R: **Controlled preparation of the endometrium with exogenous estradiol and progesterone in women having functioning ovaries.** *Fertil Steril* 1991, **56**:851-855.
30. de Ziegler D, Bergeron C, Cornet C, Medalie DA, Massai MR, Milgrom E, Frydman R, Bouchard P: **Effects of luteal estradiol on the secretory transformation of human endometrium and plasma gonadotropins.** *J Clin Endocrinol Metab* 1992, **74**:322-331.
31. Steingold K, Stumpf P, Kreiner D, Liu HC, Navot D, Rosenwaks Z: **Estradiol and progesterone replacement regimens for the induction of endometrial receptivity.** *Fertil Steril* 1989, **52**:756-760.
32. Younis JS, Simon A, Laufer N: **Endometrial preparation: lessons from oocyte donation.** *Fertil Steril* 1996, **66**:873-884.
33. Nikas G: **Endometrial receptivity: changes in cell-surface morphology.** *Semin Reprod Med* 2000, **18**:229-235.
34. Noyes RW, Hertig AT, Rock J: **Dating the endometrial biopsy.** *Am J Obstet Gynecol* 1975, **122**:262-3.
35. Psychoyos A, Nikas G: **Uterine pinopods as markers of uterine receptivity.** *Ass Reprod Rev* 1994, **4**:26-32.
36. Nikas G, Psychoyos A: **Uterine pinopodes in peri-implantation human endometrium. Clinical relevance.** *Ann NY Acad Sci* 1997, **816**:129-142.
37. Johannisson E, Nilsson L: **Scanning electron microscopic study of the human endometrium.** *Fertil Steril* 1972, **23**:613-625.
38. Psychoyos A, Martel D: **Problems related to the implantation of the human egg after in vitro fertilization.** *Acta Europ Fertil* 1985, **16**:107-109.
39. Nikas G, Drakakis P, Loutradis D, Mara-Skoufari C, Koumantakis E, Michalas S, Psychoyos A: **Uterine pinopodes as markers of the 'nidation window' in cycling women receiving exogenous oestradiol and progesterone.** *Hum Reprod* 1995, **10**:1208-1213.
40. Paulson RJ, Sauer MV, Lobo RA: **Potential enhancement of endometrial receptivity in cycles using controlled ovarian hyperstimulation with antiprogesterins: a hypothesis.** *Fertil Steril* 1997, **67**:321-325.
41. Nikas G: **Cell-surface morphological events relevant to human implantation.** *Hum Reprod* 1999, **14**(Suppl 2):37-44.
42. Nikas G: **Pinopodes as markers of endometrial receptivity in clinical practice.** *Hum Reprod* 1999, **14**(Suppl 2):99-106.
43. Stavreus-Evers A, Nikas G, Sahlin L, Eriksson H, Landgren B-M: **Formation of pinopodes in human endometrium is associated with the concentrations of progesterone and progesterone receptors.** *Fertil Steril* 2001, **76**:782-791.
44. Develioglu OH, Hsiu JG, Nikas G, Toner JP, Oehninger S, Jones HW Jr: **Endometrial estrogen and progesterone receptor and pinopode expression in stimulated cycles of oocyte donors.** *Fertil Steril* 1998, **71**:1040-1047.
45. Ferenczy A, Richart RM, Agate FJ Jr, Purkerson ML, Dempsey EW: **Scanning electron microscopy of the human endometrial surface epithelium.** *Fertil Steril* 1972, **23**:515-521.
46. Ferenczy A, Richart RM: **Scanning electron microscopy of human female genital tract.** *N Y St J Med* 1974, **74**:794-802.
47. Martel D, Malet C, Gautray JP, Psychoyos A: **Surface changes of the luminal uterine epithelium during the human menstrual cycle: a scanning electron microscopic study.** In *The Endometrium: Hormonal Impacts* Edited by: de Brux J, Mortel R, Gautray JP. Plenum Publishing Corporation; 1981:15-29.
48. Ludwig H, Spornitz UM: **Microarchitecture of the human endometrium by scanning electron microscopy: menstrual desquamation and remodeling.** *Ann NY Acad Sci* 1991, **622**:28-46.
49. Ludwig H, Metzger H: **The Human Female Reproductive Tract: a scanning electron microscopic atlas.** Springer-Verlag, New York; 1976.
50. Sundstrom P, Nilsson BO: **Postovulatory endometrium.** In *Atlas of Human Reproduction by Scanning Electron Microscopy* Edited by: Hafez ESE, Keneman P. MTP Press Ltd., Lancaster; 1982:61-70.
51. Bourgain C, Devroey P, Van Waesberghe L, Smitz J, Van Steirteghem AC: **Effects of natural progesterone on the morphology of the endometrium in patients with primary ovarian failure.** *Hum Reprod* 1990, **5**:537-543.
52. Li TC, Dockery P, Ramsewak SS, Klentzeris L, Lenton EA, Cooke ID: **The variation of endometrial response to a standard hormone replacement therapy in women with premature ovarian failure. An ultrasonographic and histological study.** *Br J Obstet Gynaecol* 1991, **98**:656-661.
53. Pellicer A, Gaitan P, Neuspiller F, Ardiles G, Albert C, Remohi J, Simon C: **Ovarian follicular dynamics: from basic science to clinical practice.** *J Reprod Immunol* 1998, **39**:29-6.
54. Baracat EC, Simoes MJ, Soares JM Jr, Haidar MA, Rodrigues de Lima G: **Ultrastructural aspects of the postmenopausal endometrium after oral or transdermal estrogen administration.** *Clin Exp Obstet Gynecol* 2001, **28**:26-30.
55. Nikas G, Develioglu OH, Toner JP, Jones HW Jr: **Endometrial pinopodes indicate a shift in the window of receptivity in IVF cycles.** *Hum Reprod* 1999, **14**:787-792.

56. Dallenbach-Hellweg G: **The endometrium in the climacterium and after the menopause.** In *Histopathology of the Endometrium* Springer-Verlag, Berlin; 1987:86-92.
57. Woodruff JD, Pickar JH: **Incidence of endometrial hyperplasia in postmenopausal women taking conjugated estrogens (Premarin) with medroxyprogesterone acetate or conjugated estrogens alone.** *Am J Obstet Gynecol* 1994, **170**:1213-1223.
58. Nilsson BO, Knoth M, Nathan E: **Scanning electron microscopy of the responses of postmenopausal endometrium to treatment with estriol and estriolprogesterone.** *Ups J Med Sci* 1980, **85**:1-6.
59. Noci I, Borri P, Scarselli G, Chieffi O, Bucciantini S, Biagiotti R, Paglierani M, Moncini D, Taddei G: **Morphological and functional aspects of the endometrium of asymptomatic post-menopausal women: does the endometrium really age?** *Hum Reprod* 1996, **11**:2246-2250.
60. Creus M, Ordi J, Fábregues F, Casamitjana R, Carmona F, Cardesa A, Vanrell JA, Balash J: **The effect of different hormone therapies on integrin expression and pinopode formation in the human endometrium: a controlled study.** *Hum Reprod* 2003, **18**:683-693.

Publish with **BioMed Central** and every scientist can read your work free of charge

"BioMed Central will be the most significant development for disseminating the results of biomedical research in our lifetime."

Sir Paul Nurse, Cancer Research UK

Your research papers will be:

- available free of charge to the entire biomedical community
- peer reviewed and published immediately upon acceptance
- cited in PubMed and archived on PubMed Central
- yours — you keep the copyright

Submit your manuscript here:
http://www.biomedcentral.com/info/publishing_adv.asp

