

Available online at www.sciencedirect.com

ScienceDirect

journal homepage: www.elsevier.com/locate/radcr

Case Report

Recurrent MALT lymphoma presenting as renal calyceal-pelvic rupture. What is the cause of this break?

Donatella Ferrari, MD*, Silvia Pugliese, MD, Salvatore Marsico, MD, Feliciano Lamacchia, MD, Federica Di Tosto, MD, Andrea Amico, MD, Emanuela Beninati, MD, Andrea Cimini, MD, Roberto Floris, PhD

Department of Biomedicine and Prevention, UOC of Diagnostic Imaging, University of Rome "Tor Vergata", Viale Oxford 81, 00133, Rome, Italy

ARTICLE INFO

Article history:

Received 24 March 2019

Revised 2 June 2019

Accepted 2 June 2019

Available online 26 June 2019

Keywords:

Spontaneous

Renal

Calyceal-pelvic

Rupture

Lymphoma

Recurrence

ABSTRACT

Urinary collecting system rupture is an uncommon condition that usually occurs with symptoms of acute abdomen, secondary to peritoneal irritation by urine leaking. We report a case of a 49-year-old man admitted to our emergency department because of a worsening deep lower abdominal pain started 3 days before.

The abdominal computed tomography revealed urine extravasation suggesting for urinoma. Because of patient pathological history of lymphoma, despite its apparent state of remission, he underwent a positron emission tomography - computed tomography with ¹⁸F-FDG and magnetic resonance in order to rule out a recurrence.

Imaging supported the diagnostic hypothesis of a lymphatic recurrence that had compressed "ab-extrinseco" the urinary tract so much to break it. Based on our experience we can suggest that nontraumatic calyceal-pelvic rupture is an extremely rare manifestation of an onset of lymphoma.

© 2019 The Authors. Published by Elsevier Inc. on behalf of University of Washington.

This is an open access article under the CC BY-NC-ND license.

(<http://creativecommons.org/licenses/by-nc-nd/4.0/>)

Case report

A 49-year-old man was admitted to our emergency department because of a worsening deep lower abdominal pain started 3 days before. The patient denied the pres-

ence of any hematuria, dysuria or other significant lower urinary tract symptoms. He did not report previous trauma, surgery, urolithiasis history, or relevant past diseases except for a MALT (Mucosa Associated Lymphoid Tissue) with gastric localization, diagnosed 6 months before and under chemotherapy treatment, in clinical and radiological remis-

Abbreviations: MALT, Mucosa Associated Lymphoid Tissue; PET/CT, Positron Emission Tomography - Computed Tomography; FDG, ¹⁸F-fluorodeoxyglucose; CT, Computed Tomography; MR, Magnetic Resonance; DWI, Diffusion Weighted Imaging.

Competing Interests: The authors have declared that no competing interests exist.

* Corresponding author.

E-mail address: donatella.ferrari91@gmail.com (D. Ferrari).

<https://doi.org/10.1016/j.radcr.2019.06.002>

1930-0433/© 2019 The Authors. Published by Elsevier Inc. on behalf of University of Washington. This is an open access article under the CC BY-NC-ND license. (<http://creativecommons.org/licenses/by-nc-nd/4.0/>)

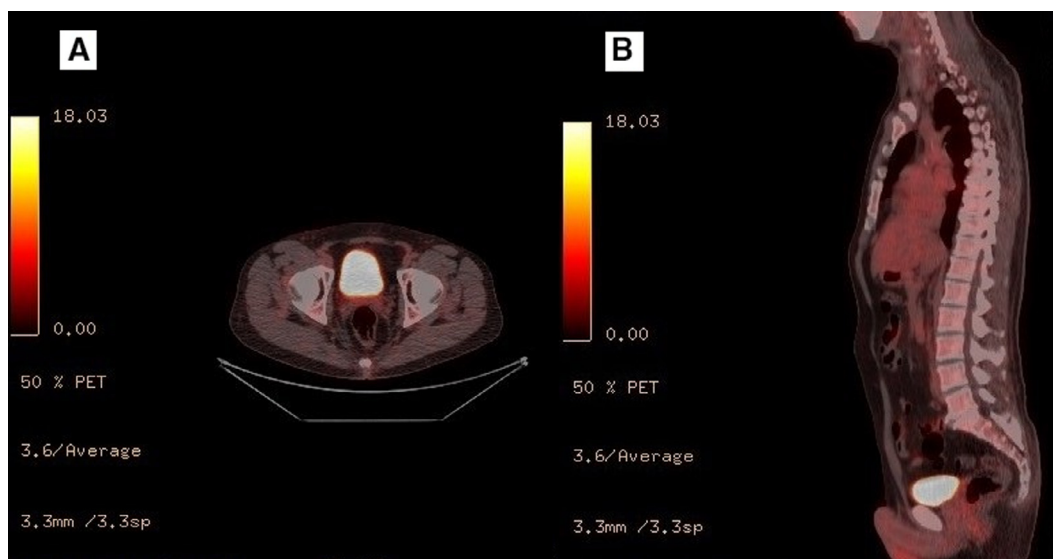


Fig. 1 – PET/CT evaluation with ^{18}F -fluorodeoxyglucose, executed a months before the access in emergency department, showing in axial (A) and sagittal planes (B) no FDG uptake resulting as a remission of original lymphoma. PET/CT, positron emission tomography - computed tomography; FDG, ^{18}F -fluorodeoxyglucose.

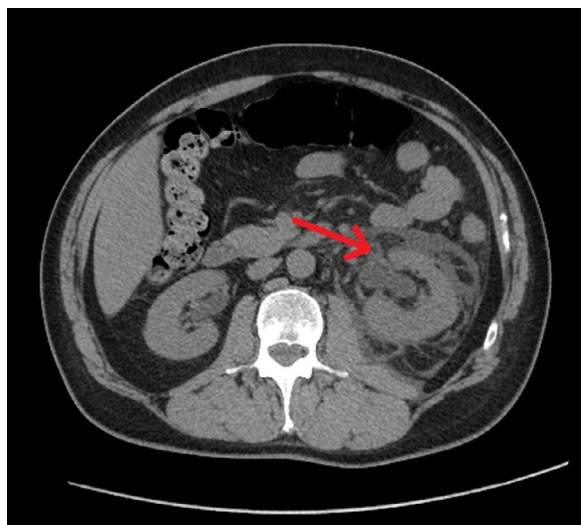


Fig. 2 – Abdominal CT in axial plane showing, at the point indicated by the arrow, retroperitoneal free fluid around the left renal pelvis and in the anterior perinephric space. CT, computed tomography.

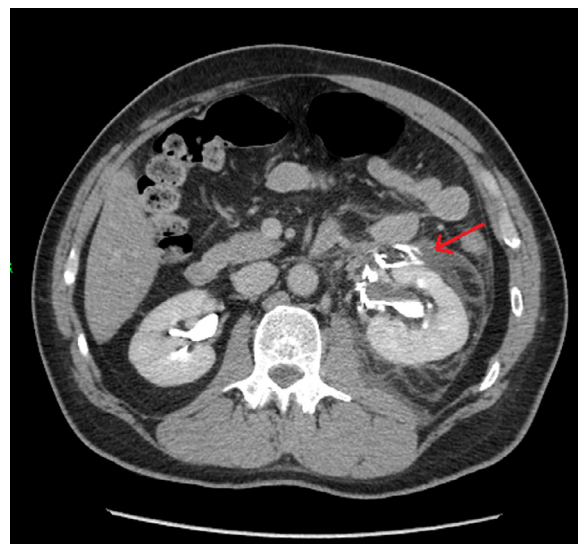


Fig. 3 – Contrast-enhanced CT in axial plane, after 8 minutes, showing, at the point indicated by the arrow, the iodinated urine leakage and the increasing density of fluid collection.

sion. The positron emission tomography - computed tomography (PET/CT) with ^{18}F -fluorodeoxyglucose (FDG), executed a month before, after the last chemotherapy cycle, showed no uptake of the radiotracer in the gastric wall or in close lymph nodes, previously identified as pathological localizations, thus defining a radiological remission of the original lymphoma (Fig. 1).

Clinically, the patient was afebrile and hemodynamically stable with a 100 beats/min pulse and a 145/90 mm Hg blood pressure. At the physical examination the abdomen was not tense, but very painful in the lower side, with associated positive renal punch on the left side. Blood test showed a

WBC count within regular limits associated with an altered neutrophil-to-lymphocyte ratio (83.1%-6.7%); other laboratory exams were into the normal range including renal and liver function tests.

The abdominal X-rays did not reveal any suspicious elements but, despite the analgesia, the symptoms were getting worse and a computed tomography (CT) was required to define a proper etiology.

The abdominal CT, performed with a Lightspeed VCT 64-slice (General Electric, Boston, MA) revealed a retroperitoneal free fluid around the left renal pelvis and in the anterior perinephric space, as well as in the lower abdomen, suggesting

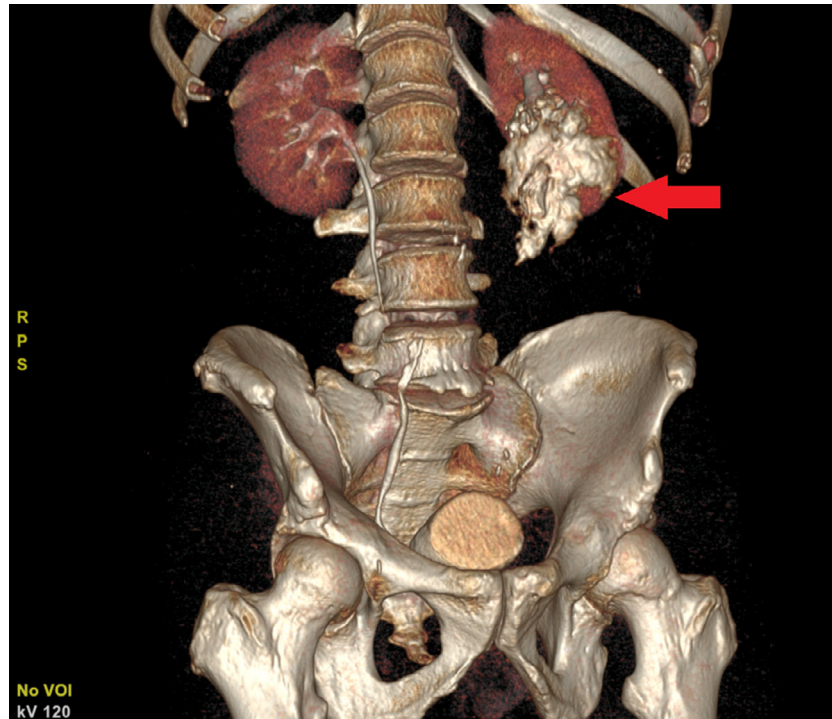


Fig. 4 – 3D volume rendering coronal reconstruction identifying the position of leak, likely originating from the upper and middle calyceal group of the left kidney, as indicated by the arrow.

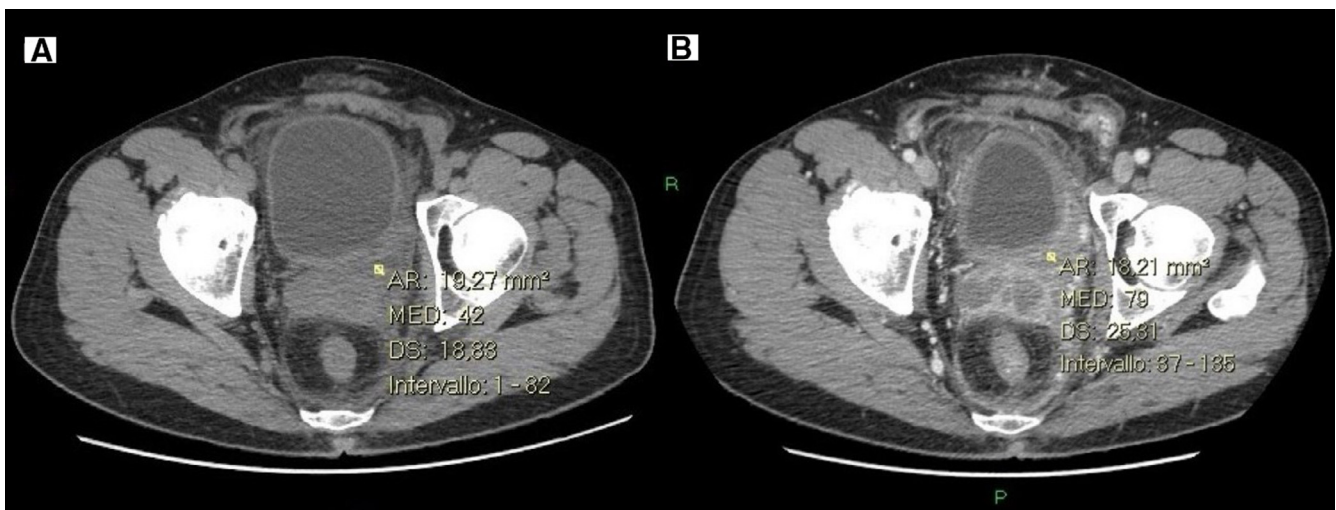


Fig. 5 – Abdominal CT in axial plane showing the presence of high density fluid collection with contrast enhancement.

for urine extravasation (Fig. 2). The urinoma was confirmed at delayed scans (after 8 minutes) after iodinated contrast intravenous administration (100 mL, 350 mg/mL, 2.5 mL/s.), by the iodinated urine leakage and the increasing density of fluid collection over time (Fig. 3). No calculi inside the genitourinary system have been demonstrated. No obstruction or injuries were detected in right ureter. Three-dimensional volume rendering reconstruction images accurately identified the position of the leak, likely originating from the upper and middle calyceal group of the left kidney (Fig. 4).

A retrograde pyelography was quickly performed in order to treat the acute lesion.

Through the introduction of a rigid cystoscope (Storz 22 Ch), that did not demonstrate bladder abnormalities, left ascending pyelography did not show any calculus or stenosis of the ipsilateral ureter. There was a good visualization of pelvis and calyceal groups, and contrast media injection under fluoroscopy allowed to precisely demonstrate the site of the rupture in the upper and middle calyceal group. Subsequently, ureteral stent JJ (Vortek 6/26) was positioned from upper

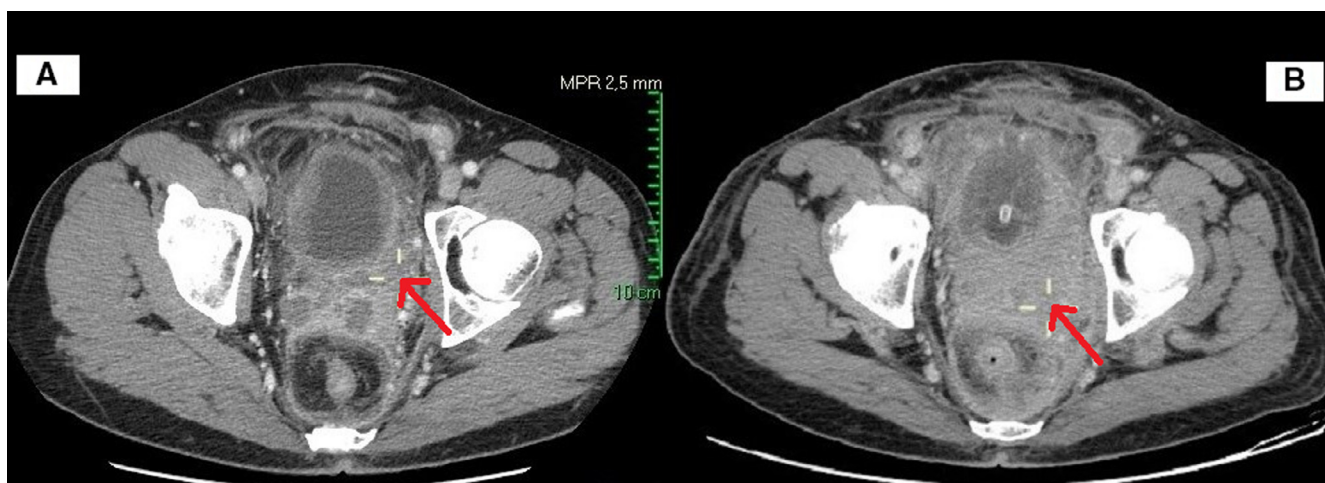


Fig. 6 – Abdominal CT in axial plane performed 10 days after the urine leakage (B) compared to the CT performed after stent placement (A) shows dimensional increase of the high density fluid located in pelvis, pointed by the arrows.

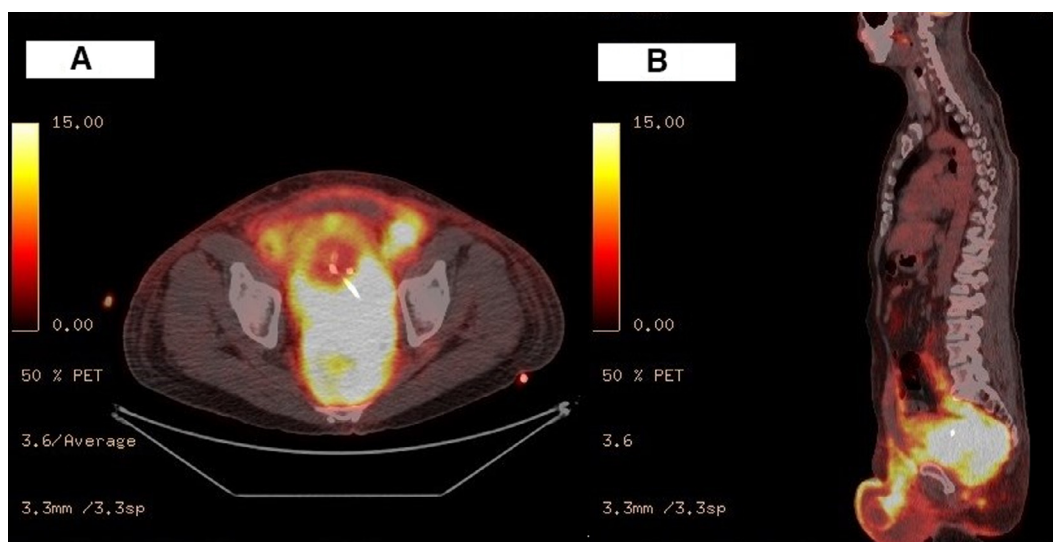


Fig. 7 – PET/CT evaluation with ^{18}F -fluorodeoxyglucose, showing in axial (A) and sagittal (B) planes high FDG uptake in pathological tissue located in pelvis.

calyceal group to bladder, along hydrophilic guidewire, checking its correct positioning. At the end of the procedure, a Dufur-type bladder catheter was inserted, which pulled out freshly-pinked urine, and the patient was sent to an empiric antibiotic therapy.

After the acute situation, 3 days later a urographic CT with iodinated contrast intravenous administration was performed showing left ureteral stent in situ without contrast extravasation. Few days later another CT examination showed the dimensional increase of a high-density fluid collection (42 HU attenuation spreading) with contrast enhancement (Fig. 5), that was located in pelvis, mainly situated on the left side up to the scrotal region, and involving left ureter and blood vessels, as a possible substrate that increased pressure and caused the calyceal-pelvic rupture (Fig. 6). Because of his pathological history of lymphoma, the patient underwent a

PET/CT with ^{18}F -FDG, that showed intense and diffuse radio-tracer uptake in that pelvic pathological tissue (Fig. 7), not evident in the first PET/CT, executed a month before the access in the emergency department, and better characterized in a consecutive Magnetic Resonance exam performed by an Achieva 1.5 T (Philips Healthcare, Best, Netherlands) with 14 mL gadoteridol Prohance (Bracco, Milan, Italy) as paramagnetic intravenous contrast agent.

The pathological tissue was extended from the rectovesical pouch, and the scrotal region up to the upper tract of the left ureter, causing an important compression of this one (Fig. 8). Moreover, the diffusion-weighted imaging revealed low values of apparent diffusion coefficient (ADC) with a middle value of $0.7 \text{ mm}^2/\text{sec}$, which supported the diagnostic hypothesis of a lymphatic recurrence (Fig. 9).

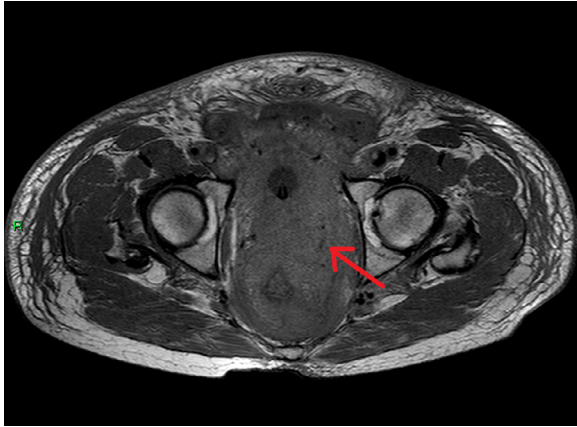

Fig. 8 – MR T1 TSE sequence in axial plane showing the extension of the pathological tissue from rectovesical pouch (pointed by the arrow) and scrotal region until the upper tract of left ureter.

Discussion

Urine leak can originate from kidney, ureter, bladder, and urethra. It is defined “spontaneous” when it is not caused by trauma, iatrogenic events, or degenerative renal diseases.

Concerning renal urine leaks, they origin from disruption of the calices, infundibula, or renal pelvis. Most commonly, these kinds of leaks result from blunt or penetrating renal trauma, but they may also be the result of transmitted back pressure caused by the obstruction of the genitourinary system due to an ureteral stone, pelvic mass, pregnancy, retroperitoneal fibrosis, posterior urethral valves, or bladder outlet obstruction [1]. Of course also urinary tract primary tu-

mors and metastatic pathology must be considered. In our case, at first the urine extravasation seemed with unknown origin, also due to the absence of urothelial calculi, any genitourinary pathological antecedents and to the apparent state of remission of the patient from the lymphoma.

In literature, very few cases of urinary tract rupture of unknown origin have been observed. A case in which the cause has not been found has been described by Aggarwal et al [2], while the largest number of events have been reported by Stravodimos et al [3], and by Paaajanen [4] which listed respectively 4 cases, and 3 cases of ureter urine extravasation with unknown origin.

In our case, as showed in Figure 10, we continued on the radiological diagnostic path to find an etiology of spontaneous rupture. In particular we studied the pelvic pathological tissue detected by the second CT suspected for lymphoma recurrence and possible cause of calyceal-pelvic rupture. We believe that the pathophysiologic reason for the caliceal breakage is an “ab extrinseco” compressions mechanism, caused by a sudden increase pressure in the upstream section of the constriction due to the distal pathological tissue dimensional growth. The increase in pressure causes a gradual dilatation ending with the breakage. This can also be justified by the fact that pathological tissue was located in lower abdomen in a paramedian position on the left side, and this agrees with the breaking of the left calices and with the uninjured condition of right ureter and right caliceal groups.

To our knowledge this is the first case of calyceal-pelvic rupture in a patient with extraurinary lymphoma reported in literature. Only 1 case of spontaneous perforation in a patient with lymphomatous disease was reported [5], but in this case, pyelography showed a diffuse filling defect in the left ureter with histopathological diagnosis of diffuse large B-cell lymphoma.

In MALT lymphomas the stomach is generally the commonest localization. The clinical aspects and most common presenting symptoms are nonspecific dyspepsia, epigastric pain, nausea, and chronic manifestations of gastrointestinal bleeding, such as anemia. Regarding the small intestine, the

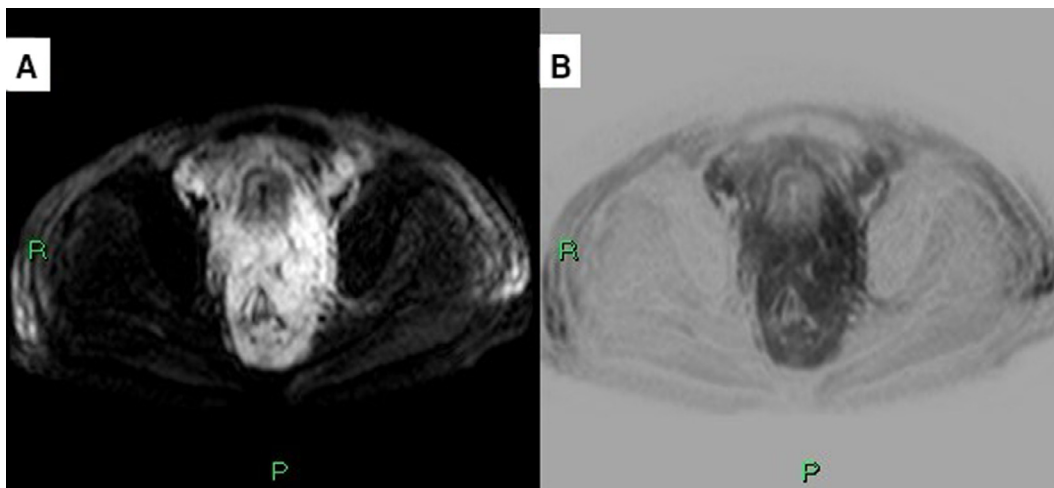


Fig. 9 – MR diffusion-weighted imaging (DWI) (A) and inverted DWI (B).

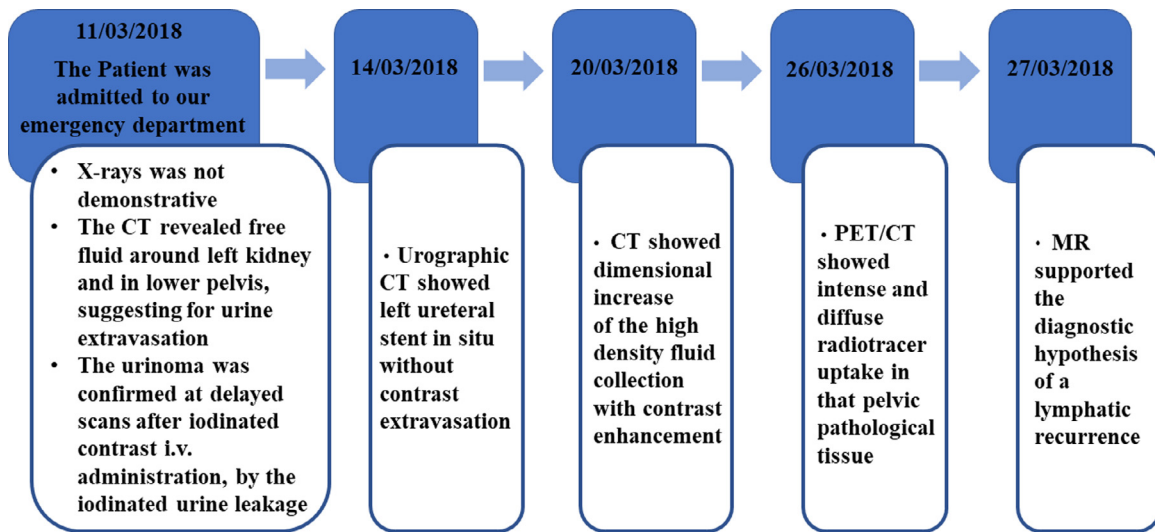


Fig. 10 – Timeline of radiological diagnostic path beginning from the presentation.

clinical manifestations usually are severe with unremitting malabsorption [6].

In our case, the patient did not have neither any typical MALT symptoms, or nocturne perspiration, or fever, nor any rare symptoms such as priapism, which is more common as initial manifestation in leukemia, but not in lymphoma [7]. Additionally blood exams were all into regular ranges.

Only later, we diagnosed the rupture as a result of transmitted back pressure caused by a rapidly growing pelvic mass, as a recurrence of MALT lymphoma, which for the rest was asymptomatic.

Currently, renal pelvis rupture causes urinoma or local inflammation and it is successfully treated by conservative methods with ureteral stent implantation [8], but surgical complication like peritonitis and septic shock can occur, so exploratory laparotomy and surgical intervention should be warranted in emergency cases [9]. Our patient was treated with ureteral stent by interventional radiology without complications and then addressed to medical therapy for the treatment of lymphoma.

Acknowledgments

None.

REFERENCES

- [1] Titton RL, Gervais DA, Hahn PF, Harisinghani MG, Arellano RS, Mueller PR. Urine leaks and urinomas: diagnosis and imaging-guided intervention. *Radiographics* 2003;23(5):1133–47.
- [2] Aggarwal G, Das Adhikary S. Spontaneous ureteric rupture, a reality or a faux pas? *BMC Urol* 2016;16(1):37.
- [3] Stravodimos K, Adamakis I, Koutalellis G. Spontaneous perforation of the ureter: clinical presentation and endourologic management. *J Endourol* 2008;22:479–84.
- [4] Paajanen H, Kettunen J, Tainio H, Jauhiainen K. Spontaneous peripelvic extravasation of urine as a cause of acute abdomen. *Scand J Urol Nephrol* 1993;27:333–6.
- [5] Yoshii T, Horiguchi A, Shirotake S, Tobe M, Hayakawa M, Sumitomo M, et al. Spontaneous rupture of the ureter as the primary symptom of malignant lymphoma. *Hinyokika Kiyo* 2010;56(11):639–43.
- [6] Thieblemont C, Zucca E. Clinical aspects and therapy of gastrointestinal MALT lymphoma. *Best Pract Res Clin Haematol* 2017;30(1-2):109–17.
- [7] Gong Z, Zhang Y, Chu H, Lian P, Zhang L, Sun P, et al. Priapism as the initial symptom of primary penile lymphoma: a case report. *Oncol. Lett.* 2014;8(5):1929–32 Epub 2014 Aug 28.
- [8] Takena Kerem, Oncub Mehmet Res, Ergunc Muslum, Eryilmaz Recep, Gunes Mustafa. Isolated renal pelvis rupture secondary to blunt trauma: case report. *Int J Surg Case Rep* 2015:82–4.
- [9] Ghritlaharey R.K., More S. Management of ruptured occult left hydronephrotic kidney in 7-year-old boy: a case report. 2014;8(10):ND12–4.