

Contents lists available at [ScienceDirect](http://www.sciencedirect.com)

## International Journal of Surgery Case Reports

journal homepage: [www.casereports.com](http://www.casereports.com)Pulmonary mucinous cystadenocarcinoma presenting as a pleural mesothelioma<sup>☆</sup>Radwan Kassir<sup>a,\*</sup>, Fabien Forest<sup>b</sup>, David Kaczmarek<sup>c</sup><sup>a</sup> Department of General Surgery, CHU Hospital, Jean Monnet University, Saint Etienne, France<sup>b</sup> Department of Pathology, CHU Hospital, Jean Monnet University, Saint Etienne, France<sup>c</sup> Department of Thoracic Surgery, Clinique Chirurgicale Mutualiste, Saint Etienne, France

## ARTICLE INFO

## Article history:

Received 18 June 2013

Received in revised form 6 August 2013

Accepted 7 August 2013

Available online 13 August 2013

## Keywords:

Surgery

Pleura

Lobectomy

Lung cancer

Outcomes

## ABSTRACT

**INTRODUCTION:** Primary Pulmonary Mucinous Cystadenocarcinoma PPMC is an extremely rare subtype of pulmonary adenocarcinoma, with only a few dozen cases reported in the literature to date.**PRESENTATION OF CASE:** We report an extremely rare case of pulmonary mucinous cystadenocarcinoma presenting as a pleural mesothelioma. 53-year-old man exposed to asbestos, he is admitted in hospital with a 5 cm mass in right pleura. He was treated by wedge resection. Sparse groups of malignant cells were microscopically observed in pools of mucin. The postoperative histopathological findings were in accordance with the diagnosis of pulmonary mucinous cystadenocarcinoma on cystic adenoid malformation of lung. 5 years later, the patient has no recurrence.**DISCUSSION:** PPMC is usually asymptomatic; hemoptysis is seen occasionally. Preoperative diagnosis is very difficult to establish. Both FNA cytology and transbronchial lung biopsy seem inadequate. Our patient went on to undergo open lung biopsy and histopathological testing that confirmed the diagnosis of PPMC. **CONCLUSION:** It is important to differentiate this rare pathological feature of the lung from other lung tumors as the treatment is surgical rather than medical. Thoracic surgeons should bear in mind this rare tumor for the differential diagnosis of a pleural mesothelioma because this tumor has a favorable prognosis.

© 2013 The Authors. Published by Elsevier Ltd on behalf of Surgical Associates Ltd. All rights reserved.

## 1. Introduction

Primary Pulmonary Mucinous Cystadenocarcinoma PPMC is an extremely rare variety of lung cancer. PPMC belongs to a group of cystic neoplasms characterized by extracellular mucin secretion. These mucinous neoplasms are histologically similar to well-recognized mucinous tumors of the pancreas, breast, and ovary. Preoperative diagnosis is very difficult. This tumor has a remarkably favorable prognosis.

## 2. Presentation of case

A 49-year-old former smoker exposed to asbestos was admitted to our unit of general and thoracic surgery for exploration

mass in the right lung. The patient had no relevant history of lung disease, but few months before hospital admission had reported a pain in the right hemithorax. He had no fever, cough, sputum or hemoptysis. Chest X-ray revealing a solitary tumor in the right lower lobe of the lung. CT scan of the chest showed a heterogeneous mass, 5 cm × 7 cm at its maximum diameter in the inferior lobe of the right lung. The contrast-enhancing tumor seemed to be pleural (Figs. 1 and 2). We had suspected pleural mesothelioma, sarcoma. The case was discussed by multidisciplinary oncological team with decision to do wedge resection without transthoracic CT-guided needle aspiration, bronchoscopy, or FNA.

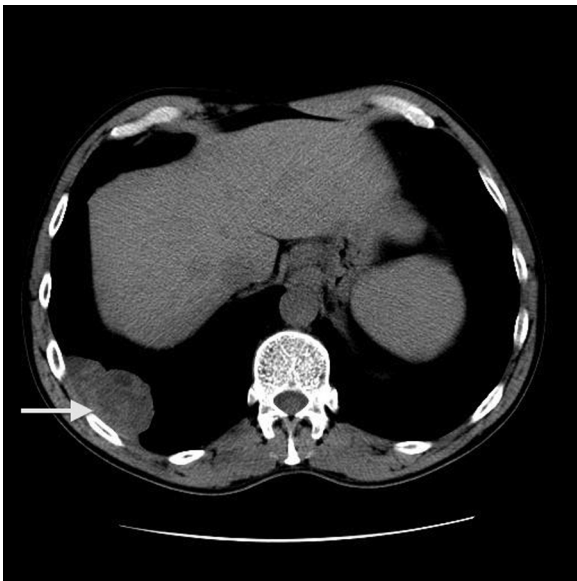
Because a malignant tumor could not be ruled out, a thoracotomy and wedge resection of the right lower lobe with sufficient surgical margin was performed to obtain a definitive diagnosis. The postoperative histopathological findings were in accordance with the diagnosis of PPMC on cystic adenoid malformation of lung type 2 (Figs. 3 and 4). Immunohistochemical analysis showed positive immunostaining for CK 20 (in the mucous glands), TTF1 (in the serous glands) CK 7 and smooth muscle actin and negative immunostaining for CK34, PSA, TTF1 (in the mucous glands), and CK20 (in the serous glands).

Lobectomy was performed. The postoperative period was simple. The multidisciplinary oncological team decided to do surveillance. 5 years later, the patient has no recurrence.

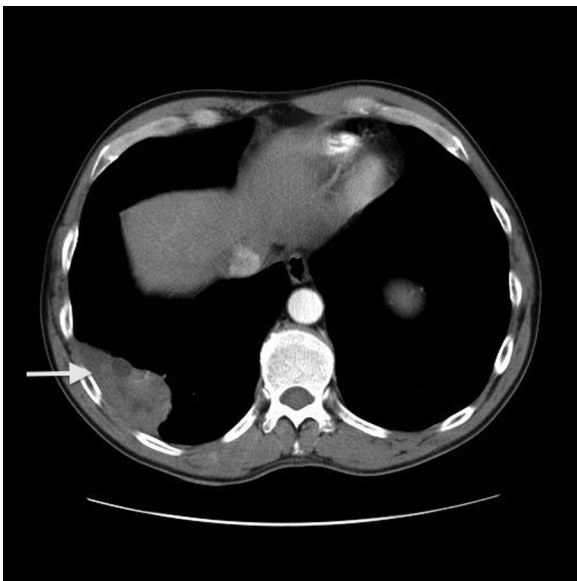
<sup>☆</sup> This is an open-access article distributed under the terms of the Creative Commons Attribution-NonCommercial-No Derivative Works License, which permits non-commercial use, distribution, and reproduction in any medium, provided the original author and source are credited.

\* Corresponding author at: Department of Digestive Surgery, CHU Hospital, Jean Monnet University, Avenue Albert Raimond, 42270 Saint Etienne, France. Tel.: +33 6 13 59 19 71.

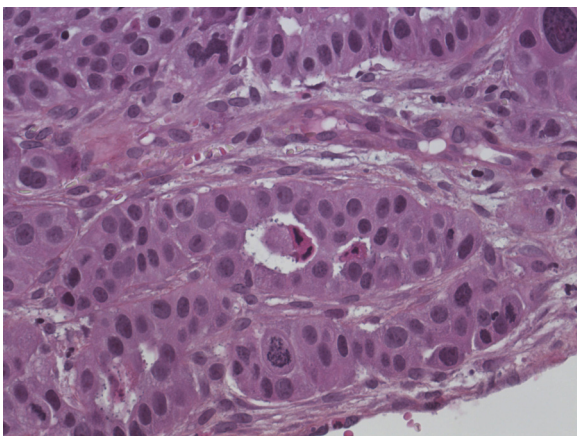
E-mail address: [Radwankassir42@hotmail.fr](mailto:Radwankassir42@hotmail.fr) (R. Kassir).



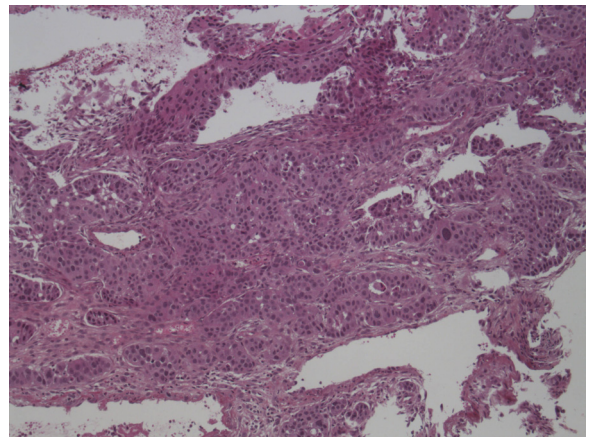
**Fig. 1.** CT scan of the chest without contrast showed a heterogeneous mass in the inferior lobe of the right lung (arrow).



**Fig. 2.** CT scan of the chest with contrast. The contrast-enhancing tumor seemed to be pleural.



**Fig. 3.** The anatomopathologic results. Pulmonary Mucinous Cystadenocarcinoma.



**Fig. 4.** The anatomopathologic results. Pulmonary Mucinous Cystadenocarcinoma.

**3. Discussion**

Primary Pulmonary Mucinous Cystadenocarcinoma PPMC is an extremely rare subtype of pulmonary adenocarcinoma,<sup>1</sup> with only a few dozen cases reported in the literature to date.<sup>2</sup> Approximately 2/3 of cases have been associated with tobacco smoking.<sup>2</sup> Cases have been reported in patients as young as 29.<sup>3</sup> PPMC is usually asymptomatic.<sup>4</sup> Hemoptysis is seen occasionally.<sup>4</sup> Preoperative diagnosis is very difficult to establish. Both FNA cytology and transbronchial lung biopsy seem inadequate.

We report a first case of PPMC presenting as a pleural mesothelioma. Indeed, the pain, the asbestos exposure and the CT scan of the chest evoked pleural mesothelioma. The postoperative histopathological findings were in accordance with the diagnosis of PPMC. Therefore we must have to add the pleural mesothelioma in the list of differentials diagnostics of PPMC. The histopathological differential diagnosis of primary PPMC includes primary lesions of the lung and metastatic tumors from other organs, especially the ovary, breast, and pancreas. The biological behavior of PPMC is generally unknown.

The tumors tend to be well circumscribed by a partial fibrous tissue capsule with central cystic change and copious mucin pooling.<sup>2</sup> The thin, fibrous wall circumscribing the tumor is highly characteristic of this lesion.<sup>5</sup>

The most effective treatment for PPMC is surgical resection. Lobectomy is considered to be the standard surgical modality for PPMC.<sup>6</sup> It has much more favorable prognosis than most other forms of adenocarcinoma<sup>7</sup> and most pleural mesothelioma. Cases have been documented of continued growth of these lesions over a period of 10 years without symptoms.<sup>3</sup> Thorough clinical examination is necessary to rule out another site of origin. No metastasis to extrathoracic sites has been reported.

We should have suggested preoperative histological verification by means of bronchoscopy and FNA, or transthoracic CT-guided needle aspiration. May be we should have invested more efforts in establishing preoperative verification. Preoperative histological diagnosis will contribute to prevent an unnecessary second surgery in general anesthesia, which was required in our patient. Considering the number of differential diagnoses, it may be difficult for the pathologist to decide on one definitive diagnosis in a frozen section test.

Before the final choice of treatment is made, thoracic surgeons should bear in mind this rare tumor for the differential diagnosis of a pleural mesothelioma, metastatic lesion and pulmonary cystic lesion. It is important to differentiate this rare pathological feature of the lung from other lung tumors as the treatment is surgical rather than medical. Indeed, this tumor has a remarkably favorable prognosis.

**Conflict of interest statement**

None.

**Funding**

None.

**Consent**

“Written informed consent was obtained from the patient for publication of this case report and accompanying images. A copy of the written consent is available for review by the Editor-in-Chief of this journal on request.”

**Author contributions**

Radwan Kassir: Writing.

Fabien Forest: Writing.

David Kaczmarek: Data collections.

**References**

1. Ishibashi H, Moriya T, Matsuda Y, et al. Pulmonary mucinous cystadenocarcinoma: report of a case and review of the literature. *Ann Thorac Surg* 2003;**76**(5): 1738–40.
2. Gao ZH, Urbanski SJ. The spectrum of pulmonary mucinous cystic neoplasia: a clinicopathologic and immunohistochemical study of ten cases and review of literature. *Am J Clin Pathol* 2005;**124**(1):62–70.
3. Sezer O, Hoffmeier A, Bettendorf O, et al. Mucinous cystadenocarcinoma—an extremely rare tumor in a young patient. *Thorac Cardiovasc Surg* 2006;**54**(3): 216–7.
4. Iwasaki T, Kawahara K, Nagano T, Nakagawa K. Pulmonary mucinous cystadenocarcinoma: an extremely rare tumor presenting as a cystic lesion of the lung. *Gen Thorac Cardio Vasc Surg* 2007;**55**(3):143–6.
5. Tangthangtham A, Chonmaitri I, Tungsagunwattana S, Charupatanapongse U. Mucinous cystadenocarcinoma of the lung. *J Med Assoc Thai* 1998;**81**(10): 794–8.
6. Okimasa S, Kurimoto N. Mucinous (colloid) adenocarcinoma. *Jpn J Thorac Cardiovasc Surg* 2005;**53**:305–8.
7. Raza SA, Alexakis C, Creagh M, Lawrence DR, Wood M. Primary pulmonary mucinous cystadenocarcinoma presenting as a complex bronchocele: a case report. *J Med Case Rep* 2009;**3**:858–61.

**Open Access**

This article is published Open Access at [scimedirect.com](http://scimedirect.com). It is distributed under the [IJSCR Supplemental terms and conditions](#), which permits unrestricted non commercial use, distribution, and reproduction in any medium, provided the original authors and source are credited.