



Case report

A rare case of low voltage electrical injury leading to bilateral femur fractures and vertebral body fractures: A case report and review of the literature

David Ritchie^a, Adel Elkbuli^{a,*}, Mark McKenney^{a,b}, Michael Renda^{a,b}

^a Department of Surgery, Division of Trauma and Surgical Critical Care, Kendall Regional Medical Center, Miami, FL, USA

^b University of South Florida, Tampa, FL, USA

ARTICLE INFO

Keywords:

Bilateral femoral neck fractures
Electrical injuries
Thoracic vertebral fractures
Trauma outcomes

ABSTRACT

Introduction and importance: Low voltage electrical injuries (less than 1000 V) can produce enough tetany to cause fractures, usually of the upper extremities. Simultaneous bilateral fractures of the femoral neck are an extremely rare occurrence. It is even more uncommon for a young healthy male to suffer significant fractures from a low voltage injury.

Case presentation: A 25-year-old male attempted suicide by filling a bathtub with water and getting into it prior to dropping a blender into the water. He experienced full body convulsions but remained awake throughout the entire event. In the trauma bay his primary complaints were bilateral hip pain and back pain, without neurologic deficit. Radiological studies confirmed bilateral sub-capital femur fractures and thoracic vertebral fractures (compression fractures of T3, T4, T5, T6, T7, T9, and T11). The patient underwent bilateral open reduction and internal fixation (ORIF) of the femurs, while the spine fractures were treated with a thoracic-lumbar-sacral orthosis TLSO brace.

Clinical discussion: Low voltage electrical injury is more likely to lead to fractures in patients with chronic renal failure and metabolic conditions such as hypocalcemia, osetomalacia, and osteoporosis. Fractures after low voltage electrical injury are extremely uncommon and a high suspicion for these injuries should be maintained because if missed there is a high risk of morbidity and mortality.

Conclusion: We present a rare case of low voltage electrical injury by 120 V from a domestic US power supply, amplified by water conduction resulting in bilateral femoral neck fractures and vertebral body fractures.

1. Background

Electrical burns have been called the “grand masquerader” because even the smallest surface injuries can be associated with devastating internal injury including death. Currently in the United States electrical injury results in around 1000 deaths per year. Because of the diverse presentation, electrical injuries can confuse even the most experienced burn/trauma surgeons [1]. In our review of the literature, it was found that low voltage (<1000 V) electrical induced fractures are extremely rare, with the rarest types of fractures being vertebral and bilateral femur fractures. Bilateral fractures of the neck of the femur have been reported in 10 cases to date and vertebral body fractures have been reported in 2 cases to date [2–11]. The cause of these fractures is violent unopposed muscle contraction [12–14]. Femur fractures are rare in a

young healthy male without high velocity trauma such as a motor vehicle collision. Low velocity trauma resulting in femur fractures most commonly occur in the elderly who often have osteoporosis or some other insult to their musculoskeletal system [15]. We report a rare case of bilateral femoral neck fractures and multiple thoracic vertebral body fractures due to a low voltage electrical injury amplified by water conduction. This report aligns with the 2020 Surgical Case Report (SCARE) guidelines [16].

2. Case report

A 25-year-old male presented to our emergency department as a trauma activation. Initial evaluation began with a report from EMS stating that the patient had attempted to commit suicide with a small

* Corresponding author at: Department of Surgery, Kendall Regional Medical Center, 11750 SW 40th St, Miami, FL 33175, USA.

E-mail address: Adel.Elkbuli@hcahealthcare.com (A. Elkbuli).

<https://doi.org/10.1016/j.ijscr.2021.106066>

Received 14 May 2021; Received in revised form 29 May 2021; Accepted 2 June 2021

Available online 9 June 2021

2210-2612/© 2021 The Authors. Published by Elsevier Ltd on behalf of IJS Publishing Group Ltd. This is an open access article under the CC BY-NC-ND license

(<http://creativecommons.org/licenses/by-nc-nd/4.0/>).

electrical device (blender) dropped into the bathtub. On arrival his primary complaints were bilateral hip pain and significant back pain. He denied loss of consciousness and had memory of the event. His primary survey was unremarkable and his vital signs were in the normal range. He had good range of motion, although with pain, of the bilateral lower extremities. The bilateral lower extremities were equal in length and exhibited slight external rotation. There were no obvious deformities or visible injuries. Adjunctive plain radiographic images were obtained; including chest, pelvis and bilateral thighs, which revealed multiple thoracic vertebral fractures, (T3 through T9 and T11, and bilateral sub-capital femur fractures (Figs. 1, 2, & 3)). The patient's past medical history was significant for major depressive disorder and previous suicide attempts for which he wasn't receiving any treatment prior to presenting at our trauma center. Additional CT images of the thoracic vertebral fractures identified compression fractures of 3rd through 9th thoracic body and the 11th thoracic body. The most severe compression fracture in our patient was at T4 and is shown in Fig. 4.

Orthopedic surgery was consulted for management of the bilateral sub-capital femur fractures. The patient was taken to the operating theater the same day and underwent bilateral open reduction and

internal fixation (ORIF) of the fractures. No complications or abnormalities were reported during the surgery.

The neurosurgery spine service determined that the thoracic fractures did not require surgical intervention and the treatment plan was a thoracic-lumbar-sacral orthosis (TLSO) brace and physical therapy. The patient improved over the next week and was cleared for transfer to the behavioral health (Psychiatric) unit. After a week in the behavioral health unit, the Psychiatry team noted the patient was in good spirits without any further suicidal ideation. The patient was discharged to home with his parents. He continues to work with the physical therapy team.

3. Discussion

Low voltage electrical injuries resulting in fractures are extremely uncommon. In the current American Burn Association guidelines, it is recommended to suspect spinal fractures in high voltage injuries (>1000 V). In low voltage electrical injuries (<1000 V), fractures aren't mentioned as a consideration with the primary focus of current electrical injury management following the ATLS protocol of the trauma

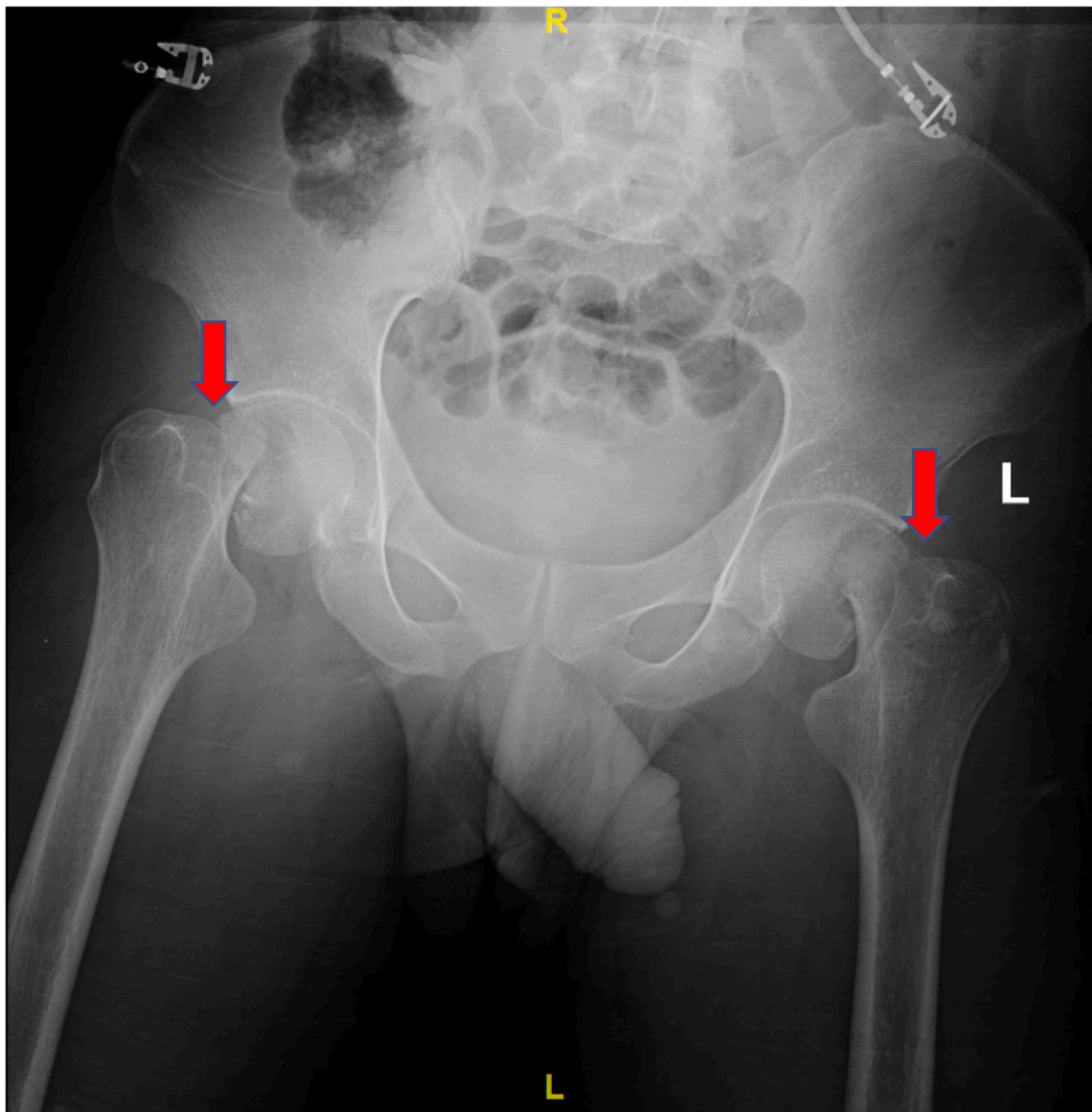


Fig. 1. Pelvis X-ray completed during primary survey: bilateral subcapital femur fractures. Arrows are marking the bilateral fractures.

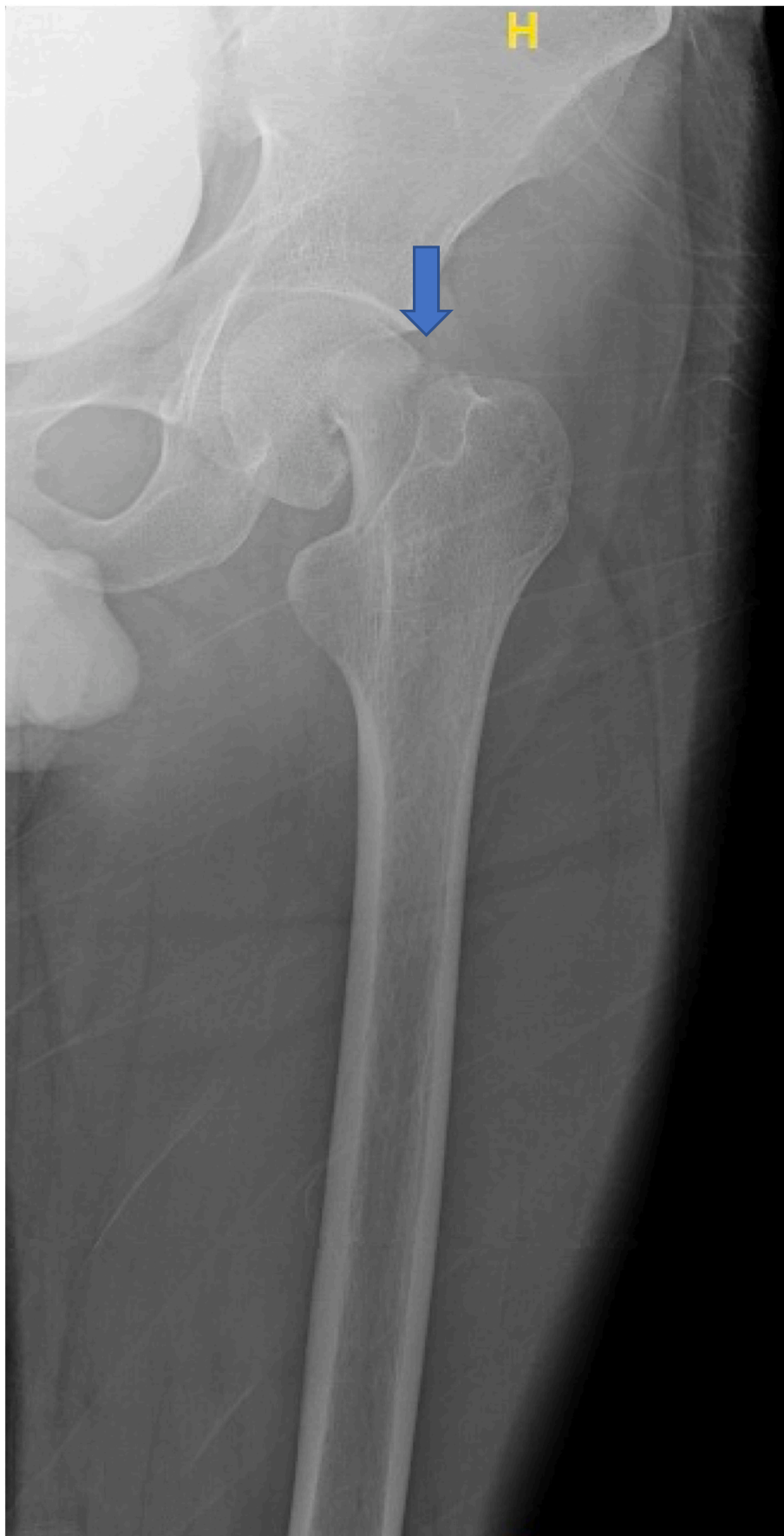

Fig. 2. Left femur X-Ray demonstrating the right femoral neck fracture. The arrow is marking the fracture.

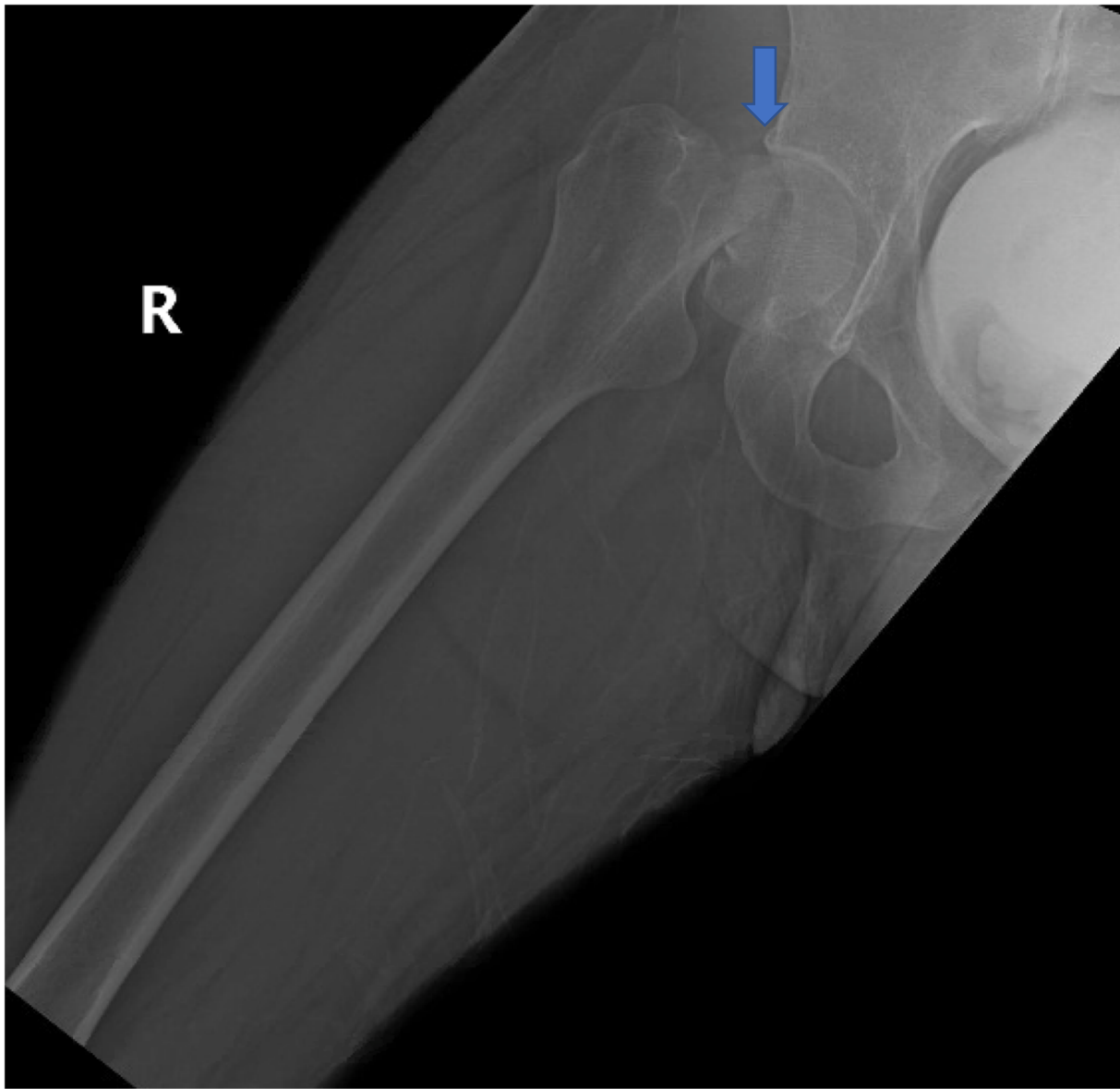


Fig. 3. Right femur X-Ray demonstrating the right femoral neck fracture. The arrow is marking the fracture.

evaluation, having an emphasis in circulation and cardiac status [1,17].

Electrical induced bilateral fractures of the neck of the femur are extremely uncommon injuries and vertebral body compression fractures are even rarer [18]. In reviewing the literature there is not a prior case of a patient reported with simultaneous bilateral fractures of the neck of the femur and multiple vertebral body fractures. Taking the types of injuries separately in our review of the literature low voltage electrical injury inducing simultaneous bilateral fractures of the neck of the femur have been reported in 10 cases to date [2–9]. While low voltage electrical injury inducing vertebral body fractures in our review of the literature have been reported in 2 cases to date with 3 additional cases if including vertebral fractures induced by conducted electrical device (CED), usually Taser®, that is commonly used by law enforcement officers [10–12,19]. The conducted electrical device that police use is commonly stated to operate at 50,000 V. However, only a maximum of 1200 V are transmitted to the target. The amount transmitted varies based on the targets clothing and how well the probes attach. Because of this variability it is hard to say whether it is a low voltage electrical injury or a high voltage electrical injury in these studies [19]. In reviewing these reports of electrical injury induced vertebral fractures,

the fractures tend to be mechanically stable without long term morbidity or neurological sequelae and exhibit high recovery rates with minimal long-term disability [20].

The likely mechanism of these fractures results from the forceful muscle contracture that occurred in the thoracic spine and in the pelvis that occur as a result of low-voltage electrically induced injury [11,21]. The severity of these injuries is believed to increase with both the intensity and duration of the muscle contraction [18]. In support of the unopposed muscle contraction leading to fractures in low voltage electrical injury, there have been multiple cases of fractures resulting from the tetany generated during tonic-clonic seizure as well as electroconvulsive therapy [12–14,21]. Overall there is a 1.1% incidence of fractures and/or dislocation following seizures with convulsions [22].

Given the severity of our patient's injuries, an examination was made into possible contributing factors associated with low voltage electrical injury and fractures. Our patient was not overtly muscular and was a relatively thin young man making extensive musculature contributing to his injuries to be unlikely. In the current literature it has been suggested that chronic renal failure and metabolic conditions such as hypocalcemia, osetomalacia, and osteoporosis are risk factors [21,23–25]. Our

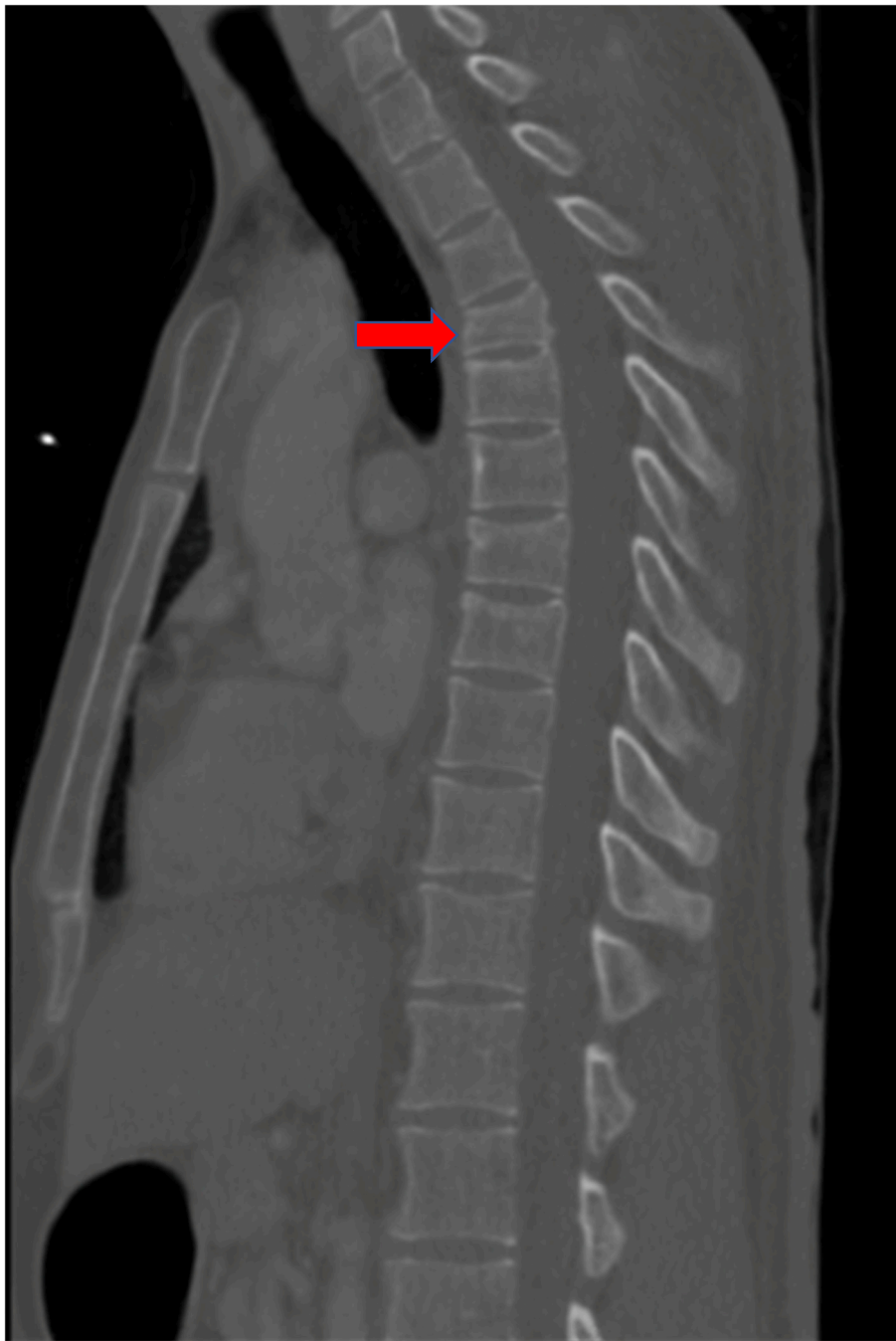

Fig. 4. CT sagittal image (Bone Window) of the Thoracic Spine Demonstrating the most significant thoracic spine fracture T4 marked by the red arrow. (For interpretation of the references to colour in this figure legend, the reader is referred to the web version of this article.)

patient did not suffer from chronic renal failure and had normal calcium levels. However, he did have low levels of serum vitamin D, which is associated with osteomalacia and osteoporosis and could have contributed to the grievous nature of the injury [25]. Vitamin D levels are currently defined into three categories: sufficiency defined as a 25(OH)D concentration greater than 20 ng/mL, insufficiency defined as a 25(OH)D concentration of 12 to 20 ng/mL and, deficiency defined as a 25(OH)D level less than 12 ng/mL [24]. Our patient was on the low end of vitamin D insufficiency with a 25(OH)D concentration of 13.6. The appearance of clinical symptoms in the setting of hypovitaminosis D depends on severity and duration of the hypovitaminosis [26]. While there have been associations of hypovitaminosis D with fractures; the asymptomatic presentation of our patient's hypovitaminosis and his young age

limiting duration of the effect of this malnutrition make it unlikely that this significantly contributed to his injuries. [27,28]

A factor that may have significantly increased our patient's risk for severe injury with a low voltage electrical injury is the environment of the bathtub and the effect of water on the skin. The intensity of an electrocution can be increased by wet skin and even by humid environment alone [29,30]. In general, different types of tissue have different levels of resistance: skin and bone are high resistant tissues and muscles and blood vessels have low resistance [1]. When skin gets wet it drastically lowers the resistance of skin permitting electricity to more easily enter the body [1,31]. Given our patient's suicide attempt taking place in a bath tub filled with water it is likely that the water could have amplified the low voltage electrical injury, thus increasing the likelihood

of significant injury.

The presentation of electrical injury can often be deceiving and confuse even the most experienced trauma/burn surgeon resulting in a delay in diagnosis [1]. The delay of diagnosis of fractures following electrical injury is often due to delayed presentation, failure to investigate more significant injury, and the difficulty in elucidating a clear history from a recently electrocuted patient; this delay in presentation can range from days to weeks [10,16,32–34].

4. Conclusion

Fractures after low voltage electrical injury are relatively uncommon and often can have a delayed diagnosis days or weeks after the initial injury. Current care for traumatic electrical injury is appropriately focused on high mortality and morbidity issues and common sequelae of the injury are cardiac injury leading to arrhythmias, myonecrosis potentially leading to renal failure, and cutaneous burns. However due to the high morbidity of a delayed diagnosis in fractures resulting from an electrical etiology, appropriate suspicious and clinical evaluation for these injuries should be maintained, especially with existed comorbid conditions and confounding factors as to the specific etiology of such injuries.

Funding

This research did not receive any specific grant from funding agencies in the public, commercial, or not-for-profit sectors.

Ethical approval

This report was conducted in compliance with ethical standards.

Informed consent

Written informed consent was obtained from the patient for publication of this case report and accompanying images. A copy of the written consent is available for review by the Editor-in-Chief of this journal on request.

Registration of research studies

Not applicable. This is a case report study.

Guarantor

Michael Renda
Mark McKenney

Provenance and peer review

Not commissioned, externally peer-reviewed.

CRedit authorship contribution statement

DR, AE, MM, MR– Conception of study, acquisition of data, analysis and interpretation of data, drafting the article, and revision of article.

MR – Management of case, revision of article, and final approval of the version to be submitted

DR, AE, MM, MR – Approval of the final version for submission.

Declaration of competing interest

The authors declare no conflicts of interest.

References

- [1] American Burn Association. (2018). Advanced Burn Life Support Course Provider Manual 2018 Update [brochure]. Chicago, Illinois: author. Retrieved April 04, 2021, from <http://ameriburn.org/wp-content/uploads/2019/08/2018-abls-providermanual.pdf>.
- [2] Atkinson RE, Kinnett G, Arnold WD. Simultaneous fractures of both femoral necks, review of the literature and report of two cases. *ClinOrthop*. 1980;152:284–7.
- [3] Gehlen JMLG, Hoofwijk AGM. Femoral neck fracture after electrical shock injury. *Eur. J. Trauma Emerg. Surg*. 2010;36:491–493.
- [4] S. Nekkanti, Js S.T. C V, Raj S. R R, An unusual case of simultaneous bilateral neck of femur fracture following electrocution injury—a case report and review of literature, *J. Orthop. Case Rep*. 6 (3) (2016) 70–72, <https://doi.org/10.13107/jocr.2250-0685.514>. Jul-Aug. (PMID: 28116275; PMCID: PMC5245945).
- [5] G.S. Tompkins, R.C. Henderson, H.D. Peterson, Bilateral simultaneous fractures of the femoral neck: a case report, *J. Trauma* 30 (11) (1990) 1415–1416.
- [6] R.R. Slater Jr., H.D. Peterson, Bilateral femoral neck fractures after electrical injury: a case report and literature review, *J. Burn Care Rehabil*. 11 (3) (1990) 240–243.
- [7] M.A. Shaheen, N.A. Sabet, Bilateral simultaneous fracture of the femoral neck following electrical shock, *Injury* 16 (1) (1984) 13–14.
- [8] H.S. Sohal, D. Goyal, Simultaneous bilateral femoral neck fractures after electrical shock injury: a case report, *Chin. J. Traumatol*. 16 (2) (2013) 126–128. PMID: 23540905.
- [9] . Nyoni L, Saunders CR, Morar AB. Bilateral fracture of the femoral neck as a direct result from electrocution shock. *Centr. Afr. J. Med.* 1994;40(12):355–6.
- [10] W.A. Van den Brink, O. van Leeuwen, Lumbar burst fracture due to low voltage shock. A case report, *Acta Orthop. Scand*. 66 (4) (1995) 374–375, <https://doi.org/10.3109/17453679508995566>. Aug. (7676831).
- [11] A. Sinha, M. Dholakia, Thoracic compression fracture caused by electrically induced injury, *PM R* 1 (8) (2009) 780–782, <https://doi.org/10.1016/j.pmrj.2009.05.011>. Aug. (19695533).
- [12] Takahashi T, Tominaga T, Shamoto H, Shimizu H, Yoshimoto T. Seizure-induced thoracic spine compression fracture: Case report. *Surg. Neurol*. 2002;58:214–216.
- [13] Mehlhorn AT, Strohm PC, Hausschildt O, Schmal H, Südkamp NP. Seizure-induced muscle force can cause lumbar spine fracture. *Acta Chir. Orthop. Traumatol. Cech*. 2007;74:202–205.
- [14] G.M. McCullen, C.C. Brown, Seizure-induced thoracic burst fractures: a case report, *Spine* 19 (1994) 77–79.
- [15] A. Reynolds, The fractured femur, *Radiol. Technol*. 84 (3) (2013) 273–291. Jan-Feb. quiz p.292-4, 23322864.
- [16] R.A. Agha, T. Franchi, C. Sohrabi, G. Mathew, for the SCARE Group, The SCARE 2020 guideline: updating consensus surgical Case REport (SCARE) guidelines, *Int. J. Surg*. 84 (2020) 226–230.
- [17] Bingham H. Electrical burns. *Clin. Plast. Surg.* 1986;13:75-85. PMID: 39560831.
- [18] N. Stone 3rd, M. Karamitopoulos, D. Edelstein, J. Hashem, J. Tucci, Bilateral distal radius fractures in a 12-year-old boy after household electrical shock: case report and literature summary, *Case Rep. Med*. (2014) (2014) 235756, <https://doi.org/10.1155/2014/235756> (Epub 2014 Jan 5. PMID: 24511315; PMCID: PMC3912817).
- [19] Kroll, Mark W., and Patrick Tchou. "How a Taser works the stun gun shocks without killing—but how safe is it? Two experts take a look." *IEEE Spectrum: Technology, Engineering, and Science News*, 30 Nov. 2007.
- [20] J.E. Winslow, W.P. Bozeman, M.C. Fortner, R.L. Alson, Thoracic compression fractures as a result of shock from a conducted energy weapon: a case report, *Ann. Emerg. Med*. 50 (5) (2007) 584–586, <https://doi.org/10.1016/j.annemergmed.2007.06.008>. Nov. (Epub 2007 Sep 10. PMID: 17826867).
- [21] H.D.W. Powell, Simultaneous bilateral fractures of the neck of the femur, *J. Bone Joint Surg. Br*. 42-B (2) (1960) 236–252.
- [22] T. Çağırnaz, C. Yapıcı, M. M. Orak, and O. Guler, "Bilateral femoral neck fractures after an epileptic attack: a case report," *Int. J. Surg. Case Rep.*, vol. 6, pp. 107 – 110, 2015.
- [23] J.C. Gerster, S.A. Charhon, P. Jaeger, et al., Bilateral fractures of the femoral neck in patients with moderate renal failure receiving fluoride for spinal osteoporosis, *Br. Med. J. (Clin. Res. Ed)* 287 (6394) (1983) 723–725.
- [24] Karapinar H, Ozedemir M, Akyol S ,et al. Spontaneous bilateral femoral neck fractures in a young adult with chronic renal failure. *ActaOrthopBelg* 2003;69(1): 82–5.
- [25] Giustina A, Adler RA, Binkley N, et al. Controversies in vitamin D: summary statement from an international conference. *J. Clin. Endocrinol. Metab*. 2019; 104: 234.
- [26] Valcour A, Blocki F, Hawkins DM, Rao SD. Effects of age and serum 25-OH-vitamin D on serum parathyroid hormone levels. *J. Clin. Endocrinol. Metab*. 2012; 97: 3989.
- [27] B.W. Hollis, Circulating 25-hydroxyvitamin D levels indicative of vitamin D sufficiency: implications for establishing a new effective dietary intake recommendation for vitamin D, *J. Nutr*. 135 (2005) 317.
- [28] A. Malabanan, I.E. Veronikis, M.F. Holick, Redefining vitamin D insufficiency, *Lancet* 351 (1998) 805.
- [29] C. Spies, R.G. Trohman, Narrative review: electrocution and life-threatening electrical injuries, *Ann. Intern. Med*. 145 (7) (2006) 531–537, <https://doi.org/10.7326/0003-4819-145-7-200610030-00011>.
- [30] Zhang P, Cai S. Study on electrocution death by low-voltage. *Forensic Sci. Int.* 1995;76(2): 115–119. doi: [https://doi.org/10.1016/0379-0738\(95\)01804-2](https://doi.org/10.1016/0379-0738(95)01804-2).
- [31] M.M. Glatstein, I. Ayalon, E. Miller, D. Scolnik, Pediatric electrical burn injuries: experience of a large tertiary care hospital and a review of electrical injury,

- Pediatr. Emerg. Care 29 (6) (2013) 737–740, <https://doi.org/10.1097/PEC.0b013e318294dd64>.
- [32] Chadha M, Balain B, Maini L, et al. Spontaneous bilateral displaced femoral neck fractures in nutritional osteomalacia- a case report. *ActaOrthopScand* 2001;72(1): 94–6.
- [33] A. H. C. Tan, “Missed posterior fracture-dislocation of the humeral head following an electrocution injury to the arm,” *Singapore Med. J.*, vol. 46, no. 4, pp. 189–192, 2005.
- [34] J. P. Simon, I. Van Delm, and G. Fabry, “Comminuted fracture of the scapula following electric shock. A case report,” *Acta Orthop. Belg.*, vol. 57, no. 4, pp. 459–460, 1991.