

[CASE REPORT]

Graves' Disease after Adrenalectomy for Cushing's Syndrome

Yuji Hiromatsu^{1,2}, Hiroyuki Eguchi², Yui Nakamura² and Kei Mukohara³

Abstract:

A 44-year-old woman presented with a 3-month history of back pain, gait disturbance, and insomnia. She had moon face and central obesity but no goiter. Cushing's syndrome due to left adrenal adenoma was diagnosed. She also had low triiodothyronine syndrome and central hypothyroidism. Treatment involved adrenalectomy followed by 30 mg/day of hydrocortisone. Inappropriate secretion of thyroid-stimulating hormone occurred postoperatively. She developed Graves' disease nine months postoperatively and was treated with methimazole. Excess glucocorticoids followed by their withdrawal may influence the hypothalamic-pituitary-thyroid axis and immune system. Therefore, a careful evaluation of the thyroid function and antibodies is important after surgery for Cushing's syndrome.

Key words: Cushing's syndrome, Graves' disease, central hypothyroidism, syndrome of inappropriate secretion of thyroid-stimulating hormone

(Intern Med 60: 99-103, 2021)

(DOI: 10.2169/internalmedicine.4469-20)

Introduction

Cushing's syndrome is a disorder caused by chronic glucocorticoid excess, resulting in various symptoms, such as moon face, central obesity, a "buffalo hump," red striae, and fatigue (1). The excess glucocorticoid affects the hypothalamic-pituitary-thyroid axis and results in central hypothyroidism and low triiodothyronine (T3) syndrome (2, 3). The excess glucocorticoid also suppresses the immune system (4). Rapid withdrawal of glucocorticoid sometimes causes steroid withdrawal syndrome (SWS) and syndrome of inappropriate secretion of thyroid-stimulating hormone (SITSH) despite treatment with physiological doses of hydrocortisone (5, 6). The resolution of hypercortisolism may also trigger the development of autoimmune disorders, including autoimmune thyroid diseases (1, 7-14).

We herein report a case of Graves' disease after unilateral adrenalectomy for Cushing's syndrome.

Case Report

A 44-year-old woman presented to our hospital with a 3-month history of back pain, gait disturbance, insomnia, and depression. She had moon face, central obesity, hypertrichosis, and pitting edema on her legs and feet. She also had a 2-year history of hypertension. The patient had no family history of thyroid disease or other autoimmune diseases.

Her height was 172.7 cm, and her body weight was 71.5 kg. Her blood pressure was 132/107 mmHg. No goiter, exophthalmos, Graefe's sign, or Dalrymple's sign was present. Laboratory tests showed leukocytosis [white blood cell count, 10,900 cells/mL (neutrophils, 82.5%; eosinophils, 0.5%)] and hypokalemia (potassium, 3.4 mmol/L). Her serum free thyroxine (FT4) level was normal (0.82 ng/dL; reference range, 0.76-1.65 ng/dL), but her thyroid-stimulating hormone (TSH) level (0.377 IU/mL; reference range, 0.541-4.261 IU/mL) and free T3 (FT3) level (1.65 pg/mL; reference range, 2.39-4.06 pg/mL) were low. Her plasma adrenocorticotropic hormone (ACTH) level (<2.0 pg/mL; reference

¹Thyroid Center, Shin Koga Hospital, Japan, ²Division of Endocrinology and Metabolism, Department of Medicine, Kurume University Medical Center, Japan and ³Department of General and Family Medicine, Kurume University Medical Center, Japan

Received: January 14, 2020; Accepted: June 21, 2020; Advance Publication by J-STAGE: September 5, 2020

Correspondence to Dr. Yuji Hiromatsu, yuji@med.kurume-u.ac.jp

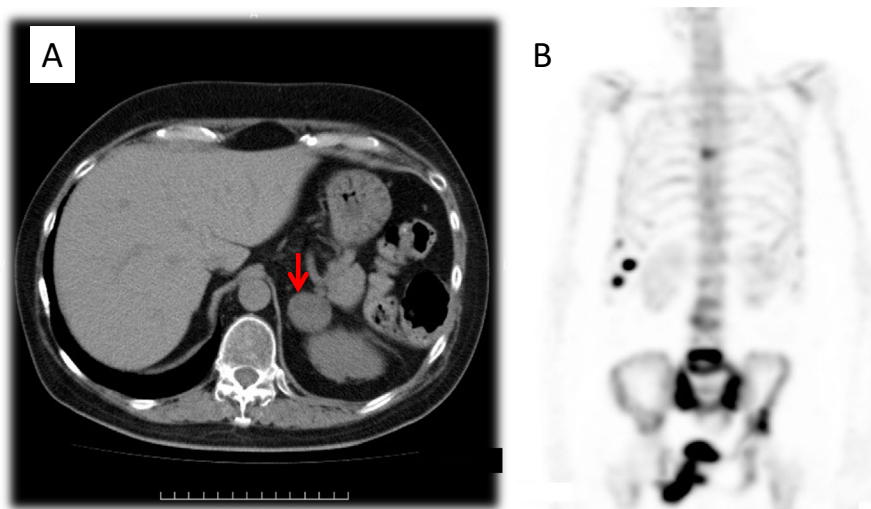


Figure 1. Computed tomography (CT) and whole-body ^{99m}Tc -methylene diphosphonate bone scintigraphy. (A) CT revealed a 30-mm left adrenal tumor (arrow). (B) A bone scan showed a significant abnormal isotope uptake in multiple ribs and vertebrae, the sacroiliac joints, and the right ileum.

range, 7.2-63.3 pg/mL) was suppressed, and her plasma cortisol level (17.2 $\mu\text{g/dL}$; reference range, 6.24-18.0 $\mu\text{g/dL}$) and 24-h urinary free cortisol level (967 $\mu\text{g/day}$) were elevated. Loss of diurnal variation of plasma ACTH and cortisol was observed. The oral administration of 1 mg of dexamethasone at 11:00 PM did not suppress the plasma cortisol level at 8:00 AM the following morning (17.9 $\mu\text{g/dL}$).

Computed tomography revealed a 30-mm tumor in the left adrenal gland (Fig. 1A). Magnetic resonance imaging did not show a pituitary tumor. ^{99m}Tc -methylene diphosphonate (MDP) scintigraphy indicated multiple fractures in the seventh to ninth right ribs, fourth and fifth lumbar vertebrae, bilateral sacroiliac joints, and left ilium (Fig. 1B). The patient was diagnosed with Cushing's syndrome due to a left adrenal adenoma. She also had low T3 syndrome and central hypothyroidism.

Unilateral adrenalectomy was performed 5 months after the first visit to our hospital, and oral hydrocortisone was administered at 30 mg/day after surgery. She had general malaise and hypotension for 3 months despite medication with 30 mg/day hydrocortisone. Five months after surgery, the dose of hydrocortisone was reduced to 20 mg/day. Inappropriate secretion of TSH had been observed from 1 month after surgery (FT3, 4.16 pg/mL; TSH, 0.575 IU/mL) to 7 months after surgery (FT3, 4.12 pg/mL; TSH, 1.361 IU/mL).

The patient developed tachycardia and diffuse goiter 9 months after the adrenalectomy and was diagnosed with Graves' disease [FT3, 10.27 pg/mL; FT4, 3.16 ng/dL; TSH, <0.003 IU/mL; anti-thyroglobulin antibody, 1,063.2 IU/mL (reference range, <40.6 IU/mL); anti-thyroid peroxidase antibody, 225.5 IU/mL (reference range, <9.4 IU/mL); anti-TSH receptor antibody (third-generation TRAb electrochemiluminescence immunoassay), 7.4 IU/L (reference range, <2.0 IU/L); and thyroid-stimulating antibody (TSAb Bioassay Enzyme Immunoassay; Yamasa, Choshi, Japan),

1,196% (reference range, <120%)]. Ultrasonography showed the diffuse enlargement of her thyroid glands with increased blood flow.

She was started on oral methimazole at 15 mg/day. She remained euthyroid on oral methimazole at 5 mg/day for 15 months after adrenalectomy. The serum thyroid-stimulating antibody level gradually decreased to 216% 17 months after adrenalectomy and 149% 23 months after surgery (Fig. 2).

Discussion

Excess glucocorticoid followed by its withdrawal may influence the hypothalamic-pituitary-thyroid axis and immune system (1-14). In our case, low T3 syndrome and TSH suppression were present before adrenalectomy. The patient developed SITSH one month after surgery and Graves' disease nine months after adrenalectomy.

The serum TSH level is suppressed in patients with Cushing's syndrome. Hypercortisolemia decreases the TSH pulse amplitude and nocturnal surge (15, 16) and suppresses TSH secretion through the suppression of the thyrotropin-releasing hormone gene expression (17) or through the direct suppression of TSH secretion via leptin, dopamine, annexin 1, and somatostatin (18-21). Increased activity of type II deiodinase by glucocorticoids also causes increased local T3 levels, eventually leading to suppression of thyrotropin-releasing hormone and TSH secretion (6, 22).

Although the FT4 level was within the reference range in our case, central hypothyroidism with a reduced T4 level is sometimes present in patients with Cushing's syndrome. The prevalence of central hypothyroidism ranges from 18% to 26% (2, 23).

In our patient, SWS was observed after adrenalectomy despite supplementation with oral hydrocortisone at 30 mg/day. She also complained of anorexia and fatigue. Her serum TSH and FT3 levels were higher than the upper limit of

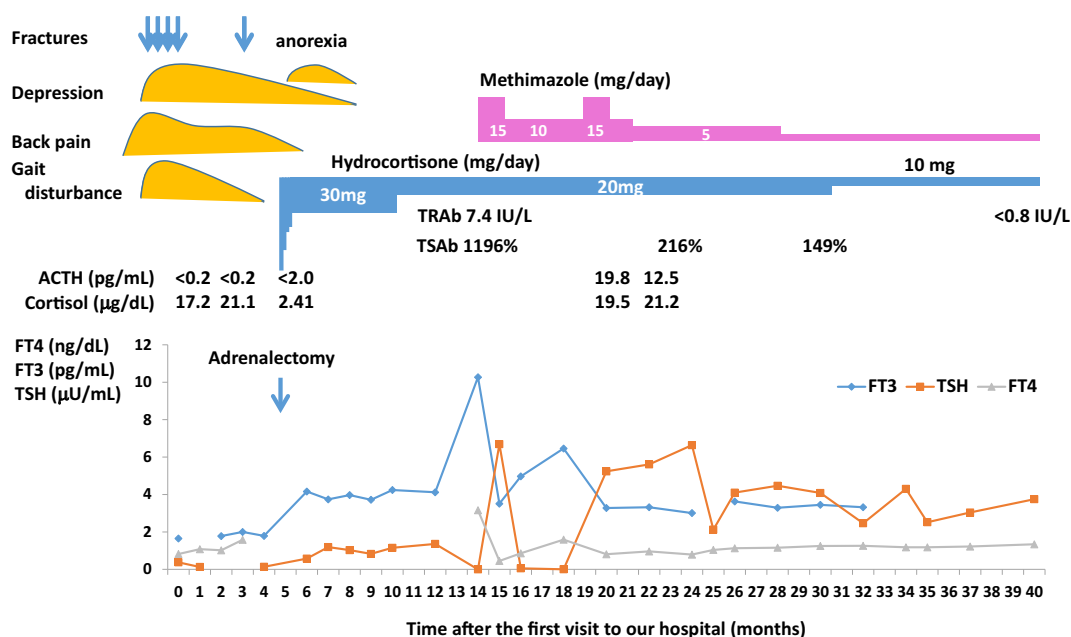


Figure 2. Clinical course. FT3: free triiodothyronine, FT4: free thyroxine, TSH: thyroid-stimulating hormone, TRAb: anti-TSH receptor antibody, TSAb: thyroid-stimulating antibody

Table. Previous Reports on Exacerbation or Development of Graves' Disease after Adrenalectomy for Cushing's Syndrome.

Reference	Sex	Age	Time of presentation of Graves' disease after surgery	TSH receptor antibody and iodine uptake	Prevalence of Graves' disease	Treatment used
27	-	-	3 M, 14 M, 18 M, 100 M, -20 Y	-	8.5% (5/59)	
28	Male	49	80 D	TRAb-, TSAb- positive	-	Remission without treatment
29	Female	50	9 M	TRAb 30 IU/L, I uptake 31% at 2 hr	-	PTU
24	Female	58	27 M	TRAb 9.8 IU/L, I uptake 37.8% at 24 hr	1.5% (1/66)	MMI
25	Female	15	12 M	-	0.8% (1/127)	
present study	Female	44	9 M	TRAb 7.4 IU/L, TSAb 1196%	-	MMI

TSH: thyroid-stimulating hormone, D: days, M: months, Y: years, TRAb: anti-TSH receptor antibody, TSAb: thyroid-stimulating antibody, PTU: propylthiouracil, MMI: methimazole

normal, which indicated SITSH. A recent report described SITSH as a clinical condition with the presence of normal or elevated TSH secretion despite inappropriately high levels of thyroid hormones in patients who receive insufficient hydrocortisone replacement following surgery for Cushing's syndrome (6). Because the symptoms of hyperthyroidism due to SITSH overlap with those of SWS, SITSH is considered the main cause of SWS (23). Tamada et al. (6) reported that SITSH was detected in the first month of follow-up when the daily hydrocortisone replacement doses were <20 mg. SITSH was present in 75% of patients with Cushing's syndrome up to 6 months after surgery and disappeared by 12 months after surgery (6). In contrast, Dogansen et al. (2) failed to detect SITSH in the early postoperative period with

their prednisolone replacement doses.

Several reports have described the exacerbation or development of autoimmune disorders, including thyroid diseases, after surgery for Cushing's syndrome (7-14). Although the pathogenesis underlying the exacerbation of autoimmune thyroid disease is not well known, rebound immunity and activation of latent autoimmune thyroid disease have been postulated. In previous studies, the prevalence of autoimmune dysfunction after surgery for Cushing's syndrome was 16.7% in adults (24) and 7.8% in children (25). The prevalence of autoimmune thyroid disease after surgery for Cushing's syndrome reportedly ranges from 10% to 35% (9, 13, 26). Colao et al. (14) reported an increased prevalence of positive thyroglobulin and thyroid peroxidase

antibody titers in patients after Cushing's syndrome remission than during active Cushing's syndrome (60% vs. 20%). Niepomniszcze et al. (27) reported that thyroid autoimmunity was detected in 21.7% of patients at the time of diagnosis of Cushing's syndrome and in 65.2% of patients after remission of hypercortisolism. Several case reports have described Graves' disease after surgery for Cushing's syndrome (24, 25, 27-29), reporting prevalence rates of 0.8% to 8.5% (Table). Most patients developed autoimmune thyroid disorders 7 to 10 months after surgery. Graves' disease developed 3 to 100 months after surgery for Cushing's syndrome. Therefore, physicians need to be aware of this possible outcome.

It is reasonable to hypothesize that predisposed patients are protected from autoimmune attack by immunologic tolerance related to steroid excess and overt thyroid dysfunction that develops after the decline in glucocorticoid concentration (9). However, the possibility of other mechanisms precipitating the occurrence of the disease, such as iodine excess, cannot be ruled out. The present case had SITSH for a six-month period until two months before the diagnosis of Graves' disease, although the role of SITSH in the development of Graves' disease is unclear.

In conclusion, this study suggests that the thyroid function and antibody tests should be carefully evaluated before and after surgery for Cushing's syndrome.

The authors state that they have no Conflict of Interest (COI).

Acknowledgement

We thank Angela Morben, DVM, ELS for editing a draft of this manuscript.

References

- Pivonello R, Isidori AM, De Martino MC, Newell-Price J, Biller BM, Colao A. Complications of Cushing's syndrome: state of the art. *Lancet Diabetes Endocrinol* **4**: 611-629, 2016.
- Dogansen SC, Yalin GY, Canbaz B, Tanrikulu S, Yarman S. Dynamic changes of central thyroid functions in the management of Cushing's syndrome. *Arch Endocrinol Metab* **62**: 164-171, 2018.
- Tamada D, Kitamura T, Onodera T, Hamasaki T, Otsuki M, Shimomura I. Clinical significance of fluctuations in thyroid hormones aftersurgery for Cushing's syndrome. *Endocr J* **62**: 805-810, 2015.
- Oppong E, Cato AC. Effects of glucocorticoids in the immune system. *Adv Exp Med Biol* **872**: 217-233, 2015.
- Bhattacharyya A, Kaushal K, Tymms DJ, Davis JR. Steroid withdrawal syndrome after successful treatment of Cushing's syndrome: a reminder. *Eur J Endocrinol* **153**: 207-210, 2005.
- Tamada D, Onodera T, Kitamura T, et al. Hyperthyroidism due to thyroid-stimulating hormone secretion after surgery for Cushing's syndrome: a novel cause of the syndrome of inappropriate secretion of thyroid-stimulating hormone. *J Clin Endocrinol Metab* **98**: 2656-2662, 2013.
- Uthman I, Senecal JL. Onset of rheumatoid arthritis after surgical treatment of Cushing's disease. *J Rheumatol* **22**: 1964-1966, 1955.
- Noguchi Y, Tamai H, Fujisawa K, et al. Systemic lupus erythematosus after pituitary adenomectomy in a patient with Cushing's disease. *Clin Endocrinol* **48**: 670-672, 1998.
- Haraguchi K, Hiramatsu K, Onaya T. Transient thyrotoxicosis after unilateral adrenalectomy in two patients with Cushing's syndrome. *Endocrinol Jpn* **31**: 577-582, 1984.
- Takasu N, Komiya I, Nagasawa Y, Asawa T, Yamada T. Exacerbation of autoimmune thyroid dysfunction after unilateral adrenalectomy in patients with Cushing's syndrome due to an adrenocortical adenoma. *N Engl J Med* **322**: 1708-1712, 1990.
- Colombo P, Passini E, Ambrosi B. Autoimmune thyroid disease after successful treatment of Cushing's syndrome. *J Endocrinol Invest* **17**: 289-290, 1994.
- Cioni K, Pantaleoni M, Toschi E, Frank G, Marrama P, Velardo A. Exacerbation of autoimmune hypothyroidism after hemi-hypophysectomy in a patient with Cushing's disease. *Minerva Endocrinol* **18**: 139-141, 1993.
- Yamakita N, Sakata S, Hayashi H, Maekawa H, Miura K. Case report: silent thyroiditis after adrenalectomy in a patient with Cushing's syndrome. *Am J Med Sci* **305**: 304-306, 1993.
- Colao A, Pivonello R, Faggiano A, et al. Increased prevalence of thyroid autoimmunity in patients successfully treated for Cushing's disease. *Clin Endocrinol* **53**: 13-19, 2000.
- Adriaanse R, Brabant G, Ender E, Wiersinga WM. Pulsatile thyrotropin secretion in patients with Cushing's syndrome. *Metabolism* **43**: 782-786, 1994.
- Bartalena L, Martino E, Petrini L, et al. The nocturnal serum thyrotropin surge is abolished in patients with adrenocorticotropin (ACTH)-dependent or ACTH-independent Cushing's syndrome. *J Clin Endocrinol Metab* **72**: 1195-1199, 1991.
- Alkemade A, Unmehopa UA, Wiersinga WM, Swaab DF, Fliers E. Glucocorticoids decrease thyrotropin-releasing hormone messenger ribonucleic acid expression in the paraventricular nucleus of the human hypothalamus. *J Clin Endocrinol Metab* **90**: 323-327, 2005.
- Saane LM, Carro E, Tovar S, Casanueva FF, Dieguez C. Regulation of in vivo TSH secretion by leptin. *Regul Pept* **92**: 25-29, 2000.
- Lewis BM, Dieguez C, Lewis MD, Scanlon MF. Dopamine stimulates release of thyrotropin-releasing hormone from perfused intact rat hypothalamus via hypothalamic D2-receptors. *J Endocrinol* **115**: 419-424, 1987.
- Taylor AD, Flower RJ, Buckingham JC. Dexamethasone inhibits the release of TSH from the rat anterior pituitary gland in vitro mechanisms dependent on de novo protein synthesis and lipocortin 1. *J Endocrinol* **147**: 533-544, 1995.
- Estupina C, Belmar J, Tapia-Arancibia L, Astier H, Arancibia S. Rapid and opposite effects of dexamethasone on in vivo and in vitro hypothalamic somatostatin release. *Exp Brain Res* **113**: 337-342, 1997.
- St Germain DL, Galton VA, Hernandez A. Minireview: defining the roles of the iodothyronine deiodinase: current concepts and challenges. *Endocrinol* **150**: 1097-1107, 2009.
- Mathioudakis N, Thapa S, Wand GS, Salvatori R. CTH-secreting pituitary microadenomas are associated with a higher prevalence of central hypothyroidism compared to other microadenoma types. *Clin Endocrinol (Oxf)* **77**: 871-876, 2012.
- da Mota F, Murray C, Ezzat S. Overt immune dysfunction after Cushing's syndrome remission: a consecutive case series and review of the literature. *J Clin Endocrinol Metab* **96**: E1670-E1674, 2011.
- Tatsi C, Keil M, Lyssikatos C, Belyavskaya E, Stratakis CA, Lodish MB. Incidence of autoimmune and related disorders after resolution of endogenous Cushing syndrome in children. *Horm Metab Res* **50**: 290-295, 2018.
- Takasu N, Ohara N, Yamada T, Komiya I. Development of autoimmune thyroid dysfunction after bilateral adrenalectomy in a patient with Carney's complex and after removal of ACTH-producing pituitary adenoma in a patient with Cushing's disease. *J Endocrinol Invest* **16**: 697-702, 1993.
- Niepomniszcze H, Pitoia F, Katz SB, Chervin R, Bruno OD. Pri-

- mary thyroid disorders in endogenous Cushing's syndrome. *Eur J Endocrinol* **147**: 305-311, 2002.
28. Morita H, Isaji M, Mune T, et al. Transient Graves disease developing after surgery for Cushing disease. *Am J Med Sci* **323**: 162-165, 2002.
29. Arıkan E, Guldiken S, Altun BU, Kara M, Tugrul A. Exacerbations of Graves' disease after unilateral adrenalectomy for Cushing's syndrome. *J Endocrinol Invest* **27**: 574-576, 2004.

The Internal Medicine is an Open Access journal distributed under the Creative Commons Attribution-NonCommercial-NoDerivatives 4.0 International License. To view the details of this license, please visit (<https://creativecommons.org/licenses/by-nc-nd/4.0/>).

© 2021 The Japanese Society of Internal Medicine
Intern Med 60: 99-103, 2021