

➤ **Case Report** ◀

Bilateral External Iliac Artery Dissection in a Middle-Aged Male Athlete

Yasushi Yamanaka, MD,¹ Tetsuya Yoshida, MD, PhD,² and Eiki Nagaoka, MD, PhD³

We present the case of a bilateral external iliac artery (EIA) dissection in a 44-year-old male athlete. The patient was referred to our department for right lower abdominal pain without claudication during single squatting. His athletic history included participation in approximately five athletic events per year. Contrast-enhanced computed tomography (CT) revealed bilateral EIA dissection and right renal infarction. Following medical treatment for his hypertension and considering his medical history, a bilateral EIA replacement with 8-mm Dacron straight grafts was performed on the 24th day after hospital admission. Postoperative contrast-enhanced CT revealed good bilateral graft patency and perfusion following surgery.

Keywords: bilateral external iliac artery dissection, open surgery

Introduction

Spontaneous bilateral external iliac artery (EIA) dissection is rare. Only a few case reports have been published, and some cases in middle-aged athletes have been reported. Optimal treatments include conservative medication, open surgery, and endovascular treatment.^{1–6} We report a case of bilateral EIA dissection in a middle-aged male athlete. On the basis of the patient's history, we decided to perform open surgery; the operation was successful.

Case Report

A 44-year-old male was referred to our department for

right lower abdominal pain without claudication during single squatting. He reported that he smoked cigarettes for 25 years and had a history of untreated hypertension and hyperlipidemia. There was no familial history of fibromuscular dysplasia. He had participated in approximately five athletic events, such as marathons and triathlons every year since he was in high school. Therefore, he had a habit of swimming, cycling, and running for long distances at least twice a week until he had to discontinue the physical activities owing to the development of pain symptoms. On medical examination, bruit was detected bilaterally on his lower abdomen, and spontaneous pain and tenderness were detected in the right lower abdomen. Costovertebral angle tenderness was positive on the right side. Pulsations of the lower limb arteries were palpable. Contrast-enhanced computed tomography (CT) revealed bilateral EIA dissection with patent false lumens and right renal infarction. The aneurysm of the right EIA was 21 mm in diameter and that of the left EIA was 15 mm in diameter (Fig. 1). The patient's white blood cell count was $10.8 \times 10^3/\mu\text{L}$, and D-dimer concentration was 1.1 $\mu\text{g/dL}$. Serum total and low-density lipoprotein cholesterol levels were 271 mg/dL and 176 mg/dL, respectively. Urine occult blood test was positive. Electrocardiogram did not document atrial fibrillation; transthoracic echocardiogram detected no remarkable findings. Ankle-brachial indices (ABIs) were 0.93 on the right side and 1.01 on the left side. No claudication was documented before or after hospital admission, and we chose conservative treatments, including antihypertensive therapy. After the symptoms had disappeared following blood pressure management, a rehabilitation program based on type B aortic dissection was initiated. During the rehabilitation program, the patient had neither symptoms nor claudication. During a discussion prior to discharge, the patient revealed that he wished to continue participating in athletic events; therefore, we decided to perform a bilateral vascular prosthesis replacement on the 24th day following the hospital admission. This decision was made considering the patient's age, his wish to continue participating in athletic events, the estimated risk of rupture after vigorous exercises following conservative treatments, and the limited number of approved devices available for endovascular treatment

¹The Department of Surgery, Suwa Central Hospital, Nagano, Japan

²The Department of Cardiovascular Surgery, Hokushin General Hospital, Nagano, Japan

³Division of Cardiac Surgery, London Health Science Centre, Ontario, Canada

Received: July 5, 2017; Accepted: September 5, 2017
Corresponding author: Yasushi Yamanaka, MD. The Department of Surgery, Suwa Central Hospital, 4300 Tamagawa, Chino, Nagano 391-8503, Japan
Tel: +81-266-72-1000, Fax: +81-266-72-4120
E-mail: into_mt@yahoo.co.jp



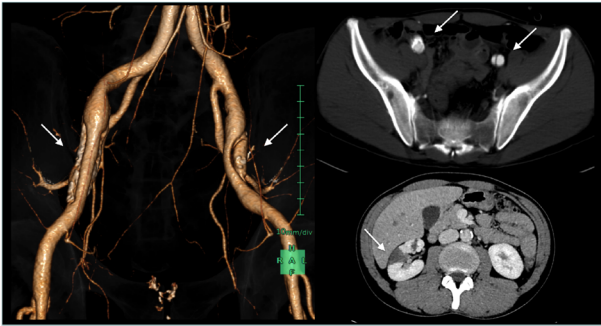


Fig. 1 Preoperative contrast-enhanced CT findings. **A, B:** Bilateral EIA dissection (arrows). (left side/upper right side). **C:** Right renal infarction (arrow). (lower right side).

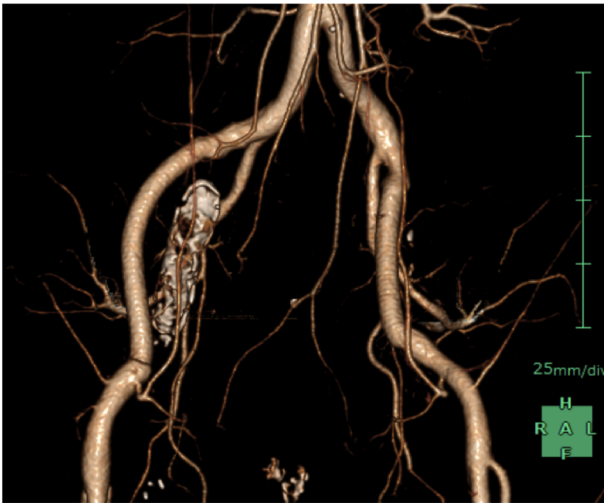


Fig. 2 Postoperative contrast-enhanced CT showing good graft patency and no anastomotic leakage.

at that time.

Under general anesthesia, we approached the retroperitoneum with bilateral pararectal incisions and reached the EIAs with aneurysms. After heparinization, cross-clamps were applied to the EIAs, and the aneurysms were incised. We found bilateral antegrade EIA dissections with intimal entry/distal reentry tears and false lumens. The false lumens were 70-mm long in the right EIA and 45-mm long in the left EIA. We replaced these with 8-mm Dacron straight grafts (Hemashield Platinum Woven Double Velour Vascular Graft, MAQUET Cardiovascular LLC, Wayne, NJ, USA). Pathological findings included bilateral intima-media dissections with severe loss of elastic tissue. The patient restarted his rehabilitation program on postoperative day (POD) 1. Contrast-enhanced CT on POD 7 revealed good bilateral graft patency and perfusion (Fig. 2). ABIs were 1.04 on the right side and 1.08 on the left side. After satisfactory rehabilitation, the patient was discharged on POD 16. The follow-up visits every three months indicated no claudication. Forty-five months since

the surgery and no complications have been observed so far, and the ABIs were 1.03 on the right side and 0.98 on the left. He gradually restarted his physical training 12 months after the surgery and currently participates in athletic events about twice a year.

Discussion

Spontaneous EIA dissection is a rare event, and spontaneous bilateral EIA dissection is even rarer. There have been few reports of spontaneous EIA dissection in athletes or workers; the prevalence is highest among cyclists.¹⁻³⁾ Cases in runners,¹⁾ golf swing trainers,⁴⁾ and blue collar workers⁵⁾ have also been reported. EIA dissection in athletes are considered to be caused by the following mechanisms.^{1,4-6)} During exercise, the cardiac output increases above 30L/min, and systolic blood pressure increases over 200 mmHg; therefore, the blood flow of the lower limbs increases by 12 times as much as it does in the resting position. In a hyper-dynamic state, joint motions or cardiac strokes cause turbulent blood flow at the curvature or bifurcation of the arteries by exerting shear stress on the arterial walls. Repetition of shear stress causes the development of intimal tears, plaque formation, and fibrosis of the arterial walls. In addition, the hip-flexed position assumed during squatting or competitive cycling and the thickened iliopsoas muscles of well-trained athletes lead to a stronger EIA curvature^{1,3)} that was less apparent in our CT examination (Fig. 1). Thus, middle-aged cyclists with a long history of training are expected to have a high risk of EIA dissection; this theory is compatible with the present case. Arteriosclerosis may be a strong risk factor for EIA dissection, although EIA dissection has also been reported in some patients without arteriosclerosis.^{1,5-7)} To our knowledge, no previous studies have reported cases associated with renal infarctions. However, in the present case, the existence of arteriosclerosis, untreated hypertension, hyperlipidemia, and the repetition of shear stress on the arterial walls caused right renal infarction.

Therapeutic options for EIA dissection are conservative medications, open surgery, and endovascular treatment; the optimal treatment from among these is yet to be established. The reported treatments for EIA dissection are shown in Table 1. Patient history is a critical consideration for determining the treatment approach. Although conservative medications are suitable for patients without symptoms, frequent hospital visits are essential. However, according to previous reports, several patients have been unable to resume participation in athletic events because they could not recover their previous exercise tolerance.^{1,4)} Open surgery is suitable for patients with a strong desire to participate in athletic events because several patients have recovered sufficient exercise tolerance.³⁾ However,

Table 1 Reported cases of spontaneous external iliac artery dissection

Author (year)	Age (years)	Sex	Etiology	Symptoms	Treatment (stent)	Outcome
Cook (1995)	50	Male	Rowing	Claudication	Conservative	Partially cured
Yoong (2015)	46	Male	Golf swings	Lower limb pain and numbness	Conservative	Partially cured
Cook (1995)	45	Male	Triathlon	Claudication	Open surgery	Cured
Engin (2005)	41	Male	No exercise	Lower limb pain	Open surgery	Cured
Fukui (2007)	49	Male	Cycling	Claudication	Open surgery	Cured
Wilson (2010)	47	Male	Cycling	Lower limb pain and cramping	Open surgery	Cured
Sedivy (2011)	41	Male	Roofing	Lower limb pain	Open surgery	Cured
Cook (1995)	50	Female	Running	Claudication	EVT (BMS)	Cured
Hirai (2002)	36	Male	No exercise	Claudication	EVT (BMS)	Cured
Teh (2003)	60	Male	Cycling	Claudication	EVT (BMS)	Partially cured
Yoshida (2017)	47	Male	No exercise	Claudication	EVT (ePTFE-covered stent)	Cured
Present case	44	Male	Squatting	Lower abdominal pain	Open surgery	Cured

EVT: endovascular therapy; BMS: bare metal stent; ePTFE-covered stent: expanded polytetrafluoroethylene-covered stent

the risk of complications such as infections, incisional hernia, or flank bulge persists.

Endovascular treatment has an advantage over open surgery in terms of minimal invasiveness, potentially making it preferable to athletes. As shown in Table 1, four patients were treated using endovascular treatment, three using bare metal stents (BMS),^{1,2,8)} and one using an expanded polytetrafluoroethylene (ePTFE)-covered stent.⁹⁾ Considering the aforementioned anatomical features of EIA,^{1-5,8)} the long-term patency and risk of stent kinking or fracture should be considered. Calligaro et al.¹⁰⁾ revealed that ePTFE-covered stents used in iliac arteries yielded a 2-year primary patency rate of 93.8% and an assisted primary patency rate of 100% without evidence of stenosis or kinking in the graft. Even in cases of popliteal arteries that appear more flexible than EIAs, the 3-year primary patency rate was greater than 80%. Although the long-term patency under vigorous exercises should be considered when treating athletes, these findings provide evidence regarding the safe use of covered stents in EIAs. The absence of an approved covered stent for EIA in Japan proved to be a practical challenge when we were considering the treatment options in our case. Even today, the use of covered stents for EIA is only partially permitted for special use such as urgent hemostasis for arterial injuries in Japan. However, once the use of covered stents in EIA is approved, endovascular treatment will be a suitable option for treating EIA dissections.

Conclusion

We have reported a case of bilateral EIA dissection in a middle-aged male athlete. After conservative treatment, we successfully performed bilateral vascular prosthesis replacement. At the 45-month follow-up, the patient had no complications and has resumed participation in athletic events.

Disclosure Statement

All authors have no conflict of interest.

Author Contributions

Writing: YY

Critical review and revision: all authors

Final approval of the article: all authors

Accountability for all aspects of the work: all authors

References

- 1) Cook PS, Erdoes LS, Selzer PM, et al. Dissection of the external iliac artery in highly trained athletes. *J Vasc Surg* 1995; **22**: 173-7.
- 2) Teh LG, Sieunarine K, Van Schie G, et al. Spontaneous common iliac artery dissection after exercise. *J Endovasc Ther* 2003; **10**: 163-6.
- 3) Willson TD, Revesz E, Podbielski FJ, et al. External iliac artery dissection secondary to endofibrosis in a cyclist. *J Vasc Surg* 2010; **52**: 219-21.
- 4) Yoong S, Heyes G, Davison GW, et al. Spontaneous dissection of the external iliac artery secondary to golf club manufacturing. *Vasc Endovascular Surg* 2013; **47**: 73-5.
- 5) Sedivy P, El Samman K, Slais M, et al. A spontaneous isolated dissection of the external iliac artery in a roofer. *Bratisl Lek Listy* 2011; **112**: 407-9.
- 6) Fukui S, Chelbi E, Paraskevas N, et al. Bilateral dissection of external iliac artery. *Ann Vasc Surg* 2007; **21**: 373-5.
- 7) Engin C, Calkavur T, Apaydin AZ, et al. Bilateral spontaneous and isolated dissection of the external iliac arteries: report of a case. *EJVES Extra* 2005; **9**: 19-21.
- 8) Hirai S, Hamanaka Y, Mitsui N, et al. Spontaneous and isolated dissection of the external iliac artery: a case report. *Ann Thorac Cardiovasc Surg* 2002; **8**: 180-2.
- 9) Yoshida RA, Kolvenbach R, Vieira PRB, et al. Endovascular treatment of spontaneous isolated common and external iliac artery dissections with preservation of pelvic blood flow. *Ann Vasc Surg* 2015; **29**: 126.e9-14.
- 10) Calligaro KD, Balraj P, Moudgill N, et al. Results of polytetrafluoroethylene-covered nitinol stents crossing the inguinal ligament. *J Vasc Surg* 2013; **57**: 421-6.