

Case Report

ALK Negative Inflammatory Myofibroblastic Tumor Synchronous with Classical Hodgkin Lymphoma

Letícia Sandoval^a Marcos Vinícius França^b Daniel Sanmartino^c
Flávia Zattar Piazero^d

^aUniversity of Brasília, Medical Department, University Hospital of Brasília, Brasília, Brazil;

^bOncology treatment centre Cettro, Clinical oncology, Cettro, Brasília, Brazil; ^cBreath Clinic, Thoracic Surgery, Hospital Breath Clinic, Brasília, Brazil; ^dUniversity of Brasília, Medical department, University Hospital of Brasília, Brasília, Brazil

Keywords

Inflammatory myofibroblastic tumor · Hodgkin lymphoma · Synchronous tumors

Abstract

Inflammatory myofibroblastic tumor or inflammatory pseudotumor was first described by Brunn in 1932. Umiker et al. named it so in 1954 for its ability to mimic malignancy clinically and radiologically [Med Pediatr Oncol 2000;35(5):484–7]. This tumor, characterized by its rareness, affects mainly the lung and the orbit. Histologically, the tumor is characterized by the presence of fibroblasts, myofibroblasts, polymorphs, lymphocytes, and neutrophils. This case report and review of literature present a male patient, 37 years old, with a bulky mediastinal lesion at the topography of the 4th rib. Histopathology reveals Hodgkin's Lymphoma (HL) concomitant with inflammatory myofibroblastic tumor (IMT). This report aims to emphasize the relevance of differential diagnoses to a better medical assistance. To the best of our knowledge, a case with this characteristic has never been seen before.

© 2019 The Author(s)
Published by S. Karger AG, Basel

Introduction

IMT is a rare lesion that has no predilection of age, gender or race. Still, the majority of cases are found on persons under the age of 40 [1, 2]. The physiopathology underlying this disease is still unknown, with the existence of two principal hypothesis [2]. Firth suggests that it is an intensive inflammatory response to an infection. Other hypothesis advocates that there is a relation between the proliferation of immune cells and a lesion of low-grade malignancy. The chromosomal rearrangement found in nearly two-thirds of cases the ALK locus (2p23) supports the uncontrolled response to low-grade tumors. As a final consideration, it is recommended, for treatment, the resection of the tumor, if possible, an association with corticosteroids, chemotherapy or radiotherapy, is also preconized. There are studies undergoing for the use of Crizotinib for IMT with positive ALK rearrangement [3].

Case Report

A 37-year-old male patient was evaluated in the Thoracic Surgery Outpatient, Brasília, Brazil after complaining about ventilatory-dependent thoracic pain in the right costal grid, due to a mass that progressively increased in a three-month period. At clinical examination, a painless tumor was observed in the anterior portion of the right hemithorax with an infiltrative and erythematous pattern. It was also observed facial edema and jugular turgidity, compatible with superior vena cava syndrome. He had smoked for ten years, twenty cigarettes per day. Even though he stopped eight years ago, his mother died from metastatic breast neoplasia when she was 35 years old. Laboratory test results showed the presence of hypergammaglobulinemia, increased production of IgM, IgA and IgG and a higher erythrocyte sedimentation rate. The contrasted chest magnetic resonance evidenced an expansive lesion of infiltrative pattern in the retrosternal region, reaching the soft parts and the intercostal muscles between the first and the fourth right costal cartilages (Fig. 1).

Surgical approach of the tumor was performed through a posterolateral thoracotomy. A surgical biopsy was made. The histological description was compatible with IMT without atypical lymphocytes. Histological samples also revealed fusiform cells proliferation, arranged in curved bundles, sometimes in a whirl pattern, between which there was founded an important number of foamy histiocytes, plasmocytes and multinucleate cells (Fig. 2).

Considering the impossibility of surgical resection, treatment with corticoids (1 mg of prednisone per kilo) was initiated. After a month of therapy, the patient presented regression of the expansive lesion of the chest. Nevertheless, the facial edema and the Superior vena cava syndrome got worse. New images were made.

The computerized tomography with protons emission – PET/CT-scan – revealed retrosternal expansive lesion, poorly defined and with an heterogeneous metabolism increasing, that extends from the first to the fourth right costal arches and involves the region of the right internal mammary and the right cardiophrenic region, presenting an increased metabolism (SUV = 3, 8) and mediastinal lymphadenomegaly, presenting an increased metabolism in the upper and lower paratracheal region (SUV = 19, 9) (Fig. 1).

Considering the advance of the mediastinal lymphadenomegaly and the expansive lesion, the patient was submitted to a mediastinoscopy with an excisional biopsy of several

mediastinal lymph nodes, which report revealed: fibrofatty tissue with elongated cells proliferation and no evident atypia related to the collagen deposition and the mixed infiltration of lymphocytes, plasmocytes and frequent eosinophils. There were also observed, in the sample, atypical big lymphocytes, and positive CD30 (Fig. 2), following the immunohistochemistry panel (Table 1), suggesting the hypothesis of the Classical Hodgkin lymphoma, nodular sclerosis subtype.

Considering the hypothesis of two synchronous neoplasias and the fact that some rare variants of the IMT don't react to the corticoids, it was made a research for the ALK rearrangement with the FISH method (Fluorescent In Situ Hybridisation). The result was negative for the rearrangement. Therefore, it can be concluded that the HL in Ann Arbor staging 2BX, was coexisting with the IMT. The histopathology strengthens the diagnosis, the morphological presentation of the inflammatory tissue and the atypical lymphocytes were not similar to any LH subtype. It presented a bigger number of fibroblasts than usual and no nodular disposition, as expected. Facing those histological and genetic findings, a therapy with adriamycin, bleomycin, vinblastine, dacarbazine was started, following the ABVD protocol, in four cycles in tandem with the radiotherapy. After treatment, the patient made a PET-scan for control that resulted in the complete resolution of the expansive lesion in the thorax and a mediastinal lymphadenomegaly (Fig. 1).

Considering the diagnose off two synchronous neoplasia and of the family history, the patient has been investigated following the short hereditary panel to exclude the main genetic syndromes linked to cancer: BRCA1, BRCA2, NBN.

Finally, as differentiated diagnoses, malign tumors in lung, lung metastasis and sarcoidosis have been considered. However, the clinical investigation described earlier allowed the exclusion of those and the confirmation of a rare case where there can be found an LH synchronous with an IMT.

Results

The medical investigation concluded that this case consisted of two synchronous lesions, IMT concomitant with classical HL. The histopathology confirms the diagnosis. The patient had a full response to treatment.

Discussion/Conclusion

ITM is a rare lesion. However, it has been reported in a variety of anatomical sites. It is a non-neoplastic lesion, however, it is clinically an radiologically similar to malignant diseases. In this way, the medical team needs to keep in mind this differential diagnosis. In addition, as highlighted with the literature review, there are few cases where the ITM can occur simultaneously or after a neoplastic disease [4].

ITM can be characterised pathologically, radiologically or in a laboratory. A classical histopathology of ITM is characterised by fusiform organised myofibroblasts – this can be observed in Figure from the biopsy – [4]. Laboratory findings revealed hypergammaglobulinemia, with an increase of immunoglobulins fractions, such as IgM, IgA, IgG, increased hemo

sedimentation rate and thrombocytosis. Our patient presented hypergammaglobulinemia and increased hemo sedimentation rate. Depending on the affected anatomical site, IMT can have several presentations, but generally, it is a limited lesion that can present calcification, especially on kids. In some cases, it is necessary to make a computed tomography to eliminate other etiologies. In this case, the tumor mass was not delimited. The atypical morphology can be due to ITM and Hodgkin lymphoma synchrony.

As described, the ITM appeared simultaneously with the Hodgkin lymphoma and in the same anatomic place. The literature review about ITM and malignant diseases was made considering that the ITM was the first one to appear in the anatomic site. It revealed one unique case [14]. Concomitant cases were summarised in Table 2 [5–15]. The anatomical place of the disease has been assessed in cases 1, 3, 4 and 6 – summarised in Table 2. There can be seen an anatomical proximity between ITM and malignant neoplasia with none corresponding to HL. The only case where an anatomical correlation between ITM and HL existed was case number 10. However, in this case, the IMT was grown after radiation, which means that the IMT was localized in a region once affected by HL, but no concomitantly with this neoplasia.

Our literature review emphasise the correlation between IMT and other malignant diseases, being before, after or during the evolution of the IMT. At the best of our knowledge, no case has been found where IMT was coexisting with HL. It can be said that this case is the first report of a tumor characterized by HL and ITM, without being a complication or relapse from the neoplasia, as mentioned before.

Acknowledgement

None.

Statement of Ethics

We have no ethical conflicts to disclose.

Disclosure Statement

We have no conflicts of interest to declare.

Funding Sources

None.

Author Contributions

Conceptualization: Leticia Assad Sandoval.

Writing – original draft preparation: Leticia Assad Sandoval.

Writing – review and editing: Leticia Assad Sandoval.

Approval of final manuscript: all authors.

References

- Gorospe L, Fernández-Gil MA, Torres I, Tovar J, García-Miguel P, Tejerina E. Misleading lead: inflammatory pseudotumor of the mediastinum with digital clubbing. *Med Pediatr Oncol*. 2000 Nov;35(5):484–7.
- Weinberger SE. Inflammatory myofibroblastic tumor (plasma cell granuloma) of the lung. Uptodate2018 [updated 2016].
- Murga-Zamalloa C, Lim MS. ALK-driven tumors and targeted therapy: focus on crizotinib. *Pharmacogenomics Pers Med*. 2014 Mar;7:87–94.
- Narla LD, Newman B, Spottswood SS, Narla S, Kolli R. Inflammatory pseudotumor. *Radiographics*. 2003 May-Jun;23(3):719–29.
- Shin HC, Gu MJ, Kim SW, Kim JW, Choi JH. Coexistence of gastrointestinal stromal tumor and inflammatory myofibroblastic tumor of the stomach presenting as a collision tumor: first case report and literature review. *Diagn Pathol*. 2015 Oct 6;10:181.
- Dobrosz Z, Ryś J, Paleń P, Właszczuk P, Ciepiela M. Inflammatory myofibroblastic tumor of the bladder—an unexpected case coexisting with an ovarian teratoma. *Diagn Pathol*. 2014 Jul 15;9:138.
- Li J, Yun W, Qin J, Zhao J, Liu X, Wu J, et al. Inflammatory myofibroblastic tumor of the breast coexisting with breast cancer: a case report. *Breast Care (Basel)*. 2013 Aug;8(4):290–2.
- Papadopoulou D, Chatziralli I, Papadopoulos V, Filitantzi C, Demertzidis C. Synchronous gastric inflammatory myofibroblastic tumour with gastrointestinal stromal tumour of the stomach and hepatic syringous haemangioma. *J Surg Case Rep*. 2012 Jan;2012(1):7–7.
- Gasljević G, Lamovec J. Malignant lymphoma of the stomach in association with inflammatory myofibroblastic tumor of the spleen. A case report. *Pathol Res Pract*. 2003;199(11):745–9.
- Nwogu CE, Tan DF, McLean M. Diagnostic dilemma: persistent superior mediastinal mass following treatment of hodgkin's lymphoma. *Case Rep Clin Pract Rev*. 2005;6:128–30.
- Cotelingam JD, Jaffe ES. Inflammatory pseudotumor of the spleen. *Am J Surg Pathol*. 1984 May;8(5):375–80.
- Özbalak M, Torun ES, Özdemirli M, Uçar AR, Akpınar TS, Taşcıoğlu C, et al. Inflammatory myofibroblastic tumor mimicking a relapse in a patient with Hodgkin's lymphoma: report of an unusual case and review of the literature. *Clin Case Rep*. 2017 May;5(6):945–9.
- Ilic V, Dunet V, Beck-Popovic M, Boubaker A. Pulmonary inflammatory myofibroblastic tumour after Hodgkin's lymphoma. *BMJ Case Rep*. 2014 Jan;2014:bcr2013202491.
- Howman-Giles R, London K, McCowage G, Graf N, Harvey J. Pulmonary inflammatory myofibroblastic tumor after Hodgkin's lymphoma and application of PET imaging. *Pediatr Surg Int*. 2008 Aug;24(8):947–51.
- Kroft SH, Stryker SJ, Winter JN, Ergun G, Rao MS. Inflammatory pseudotumor of the pancreas. *Int J Pancreatol*. 1995 Dec;18(3):277–83.

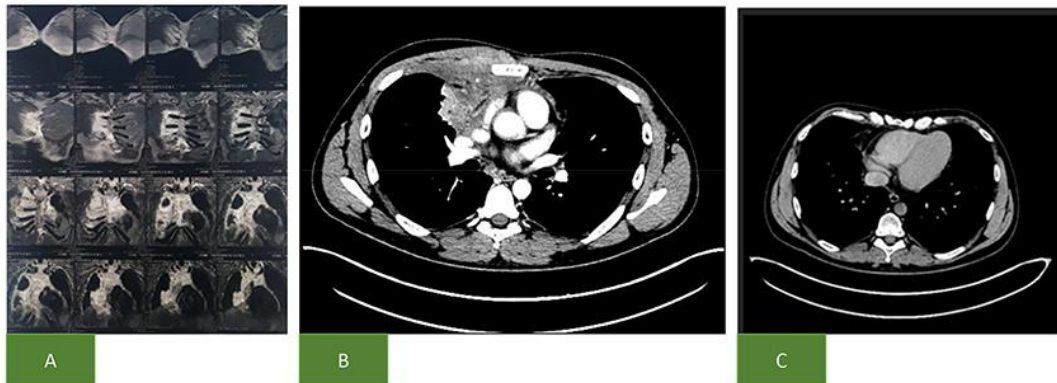

Fig. 1. **A** – Surgical biopsy demonstrates: fusiform cells proliferation, arranged in curved bundles, sometimes in a whirl pattern, between which there was founded an important number of foamy histiocytes, plasmocytes, and multinucleate cells. **B** – Second biopsy, it is observed, in the sample, atypical big lymphocytes. **C** – Second biopsy, it is observed, in the sample, positive CD30.

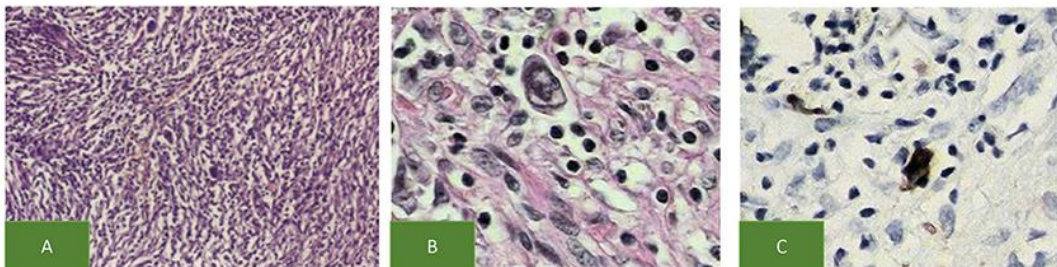


Fig. 2. **A** – Firth contrasted chest magnetic resonance evidenced an expansive lesion of infiltrative pattern in the retrosternal region, reaching the soft parts and the intercostal muscles between the first and the fourth right costal cartilages. There wasn't a cleavage plane between the lesion and the pectorals major muscle. **B** – Computerised tomography with protons emission – PET/CT-scan – revealed retrosternal expansive lesion, poorly defined and with an heterogeneous metabolism increasing, that extends from the first to the fourth right costal arches and involves the region of the right internal mammary and the right cardiophrenic region, presenting an increased metabolism (SUV = 3, 8) and mediastinal lymphadenomegaly, presenting an increased metabolism in the upper and lower paratracheal region (SUV = 19, 9). **C** – Control computerised tomography with protons emission – PET/CT-scan that resulted with the complete resolution of the expansive lesion in the thorax and a mediastinal lymphadenomegaly.

Table 1. Immunohistochemistry panel

Antibodies	Clone	Result
Smooth muscle actin	1A4	Negative
CD34 – antigen of haemopoietic progenitor cells and pericytes	QBEnd 10	Negative
Desmin (intermediary filament of muscular cells)	D33	Negative
Protein S-110	Polyclonal	Negative
STAT6	Polyclonal	Negative
CD246 – protein ALK, translocation product(2;5)	ALK1	Negative
Cytokine de 40, 48, 50 e 50.6 kDa	AE1/AE3	Negative
CD30 – antigen Ki-1	Ber-H2	Positive in atypical lymphocytes cells
CD15 – antigen of granulocytes and Reed- Sternberg cells	Carb-3	Negative
Oncoprotein LPM-1 of Epstein-Barr virus	CS1-4	Negative
PAX5, Familiar transcription factor – paired box	Polyclonal	Negative

Table 2. IMT concomitant cases summarised [5–15]

N	Clinical context	Age/ sex	IMT anatomical location	Linked bibliography
1	Gastric collision tumor formed by GIST e IMT	16/F	Stomach body	5
2	IMT in bladder coexisting with ovarian teratoma	19/F	Bladder	6
3	IMT in breast coexisting with breast cancer	39/F	Left breast medial upper quadrant	7
4	Stomatal IMT coexisting with GIS and e hepatic hemangioma	80/M	Pre-pyloric	8
5	Spleen IMT as found during surgery for removing tumor cells B in stomach	40/M	Spleen	9
6	Mediastinal IMT simultaneously with HL	58/M	Superior mediastinum	10
7	Spleen IMT as found during investigation for HL staging	60/M	Spleen	11
8	IMT after HL considered cured	70/F	Abdomen and mediastinum	12
9	IMT after HL considered cured	14/F	Lower lobe of the left lung	13
10	IMT formerly affected region with HL	16/M	Left upper lobe of the lung former infected region by HL and radiated	14
11	Diagnosed Pancreas IMT during chemotherapy support for Lymphoma of uterine cervix treatment	42/F	Pancreas	15