

Peristomal pagetoid spread of urothelial carcinoma of the ureter

Fumio Ito,¹ Ken Kihara,² Koh Shiomi,² Sumiko Ishizaki,³ Masaru Tanaka,³ Motohiko Aiba,⁴ Mariko Fujibayashi,⁴ Hayakazu Nakazawa¹

¹Department of Urology, Tokyo Women's Medical University, Medical Center East, Tokyo; ²Division of Urology, Showa-kai Hospital, Tokyo; ³Department of Dermatology, Tokyo Women's Medical University, Medical Center East, Tokyo; ⁴Department of Surgical Pathology, Tokyo Women's Medical University, Medical Center East, Tokyo, Japan

Abstract

Patients with ostomy including urinary stoma often develop peristomal complications, especially skin damage. The patient in this case was a 69-year old female with a history of urothelial carcinoma of the bladder and left ureter who underwent transurethral resection of a bladder tumor, nephroureterectomy and cystectomy combined with ureterocutaneostomy. Later, she had recurrence of urothelial carcinoma in the remaining ureter that spread to the peristomal epidermis, with a skin appearance resembling Paget's disease. We report this case based on its clinical significance since we believe it is the first description of this condition in the literature.

Introduction

Peristomal inflammation often develops in patients with ureterocutaneostomy or ileal conduit.¹ The inflammation presumably results from direct irritation by urinary contents, allergic reaction to stomal devices, regional infection, or abrasion. The case reported here showed persistent inflammation including erythematous, erosive, eczematous, and pruritic lesions in the peripheral region of the ureterocutaneostomy stoma. A pagetoid variant of urothelial carcinoma (UC) recurred in the upper urinary tract and spread to the peristomal skin, with a skin appearance similar to that in Paget's disease. To the best of our knowledge, there have been no reports of a peristomal Paget phenomenon in UC patients who underwent ureterocutaneostomy or ileal conduit, and only one report of a similar phenomenon in a patient who underwent ileostomy for

ulcerative colitis.² However, urologists may overlook Paget phenomenon as simple peristomal inflammation, and thus cases with such a lesion may be latently larger in number than expected. Therefore, we describe this case to increase awareness of the possibility of this phenomenon in association with a peristomal lesion.

Case Report

The patient was a 69-year-old female who developed macroscopic hematuria 7 years ago. Under clinical diagnosis of bladder carcinoma, she underwent transurethral resection, with a resultant pathological diagnosis of urothelial carcinoma in situ (CIS). Two years later, she developed recurrence of stage Tis UC in the most distal part of the left ureter and underwent left nephroureterectomy. One year later, she had intravesical recurrence of UC as stage Tis disease with resistance to BCG therapy and underwent radical cystectomy and reconstruction with ureterocutaneostomy. Two years ago, peristomal inflammation developed and persisted despite regular medication for dermatitis.

Two dermatologists (S.I. and M.T.) suspected squamous cell carcinoma or metastatic skin carcinoma by inspection and performed peristomal skin biopsy. Under a diagnosis of a peristomal Paget phenomenon of UC, we performed *en-bloc* resection of the remaining ureter and peristomal skin with a sufficient normal margin (Figure 1) and percutaneous nephrostomy, followed by reconstruction of the

Correspondence: Fumio Ito, Department of Urology, Tokyo Women's Medical University, Medical Center East, 2-1-10, Nishiogu, Arakawa-ku, 116-8567 Tokyo, Japan.
Tel. +81.338.101.111 - Fax: +81.338.9402.82
E-mail: fitour@dnh.twmu.ac.jp

Key words: urothelial carcinoma, secondary Paget's disease, peristomal complication.

Contributions: the authors contributed equally.

Conflict of interests: the authors declare no potential conflict of interests.

Received for publication: 5 April 2013.

Revision received: 3 July 2013.

Accepted for publication: 8 July 2013.

This work is licensed under a Creative Commons Attribution NonCommercial 3.0 License (CC BY-NC 3.0).

©Copyright F. Ito et al., 2013

Licensee PAGEPress, Italy

Rare Tumors 2013; 5:e49

doi:10.4081/rt.2013.e49

abdominal wall to wrap the exposed fascia with surrounding excess skin.

Pagetoid cells and conventional CIS cells were observed by light microscopy in the distal two-thirds of the right ureter. The pagetoid cells formed a cluster and had spread to basal layers of transitional epithelium with partial squamous metaplasia. These cells were characterized by abundant clear cytoplasm with

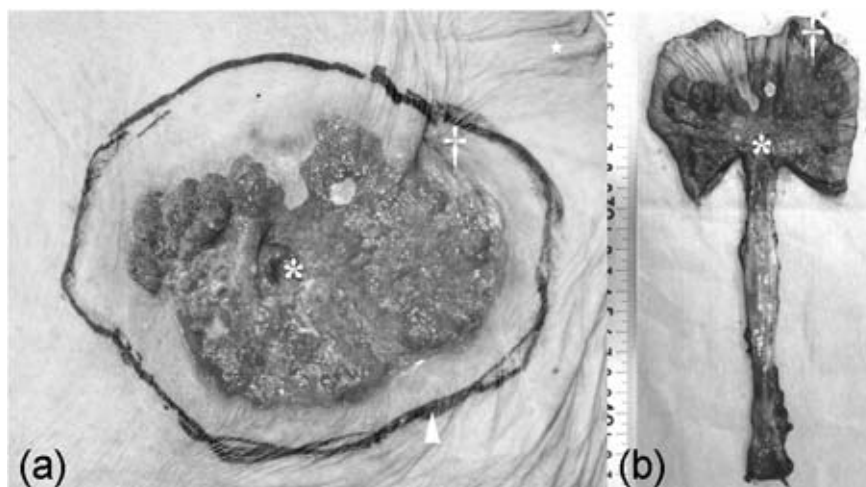


Figure 1. Gross appearances of (a) peristomal skin lesion and (b) *en-bloc* extirpated specimen including the peristomal skin and right ureter (b). The peristomal skin included erythematous, erosive, eczematous and circinate lesions, which resembled Paget's disease, but the surgical margin was free from these lesions. The ureter cut open showed extensive roughness on the mucosal surface. * means exit of the right ureter, † means navel, ▲ means planned resection line.

occasional vacuoles, enlarged hyperchromatic nuclei and overt nucleoli. Pagetoid cells had also spread into the peristomal epidermis directly from the ureteral mucosa (Figure 2a) and were present among p63-positive cells (*i.e.* epidermal basal cells), which showed that pagetoid cells had spread to the basal layer of the epidermis. However, the basal membrane between the epidermis and dermis was intact and the tumor cells had not invaded the dermis. The intraepidermal pagetoid cells had abundant mitoses and formed a papillary or pseudoalveolar architecture. The surrounding stroma showed prominent congestion and infiltration of lymphocytes and histiocytes, but neither via-vessel extension nor direct invasion of neoplastic cells (Figure 2b). In immunohistochemistry, the cells in the epidermis and ureteral mucosa were positive for CK7 and CK20 (Figure 2c) and pagetoid cells were positive for HER2 (Figure 2c). In contrast to the distal region, the proximal surgical end of the ureter was free of cancerous cells.

Discussion and Conclusions

In this report, we presented a case in which a pagetoid variant of UC derived from the ureter after ureterocutaneostomy spread to the skin of the peripheral region of a ureterocutaneostomy stoma, with a resulting appearance that resembled Paget's disease. Pagetoid growth of UC is one phenotype of urothelial carcinoma *in situ* (CIS), which was first described in 1952 by Melicow *et al.*³ Among bladder CIS cases, 12-16% involve pagetoid change.^{4,5} However, cases with pagetoid spread of UC to the skin are rare, and there have been only a few reports of UC of the bladder that spread to the skin, including the glans penis, urethral meatus, and vulva.⁶ In such cases, discrimination of a perineal pagetoid lesion of UC from primary extramammary Paget's disease requires immunohistochemistry with antibodies against CK7, CK20, Mucin, PAS, CEA and GCDFP15.⁶⁻⁹

In our case, the previously extirpated left ureter and bladder had conventional CIS without pagetoid change. Therefore, pagetoid UC cells may have newly developed from CIS in the remaining right ureter and spread to the peristomal skin. UC of the upper urinary tract often recurs in the downstream portion (*i.e.* the bladder), presumably due to tumor implantation.¹⁰ In our case, however, metastasis of pagetoid UC cells to the peristomal skin may not have occurred through implantation or via-vessel extension, but by direct invasion, based on the pathological findings. Interestingly, UC cells that spread to urinary skin downstream have had a pagetoid phenotype in previous reports, and this was also found in our case.

This suggests that UC cells with a pagetoid phenotype have closer affinity with skin than those with a conventional phenotype. The pagetoid UC cells in our case were positive for HER2, via which a motility factor is believed to induce epidermal spread of Paget's cells in Paget's disease.¹¹

The differential diagnosis for the pagetoid lesion was relatively easy in our patient because her lesion was distant from predilec-

tion sites for mammary or extramammary Paget's disease, such as the nipple, axilla, external genitalia, anus and umbilicus. Immunohistochemistry also showed that the pagetoid cells were positive for CK7 and CK20, and negative for mucin, PAS and CEA (data not shown), which classified the lesion as secondary Paget's disease.^{7,8}

Urologists sometimes encounter recurrence of UC from the urothelium itself at the stoma,

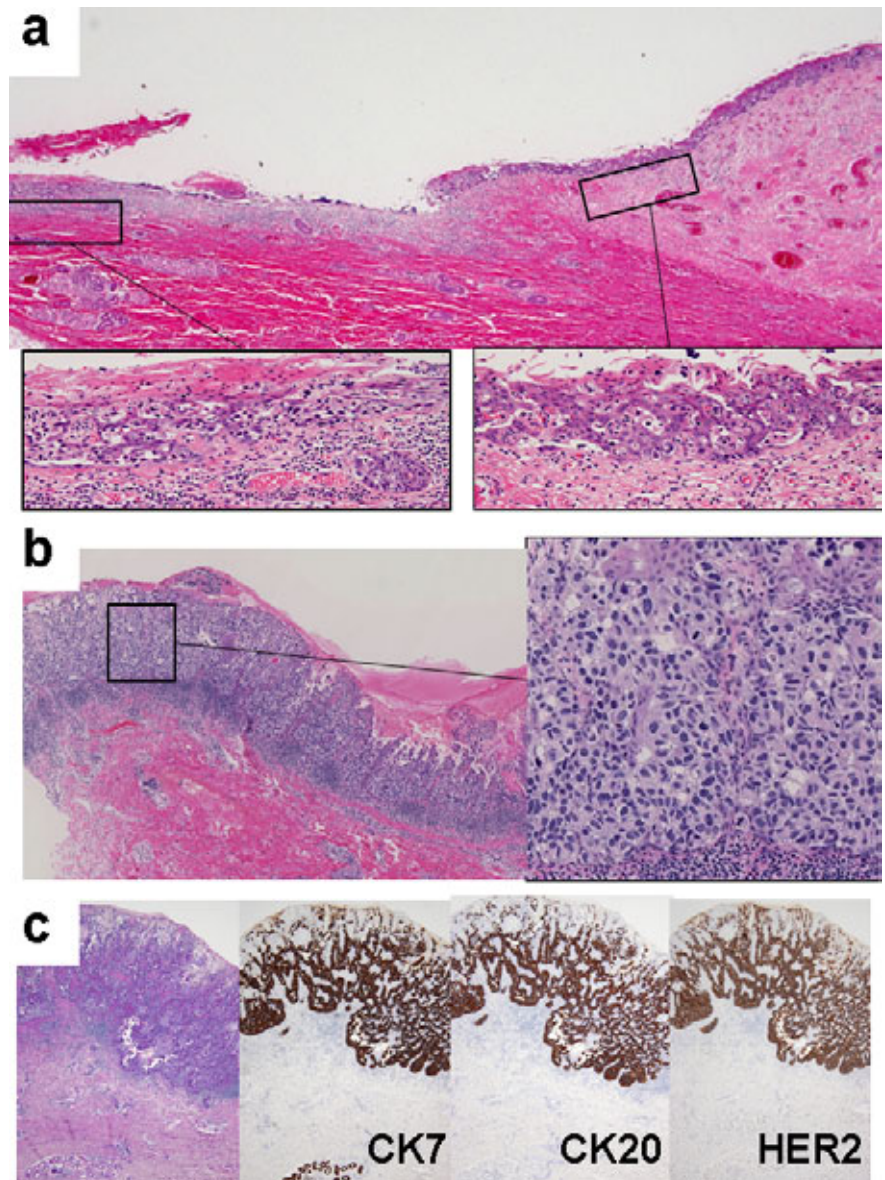


Figure 2. Light microscopic appearance of pagetoid lesions. (a) Junction of the right ureter and peristomal skin. Most of the junction was eroded. In the residual intact junction, pagetoid cells spread into the peristomal epidermis directly from the ureteral mucosa. (hematoxylin-eosin stain, 4× and 100×). (b) Intraepidermal pagetoid lesion in the peristomal skin. (hematoxylin-eosin stain, 40× and 200×). (c) Immunohistochemistry with anti-HER2, anti-CK7 or anti-CK20 antibody. The presence of both CK7 and CK20 is characteristic of secondary Paget's disease. Expression of HER2 implies an epidermotropic ability of pagetoid tumor cells (hematoxylin-eosin or immunoperoxidase stain, 40×).

but it may be difficult for general urologists with limited expertise in dermatology to distinguish epidermal spread of pagetoid UC, especially at an early stage, from incurable peristomal inflammation based on gross appearance alone. The case reported here has no precedent in the English literature, which implies that spread of pagetoid UC to peristomal skin is rare. However, such a malignant lesion might be overlooked as simple inflammation. Therefore, urologists should bear in mind the possible phenotype of UC spread in a patient with persistent peristomal inflammation. In such a case, a dermatologist should be consulted for a skin biopsy.

References

1. Salvadalena G. Incidence of complications of the stoma and peristomal skin among individuals with colostomy, ileostomy, and urostomy: a systematic review. *J Wound Ostomy Continence Nurs* 2008;35:596-607.
2. Liu X, Melton GB, Xie H, Dietz DW. Extramammary Paget disease in peristomal skin: report of a unique case. *J Gastrointest Surg* 2012;16:1967-71.
3. Melicow MM, Hollowell JW. Intra-urothelial cancer: carcinoma in situ, Bowen's disease of the urinary system: discussion of thirty cases. *Urol* 1952;68:763-72.
4. McKenney JK, Gomez JA, Desai S, et al. Morphologic expressions of urothelial carcinoma in situ: a detailed evaluation of its histologic patterns with emphasis on carcinoma in situ with microinvasion. *Am J Surg Pathol* 2001;25:356-62.
5. Orozco RE, Vander Zwaag R, Murphy WM. The pagetoid variant of urothelial carcinoma in situ. *Hum Pathol* 1993;24:1199-202.
6. Salamanca J, Benito A, García-Peñalver C, et al. Paget's disease of the glans penis secondary to transitional cell carcinoma of the bladder: a report of two cases and review of the literature. *J Cutan Pathol* 2004;31:341-5.
7. Malik SN, Wilkinson EJ. Pseudo-Paget's disease of the vulva: a case report. *J Low Gen Tract Dis* 1999;3:201-3.
8. Ohnishi T, Watanabe S. The use of cytokeratins 7 and 20 in the diagnosis of primary and secondary extramammary Paget's disease. *Br J Dermatol* 2000;142:243-7.
9. Goldblum JR, Hart WR. Vulvar Paget's disease: a clinicopathologic and immunohistochemical study of 19 cases. *Am J Surg Pathol* 1997;21:1178-87.
10. Habuchi T, Takahashi R, Yamada H, et al. Metachronous multifocal development of urothelial cancers by intraluminal seeding. *Lancet* 1993;342:1087-8.
11. Schelfhout VR, Coene ED, Delaey B, et al. Pathogenesis of Paget's disease: epidermal heregulin-alpha, motility factor, and the HER receptor family. *J Natl Cancer Inst* 2000;92:622-8.