

Access this article online

Quick Response Code:



Website:

www.e-tjo.org

DOI:

10.4103/tjo.tjo_5_17

Management of diplopia with visual-field defects

Ling-Yuh Kao, Chun-Hsiu Liu, Meng-Ling Yang

Abstract:

PURPOSE: The management of diplopia can be challenging in patients with a concurrent visual-field (VF) defect. We conducted a retrospective chart review to analyze and compare treatment outcomes for different types of VF defects.

METHODS: A retrospective chart review.

RESULTS: Seven patients with diplopia and VF defects were identified during the study. Four had bitemporal hemianopia, one had homonymous hemianopia, and two had a constricted central VF. A favorable or satisfactory outcome was achieved in all but two patients with bitemporal hemianopia.

CONCLUSIONS: The hemifield-slide diplopia may develop in patients with bitemporal hemianopia or heteronymous altitudinal visual defects. Sensory abnormalities usually persist, even after elimination of ocular misalignment.

Keywords:

Diplopia, strabismus, visual-fields

Introduction

Binocular diplopia occurs in patients with strabismus due to the image projects to a different direction of the bilateral retina. It can be a troublesome problem in patients with acquired motor dysfunction such as paralytic strabismus after trauma or an intracranial event.^[1] Patients with long-standing strabismus may experience diplopia when they lose their previous capacity for sensory adaptation, as may occur with a decompensated congenital fourth-nerve palsy. If the deviation is large and an incomitance exists, surgery can be helpful in reducing the incomitance of eye movement and in restoring ocular alignment. For those patients with small deviation complaining of diplopia, prism correction can be used to redirect the image onto corresponding retina in both eyes and thus eliminate diplopia. However, treatment can be challenging if the patient has simultaneous diplopia and a constricted

visual-field (VF), because the VF defect might interfere with binocular interaction.

Here, we present a case series of seven patients who experienced diplopia after developing a VF defect. We provide the results of treatment and perform a literature review.

Methods

This is a retrospective case series of seven patients from Chang-Gung Memorial Hospital, Taoyuan, Taiwan. All patients were examined between 2005 and 2015. We reviewed patient charts for their clinical presentation and examination, imaging findings, operative details, and postoperative outcomes. This study was approved by the research ethics board at Chang-Gung Memorial Hospital and adhered to the tenets of the Declaration of Helsinki.

Results

Seven patients with acquired diplopia after VF defect development were identified.

How to cite this article: Kao LY, Liu CH, Yang ML. Management of diplopia with visual-field defects. Taiwan J Ophthalmol 2017;7:22-7.

This is an open access article distributed under the terms of the Creative Commons Attribution-NonCommercial-ShareAlike 3.0 License, which allows others to remix, tweak, and build upon the work non-commercially, as long as the author is credited and the new creations are licensed under the identical terms.

For reprints contact: reprints@medknow.com

Department of
Ophthalmology, Chang
Gung Memorial Hospital,
Chang Gung University
College of Medicine,
Taoyuan, Taiwan

Address for correspondence:

Dr. Meng-Ling Yang,
Department of
Ophthalmology, Chang
Gung Memorial Hospital,
Chang Gung University
College of Medicine,
Taoyuan, Taiwan No. 5,
Fu-Shin Street,
Kwei-Shan Hsien,
Tau-Yuan Hsiang, Taiwan.
E-mail: menling@gmail.
com

Submission: 03-06-2016

Accepted: 17-08-2016

None had new-onset ocular motor dysfunction. The demographic, ophthalmic, and operative features of these patients are summarized in Table 1.

Patient 1

A 22-year-old male patient visited our clinic complaining of diplopia after a traffic accident 1 year prior. There was no abnormal eye position noted before his accident. The trauma caused encephalomalacia and fracture of the frontal bone and orbital bone. His best-corrected visual acuity (BCVA) was 1.0 in both eyes. Fundus examination revealed bilateral bow-tie shaped optic atrophy. His VF examination showed complete bitemporal hemianopia [Figure 1]. Traumatic optic chiasmopathy was then diagnosed. Ocular motility testing revealed no ophthalmoplegia, and the prism-cover test demonstrated 16 prism-diopter (PD) exotropia (XT) and 7 PD right hypertropia (RH). To eliminate this diplopia, we performed lateral rectus muscle (LRM) recession of 6.5 mm and superior rectus muscle (SRM) recession of 3 mm in the right eye. Three months after strabismus surgery, the prism-cover test revealed 0.5 PD XT and 4 PD RH at the primary position. Eye-alignment examination with the Hess chart also showed improvement over the preoperative findings. However, the patient complained that his diplopia persisted and failed to fuse with any prism.

Patient 2

A 16-year-old boy visited our clinic for diplopia after the removal of a brain tumor. The patient described difficulty reading: words such as “happy” would become “happy.” There was no prior history of strabismus or amblyopia. Three years prior, he was

diagnosed with a suprasellar germinoma for which he underwent craniotomy to excise the tumor, followed by radiotherapy. His BCVA was 0.2 in the right eye and 0.05 in the left eye. Fundus examination revealed bilateral diffuse optic atrophy, and VF examination showed bitemporal hemianopia and an inferonasal defect in the right eye [Figure 2]. Hirschberg testing revealed 15° of XT in the left eye, and the prism-cover test demonstrated approximately 30 PD XT. On the prism-adaptation test, he reported a narrowing image with a 35-PD base in prism while a widening image with a 25-PD base in the prism. He noted the most normal image with a 30-PD base in the prism. Ocular-motility testing revealed normal duction and version. To eliminate the diplopia, we performed LRM recession of 6.0 mm and medial rectus muscle (MRM) resection of 4.5 mm in the left eye. One month after surgery, prism-cover testing revealed residual 14 PD XT. Prism adaptation for challenging with a 14-PD base in led to image narrowing. He was free of diplopia at both near and distant fixation without any prism aid. The vision and eye position remained stable at 5-year follow-up.

Patient 3

A 10-year-old boy was referred to our clinic with the complaint of diplopia. He described a vertically displaced image that disappeared with chin-up posturing. He noted this vision change after cranial surgery for removing a craniopharyngioma 4 months prior. His preoperative ophthalmic examination was normal except for bilateral myopia. Cycloplegic refraction revealed – 2.50 diopters in the right eye and – 2.00 diopters in the left eye. Both eyes had a BCVA of 1.0. Prism-cover testing showed 11 PD XT at the primary position. Ocular motility

Table 1: Summarization of the important features of the patients

Age/ gender	BCVA		Type of visual-field defect	Cause	Preoperative deviation	Operation method	Postoperative deviation	Postoperative diplopia
	OD	OS						
22/male	1.0	1.0	Bitemporal Hemianopia	Traumatic Encephalomalacia	XT 16 PD RH 7 PD	RLR rec 6.5 mm RSR rec 3 mm	XT 0.5 PD RH 4 PD	Yes
17/male	0.2	0.05	Bitemporal Hemianopia	Suprasellar Germinoma	XT 35 PD	LLR rec 6 mm LMR res 4.5 mm	XT 14 PD	No
10/male	1.0	1.0	Bitemporal Hemianopia	Craniopharyngioma	XT 11 PD	No surgery	XT 9 PD	Occasionally
29/male	1.0	1.0	Bitemporal Hemianopia	Traumatic skull base Fracture	XT 18 PD RH 6 PD	RLR rec 9 mm RSR rec 2 mm	XT 10 PD RH 5 PD	Yes
32/male	1.0	1.0	Constricted Central island	Retinitis pigmentosa	XT 4 PD LH 30 PD	LIO myectomy	XT 4 PD LH 16 PD	Occasionally
40/male	0.5	1.0	Constricted Central island	Advanced glaucoma	XT 20 PD	RLR rec 7 mm	RHypo 3 PD	Occasionally
37/female	1.0	1.0	Right Homonymous hemianopia	Tentorial Meningioma	ET 22 PD	LMR rec 7 mm	ET 8 PD	No

BCVA = Best-corrected visual acuity, XT = Exotropia, ET = Esotropia, RH = Right hypertropia, LH = Left hypertropia, RHypo = Right hypotropia, PD = Prism diopter, RLR = Right lateral rectus, RSR = Right superior rectus, LLR = Left lateral rectus, LMR = Left medial rectus, LIO = Left inferior oblique, Rec = Recession, Res = Resection, OD = Right eye, OS = Left eye

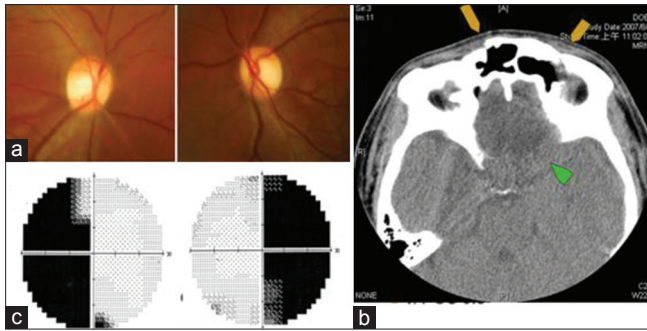


Figure 1: (a) Fundus examination revealed bilateral bow-tie shaped optic atrophy. (b) Computed tomography showed multiple skull bone fracture (yellow arrow) and encephalomalacia (green arrow). (c) Visual-field examination showed complete bitemporal hemianopia

testing revealed normal and symmetric eye movement bilaterally; however, the Hess chart demonstrated mild supraduction overaction in the right eye. Fundus examination revealed bilateral optic atrophy, and VF examination showed bitemporal hemianopia [Figure 3]. Since the patient could eliminate the diplopia with an adapted head posture, we proceeded with observation only. One year later, the patient noticed diplopia only with an upward gaze. The Worth four-dot test revealed left-eye suppression. The last follow-up was 6 years after the first visit, and the optic disc, VF defect, and XT remained stable. His BCVA was 1.0 bilaterally with a correction of -4.75 diopters in the right eye and -4.00 diopters in the left eye. The patient admitted that he seldom experienced diplopia and could simply ignore it when it occurred.

Patient 4

A 29-year-old man presented with diplopia after a traumatic skull base and orbital bone fracture 4 years prior. He was an architect and the diplopia considerably hindered his work. Ocular examination revealed the BCVA to be 1.0 in both eyes. Fundus examination revealed bilateral optic atrophy, and VF examination showed bitemporal hemianopia [Figure 4]. The prism-cover testing revealed 18 PD XT and 6 PD RH at the primary position. Ocular-motility testing demonstrated normal eye movement bilaterally. The Bagolini striated glasses test demonstrated right-eye suppression. To eliminate the diplopia, we performed LRM recession of 9 mm and SRM recession of 2 mm in the right eye. One month after surgery, prism-cover testing revealed 10 PD XT and 5 PD RH. Three months later, synoptophore testing demonstrated an unstable subjective angle from 1 to 3 PD XT and from 3 to 6 PD RH. The patient still experienced diplopia and could not tolerate prism glasses.

Patient 5

A 32-year-old male patient with retinitis pigmentosa complained of intermittent diplopia for the past few

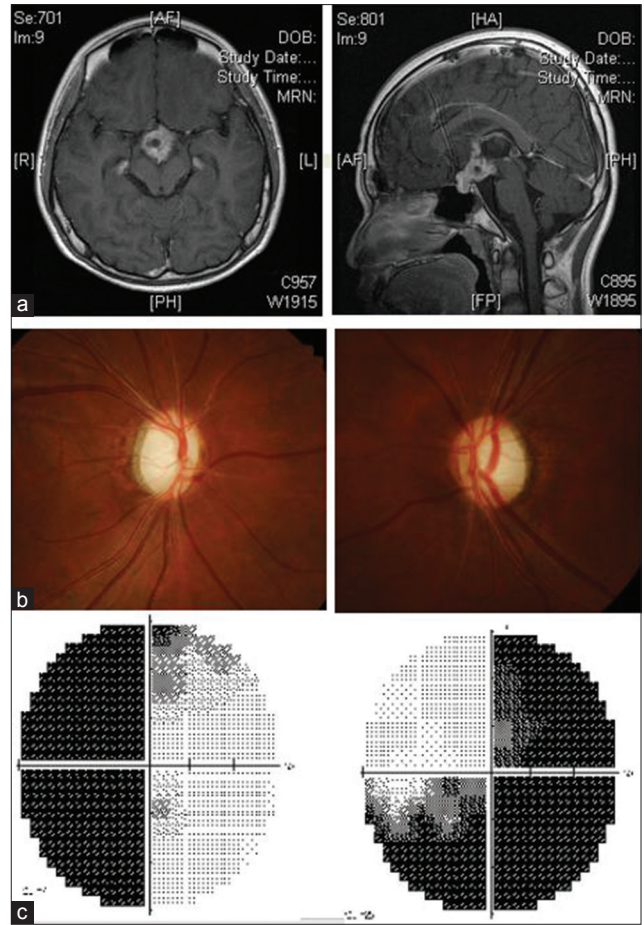


Figure 2: (a) Head magnetic resonance imaging before operation showed a sellar mass with suprasellar extension. (b) Both discs are pale. (c) Visual-field examination showed bitemporal hemianopia along with inferonasal defect in the right eye

years, with recent progression. His corrected vision was 0.8 in both eyes. Fundus examination revealed retinal pigmentary changes, narrowing vessels, and relatively pale discs bilaterally, and VF examination showed that only the central island remained bilaterally [Figure 5]. Prism-cover testing revealed 30 PD left hypertropia (LH) and 4 PD XT. Ocular-motility testing demonstrated slight overaction of the inferior oblique muscle and slight underaction of the superior oblique muscle in the left eye. On prism-adaptation testing, the patient reported no diplopia with a 16 PD prism. However, he did not like prism glasses and asked for surgical correction. We performed an inferior oblique myectomy in the left eye. One month after surgery, cover testing revealed 18 PD LH and 4 PD XT at the primary position. The patient experienced occasional diplopia only with right-up gazing, but there was no diplopia at the primary position or with near work. At the last follow-up visit 3 months later, prism-cover testing measurements were unchanged. The patient was satisfied with being free of diplopia in daily life.

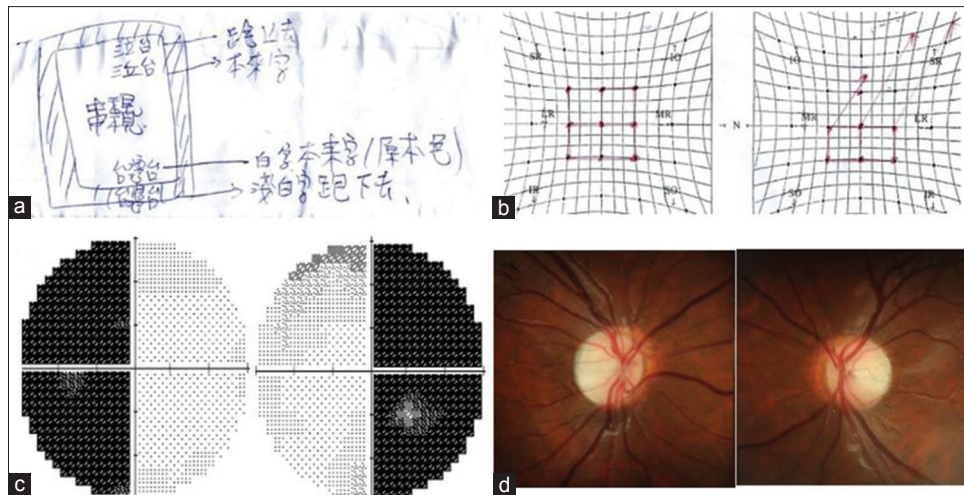


Figure 3: (a) Patient's draw about what he saw. (b) Hess chart showed supraduction overaction on right eye. (c) Visual-field showed bitemporal hemianopsia. (d) Fundus examination demonstrated bilateral optic atrophy




Figure 4: Visual-field examination showed bitemporal hemianopsia in patient 4

Patient 6

A 40-year-old man complained of diplopia 4 days after trabeculectomy of the right eye 4 months before visiting our clinic. His corrected vision was 0.5 with -5.50 -diopter correction in the right eye and 1.0 with -3.50 -diopter correction in the left eye. Fundus examination revealed enlarged disc cupping in the right eye and a normal left eye. His VF examination showed an extremely constricted VF in the right eye, with only $7.5^\circ \times 5^\circ$ remaining in the central island [Figure 6]. Prism-cover testing revealed 20 PD XT at the primary position. Ocular motility testing demonstrated no ophthalmoplegia. To eliminate the diplopia, we performed a right LRM recession of 7.0 mm. One month postoperatively, prism-cover testing revealed 3 PD right hypotropia. The patient described alleviation in diplopia, although it did occur sometimes. He also reported improved stereoacuity.

Patient 7

A 37-year-old woman developed diplopia after a second brain surgery 2 months prior, with left occipital craniotomy for recurrent tentorial meningioma removal. She had good vision and no strabismus before the

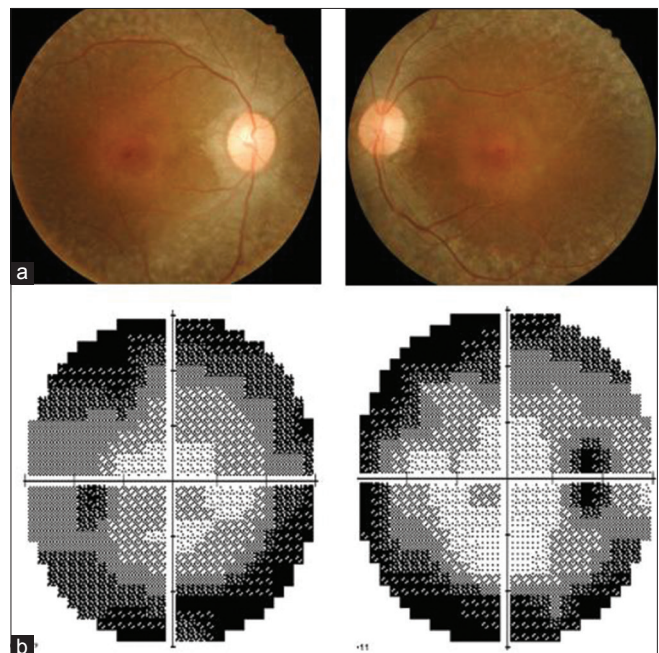


Figure 5: (a) Fundus pictures revealed retina pigmentary changes, narrowing vessels, and relative pale discs bilaterally. (b) Visual-field examination showed bilateral central island remained

first surgery for removing her brain tumor, 18 months previously. Diplopia and esotropia (ET) developed after her first brain surgery, although 10 PD prism glasses eliminated the diplopia in daily life. However, after her second surgery, she experienced diplopia even with the prism glasses. Ocular examination revealed a BCVA of 0.8 in the right eye with -1.75 -diopter correction and 1.0 in the left eye with -1.75 -diopter correction. Fundus examination revealed no optic atrophy, and VF examination showed new-onset right homonymous hemianopsia [Figure 7]. Prism-cover testing revealed 25 PDE ET at the primary position, with both near and distant

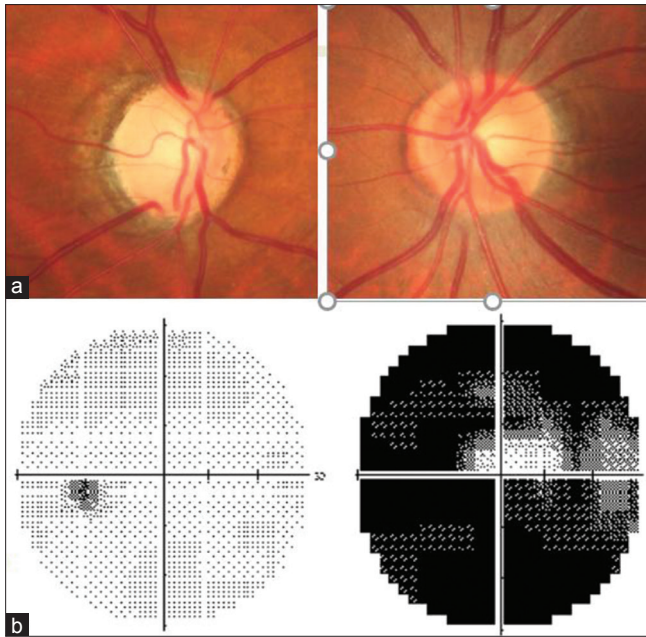


Figure 6: (a) Fundus examination revealed extended disc cupping in right eye. (b) Visual-field examination showed extremely constricted visual-field on right eye

fixation. Her eye movement was free and the range of eye movement was normal bilaterally. To eliminate the diplopia, we performed MRM recession of 7 mm in the left eye. One month after surgery, prism-cover testing revealed 8 PD ET. The patient was satisfied with new prism glasses.

Discussion

Our review shows that two of seven patients (29%) with VF defects successfully eliminated diplopia after surgery and prism-glasses correction. Another two patients (29%) were satisfied, because diplopia occurred only occasionally. Diplopia spontaneously improved in one patient (14%). The other two patients with bitemporal hemianopia still experienced diplopia after surgery.

The normal monocular VF expands to approximately 40°–50° above and 60°–70° below the horizontal meridian, and 90°–100° temporally and 50°–60° nasally from the vertical meridian. The horizontal expansion of the binocular VF reaches 180°–200°. The area of overlap of the monocular VFs of the right and left eyes, on average, has a cross-sectional diameter of 120°; this area is crucial for stereopsis and fusion.^[2] If the VF is too diminished to maintain stereopsis or fusion, then diplopia can occur, known as “hemifield-slide diplopia.”

The hemifield-slide phenomenon is a rare visual disturbance usually associated with bitemporal hemianopia or heteronymous altitudinal field defects,

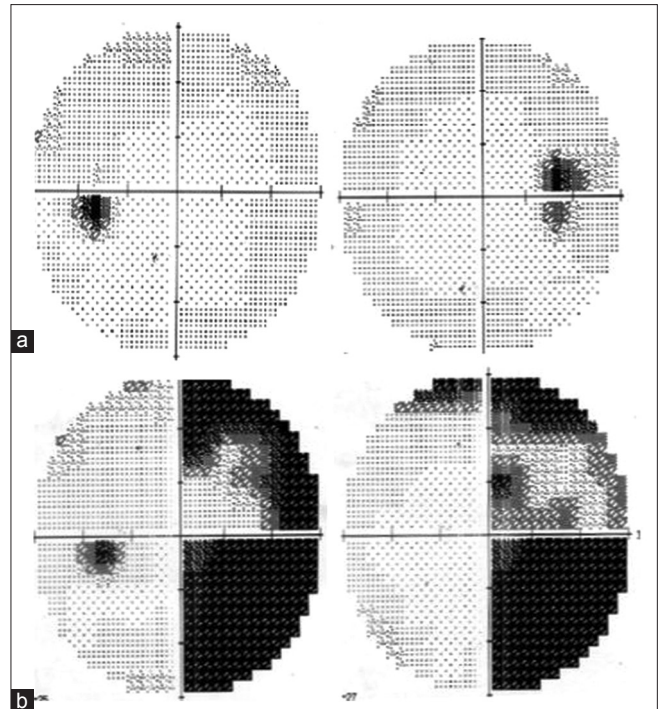


Figure 7: (a) Visual-field after the first brain surgery. (b) Right homonymous hemianopia developed after the second brain surgery

and preexisting heterophoria. VF defects can be caused by injuries of the optic chiasm that result in bitemporal hemianopia,^[3-5] or of the prechiasmal region that result in heteronymous, altitudinal VF defects.^[6] Patients complain of various sensory disturbances: blurred central vision or double vision, intermittent difficulty with reading, and gaps or splitting in vision while looking at an object in front of them.^[7] Diplopia occurs because of overlap of the binocular VFs that is inadequate to maintain fusion; thus, the images from each eye slide apart. Exodeviations cause overlap of the nasal parts of the binocular VFs, whereas esodeviations lead to a separation or “gap” between the nasal hemifields. If the patient has a preexisting vertical phoria, the images are vertically split relative to each other, possibly reported as diplopia, because parts of the same objects are seen in two vertical directions. For diplopia treatment outcomes in patients with VF defects, the residual VF matters. In our patient with right homonymous hemianopia with ET (patient 7), normal fusion could regain after treatment for ET because the retinal location of the temporal VF of the left eye and the nasal field of the right eye overlapped and corresponded to each other. The binocular field was stable, and the patient’s diplopia resolved. For patients with extreme narrowing VF, the size of the VF necessary to maintain central stereopsis is approximately 5°–6°.^[8] In our patient with advanced glaucoma (patient 6), although the central field survived, trabeculectomy could further dampen the visual function and the development of XT rendered the patient unable to fuse normally. After XT

correction, the diplopia improved and some stereopsis returned. Most patients with early-stage retinitis pigmentosa can maintain efficient vision with 10° of the central VF intact. Binocular vision is reduced with decreased visual acuity and loss of VF.^[9] Our patient with retinitis pigmentosa (patient 5) acquired diplopia after developing a decreased VF and possible congenital fourth-nerve palsy decompensation. We noted abnormal retina correspondence (ARC), and we, therefore, targeted surgical treatment on the amount of prism adaptation. After surgery, the patient noted diplopia when he looked right and upward; he was happy with this result for the purposes of work and daily life. By contrast, the treatment result can be unfavorable in patients with bitemporal hemianopia. In two of our four patients with bitemporal hemianopia with XT, diplopia at the central area persisted even after treatment for XT. This occurred because there was no physiologic linkage between the two remaining nasal half fields from the temporal projection of each eye. When the eyes are moving, the loss of overlap results in difficulty maintaining the juxtaposition of the two half fields. However, there were another two patients with bitemporal hemianopia that became almost diplopia-free. We have two hypotheses for explaining this difference. First, the existence of a midline retinal nasotemporal overlap that sends its projection to both hemispheres has been demonstrated in nonhuman primates and other mammals.^[10,11] Studies have shown that the retinal midline nasotemporal overlap exists at 1°, and a complete lateralization at 6°, in humans with normal vision.^[12] Most clinical evidence of the nasotemporal overlap concerns the phenomenon of macular sparing in hemianopic patients. However, it is controversial because macular sparing is not present in all patients, and when present, it appears in varying degrees.^[13,14] Conventional perimetric tests do not test the VF accurately within 3° of the fixation point. This means that if a patient has a relative satisfactory visual acuity and the conventional perimetric tests show a complete loss of VF, the patient may still have an intact VF of 3° around the fixation point.^[8,15,16] However, we did not perform microperimetry testing in our patients. Second, the two patients with bitemporal hemianopia in our study that had more favorable outcomes were both younger than the two that had worse outcomes. The development of a new adaptation process such as suppression or ARC might be possible and helpful in these younger patients. The management of hemifield slide diplopia is difficult due to its rarity and complexity of disease entity. Before performing surgery, it is important to consider the extent and type of the VF defects and strabismus, the presence of ARC or suppression, and to undertake the prism adaptation test to imitate the postoperative functional result and risk of diplopia.

Conclusion

We present seven patients with diplopia and VF defects without new-onset motor dysfunction. This hemifield-slide phenomenon results from heteronymous hemianopia or altitudinal visual defects is difficult to correct. Sensory abnormalities usually persist even after elimination of ocular misalignment.

Financial support and sponsorship

Nil.

Conflicts of interest

The authors have no any conflicts of interest to declare.

References

1. Danchaivijitr C, Kennard C. Diplopia and eye movement disorders. *J Neurol Neurosurg Psychiatry* 2004;75 Suppl 4:iv24-31.
2. van Waveren M, Jägle H, Besch D. Management of strabismus with hemianopic visual field defects. *Graefes Arch Clin Exp Ophthalmol* 2013;251:575-84.
3. Anderson DL, Lloyd LA. Traumatic lesions of the optic chiasma: A report of four cases. *Can Med Assoc J* 1964;90:110-5.
4. Pula JH, Fischer M, Kattah JC. Hemifield slide from traumatic optic chiasmopathy. *J Clin Neurosci* 2014;21:1446-7.
5. Murad-Kejbou S, Eggenberger E. Pituitary apoplexy: Evaluation, management, and prognosis. *Curr Opin Ophthalmol* 2009;20:456-61.
6. Borchert MS, Lessell S, Hoyt WF. Hemifield slide diplopia from altitudinal visual field defects. *J Neuroophthalmol* 1996;16:107-9.
7. Peli E, Satgunam P. Bitemporal hemianopia; its unique binocular complexities and a novel remedy. *Ophthalmic Physiol Opt* 2014;34:233-42.
8. Hirai T, Ito Y, Arai M, Ota Y, Kojima T, Sato M, *et al.* Loss of stereopsis with optic chiasmal lesions and stereoscopic tests as a differential test. *Ophthalmology* 2002;109:1692-702.
9. Hiromi Hayashi KY. Binocular functions on patients with retinitis pigmentosa. *Int Congr Ser* 2005;1282:564-7.
10. Stone J, Fukuda Y. The naso-temporal division of the cat's retina re-examined in terms of Y-, X- and W-cells. *J Comp Neurol* 1974;155:377-94.
11. Fukuda Y, Sawai H, Watanabe M, Wakakuwa K, Morigiwa K. Nasotemporal overlap of crossed and uncrossed retinal ganglion cell projections in the Japanese monkey (*Macaca fuscata*). *J Neurosci* 1989;9:2353-73.
12. Marzi CA, Mancini F, Sperandio I, Savazzi S. Evidence of midline retinal nasotemporal overlap in healthy humans: A model for foveal sparing in hemianopia? *Neuropsychologia* 2009;47:3007-11.
13. Leff A. A historical review of the representation of the visual field in primary visual cortex with special reference to the neural mechanisms underlying macular sparing. *Brain Lang* 2004;88:268-78.
14. Reinhard J, Trauzettel-Klosinski S. Nasotemporal overlap of retinal ganglion cells in humans: A functional study. *Invest Ophthalmol Vis Sci* 2003;44:1568-72.
15. Mendoza-Santiesteban CE, Lopez-Felipe D, Fernández-Cherkasova L, Hernandez-Echavarría O, Hernandez-Silva Y, Gonzalez-García A. Microperimetry in the study of neuro-ophthalmic diseases. *Semin Ophthalmol* 2010;25:136-43.
16. Acton JH, Greenstein VC. Fundus-driven perimetry (microperimetry) compared to conventional static automated perimetry: Similarities, differences, and clinical applications. *Can J Ophthalmol* 2013;48:358-63.