

Anterior Subcutaneous Transposition of the Ulnar Nerve Affects Elbow Range of Motion: A Mean 13.5 Years of Follow-up

Xing-Hua Liu¹, Mao-Qi Gong¹, Yang Wang¹, Chang Liu², Shao-Liang Li¹, Xie-Yuan Jiang¹

¹Department of Orthopedic Trauma, Beijing Jishuitan Hospital, Beijing 100035, China

²Department of Hand Surgery, Beijing Jishuitan Hospital, Beijing 100035, China

Abstract

Background: Surgical decompression of the ulnar nerve is effective for cubital tunnel syndrome. However, deep approaches may result in iatrogenic elbow stiffness. This long-term study was to evaluate the range of motion (ROM) of the elbow and functional outcomes after anterior subcutaneous transposition.

Methods: A total of 115 patients (78 male and 37 female; mean age: 46.6 years) who underwent anterior subcutaneous transposition of the ulnar nerve between 2001 and 2005 were evaluated retrospectively; mean follow-up was 13.5 years. Elbow ROM was measured as flexion arc, flexion, and extension preoperatively and at the final follow-up, and compared via a mixed analysis of variance adjusting for age. Neuropathy was assessed preoperatively using a modified McGowan neuropathy grade and postoperatively using modified Wilson–Kroot criteria. An ordinal logistic regression analysis used postoperative modified Wilson–Kroot criteria as the outcome and preoperative factors as predictors.

Results: Preoperative McGowan grades were Grade 1 in 14 patients (12.2%), Grade 2A in 28 (24.3%), Grade 2B in 53 (46.1%), and Grade 3 in 20 (17.4%) patients. Postoperatively, 66 patients (57.4%) had excellent results, 26 (22.6%) had good results, 16 (13.9%) had fair results, and 7 (6.1%) had poor results at the final follow-up, as per the Wilson–Kroot criteria. There were no complications. Pre- and postoperative elbow ROM was significantly decreased in patients with previous trauma or surgery of the elbow compared with those without ($P < 0.05$). Anterior subcutaneous transposition of the ulnar nerve did not significantly affect elbow ROM regardless of previous trauma or surgical history nor preoperative ROM ($P > 0.05$), after adjusting for age. Patients with prolonged symptoms prior to surgery and worse neuropathy tended to have less satisfactory functional outcomes ($P < 0.05$), after adjusting for covariates.

Conclusions: Anterior subcutaneous transposition of the ulnar nerve is an effective and reliable treatment of cubital tunnel syndrome with satisfactory outcomes and minimal effect on elbow ROM.

Key words: Cubital Tunnel Syndrome; Elbow Stiffness; Neuropathy; Transposition; Ulnar Nerve

INTRODUCTION

Ulnar nerve entrapment at the elbow, generally defined as cubital tunnel syndrome, represents the second most common compression neuropathy of the upper extremity.^[1-3] Etiology varies from either static factors due to bony and soft-tissue disorders (including osteoarthritis, cubitus valgus, ganglion, tumor, facial strictures, or accessory muscle) or dynamic components, such as minor repetitive injury secondary to increasing pressure within the cubital canal during elbow flexion or subluxation of the ulnar nerve.^[2,4-6]

Presenting symptoms range from numbness and tingling in the ulnar nerve distribution, often accompanied by weakness of the grip, to clawed fingers and occasionally

Address for correspondence: Dr. Xie-Yuan Jiang,
Department of Orthopedic Trauma, Beijing Jishuitan Hospital, Beijing
100035, China
E-Mail: jxy0845@sina.com

This is an open access article distributed under the terms of the Creative Commons Attribution-NonCommercial-ShareAlike 3.0 License, which allows others to remix, tweak, and build upon the work non-commercially, as long as the author is credited and the new creations are licensed under the identical terms.

For reprints contact: reprints@medknow.com

© 2018 Chinese Medical Journal | Produced by Wolters Kluwer - Medknow

Received: 15-09-2017 **Edited by:** Yi Cui

How to cite this article: Liu XH, Gong MQ, Wang Y, Liu C, Li SL, Jiang XY. Anterior Subcutaneous Transposition of the Ulnar Nerve Affects Elbow Range of Motion: A Mean 13.5 Years of Follow-up. Chin Med J 2018;131:282-8.

Access this article online

Quick Response Code:



Website:
www.cmj.org

DOI:
10.4103/0366-6999.223851

severe intrinsic wasting.^[3] If adequate conservative nonsurgical treatment fails to relieve progressive symptoms and dysfunction, surgical decompression is indicated, typically involving either superficial approaches (*in situ* decompression and anterior subcutaneous transposition) or deep approaches (medial epicondylectomy or anterior sub- or intramuscular transposition).^[7-13]

Elbow stiffness, another well-known disabling disorder, brings huge challenges to elbow specialists.^[14,15] It has been reported that elbow stiffness may occur in 5–10% of cases after use of deep approaches.^[16-19] However, there have been few studies that have reviewed whether elbow stiffness develops after a superficial approach, i.e., anterior subcutaneous transposition. In this study, we retrospectively reviewed long-term alterations in elbow range of motion (ROM) and functional outcomes of patients who underwent anterior subcutaneous transposition of the ulnar nerve for cubital tunnel syndrome.

METHODS

Ethical approval

The study protocol was approved by the Hospital Ethics Committee of Beijing Jishuitan Hospital and informed consent was obtained from all patients before their enrolment at the final follow-up.

Patients

A total of 134 consecutive patients with unilateral cubital tunnel syndrome who underwent anterior subcutaneous transposition of the ulnar nerve between 2001 and 2005 were retrospectively evaluated. At the final follow-up, six patients were excluded for the following reasons: concomitant cervical radiculopathy, carpal tunnel syndrome, elbow surgery for fractures, uncontrolled thyroid abnormalities, diabetes, or chronic renal failure. Four patients died from comorbidities and nine patients were lost to follow-up. This resulted in 115 patients who qualified for analysis: 78 males and 37 females with a mean age of 46.6 years (range: 12–72 years). Of these, 40 patients had previous elbow trauma or surgery, including elbow dislocation, radial head fracture, olecranon fracture, Monteggia fracture, distal humeral fracture, and unknown injuries treated either by nonoperative or open reduction internal fixation at least one year before, without obvious infection, elbow deformity, instability, or remaining stiffness. The dominant side was involved in 65 patients. The mean elbow ROM variables (measured by flexion arc, flexion, and extension) were 139.4°, 142.9°, and –4.0°, respectively. All patients had conservative treatment for at least 6 weeks before surgery. The mean preoperative duration of symptoms to surgical consultation was 23.8 months (range: 1.5–240.0 months). All operations were performed by the same surgical team. All patients were reviewed by an independent observer at an average of 13.5 years (range: 12–16 years) postoperatively [Table 1].

The precise clinical diagnosis of cubital tunnel syndrome was based on a thorough history, imperative physical

Table 1: Patient demographics and clinical characteristics

Variables	Data (n = 115)
Gender, n (%)	
Male	78 (67.8)
Female	37 (32.2)
Age (years), mean (range)	46.6 (12–72)
Surgery on the dominant side, n (%)	65 (56.5)
T/S history, n	40
Nonsurgical, by plaster/splint	23
Elbow dislocation	12
Radial head fracture	5
Unknown	6
ORIF	17
Olecranon fracture	8
Distal humeral fracture	5
Monteggia fracture	3
Radial head fracture	1
Elbow ROM (°), mean (range)	
Flexion arc	139.5 (105.0–145.0)
Flexion	143.1 (120.0–145.0)
Extension	–3.7 (–30.0–0)
Duration of symptoms (months), mean (range)	23.8 (1.5–240.0)
Follow-up time (years), mean (range)	13.5 (12–16)

T/S: Trauma or surgical; ORIF: Open reduction internal fixation; ROM: Range of motion.

examination including inspection of the clawed posture of the hand, sensory evaluation of the ulnar innervation, two-point discrimination, motor function by grading of intrinsic muscle power, check for a positive Tinel's sign, an elbow flexion test, and Froment's sign, sequentially confirmed through electromyography (EMG) and nerve conduction studies. Findings were considered to be positive for diagnosis by abnormally prolonged motor conduction velocity and sensory conduction velocity, often accompanied with pathological findings on EMG, including fibrillation activity, decreased recruitment, and abnormalities in the configuration of the motor unit action potential.^[20] Recently, short-segment nerve conduction studies (the inching test) have been shown to detect lesions of compressive neuropathy more precisely and may predict prognosis to a certain extent.^[21]

All preoperative electrodiagnostic test data were collected; however, no patients consented to re-examine the invasive electrodiagnostic test at the final follow-up. Radiographs of the elbow and the cervical spine were evaluated to rule out additional pathology, especially obvious heterotopic ossification, osteoarthritis, and internal fixation failure for those having previous elbow surgical history. Further laboratory tests were evaluated for those suffering systemic disorders and in consideration of postoperative infections. Patients were classified into four grades according to the modified McGowan system [Figure 1].^[22,23] Results at the final follow-up were also graded according to the modified Wilson–Krout criteria [Figure 2].^[24]

Surgical technique

All patients had a brachial plexus block with pneumatic tourniquet hemostasis during the procedure. This procedure is simpler to perform than deep transpositions, and it is warranted to ensure thorough release; all possible constriction sites must be double checked with careful dissection to protect the vascular bundles of the ulnar nerve and to preserve the motor branches to the flexor carpi ulnaris and flexor digitorum profundus [Figure 3]. A fasciodermal sling sutured over the medial epicondyle was created to hold the ulnar nerve in position [Figure 4]. Adherence and scarring of the surrounding tissues was observed in patients with internal fixation, especially through a medial surgical approach of the elbow. The elbow was allowed immediate ROM exercises postoperatively. No complications occurred.

Statistical analysis

Statistical analyses were performed using the SPSS version 24.0 statistical package (IBM Corp., Armonk, NY, USA). The preoperative and final follow-up elbow ROMs as continuous variables were compared through a mixed analysis of variance (ANOVA) between patients with and without trauma/surgical history, adjusting for

age, thus evaluating the within-subjects effect of anterior subcutaneous transposition of the ulnar nerve and the between-subjects effect of trauma/surgical history on elbow ROMs. Subsequently, ordinal logistic regression analysis, an adequate model for ordinal categorical outcome variables, was performed to evaluate the association of postoperative modified Wilson–Kroot criteria with preoperative variables including age, gender, duration of symptoms, trauma/surgical history, preoperative elbow ROMs, and modified McGowan grade, which were expressed as adjusted proportional odds ratios (ORs) with 95% confidence intervals (CIs). In the mixed ANOVA and ordinal logistic regression analysis, all the variables were chosen based on clinical judgment. Statistical significance was accepted for $P < 0.05$.

RESULTS

Postoperatively, 66 patients (57.4%) had excellent results, 26 (22.6%) had good results, 16 (13.9%) had fair results, and 7 (6.1%) had poor results at the final follow-up, as per the Wilson–Kroot criteria [Figure 2].

The mean elbow ROMs and the differences between patients with and without trauma/surgical history pre- and postoperatively are shown in Table 2, and the variation directly displayed in profile plots [Figure 5].

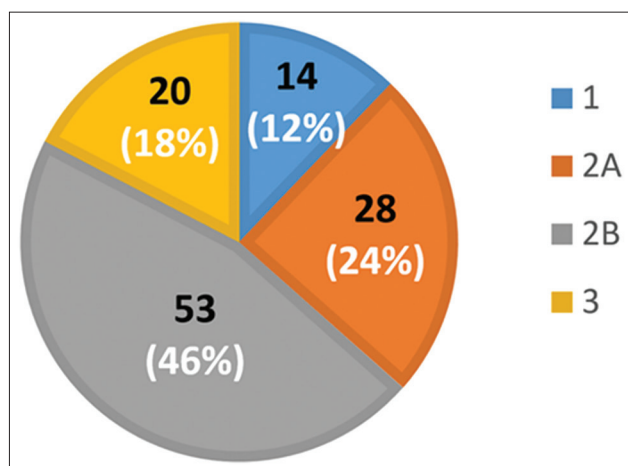


Figure 1: Preoperative modified McGowan grading of patients.

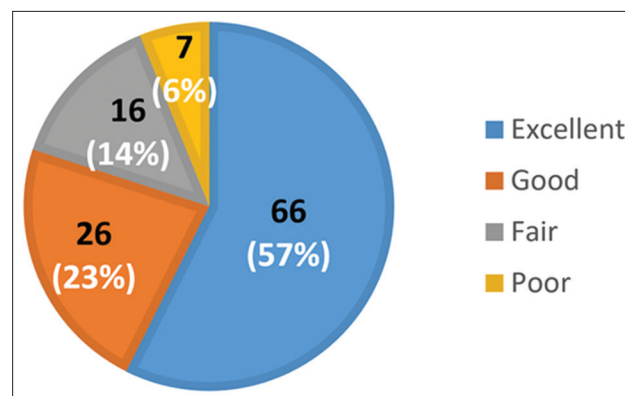


Figure 2: Postoperative modified Wilson–Kroot grading of patients.

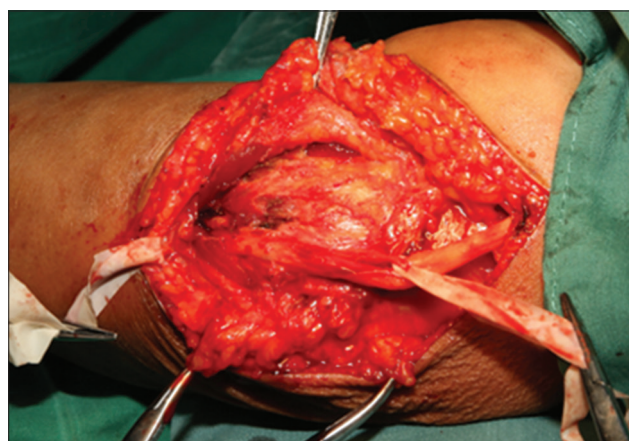


Figure 3: Thorough release of ulnar nerve.

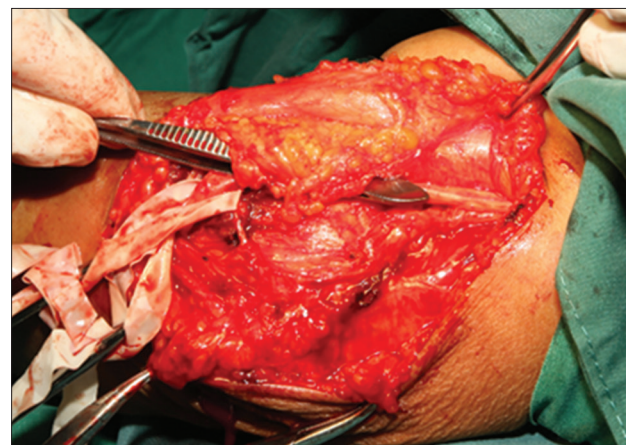


Figure 4: Subcutaneous transposition of ulnar nerve held by fasciodermal sling in position.

The mixed ANOVA adjusted for age showed that there was a significant difference in the between-subject effect of trauma/surgical history on ROMs ($P < 0.05$). However, there was no significant difference in the within-subject effect of the anterior subcutaneous transposition of the ulnar nerve in ROMs ($P > 0.05$) [Table 2].

After adjusting for age, gender, trauma/surgical history, and preoperative elbow ROMs, the results of the ordinal logistic regression analyses showed an association

between preoperative variables and postoperative modified Wilson–Kruot criteria [Table 3].

There was no significant association between postoperative modified Wilson–Kruot criteria and age ($OR = 0.992$, $P = 0.395$), gender ($OR = 0.841$, $P = 0.531$), trauma/surgical history ($OR = 1.066$, $P = 0.834$), or preoperative elbow ROMs ($OR = 0.983$, $P = 0.350$).

Patients with prolonged duration of symptoms prior to surgery were significantly associated with worse postoperative

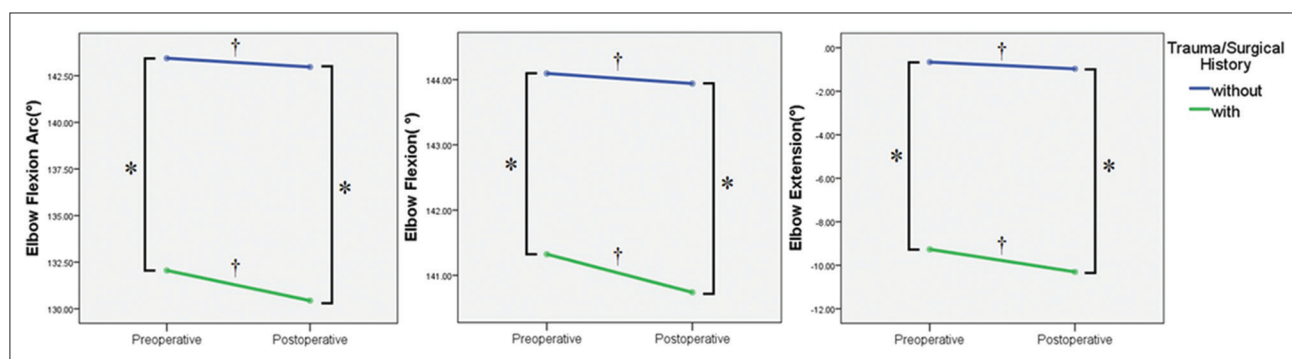


Figure 5: Profile plots of elbow ROMs (flexion, extension, and flexion arc) showing the pre- and postoperative differences between patients with and without trauma/surgical history. * $P < 0.05$, elbow ROMs significantly different between patients. † $P > 0.05$, elbow ROMs not significantly different within patients. ROMs: Range of motions.

Table 2: Mixed ANOVA results for ROM measurements, adjusted for age, mean \pm SD ($^{\circ}$)

Elbow ROM variables	T/S history		P	
	With	Without	Within subjects	Between subjects
Flexion arc				
Preoperative	131.6 \pm 11.3	143.7 \pm 3.8	0.095	<0.001*
Postoperative	129.9 \pm 13.6	143.3 \pm 4.8		
Flexion				
Preoperative	141.1 \pm 5.8	144.2 \pm 2.7	0.410	<0.001*
Postoperative	140.5 \pm 6.7	144.1 \pm 2.9		
Extension				
Preoperative	-9.5 \pm 9.6	-0.5 \pm 2.3	0.113	<0.001*
Postoperative	-10.6 \pm 11.4	-0.8 \pm 3.2		

* $P < 0.05$ considered statistically significant. ANOVA: Analysis of variance; ROM: Range of motion; T/S: Trauma or surgical; SD: Standard deviation.

Table 3: Results of ordinal logistic regression analyses showing association between preoperative variables and postoperative modified Wilson–Kruot criteria

Variables	B	SE	Wald	OR (95% CI)	P
Age	-0.008	0.10	0.724	0.992 (0.972–1.011)	0.395
Gender	-0.173	0.275	0.393	0.841 (0.491–1.443)	0.531
Trauma/surgical history	-0.064	0.306	0.044	1.066 (0.586–1.940)	0.834
Preoperative elbow ROM	-0.017	0.019	0.873	0.983 (0.947–1.019)	0.350
Preoperative duration of symptoms	0.015	0.005	10.050	1.015 (1.006–1.024)	0.002*
Modified McGowan grade					
1	-2.744	0.763	12.949	0.064 (0.014–0.287)	<0.001*
2A	-1.550	0.445	12.123	0.212 (0.089–0.508)	<0.001*
2B	-0.786	0.392	4.026	0.456 (0.211–0.982)	0.045*
3					

Link function: Complementary log-log. Model fitting information $P < 0.001$. Pseudo $R^2 \geq 0.889$. Test of parallel lines $P = 1.000$. * $P < 0.05$ considered statistically significant. B: Standardized coefficients; SE: Standard error; Wald: Wald Chi-square test; OR: Odds ratio; CI: Confidence interval; ROM: Range of motion.

modified Wilson–Kroot criteria results, adjusting for age, gender, trauma/surgical history, and preoperative elbow ROMs ($OR = 1.015, P = 0.002$).

Compared with patients with modified McGowan Grade 3, the odds of having at a modified Wilson–Kroot criteria result at least one grade better were 0.064 times larger for patients evaluated as modified McGowan Grade 1 ($P < 0.001$), 0.212 times larger for Grade 2A ($P < 0.001$), and 0.456 times larger for Grade 2B ($P = 0.045$) [Figure 6].

DISCUSSION

It is well known that ulnar nerve entrapment at the elbow, known as cubital tunnel syndrome, has been identified as a frequently disabling upper-extremity sensory and motor disorder. The ulnar nerve may be compressed at five anatomical sites proximally to distally: at the arcade of Struthers, the medial intermuscular septum, epicondylar groove, Osborne’s ligament (the roof of the actual boundary of the cubital tunnel), and flexor-pronator aponeurosis; the epicondylar groove and Osborne’s ligament are the most frequent areas.^[2,25] The effective surgical treatment for nerve entrapment is timely decompression, involving several controversial approaches typically involving one of the following: *in situ* decompression (open or endoscopic), medial epicondylectomy, or anterior transposition (subcutaneous, submuscular, or intramuscular).^[7-13] None of these are considered superior to the others. According to current clinical evidence, there is no significant difference between simple decompression of the nerve and decompression with either subcutaneous or deep transposition.^[17,18,26-30]

The cubital tunnel has been shown to normally change its shape from ovoid to elliptic during the process of elbow flexing, thus decreasing its volume by 55% and increasing the pressure inside and outside the ulnar nerve within the cubital tunnel.^[31-34] The ulnar nerve was found to elongate between 4 mm and 7 mm upon flexion of the elbow due to the nerve’s curving located away from elbow’s center of rotation. Therefore, traction on the ulnar nerve during elbow

flexion makes it more vulnerable to entrapment.^[35] The extraneural pressure on the nerve may be eliminated by either simple decompression or anterior transposition, whereas the intraneural pressure remains unchanged, reaching 45% greater than the extraneural pressure inside the tunnel and 63% greater than the extraneural pressure at 4 cm proximal to the tunnel with the elbow flexed at 130°.^[4,5,36] Furthermore, the ulnar nerve also suffers from strain, which pressure-relief *in situ* cannot alter. On the contrary, anterior transposition may relieve strain with elbow flexion while increasing no extra strain with elbow extension.^[37] Therefore, there seems to be a tendency toward improved clinical outcomes with nerve transposition compared with simple decompression, due to cubital tunnel syndrome being successfully managed as both a compression and a traction neuropathy.^[26,38]

Elbow stiffness is another well-recognized disabling condition impairing upper-limb function, with occurrence in nearly 12% of patients after mild trauma, minor surgery, delayed rehabilitation, or prolonged immobilization.^[14,15,39] Elbow stiffness as a sequel should be considered when performing any minor surgery of the elbow, which is likely attributable to mast cell degranulation stimulated by neuropeptide substance-P and calcitonin-G-related peptide released from nerve terminals in response to injury and pain, thus stimulating myofibroblasts causing collagen contraction in the joint capsule.^[40-43] There have been reports in the literature of stiffness occurring in 5–10% of cases after surgical decompression of the ulnar nerve due to damage of the collateral ulnar ligament, excessive fibrosis formation in the soft tissue, or prolonged postoperative immobilization after medial epicondylectomy or deep transposition.^[16-19] In contrast, the anterior subcutaneous approach is recognized to be the most minimally invasive method among these procedures, without damage to the bony structures, deep muscular components, or the collateral ulnar ligament, with the same functional outcome and without postoperative immobilization.^[44]

In this long-term study, we found that the pre- and postoperative elbow ROMs were more significantly decreased in patients with previous trauma or surgery compared with those without such history [between-subject effect, $P < 0.05$, Table 2]. As mentioned, any trauma or surgery that damaged the bony structure along with soft tissue may result in articular incongruity, damage of the collateral ulnar ligament, or excessive fibrosis formation. All of these conditions contribute to limited motion of the elbow joint. However, no patients had flexion $< 130^\circ$ or limitation of extension of $> 30^\circ$; therefore, none had an indication for open release through the medial approach either.^[45,46]

In addition, surgery of the anterior subcutaneous transposition of the ulnar nerve did not significantly affect elbow ROMs regardless of previous trauma or surgery or preoperative ROM status [within-subject effect, $P > 0.05$, Table 2], which seems to be common sense, but has rarely been discussed in literature. Even patients with past trauma or surgery who were truly susceptible to elbow stiffness did not have a

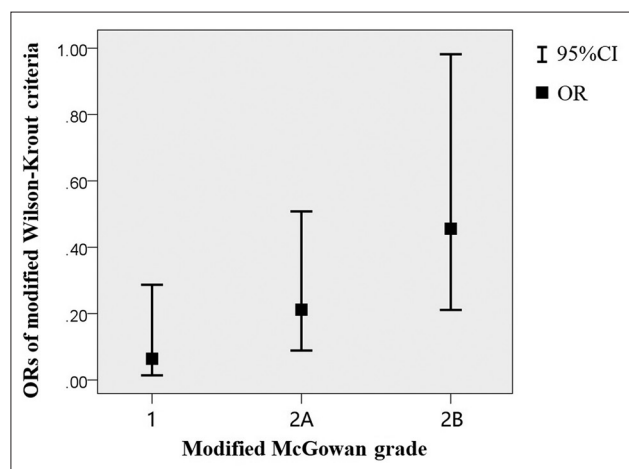


Figure 6: Correlation between modified McGowan grade and modified Wilson–Kroot criteria. *OR*: Odds ratio; *CI*: Confidence interval.

significant decrease in ROM [within-subject effect, $P > 0.05$, Table 2].

We are also concerned with another challenging scenario, the surgical management of elbow stiffness. If ulnar nerve symptoms are present prior to operative release, nerve decompression is performed simultaneously, especially when flexion contractures are more than 100° . Due to the contracture of Osborne's ligament and the posterior band of the medial collateral ligament (which increases in length by 9 mm between 60° and 120° of flexion), a stretch injury of the nerve could be generated that would exacerbate ulnar nerve symptoms with gains in flexion.^[15,45,47,48] If there is nerve instability, it is usually anterior subcutaneous transposition rather than deep transposition, which may impair the outcome of the surgical release or increase the recurrence of stiffness.^[43]

Furthermore, in this long-term study, we found that patients with a prolonged duration of presurgical symptoms and a poor modified McGowan grade tended to have less satisfactory functional outcomes as per the modified Wilson-Krout criteria [$P < 0.05$, Table 3]. From data regarding preoperative modified McGowan grades, 64% of patients had a grade more severe than Grade 2B [Figure 1], which was mainly attributed to patients in our Jishuitan Hospital, one of the most established orthopedic hospitals in China, were often in advanced stages of the disease after traveling around the country seeking a medical consultation. Moreover, the relatively poor results of anterior subcutaneous transposition reported in some of the literature could be ascribed to the preference for this relatively less invasive approach for chronic patients with a prolonged duration of symptom and advanced stages with irreversible intrinsic nerve damage, resulting in a misleading selection bias.^[38]

There are several inadequacies associated with our method. The follow-up times ought to be more frequent. More functional scores should be measured pre- and postoperatively to increase statistical accuracy. In addition, further EMG and kinematic data should be collected in high-level designed studies.

In conclusion, anterior subcutaneous transposition of the ulnar nerve is an effective and reliable approach using a simplified surgical technique, with low complication rates, early postoperative mobilization, minimal effect on elbow ROM, and satisfactory functional outcomes for the treatment of cubital tunnel syndrome. The procedure is especially suitable for patients susceptible to elbow stiffness when suffering cubital tunnel syndrome. Further prospective, randomized studies regarding the correlation between different ulnar nerve decompression and transposition approaches and elbow stiffness might add a higher level of evidence to this finding and enhance our comprehension of elbow disorders.

Financial support and sponsorship

Nil.

Conflicts of interest

There are no conflicts of interest.

REFERENCES

1. Green D, Hotchkiss RN, Pederson WC, Wolfe SW. Green's Operative Hand Surgery. 5th ed. USA: Churchill Livingstone; 2005. p. 1024-43.
2. Elhassan B, Steinmann SP. Entrapment neuropathy of the ulnar nerve. *J Am Acad Orthop Surg* 2007;15:672-81. doi: 10.5435/00124635-200711000-00006.
3. Staples JR, Calfee R. Cubital tunnel syndrome: Current concepts. *J Am Acad Orthop Surg* 2017;25:e215-24. doi: 10.5435/JAAOS-D-15-00261.
4. Gelberman RH, Yamaguchi K, Hollstien SB, Winn SS, Heidenreich FP Jr., Bindra RR, et al. Changes in interstitial pressure and cross-sectional area of the cubital tunnel and of the ulnar nerve with flexion of the elbow. An experimental study in human cadavera. *J Bone Joint Surg Am* 1998;80:492-501. doi: 10.2106/00004623-199804000-00005.
5. Patel VV, Heidenreich FP Jr., Bindra RR, Yamaguchi K, Gelberman RH. Morphologic changes in the ulnar nerve at the elbow with flexion and extension: A magnetic resonance imaging study with 3-dimensional reconstruction. *J Shoulder Elbow Surg* 1998;7:368-74. doi: 10.1016/s1058-2746(98)90025-8.
6. Nakano K, Murata K, Omokawa S, Nakanishi Y, Shimizu T, Kira T, et al. Dynamic analysis of the ulnar nerve in the cubital tunnel using ultrasonography. *J Shoulder Elbow Surg* 2014;23:933-7. doi: 10.1016/j.jse.2014.01.039.
7. Svernlöv B, Larsson M, Rehn K, Adolfsson L. Conservative treatment of the cubital tunnel syndrome. *J Hand Surg Eur Vol* 2009;34:201-7. doi: 10.1177/1753193408098480.
8. Osborne G. Compression neuritis of the ulnar nerve at the elbow. *Hand* 1970;2:10-3. doi: 10.1016/0072-968x(70)90027-6.
9. Tsai TM, Chen IC, Majd ME, Lim BH. Cubital tunnel release with endoscopic assistance: Results of a new technique. *J Hand Surg Am* 1999;24:21-9. doi: 10.1053/jhsu.1999.jhsu25a0021.
10. Danoff JR, Lombardi JM, Rosenwasser MP. Use of a pedicled adipose flap as a sling for anterior subcutaneous transposition of the ulnar nerve. *J Hand Surg Am* 2014;39:552-5. doi: 10.1016/j.jhsa.2013.12.005.
11. Hicks D, Toby EB. Ulnar nerve strains at the elbow: The effect of *in situ* decompression and medial epicondylectomy. *J Hand Surg Am* 2002;27:1026-31. doi: 10.1053/jhsu.2002.35870.
12. Lancigu R, Saint Cast Y, Raimbeau G, Rabarin F, Dellon's anterior submuscular transposition of the ulnar nerve: Retrospective study of 82 operated patients with 11.5 years' follow-up. *Chir Main* 2015;34:234-9. doi: 10.1016/j.main.2015.08.001.
13. Henry M. Modified intramuscular transposition of the ulnar nerve. *J Hand Surg Am* 2006;31:1535-42. doi: 10.1016/j.jhsa.2006.04.016.
14. Morrey BF. The posttraumatic stiff elbow. *Clin Orthop Relat Res* 2005;431:26-35. doi: 10.1097/01.blo.0000152366.58660.ea.
15. Jupiter JB, O'Driscoll SW, Cohen MS. The assessment and management of the stiff elbow. *Instr Course Lect* 2003;52:93-111.
16. O'Driscoll SW, Jalszynski R, Morrey BF, An KN. Origin of the medial ulnar collateral ligament. *J Hand Surg Am* 1992;17:164-8. doi: 10.1016/0363-5023(92)90135-c.
17. Ruchelsman DE, Lee SK, Posner MA. Failed surgery for ulnar nerve compression at the elbow. *Hand Clin* 2007;23:359-71, vi-vii. doi: 10.1016/j.hcl.2007.06.004.
18. Gabel GT, Amadio PC. Reoperation for failed decompression of the ulnar nerve in the region of the elbow. *J Bone Joint Surg Am* 1990;72:213-9. doi: 10.2106/00004623-199072020-00008.
19. Janes PC, Mann RJ, Farnworth TK. Submuscular transposition of the ulnar nerve. *Clin Orthop Relat Res* 1989;238:225-32. doi: 10.1097/0003086-198901000-00033.
20. Practice parameter: Electrodiagnostic studies in ulnar neuropathy at the elbow. American Association of Electrodiagnostic Medicine, American Academy of Neurology, and American Academy of Physical Medicine and Rehabilitation. *Neurology* 1999;52:688-90. doi: 10.1212/wnl.52.4.688.
21. Liu Z, Jia ZR, Wang TT, Shi X, Liang W. Preliminary study on the

- lesion location and prognosis of cubital tunnel syndrome by motor nerve conduction studies. *Chin Med J* 2015;128:1165-70. doi: 10.4103/0366-6999.156100.
22. McGowan AJ. The results of transposition of the ulnar nerve for traumatic ulnar neuritis. *J Bone Joint Surg Br* 1950;32-B:293-301.
 23. Goldberg BJ, Light TR, Blair SJ. Ulnar neuropathy at the elbow: Results of medial epicondylectomy. *J Hand Surg Am* 1989;14:182-8. doi: 10.1016/0363-5023(89)90003-8.
 24. Wilson DH, Krout R. Surgery of ulnar neuropathy at the elbow: 16 cases treated by decompression without transposition. Technical note. *J Neurosurg* 1973;38:780-5. doi: 10.3171/jns.1973.38.6.0780.
 25. Campbell WW, Pridgeon RM, Riaz G, Astruc J, Sahni KS. Variations in anatomy of the ulnar nerve at the cubital tunnel: Pitfalls in the diagnosis of ulnar neuropathy at the elbow. *Muscle Nerve* 1991;14:733-8. doi: 10.1002/mus.880140807.
 26. Macadam SA, Gandhi R, Bezuhly M, Lefavre KA. Simple decompression versus anterior subcutaneous and submuscular transposition of the ulnar nerve for cubital tunnel syndrome: A meta-analysis. *J Hand Surg Am* 2008;33:1314.e1-12. doi: 10.1016/j.jhssa.2008.03.006.
 27. Kleinman WB. Cubital tunnel syndrome: Anterior transposition as a logical approach to complete nerve decompression. *J Hand Surg Am* 1999;24:886-97. doi: 10.1053/jhsu.1999.0886.
 28. Zlowodzki M, Chan S, Bhandari M, Kalliainen L, Schubert W. Anterior transposition compared with simple decompression for treatment of cubital tunnel syndrome. A meta-analysis of randomized, controlled trials. *J Bone Joint Surg Am* 2007;89:2591-8. doi: 10.2106/JBJS.G.00183.
 29. Caliendo P, La Torre G, Padua R, Giannini F, Padua L. Treatment for ulnar neuropathy at the elbow. *Cochrane Database Syst Rev* 2016;11:CD006839. doi: 10.1002/14651858.CD006839.
 30. O'Grady EE, Vanat Q, Power DM, Tan S. A systematic review of medial epicondylectomy as a surgical treatment for cubital tunnel syndrome. *J Hand Surg Eur Vol* 2017;42:941-5. doi: 10.1177/1753193417724351.
 31. Apfelberg DB, Larson SJ. Dynamic anatomy of the ulnar nerve at the elbow. *Plast Reconstr Surg* 1973;51:79-81.
 32. Macnicol MF. Extraneural pressures affecting the ulnar nerve at the elbow. *Hand* 1982;14:5-11. doi: 10.1016/S0072-968X(82)80030-2.
 33. Pechan J, Julis I. The pressure measurement in the ulnar nerve. A contribution to the pathophysiology of the cubital tunnel syndrome. *J Biomech* 1975;8:75-9. doi: 10.1016/0021-9290(75)90045-7.
 34. Werner CO, Ohlin P, Elmquist D. Pressures recorded in ulnar neuropathy. *Acta Orthop Scand* 1985;56:404-6. doi: 10.3109/17453678508994358.
 35. Baek GH, Kwon BC, Chung MS. Comparative study between minimal medial epicondylectomy and anterior subcutaneous transposition of the ulnar nerve for cubital tunnel syndrome. *J Shoulder Elbow Surg* 2006;15:609-13. doi: 10.1016/j.jse.2005.10.007.
 36. Charles YP, Coulet B, Rouzaud JC, Daures JP, Chammas M. Comparative clinical outcomes of submuscular and subcutaneous transposition of the ulnar nerve for cubital tunnel syndrome. *J Hand Surg Am* 2009;34:866-74. doi: 10.1016/j.jhssa.2009.07.014.
 37. Mitchell J, Dunn JC, Kusnezov N, Bader J, Ipsen DF, Forthman CL, *et al.* The effect of operative technique on ulnar nerve strain following surgery for cubital tunnel syndrome. *Hand (N Y)* 2015;10:707-11. doi: 10.1007/s11552-015-9770-y.
 38. Gökay NS, Bagatur AE. Subcutaneous anterior transposition of the ulnar nerve in cubital tunnel syndrome. *Acta Orthop Traumatol Turc* 2012;46:243-9. doi: 10.3944/AOTT.2012.2836.
 39. Myden C, Hildebrand K. Elbow joint contracture after traumatic injury. *J Shoulder Elbow Surg* 2011;20:39-44. doi: 10.1016/j.jse.2010.07.013.
 40. Tomasek J, Rayan GM. Correlation of alpha-smooth muscle actin expression and contraction in Dupuytren's disease fibroblasts. *J Hand Surg Am* 1995;20:450-5. doi: 10.1016/S0363-5023(05)80105-4.
 41. Schäffer M, Beiter T, Becker HD, Hunt TK. Neuropeptides: Mediators of inflammation and tissue repair? *Arch Surg* 1998;133:1107-16. doi: 10.1001/archsurg.133.10.1107.
 42. Duggan AW, Morton CR, Zhao ZQ, Hendry IA. Noxious heating of the skin releases immunoreactive substance P in the substantia gelatinosa of the cat: A study with antibody microprobes. *Brain Res* 1987;403:345-9. doi: 10.1016/0006-8993(87)90073-4.
 43. Charalambous CP, Morrey BF. Posttraumatic elbow stiffness. *J Bone Joint Surg Am* 2012;94:1428-37. doi: 10.2106/JBJS.K.00711.
 44. Weirich SD, Gelberman RH, Best SA, Abrahamsson SO, Furcolo DC, Lins RE, *et al.* Rehabilitation after subcutaneous transposition of the ulnar nerve: Immediate versus delayed mobilization. *J Shoulder Elbow Surg* 1998;7:244-9. doi: 10.1016/S1058-2746(98)90052-0.
 45. Wada T, Ishii S, Usui M, Miyano S. The medial approach for operative release of post-traumatic contracture of the elbow. *J Bone Joint Surg Br* 2000;82:68-73. doi: 10.1302/0301-620X.82B1.9782.
 46. Morrey BF, Askew LJ, Chao EY. A biomechanical study of normal functional elbow motion. *J Bone Joint Surg Am* 1981;63:872-7. doi: 10.2106/00004623-198163060-00002.
 47. O'Driscoll SW, Horii E, Carmichael SW, Morrey BF. The cubital tunnel and ulnar neuropathy. *J Bone Joint Surg Br* 1991;73:613-7.
 48. Morrey BF, An KN. Functional anatomy of the ligaments of the elbow. *Clin Orthop Relat Res* 1985;201:84-90. doi: 10.1097/00003086-198512000-00015.