

# The “Corset Repair” for Complex Hernia: A Proof-of-concept Report of an Innovative Approach

Yasmeen M. Byrnes, BA\*  
 Sammy Othman, BA†  
 Omar Elfanagely, MD†  
 Elizabeth B. Card, BS\*  
 Joseph A. Mellia, BA†  
 Monica Llado-Farrulla, MD†  
 John P. Fischer, MD, MPH†

**Summary:** Incisional hernias, especially those below the arcuate line, pose a unique challenge to reconstructive surgeons, as no consensus exists for repair strategy. An innovative approach is presented and illustrated. The “corset repair” involves placing an onlay mesh partially beneath released bilateral external obliques. A detailed technical review is provided to illustrate the benefits of this technique particularly in large defects and in hernia after abdominal flap harvest. Hernia recurrence and surgical site occurrence rates were reviewed and analyzed for a cohort of corset repair patients between December 2016 and January 2020. Twenty patients were included. All defects were successfully closed. Zero patients experienced hernia recurrence. Eight patients (40%) had a surgical site occurrence, of which 5 (63%) were either observed or managed non-operatively. Two of the surgical site occurrences were deep surgical site infections: 1 required surgical intervention for suspected mesh infection and the other did not. One patient (5%) developed hematoma 23 months post-operatively. The “corset repair” technique represents a modification to a classic technique for hernia repair. It is feasible and may be advantageous especially for large or challenging repairs below the arcuate line. It has promising results on early follow-up, and further research is needed to evaluate long-term efficacy. (*Plast Reconstr Surg Glob Open* 2020;8:e3308; doi: [10.1097/GOX.0000000000003308](https://doi.org/10.1097/GOX.0000000000003308); Published online 16 December 2020.)

## INTRODUCTION

Large complex incisional hernias are challenging to successfully repair, and there is currently no single standardized approach.<sup>1</sup> The introduction of component separation techniques to reduce tension on the defect closure, along with the advent of mesh reinforcement, has expanded the surgical armamentarium and allowed for improved outcomes,<sup>2,3</sup> and often a combination of these 2 strategies is used. Decisions regarding mesh material and optimal plane for mesh placement are highly debated, and usually made based on individual patient anatomy. Here the authors present the “corset repair.” This approach strives to create superior strength and stability of complex hernia repairs, including those below the arcuate line, by placing an onlay biosynthetic mesh partially beneath

released bilateral external obliques (EOs), thus modifying the classic onlay technique and creating a hybrid plane.

## METHODS

This series reviewed patients with incisional hernia who underwent corset repair performed by a single plastics and reconstructive surgeon (JPF) between December 2016 and January 2020. Patient data were collected through review of medical records.

The procedure begins by making incisions along the prior abdominal scar and raising wide soft tissue flaps. The hernia defect(s) are identified and marked, and the herniated contents are dissected out and reduced. For the patients in this series, a tension-free primary closure is not initially possible, thus a bilateral anterior component separation is performed. (See [Video 1 \[online\]](#), which displays a step-by-step demonstration of the corset repair

From the \*Perelman School of Medicine, University of Pennsylvania, Philadelphia, Pa.; and †Division of Plastic Surgery, Department of Surgery, University of Pennsylvania, Philadelphia, Pa.

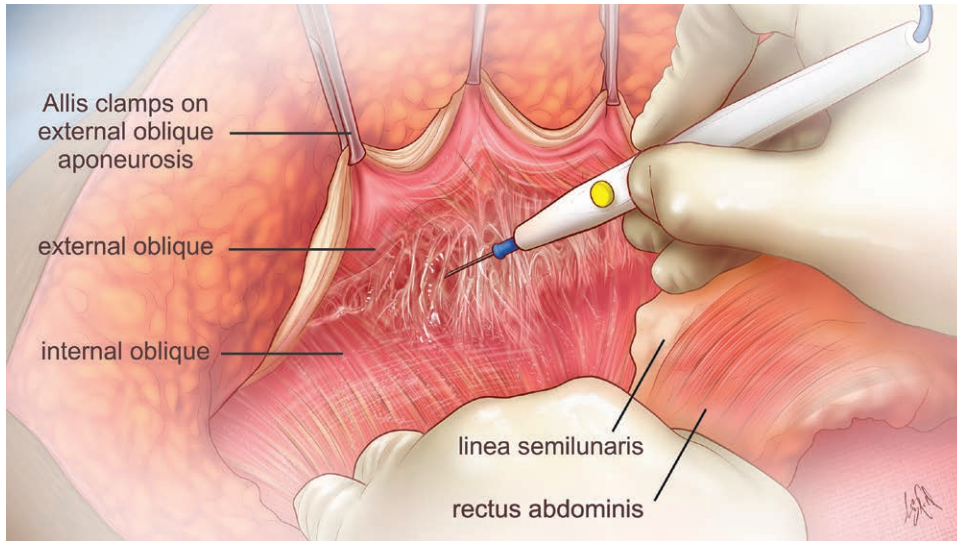
Received for publication July 20, 2020; accepted October 26, 2020.

Copyright © 2020 The Authors. Published by Wolters Kluwer Health, Inc. on behalf of The American Society of Plastic Surgeons. This is an open-access article distributed under the terms of the [Creative Commons Attribution-Non Commercial-No Derivatives License 4.0 \(CCBY-NC-ND\)](https://creativecommons.org/licenses/by-nc-nd/4.0/), where it is permissible to download and share the work provided it is properly cited. The work cannot be changed in any way or used commercially without permission from the journal.

DOI: [10.1097/GOX.0000000000003308](https://doi.org/10.1097/GOX.0000000000003308)

**Disclosure:** Dr. John P. Fischer has received consulting payments from Baxter, Becton-Dickinson, Allergan, Gore, and Integra Life Sciences. The other authors have no financial interest to declare in relation to the content of this article. No support was received for this work.

Related Digital Media are available in the full-text version of the article on [www.PRSGlobalOpen.com](http://www.PRSGlobalOpen.com).



**Fig. 1.** Dissection of the plane between the external oblique and internal oblique.

technique.) A longitudinal incision is made in the EO aponeurosis, and the EO is carefully dissected off the internal oblique (IO) (Fig. 1). (See Video 1 [online].) After the EO release is completed, a herniorrhaphy is performed without tension.

Next, the repair is reinforced with a large piece of poly-4-hydroxybutyrate biosynthetic mesh. To maintain proper vertical orientation during subsequent handling, the mesh is first anchored to the periosteum of the xiphoid process and the pubic symphysis with U stitches. (See Video 1 [online].)

The lateral portions of the mesh are trimmed and placed in the plane between the EO and IO (Fig. 2). The EO myofascial flaps are draped over the mesh, with the cut edges resting above their native location. The lateral edges of the mesh are fixed to the EOs above, but not to the IOs below, with a series of interrupted U stitches. Finally, the medial cut edges of the flaps are sutured to the mesh. (See Video 1 [online].) Two to three drains are placed and the abdomen is closed.

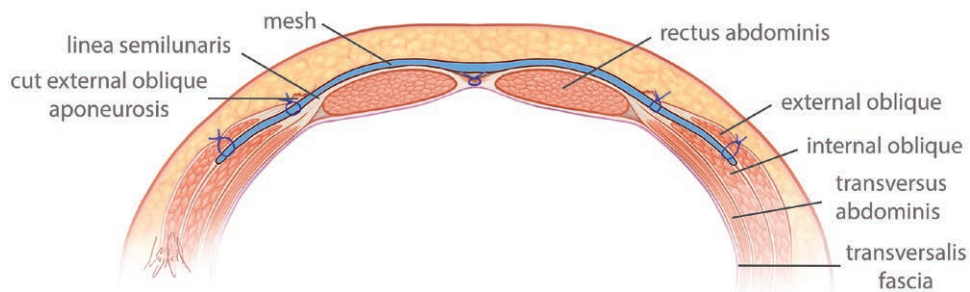
## RESULTS

A total of 20 patients were analyzed. Demographics are presented in Table 1. Median hernia defect size

was 382.5cm<sup>2</sup> (interquartile range [IQR] ± 138.0), and median operative time was 410.5 ± 73.1 minutes. Median follow-up was 2 months (IQR ± 3.5). Additional patient characteristics (including most common inciting operation for incisional hernia) are also presented in Table 1.

Zero patients experienced hernia recurrence. Eight (40%) had a surgical site occurrence. Of these, 2 had delayed wound healing that resolved without intervention. Three had superficial surgical site infection or irritation and were successfully treated empirically with antibiotics. One patient developed a hematoma 23 months after surgery, incited by trauma to the abdomen, complicated by infection, and treated with oral antibiotics and incision and drainage in the office. The 2 remaining patients had deep surgical site infections; 1 did not require surgical intervention, and 1 required debridement. The latter case also later required incision and drainage of persistent seroma and ultimate excision of a central portion of unincorporated mesh (24cm<sup>2</sup>).

Four patients (20%) had non-SSO complications. One (5%) required surgery for bowel obstruction. Three (15%) experienced venous thromboembolism (VTE); 1 had a history of breast cancer and was taking tamoxifen, 1 was a former smoker, and another had a history of



**Fig. 2.** Abdominal wall cross section showing the plane for mesh placement after corset repair for mid-line ventral hernia. The level depicted is inferior to the arcuate line.

**Table 1. Characteristics of Corset Repair Patients**

Patient Demographics			
	N (%)		N (%)
Total patients	20		
Age (y, median, IQR)	60.5 ± 6.0		HTN 6 (30%)
BMI (kg/m <sup>2</sup> , median, IQR)	30.0 ± 3.5		DM 5 (25%)
Sex			COPD 2 (10%)
Male	1 (5%)		Smoking status
Female	19 (95%)		Never 10 (50%)
Immunosuppressed	2 (10%)		Former 9 (45%)
			Current 1 (5%)
Surgical Characteristics			
	N (%)		N (%)
Defect size* (cm <sup>2</sup> , median, IQR)	382.5 ± 138.0		Operative time (min, median, IQR) 410.5 ± 73.1
ASA class			Modified VHWG classification
I	1 (5%)		Grade 1 5 (25%)
II	7 (35%)		Grade 2 9 (45%)
III	12 (60%)		Grade 3 6 (30%)
Wound classification			Inciting operation
Clean (I)	14 (70%)		Abdominal flap harvest 9 (45%)
Clean-contaminated (II)	6 (30%)		Obstetric/gynecologic 6 (30%)
Contaminated (III) or dirty (IV)	0 (0%)		General surgery (including bariatric) 5 (25%)

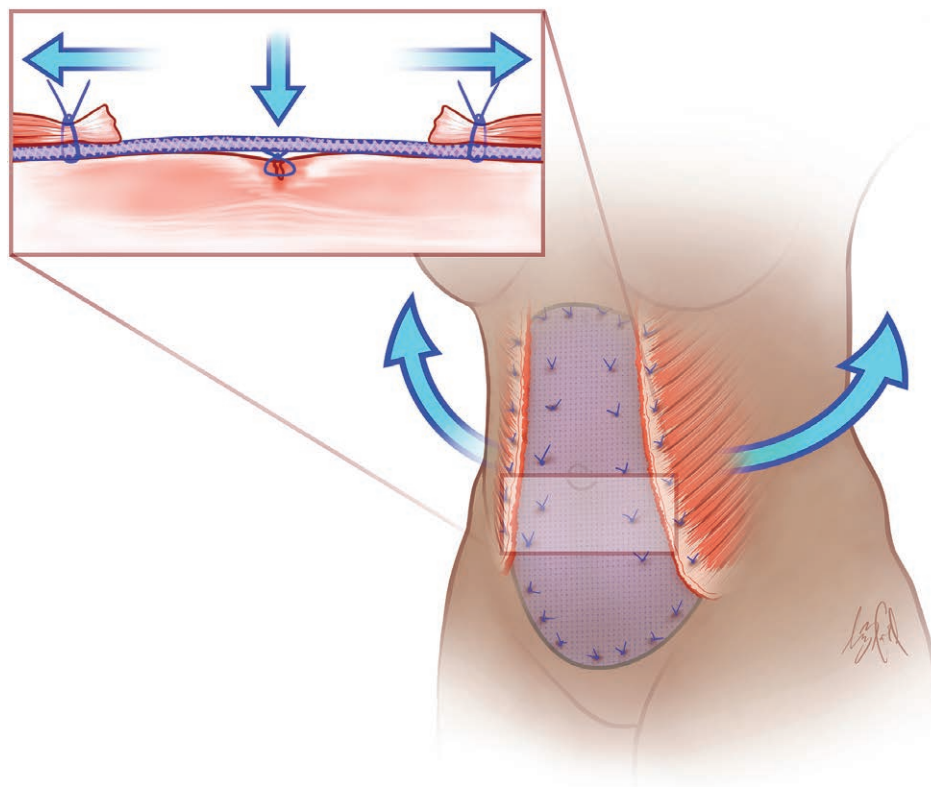
\*n = 18. Defect size data were missing for 2 patients. Sizes were obtained from the operating surgeon’s case log. If there were 2 defects, the area of the larger was listed. Defect size was calculated as the longest vertical dimension multiplied by the longest horizontal dimension.

ASA, American Society of Anesthesiologists; BMI, body mass index; COPD, Chronic obstructive pulmonary disease; DM, diabetes mellitus; HTN, hypertension; IQR, interquartile range; VHWG, Ventral Hernia Working Group.

atrial fibrillation. All 3 had received subcutaneous heparin before the start of the procedure. One (5%) required embolectomy, while the other 2 (10%) improved with anticoagulation.

**DISCUSSION**

The “corset repair” is an innovative approach to ventral hernia repair borne of a combination of existing, validated strategies. It is feasible and has several



**Fig. 3.** Theoretical force vectors implicated in the corset repair technique. As the external obliques contract, they pull the mesh taut and provide additional circumferential support to the abdominal wall and defect repair.

proposed advantages that may increase repair durability. First, unlike a classic onlay, mesh is placed partially posterior to bilateral myofascial flaps. The dynamic contractile support that the muscular layer creates (Fig. 3) is also a known advantage of retro-rectus mesh placement compared with classic onlay.<sup>4</sup> Ramirez et al. referred to this phenomenon as a “muscular corset.”<sup>5</sup> Second, the design of the corset repair could mitigate the concern that, though often necessary, EO release, by nature, weakens the abdominal wall.<sup>6</sup> Due to the mesh overlap with the donor sites of the EO flaps bilaterally, the iatrogenic disruption of the abdominal wall is ultimately reinforced with mesh (Fig. 3).

Israeli et al. proposed a hernia repair technique combining an EOR with mesh placement partially beneath the EOs bilaterally,<sup>7</sup> but our technique differs in several key ways, the most important of which is method of mesh fixation. They suture the mesh primarily to the IO muscle and fascia, whereas we suspend the mesh by attaching it primarily to the EO above it on either side. Both these strategies culminate with the mesh residing in the same plane, but they are in fact very different. By attaching primarily to the EOs bilaterally, we allow the mesh to tighten with contraction of the EOs, providing dynamic reinforcement.

In this series, no patients had hernia recurrence on early follow-up. Recurrence rates for the classic onlay technique vary widely in the literature, and can be as low as 0% or as high as 70%.<sup>8</sup> Reported surgical site infection rate for onlay ranges from 5% to 33%.<sup>8</sup> Our surgical site occurrence rate was slightly higher at 40%; however, this included non-infection surgical site occurrences such as delayed wound healing. Our series was limited by small sample size and short average follow-up; future study is necessary.

### CONCLUSIONS

The “corset repair” for complex ventral hernias is feasible to execute and has several proposed technical

advantages. In a preliminary evaluation of early patient outcomes, complication rates were acceptable and comparable to existing literature. The corset repair may be a valuable new addition to the available surgical options for challenging ventral hernias.

**John P. Fischer, MD, MPH**

Division of Plastic Surgery

Department of Surgery

University of Pennsylvania Health System

51 North 39th Street

Wright Saunders Building

Philadelphia, PA 19104

E-mail: John.Fischer2@penntmedicine.upenn.edu

### REFERENCES

1. Kokotovic D, Gögenur I, Helgstrand F. Substantial variation among hernia experts in the decision for treatment of patients with incisional hernia: a descriptive study on agreement. *Hernia*. 2017;21:271–278.
2. Blair LJ, Cox TC, Huntington CR, et al. The effect of component separation technique on quality of life (QOL) and surgical outcomes in complex open ventral hernia repair (OVHR). *Surg Endosc*. 2017;31:3539–3546.
3. Luijendijk RW, Hop WCJ, van den Tol MP, et al. A comparison of suture repair with mesh repair for incisional hernia. *N Engl J Med*. 2000;343:392–398.
4. Albino FP, Patel KM, Nahabedian MY, et al. Does mesh location matter in abdominal wall reconstruction? A systematic review of the literature and a summary of recommendations. *Plast Reconstr Surg*. 2013;132:1295–1304.
5. Ramirez OM, Ruas E, Dellon AL. “Components separation” method for closure of abdominal-wall defects: an anatomic and clinical study. *Plast Reconstr Surg*. 1990;86:519–526.
6. Hicks CW, Krpata DM, Blatnik JA, et al. Long-term effect on donor sites after components separation: a radiographic analysis. *Plast Reconstr Surg*. 2012;130:354–359.
7. Israeli R, Hazani R, Feingold RS, et al. Extended mesh repair with external oblique muscle reinforcement for abdominal wall contour abnormalities following TRAM flap. *Ann Plast Surg*. 2009;63:654–658.
8. Holihan JL, Nguyen DH, Nguyen MT, et al. Mesh location in open ventral hernia repair: a systematic review and network meta-analysis. *World J Surg*. 2016;40:89–99.