

Available online at [www.sciencedirect.com](http://www.sciencedirect.com)

ScienceDirect

journal homepage: [www.elsevier.com/locate/radcr](http://www.elsevier.com/locate/radcr)

## Case report

# Extravasation of Epirubicin chemotherapy from a port-a-cath causing extensive breast necrosis: Sequential imaging findings and management of a breast cancer patient <sup>☆</sup>

Penelope Moyle, MBChB, MRCP, FRCR<sup>a,b</sup>, Chien Soh, BA<sup>c,\*</sup>, Nuala Healy, MB BCH BAO, MRCSI, Masters Clin Ed, MD, FFR, FRCR<sup>a,b</sup>, Charles Malata, BSc (HB), MBChB, LRCP MRCS, FRCS (Glasg), FRCS (Pl)<sup>b,c,d</sup>, Parto Forouhi, BSc (Edin), MB ChB (Edin), MD (Edin), FRCS (Eng)<sup>b</sup>

<sup>a</sup> Radiology Department, Addenbrooke's Hospital, Cambridge, University Hospitals NHS Foundation Trust, Cambridge, UK

<sup>b</sup> Cambridge Breast Unit, Department of Surgery, Addenbrooke's Hospital, Cambridge, University Hospitals NHS Foundation Trust, Cambridge, UK

<sup>c</sup> Department of Plastic & Reconstructive Surgery, Addenbrooke's Hospital, Cambridge University Hospitals NHS Foundation Trust, Cambridge, UK

<sup>d</sup> School of Medicine, Anglia Ruskin University, Cambridge and Chelmsford, UK

## ARTICLE INFO

## Article history:

Received 9 June 2021

Accepted 19 August 2021

## Keywords:

Extravasation

Chemotherapy

Necrosis

Breast

MRI

Skin necrosis

Complex wound

## ABSTRACT

Extravasation of chemotherapy is rare with an estimated incidence of 0.01%–7% but can cause significant morbidity, delay in cancer treatment and potential mortality. We present a case of 55-year-old woman with a metastatic right axillary lymph node with no identifiable breast primary, commenced on chemotherapy as per multidisciplinary team decision. Extravasation of 25 mls of Epirubicin chemotherapy at the porta-a-cath (site) caused extensive inflammatory change in the breast parenchyma and chest wall with a necrotic ulcerating skin-defect. Even with ensuring port or peripheral catheter patency and position, extravasation can occur. This is the first case report to describe the use of MRI to help plan management, identifying the extent of the tissue damage and vascular compromise which could impair healing. In this case the necrotic ulcer was managed with surgical debridement and human ADM matrix (Matriderm dermal matrix) which has not been described in the literature previously.

© 2021 The Authors. Published by Elsevier Inc. on behalf of University of Washington.

This is an open access article under the CC BY-NC-ND license

(<http://creativecommons.org/licenses/by-nc-nd/4.0/>)

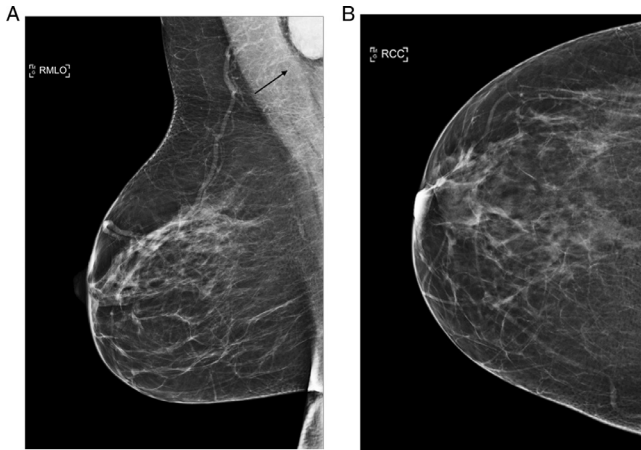
<sup>☆</sup> Competing interests: Chien Lin Soh, Dr Penelope Moyle, Mr Parto Forouhi and Professor Charles Malata declare that they do not have any conflict of interest.

\* Corresponding author.

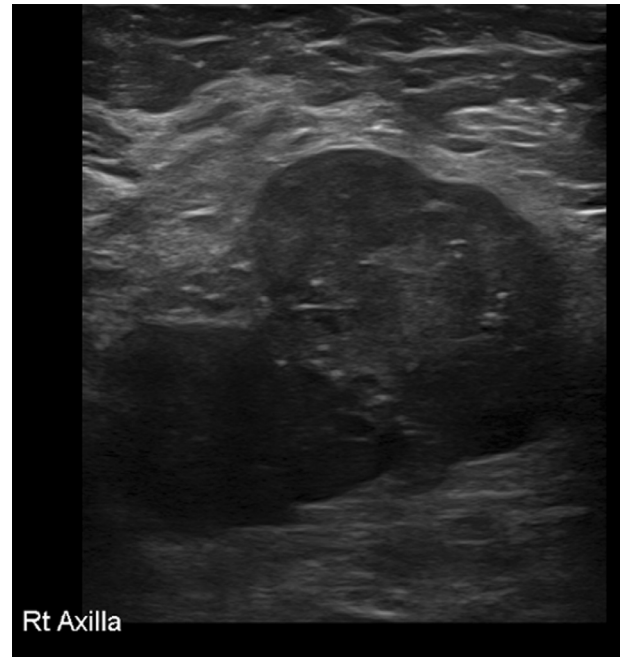
E-mail address: [cls99@cam.ac.uk](mailto:cls99@cam.ac.uk) (C. Soh).

<https://doi.org/10.1016/j.radcr.2021.08.046>

1930-0433/© 2021 The Authors. Published by Elsevier Inc. on behalf of University of Washington. This is an open access article under the CC BY-NC-ND license (<http://creativecommons.org/licenses/by-nc-nd/4.0/>)



**Fig. 1 – A: Right MLO mammogram identified a 30 mm well defined dense rounded mass overlying the right axilla (M3). B: The mass was not identified on the CC view as too posterior and superior on this view. No mass identified on the CC view as the mass was too posterior and superior.**



**Fig. 2 – Right axilla US of a well-defined lobulated hypoechoic mass 45 mm x 31 mm in keeping with a right level one axillary lymph node U4.**

## Case report

A 55-year-old woman attended the accident and emergency department at a tertiary referral centre with extensive skin necrosis of the right breast and was referred to the Breast Unit for management.

She had initially presented to a regional hospital three weeks prior, with a one-month history of a mass in the right axilla. Clinical examination at that time identified a 40 mm mobile axillary mass with normal breast examination. Digital mammograms identified a 30 mm well defined dense rounded mass overlying the right axilla (M3), only partially imaged on the medial lateral oblique view (Fig. 1). Ultrasound (US) of the right axilla confirmed a well-defined lobulated hypoechoic mass 45 mm x 31 mm in keeping with a right level one axillary lymph node which was suspicious for malignancy (U4) (Fig. 2). Histology of the US guided core biopsy (2 × 16 gauge) of the axilla identified a metastatic lymph node of ductal carcinoma type, grade 3, oestrogen receptor (ER) positive (8/8), progesterone receptor (PR) positive (8/8) and Herceptin 2 receptor positive.

To determine if there was an occult breast cancer, a dynamic contrast enhanced breast MRI was performed, but the MRI did not demonstrate abnormal enhancement in either breast, confirming only a solitary enlarged right level one axillary lymph node in keeping with biopsy-proven axillary metastatic disease (Fig. 3).

A right port-a-cath had been inserted one day prior to chemotherapy with no complications recorded and an image intensifier image confirmed the correct location of the venous line placement, with the tip projected over the superior vena cava (Fig. 4). On the first day of neoadjuvant chemotherapy after administration of 25 mls of Epirubicin the patient experienced pain at the port-a-cath site and chest wall and the infusion was stopped as it was recognised that the drug had

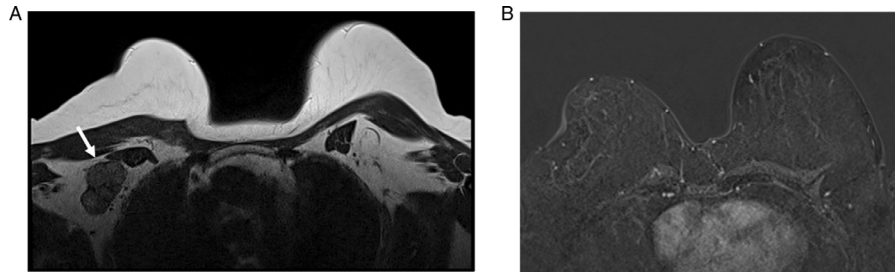
been delivered outside the port-a-cath. The extravasation was managed expectantly without saline washout, surgical intervention or the use of an antidote.

The left upper chest wall (and contiguous breast) became increasingly painful, red and swollen; four days later an MRI was performed to identify the extent of the tissue damage from the extravasated chemotherapy and to guide decision making regarding the need for tissue debridement and/ or mastectomy.

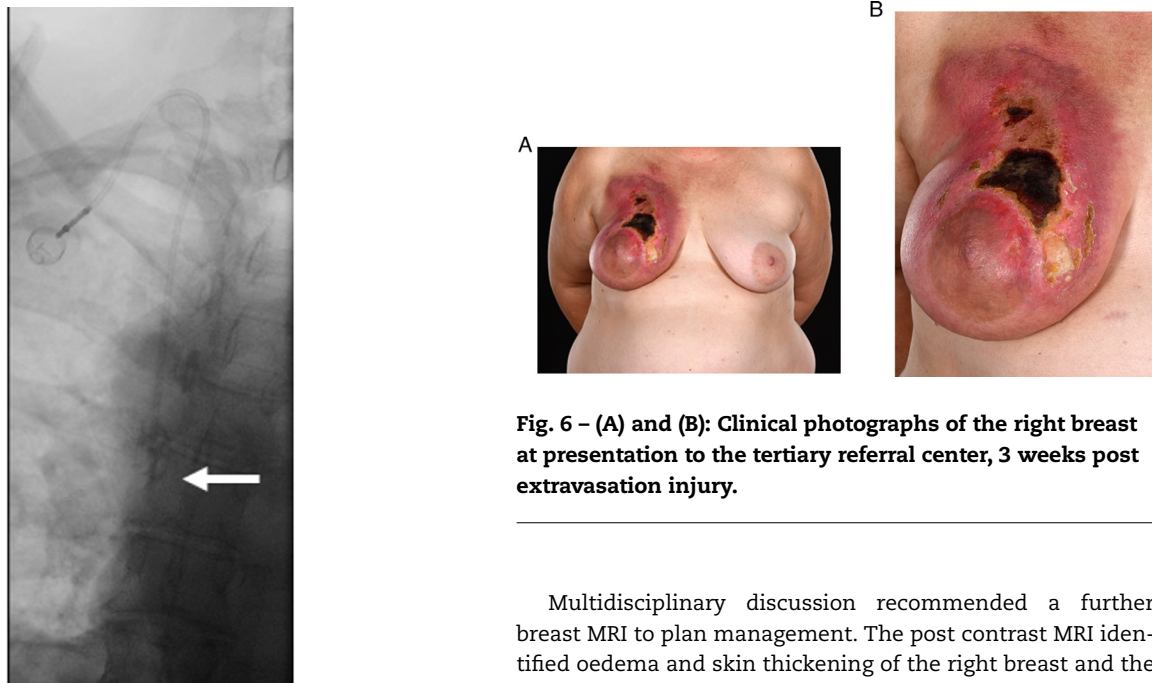
Only limited images without contrast were obtained due to the patient's chest wall pain, but this identified extensive oedema of the pectoralis muscles bilaterally, extensive oedema of the breast parenchyma and skin of the right breast and mild medial skin oedema of the left medial breast (Fig. 5). Due to the degree of inflammatory changes, she was prescribed high dose oral steroids, oral morphine and skin dressings.

At the tertiary center, there was a joint assessment by a plastic surgeon and oncological breast surgeon. She was noted to have a BMI of 47 with a prior history of hypothyroidism and congenital heart defect. Examination identified the entire chest wall was inflamed with extensive necrosis of the breast and eschar formation typical for consequences of an extravasation injury (Fig. 6).

The following challenges were identified at this time: the patient had an aggressive breast cancer in the right axillary lymph nodes adjacent to an area of skin necrosis, no effective treatment had been started 10 weeks following the initial presentation, a surgical axillary clearance in an area of compromised skin and soft tissues had the potential to result in further extensive breakdown and the patient had a BMI of 47, which can make surgery challenging.



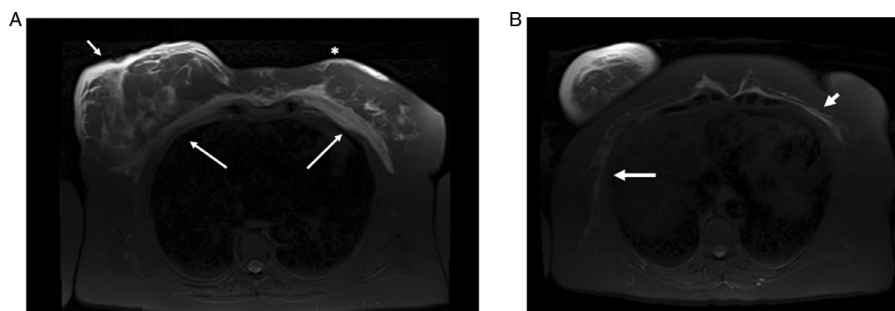
**Fig. 3 – (A):** T2W MRI confirmed the right unifocal level one axillary mass (white arrow). **(B):** Dynamic post contrast fat saturated breast MRI with no suspicious enhancement identified in the breast.



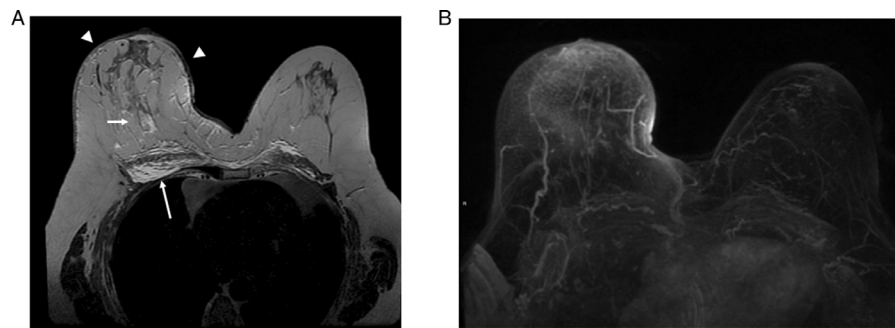
**Fig. 4 – (A):** Image intensifier image of the post placement of the right port-a-cath with the tip overlying the superior vena cava and the line appearing intact.

**Fig. 6 – (A) and (B):** Clinical photographs of the right breast at presentation to the tertiary referral center, 3 weeks post extravasation injury.

Multidisciplinary discussion recommended a further breast MRI to plan management. The post contrast MRI identified oedema and skin thickening of the right breast and the right pectoralis major and minor but normal enhancement of the vessels with the lateral thoracic, internal mammary, perforators and intercostal perforators all preserved. The right axillary mass was stable in size and no new breast or axillary lesions were identified (Fig. 7).



**Fig. 5 – (A):** STIR sequence of the post extravasation breast MRI. There was extensive high signal intensity oedema of the pectoralis muscles bilaterally (long white arrows), extensive oedema and skin thickening of the right breast (short white arrow) and mild medial skin thickening and oedema of the left medial breast (asterix). **(B):** STIR images with the extent of the high signal intensity inflammatory changes extending on to the lower chest wall (short white left arrow) and long the right lateral chest wall and serratus anterior (long white arrow).



**Fig. 7 – (A):** Post contrast, fat saturated T1w image demonstrating skin thickening of the right breast (white arrow heads), oedema of the right breast (short white arrow) and the right pectoralis major and minor (long white arrow). **(B):** Post contrast MIP images which demonstrated the intact vascularity of the breasts and internal mammary vessels (arrows).

Based on the imaging demonstrating the lack of extensive breast necrosis or abscess, further conservative management was continued and Letrozole was initiated to start cancer treatment. A surgical wash out of the wound but no significant wound debridement was performed with removal of the port-a-cath. The surgeon did not identify any break in the line and the venous catheter was a fully intact on inspection.

Treatment with Paclitaxel, Trastuzumab and Pertuzumab with Granulocyte Colony Stimulating Factor (G-CSF) cover was commenced four weeks later (delayed by wound infection and fever). Wound management continued with input from the tissue viability service and a vacuum dressing applied once the chemotherapy restarted. It was felt by the plastic surgeons in the Oncoplastic MDT that since no cancer had been identified in the breast and the ulcer was contiguous with the axillary metastasis, topical negative pressure therapy (vacuum dressing) was not contraindicated.

Following completion of chemotherapy, the axillary mass clinically had not reduced significantly in size and therefore a breast MRI was performed to plan surgery and a PET-CT to exclude metastatic disease. The dynamic post contrast breast MRI identified partial response of the right axillary mass (from 45 mm × 31 mm to 37 mm × 26 mm) with no suspicious enhancement in the right breast. There was decreased skin thickening and decreased breast oedema with no significant oedema of the pectoralis muscles. The residual cavity in the upper inner right breast had reduced and was barely visible on MRI. There were no new suspicious lymph nodes. There was normal vascularity of the breast and chest wall (Fig. 8) further validating the MRI-guided decision not to perform debridement or resection of the breast tissue underlying the skin ulceration let alone perform a mastectomy.

PET-CT showed no evidence of distant metastases with only the axillary mass present and the skin defect from the port site (Fig. 9). An axillary clearance was performed, and the skin defect in the right superior chest wall closed with human acellular dermal matrix (ADM, Matriderm dermal matrix from MedSkin Solutions, Germany) akin to a split skin graft (Fig. 10). Final histopathology of the right axillary clearance identified 1 positive lymph node from a total of 21 lymph nodes with extensive infiltration of node with metastatic carcinoma measuring 24 mm, ER, PR, Herceptin 2 receptor positive. Further MDT discussion advised further

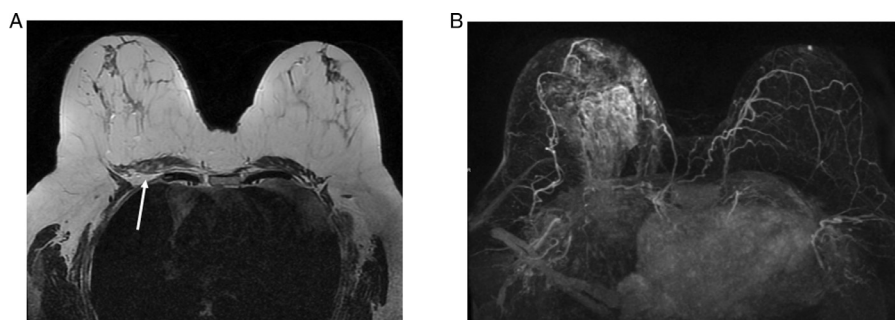
oncological treatment consisting of a trial with trastuzumab emtansine and Zoledronic acid. The patient is currently well post-surgery and the treatment is ongoing for final wound closure with a meshed split skin graft of the ever-decreasing wound. It has been possible to preserve her breast which is no longer indurated, is soft and mobile.

## Discussion

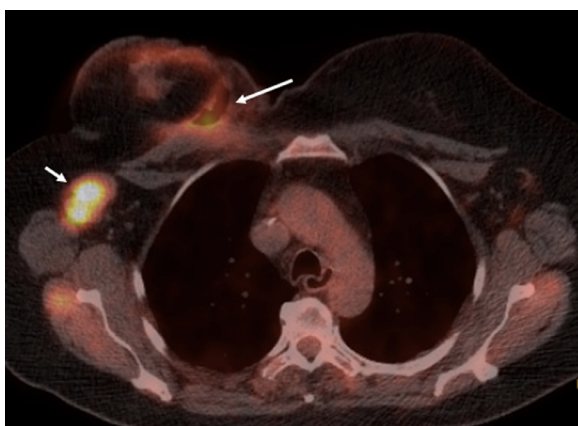
Extravasation events detected during chemotherapy are well described in the literature with an estimated incidence of 0.01%-7% [1]. These can cause significant morbidity, delay to cancer treatment and potential mortality. Schulmeister describes four major mechanisms by which extravasation injury can occur: perforation, catheter fracture, incorrect needle placement and thrombus formation [2]. Extravasation is a serious complication of chemotherapeutic agents administered intravenously, and it is vital that signs of extravasation are recognized promptly and treated immediately. These signs include sensory changes, pain, swelling, blanching and erythema [3]. The consequences of extravasation can range from pain, delay in treatment, impairment of mobility and psychological distress from the extensive tissue damage. Certain patient factors may be associated with a greater risk of extravasation such as age, underlying vascular disease, and history of multiple intravenous therapies [3]. A high body mass index has been shown to be associated with all the patients that experienced extravasation in a study by Halsik [4].

Epirubicin is an anthracycline chemotherapy agent used commonly for the treatment of breast cancer, acting as a topoisomerase inhibitor. Anthracyclines are classified as DNA-binding vesicants and if extravasation occurs can induce large blisters and tissue injuries, leading to necrosis and ulceration [1].

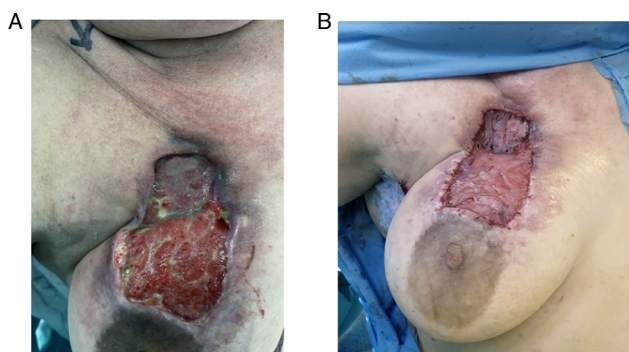
Central venous access is used for administration of chemotherapy as it minimizes its toxic effects of extravasation [5]. Extravasation injury is rarer with central administration than peripheral routes [6] however, central venous devices such as Port-a-Cath have shown extravasation rates of up to 6% in the literature [4,7]. There have been several reports



**Fig. 8 – (A), post contrast, fat saturated T1w image demonstrated partial response of the right axillary mass, decreased skin thickening, decreased breast oedema with no significant oedema of the pectoralis muscles (arrows). (B) demonstrates the normal vascularity of the breast and chest wall.**



**Fig. 9 – 18F-FDG PET-CT demonstrated avid uptake in the right axillary mass (short white arrow) with mild uptake around the remaining ulceration and defect in superior breast (long white arrow) due to granulation tissue.**



**Fig. 10 – (A), pre-operative photograph of the skin necrosis and superior defect. (B), post-operative photograph of the oncological procedure with acellular dermal matrix in situ.**

of extravasation with the use of central venous access devices with rates from 0.26% to 4.7% [8,9].

The most cohesive current guidelines on the treatment of extravasation are by the European Society of Medical On-

cologists [1]. These suggest the best treatment is dictated by the class of chemotherapy agent. For vesicants early localisation with a cold compress every 20 minutes, four times a day for 24-48 hours and treatment ideally within 6 hours with intravenous dexrazoxane and topical Dimethyl sulfoxide [10]. This is reflected in several case reports where the systemic use of dexrazoxane has resulted in favorable outcomes during extravasation injury involving central venous catheters [11,12,13]. The earlier the extravasation is detected, the more beneficial interventions such as a surgical “Subcutaneous Wash-Out Procedure” are [14].

Multi-center studies have shown that surgical treatment is the last resort, as timely treatment can prevent surgery in a large proportion of patients if intravenous infusion of dexrazoxane is given within 6 hours of the extravasation incident [15]. If the port removal is delayed, surgical management such as debridement and flap coverage may be required to manage the necrotic area [8,9]. Innovative techniques such as vacuum-sealing have also been described in the literature as per the case herein reported. This however has the potential to further stimulate tumor growth when used in the vicinity of a cancer [16].

This case illustrates that even after a small volume of epirubicin extravasation severe tissue damage can occur. The literature suggests that early administration of treatments as per ESMO guidelines can reduce the impact of the tissue damage. This is the first case report to describe the use of MRI to help plan management, identifying the extent of the tissue damage and vascular compromise which could impair healing. The serial MRIs also served to assess any progression in tissue damage and thus prevented potentially mutilating surgery (by radical debridement of necrotic tissue) or a mastectomy and the consequent need for flap reconstruction. This was especially important in someone who was a high surgical risk on account of her very high BMI. In this case the necrotic ulcer was managed with limited surgical debridement followed by dressing changes and topical negative pressure (vacuum therapy). Once the ulcerated area was clean and had no residual necrotic / sloughy tissue and had formed sufficient granulation tissue, the now superficial ulcer was resurfaced with human ADM matrix which has not been described in the literature previously. Although the take from this was less than ideal the pa-

tient went on to have skin grafting of a now favorable bed.

In conclusion clinicians must be aware of the grave implications of extravasation injuries to cancer patients and involve the multidisciplinary team, including radiology, to obtain the best outcomes.

---

### Patient consent

Patient has agreed to a case report being written based on her images. This has been entered onto the patient records (EPIC) on the 15/10/2020.

---

### REFERENCES

- [1] Pérez Fidalgo JA, García Fabregat L, Cervantes A, Margulies A, Vidall C, Roila F. Management of chemotherapy extravasation: ESMO-EONS Clinical Practice Guidelines. ESMO Guidelines Working Group. *Ann Oncol* 2012;23(7):167–73.
- [2] Schulmeister L, Camp-Sorrell D. Chemotherapy extravasation from implanted ports. *Oncol Nurs Forum* 2000;27(3):531–8.
- [3] Hale O, Deutsch PG, Lahiri A. Epirubicin extravasation: consequences of delayed management. *BMJ Case Rep* 2017;1–3 bcr2016218012.
- [4] Haslik W, et al. Port-a-Cath extravasation of vesicant cytotoxics: surgical options for a rare complication of cancer chemotherapy. *Eur J Surg Oncol* 2015;41(3):378–85.
- [5] Vano-Galvan S, Jaen P. Extravasation of Epirubicin. *N Engl J Med* 2009;360(20):2117.
- [6] Barutca S, Kadikoylu G, Bolaman Z, Meydan N, Yavasoglu I, et al. Extravasation of paclitaxel into breast tissue from central catheter port. *Support Care Cancer* 2002;10(7):563–5 Epub 2002 Jul 11. PMID:12324812. doi:10.1007/s00520-002-0372-1.
- [7] Schrijvers DL. Extravasation: a dreaded complication of chemotherapy. *Ann Oncol* 2003;14(Suppl 3):iii26–30.
- [8] Kruger S, Huf S, MacNeill F. Chemotherapy extravasation injury from a portacath requiring chest wall resurfacing. *Eur J Surg Oncol (EJSO)* 2012;38(5):450.
- [9] Vasconcelos I, Schoenegg W. Massive breast necrosis after extravasation of a full anthracycline cycle. *Case Rep* 2013;2013 bcr2013201179-b.
- [10] Aigner B, et al. Complete recovery of a wide local reaction by the use of dexrazoxane 72 hours after epirubicin extravasation: case report and review of the literature. *Dermatology* 2014;229(4):288–92.
- [11] Tsavaris NB, et al. Prevention of tissue necrosis due to accidental extravasation of cytostatic drugs by a conservative approach. *Cancer Chemother Pharmacol* 1992;30(4):330–3.
- [12] Tyson AM, Gay WE. Successful experience utilizing dexrazoxane treatment for an anthracycline extravasation. *Ann Pharmacother* 2010;44(5):922–5.
- [13] Langer SW, et al. Dexrazoxane in anthracycline extravasation. *J Clin Oncol* 2000;18(16):3064.
- [14] Giunta R. Early subcutaneous wash-out in acute extravasations. *Ann Oncol* 2004;15(7):1146.
- [15] Mouridsen HT, et al. Treatment of anthracycline extravasation with Savene (dexrazoxane): results from two prospective clinical multicentre studies. *Ann Oncol* 2007;18(3):546–50.
- [16] Rhiem K, et al. Vacuum-sealing as a treatment option for severe anthracycline extravasation in a breast cancer patient. *Breast Care* 2008;3(5):347–8.