

Perioperative management of a patient with Dandy Walker malformation with tetralogy of Fallot undergoing total correction and fresh homologous pericardial pulmonary valve conduit implantation: Report of a rare case

Vishnu Datt, D. K. Tempe, Parin Lalwani, Saket Aggarwal¹, Pradeep Kumar, Anitha Diwakar, A. S. Tomar

Department of Anaesthesiology and Intensive Care and Cardiothoracic and Vascular Surgery, G.B. Pant Hospital, New Delhi, ¹Department of Cardio-Thoracic and Vascular Surgery, G.B. Pant Hospital, New Delhi, India

ABSTRACT

Perioperative management of a patient with Dandy–Walker malformation (DWM) with tetralogy of Fallot (TOF), patent ductus arteriosus, and pulmonary artery stenosis is a great challenge to the anesthesiologist. Anesthetic management in such patients can trigger tet spells that might rapidly increase intracranial pressure (ICP), conning and even death. The increase in ICP can precipitate tet spells and further brain hypoxia. To avoid an increase in ICP during TOF corrective surgery ventriculo-peritoneal (VP) shunt should be performed before cardiac surgery. We present the first case report of a 11-month-old male baby afflicted with DWM and TOF who underwent successful TOF total corrective surgery and fresh autologous pericardial pulmonary valve conduit implantation under cardiopulmonary bypass after 1 week of VP shunt insertion.

Key words: Anesthetic management; Cardiopulmonary bypass; Dandy–Walker malformation; Homologous pulmonary valve conduit; Tetralogy of Fallot

Received: 21-10-14
Accepted: 21-04-15

INTRODUCTION

The etiopathology of Dandy–Walker malformation (DWM) consists of the developmental failure of the roof of the fourth ventricle during embryogenesis that results in the cystic expansion of the fourth ventricle in the posterior fossa. It presents early in life, 80–90% within 1st year with features of raised intracranial pressure (ICP). It is well-established that Dandy–Walker syndrome (DWS) is frequently associated with other systemic anomalies including cardiovascular malformation. Rarely, it has been associated with tetralogy

of Fallot (TOF).^[1,2] Anesthetic management in such a case is highly challenging in order to prevent two major life-threatening events, that is, raised ICP and tet spells caused by DWM and TOF respectively, as both of them can precipitate each other. To the best of our knowledge, it is the first case report on perioperative anesthetic management for total correction using cardiopulmonary bypass (CPB) in a patient with this extremely rare combination of DWM with TOF, pulmonary artery (PA) atresia, and patent ductus arteriosus (PDA). The management was based on the pathophysiology of the DWM with TOF and clinical experience.

Access this article online
Website: www.annals.in
DOI: 10.4103/0971-9784.159824
Quick Response Code:


Address for correspondence: Dr. Vishnu Datt, Room No. 619, Academic Block, G.B. Pant Hospital, New Delhi - 110 002, India. E-mail: dattvishnu@yahoo.com

CASE REPORT

An 11-month-old, male baby, weighing 5.5 kg, presented with cyanosis, failure to thrive and episodes of unconsciousness for the past 3 months. Recently, the mother also noticed increased respiratory rate and sweating during breastfeeding. On evaluation, child was tachypneic and had a heart murmur. Chest X-ray showed a boot-shaped heart with pulmonary oligemia. Two-dimensional echocardiography revealed a sub-aortic ventricular septal defect (VSD) with 50% aortic override, severe right ventricular outflow tract (RVOT) obstruction with a gradient (Gr) of 62 mmHg, a large PDA and a stenosed left PA. Computed tomography-pulmonary angiography confirmed the diagnosis of TOF with pulmonary atresia and PDA [Figure 1]. In view of episodes of unconsciousness and delayed milestones, magnetic resonance imaging brain was performed which revealed enlarged posterior fossa with cystic dilatation of fourth ventricle, hydrocephalus and elevated tentorium with cerebellar and vermian hypoplasia consistent with a diagnosis of DWM [Figure 2]. Other hematological and biochemical values were within normal limits. In view of increased neurological complications in such a patient following CPB, it was decided to perform ventriculo-peritoneal (VP) shunt before TOF corrective surgery. VP shunt surgery was performed under balanced general anesthesia technique, including thiopentone, fentanyl, midazolam, vecuronium bromide, and isoflurane. However, during intraoperative period patient developed two episodes of tet spells ($SpO_2 < 40\%$), which were managed with isolyte - P infusion, metoprolol (0.25 mg), noradrenaline (5 μ g), FiO_2 -1 and folding of legs on chest.

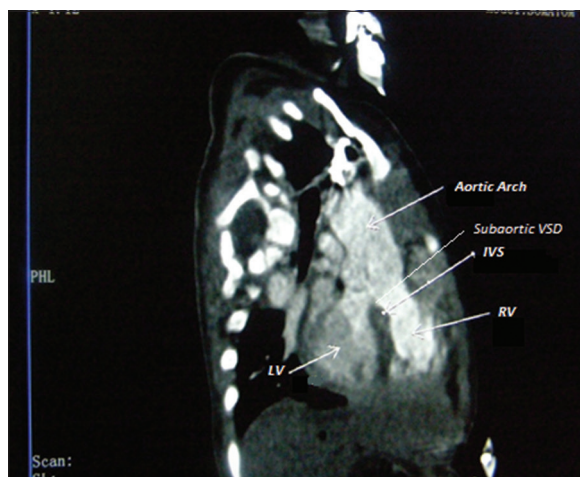


Figure 1: Computed tomography angiography shows tetralogy of Fallot with sub aortic ventricular septal defect. IVS: Interventricular septum, RV: Right ventricle, LV: Left ventricle

Patient was extubated on table in the operating room, and the postoperative course was uneventful.

After 1-week, an intra-cardiac repair via a midline sternotomy, consisting of PDA ligation, VSD closure and RVOT to main PA valved-conduit placement was planned. As an intravenous line was already *in-situ*, intravenous induction was employed using fentanyl (45 μ g), thiopentone (5 mg), and vecuronium (1 mg). Trachea was intubated with cuffed endotracheal tube 3.5 mm ID. A 22G laedercath was inserted in left femoral artery. In view of the VP shunt crossing the right side of the neck, left internal jugular vein was cannulated using 5.5 Fr triple lumen catheter. Anesthesia was maintained with intermittent fentanyl, midazolam, sevoflurane (0.5–2%), vecuronium, and oxygen in air (FiO_2 0.5–1). Standard American Society of Anesthesiologists monitoring consisting of electrocardiogram, SPO_2 , invasive arterial pressure, central venous pressure (CVP), serial arterial blood gas analyses, temperature, serum electrolytes, and urine output was performed. During sternal retraction, the surgeon was advised to be gentle as too much pressure could have compressed the VP shunt passing subcutaneously, resulting in increased ICP and thus compromising cerebral blood flow. After full heparinization (ACT >480 s), the intracardiac repair was performed under standard CPB technique. Perfusion pressure of 35–50 mmHg and hematocrit of about 30% were maintained during CPB, and modified ultrafiltration was also utilized. Methylprednisolone (180 mg) and epsilon aminocaproic acid (550 mg) were added to the pump prime. The patient was weaned off CPB using milrinone (0.5 μ g/kg/min), dobutamine (5 μ g/kg/min), nitroglycerin (1 μ g/kg/min), and adrenaline (0.025 μ g/kg/min) infusions. Total CPB

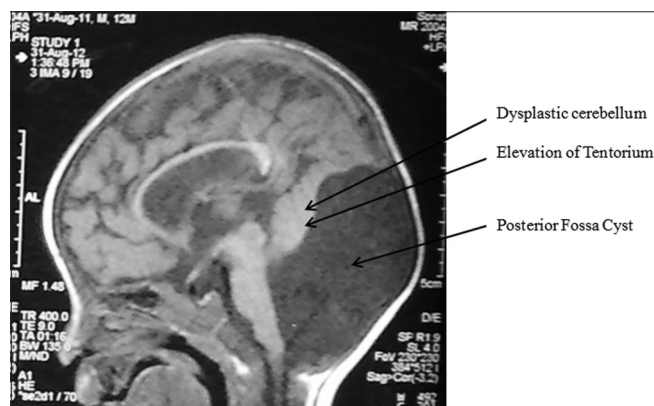


Figure 2: Magnetic resonance imaging brain shows enlarged posterior fossa with cystic dilatation of fourth ventricle, elevated tentorium with cerebellar hypoplasia. This image is suggestive of a possibility of aqueductal stenosis

time and aortic cross-clamp time were 225 and 153 min, respectively, and total urine output was 400 ml. Due to edema of cardiac structures and use of valved-conduit across RVOT, sternal closure was not possible and the overlying skin was closed, and the patient was transferred to the Intensive Care Unit (ICU) for elective ventilation. Patient maintained stable hemodynamics postoperatively and was ventilated for 48 h, after which sternal closure could be performed successfully. The patient was weaned and extubated after another 48 h.

DISCUSSION

Dandy-Walker syndrome is characterized by various neuropathological features like, cystic dilatation of fourth ventricle, hypoplasia of cerebellar vermis, hydrocephalus, elevation of tentorium and or transverse sinus, enlargement of posterior fossa, lack of patency of foramen of luschka and/or magendie.^[3] The incidence of DWM is 1:25,000–30,000 of live births and signs and symptoms of hydrocephalus and raised ICP appear within the 1st year of life in 2–4% of patients.^[4] Cardiac anomalies are said to be present in 18% of cases, and it is rarely associated with TOF.^[5] TOF is a cyanotic congenital heart defect comprising of RVOT obstruction, large malaligned subaortic VSD, overriding of aorta and right ventricular hypertrophy and with right to left shunt and the patients are prone to tet spells. About 48% patients of DWS can also be associated with other congenital anomalies such as macrocephaly, micrognathia, cleft lip and palate, lower cranial nerve palsies which may cause airway difficulties, aspiration pneumonia and prolonged postoperative ventilation.^[5,6] In addition, associated cerebral anomalies like agenesis of corpus callosum, pontine lesions, and interference with medullary control of respiration can precipitate frequent episodes of apnea, apneustic breathing, and respiratory failure.^[7-9] These respiratory abnormalities along with the decreased intravascular volume status due to persistent nausea and vomiting with raised ICP may precipitate tet spells.^[10] Tet spells exhibit increased oxygen demand, progressive hypoxia, metabolic acidosis, and hypercarbia. The occurrence of tet spells in a patient associated with DWS can cause a rise in ICP, conning, and death.^[11] Thus, the raised ICP can precipitate tet spells and tet spells can lead to increased ICP, and this poses anesthetic challenges.

Usually, a moderate pressure (12–15 cm H₂O) VP shunt is inserted to maintain normal ICP in DWM

with hydrocephalus. It helps maintaining a normal ICP by draining cerebrospinal fluid during adverse circumstances (if any) under anesthesia or CPB that may lead to transient increases in ICP. The management of tet spells necessitates the general measures to decrease infundibular spasm, right to left shunt and improve oxygenation and cardiac output by administration of beta blockers (metoprolol 0.1 mg/kg), fluid boluses (10–20 ml/kg), and folding of limbs over chest, phenylephrine (5–20 µg/kg) and noradrenaline infusion (0.1 µg/kg/min) and deepening of level of anesthesia (fentanyl 5–10 µg/kg). In refractory cases, elective ventilation and palliative shunts like modified Blalock-Taussig shunt to increase pulmonary blood flow or even total correction of TOF are mandatory.

Care of VP shunt to prevent damage, obstruction, and infection should also be considered. Opioids *per se* have minimal effects on cerebral blood flow, and by obtunding sympathetic stimulation of laryngoscopy prevent an increase in ICP.^[10] The anesthetic induction should be performed without increasing cerebral blood flow and cerebral metabolic rate and maintaining normocapnea, normotension, euglycemia may help reducing the ICP.^[12] Thiopentone or propofol reduces ICP but also decreases the systemic vascular resistance (SVR) so should be used in titrated doses. Among the inhalational agents, halothane particularly and sevoflurane maintain the hemodynamics and arterial oxygen saturation. These agents decrease myocardial contractility, infundibular spasm, and cause less reduction in SVR, so decrease R-L shunt. However, halothane as compared to sevoflurane causes more increase in cerebral blood flow and raised ICP, so sevoflurane was used in the present patient.

In order to break the vicious cycle of tet spell precipitating raised ICP and vice versa, VP shunt was performed before cardiac surgery and to avoid damage to the shunt, right internal jugular vein cannulation was avoided. Thus, the main goal of anesthetic management was to prevent a tet spell. This was especially so, as the patient had a history of tet spells and even during the surgery for VP shunt, he had tet spells. We employed high dose opioids and high FiO₂ along with maintenance of adequate preload, low heart rate in sinus rhythm, high SVR, and hematocrit of >30%.

Postoperative course may be complicated by RV dysfunction, residual VSD (PA saturation >80%), residual RVOT obstruction (Gr >30 mmHg), high RV to systemic pressure ratio (>0.6), arrhythmias like

complete heart block or junctional ectopic tachycardia and present with hypotension and raised CVP. In the present patient, epinephrine, milrinone, and dobutamine were used for weaning. Patient maintained stable hemodynamics with sinus rhythm. In case of difficulty, reinstatement of CPB to correct the residual defect, optimization of right ventricular filling, inotropic support (dobutamine, milrinone), maintenance of atrioventricular synchrony by pacing, and special ventilator maneuvers to reduce pulmonary vascular resistance and to reduce the RV after load may be necessary.^[13]

As return of spontaneous respiration may be delayed in DWS due to abnormalities of medullary control of respiration prolonged postoperative ventilator support may be required.^[7] Furthermore, high chances of recurrent apnea warrants close observation in ICU after extubation.

CONCLUSION

In patients with DWM with hydrocephalus and TOF, the performance of VP shunt surgery before the elective total correction can be a useful procedure to prevent a rise in ICP, conning, and death. Total correction can be performed safely under moderate to high dose narcotic-based anesthesia technique. However, patients with TOF and DWM can develop tet spells while undergoing VP shunt or noncardiac surgery or elective correction of TOF with DWM.

REFERENCES

- Ozdemir O, Polat A, Cinbis M, Kurt F, Kucuktasci K, Kiroglu Y. Dandy-Walker's variant and tetralogy of Fallot with atrial septal defect and patent ductus arteriosus and primary hypothyroidy – A new association. *Indian J Pediatr* 2009;76:433-5.
- Kohyama J, Watanabe S, Iwakawa Y, Fukuda C. A case of Dandy-Walker malformation: Consideration on the teratogenic period and sleep structures. *Brain Dev* 1988;10:392-6.
- Golden JA, Rorke LB, Bruce DA. Dandy-Walker syndrome and associated anomalies. *Pediatr Neurosci* 1987;13:38-44.
- Lavanya T, Cohen M, Gandhi SV, Farrell T, Whitby EH. A case of a Dandy-Walker variant: The importance of a multidisciplinary team approach using complementary techniques to obtain accurate diagnostic information. *Br J Radiol* 2008;81:e242-5.
- Osenbach RK, Menezes AH. Diagnosis and management of the Dandy-Walker malformation: 30 years of experience. *Pediatr Neurosurg* 1992;18:179-89.
- Selim M, Mowafi H, Al-Ghamdi A, Adu-Gyamfi Y. Intubation via LMA in pediatric patients with difficult airways. *Can J Anaesth* 1999;46:891-3.
- Ewart MC, Oh TE. The Dandy-Walker syndrome. Relevance to anaesthesia and intensive care. *Anaesthesia* 1990;45:646-8.
- Stahlman M, Sexton C. Ventilation control in the newborn. *Am J Dis Child* 1961;101:216-7.
- Krieger AJ, Detwiler J, Trooskin S. Respiration in an infant with the Dandy-Walker syndrome. *Neurology* 1974;24:1064-7.
- Nienaber J. Refresher course: Anaesthesia for ventriculoperitoneal shunts. *S Afr J Anaesth Analg* 2011;17:72-4.
- DiNardo JA, editor. Anesthesia for congenital heart disease. In: *Anesthesia for Cardiac Surgery*. Stanford: Appleton and Lange; 1998. p. 141-200.
- Mane S, Rao S, Ladi SD, Aphale SS. Dandy walker syndrome, case report. *Innov J Med Health Sci* 2014;4:309-11.
- Baun VC, Desouza DG. Congenital heart diseases in adults. In: Kaplan JA, editor. *Cardiac Anaesthesia: The Echo Era*. 6th ed. Philadelphia, PA: Elsevier, Saunders; 2011. p. 415-36.

Cite this article as: Datt V, Tempe DK, Lalwani P, Aggarwal S, Kumar P, Diwakar A, et al. Perioperative management of a patient with Dandy Walker malformation with tetralogy of Fallot undergoing total correction and fresh homologous pericardial pulmonary valve conduit implantation: Report of a rare case. *Ann Card Anaesth* 2015;18:433-6.

Source of Support: Nil, **Conflict of Interest:** None declared.