

A 20-year retrospective study of histopathologic patterns of gonadal germ cell tumors in males in the University of Benin Teaching Hospital

Odokuma Emmanuel Igho

Department of Human Anatomy and Cell Biology, Delta State University, Abraka, Delta State, Nigeria

ABSTRACT

Background: Localization of germ cells tumors to the gonads is not uncommon and has been shown to possess good prognosis with appropriate treatment. Studies on the prevalence and histopathologic features of these tumors in Nigerians are, however, rare. This study was, therefore, aimed at determining the pattern of gonadal germ cell tumors (GGCTs) in Benin and environs. **Materials and Methods:** This was a 20-year retrospective study conducted at the University of Benin Teaching Hospital 9-(UBTH), a tertiary health facility in Benin City. Data were obtained from the histopathology day book of the Department of Morbid Anatomy of the UBTH, and permission was obtained from the UBTH Ethics Committee protocol number ADM/E 22/A/VOL.VH/928 with results displayed in tables and figures. **Results:** Intratubular germ cell neoplasms (ITGN) was the most common GGCT with about 33.3% of the total and was distributed within the fourth to fifth decades of life; benign cystic teratoma and choriocarcinoma were observed to have a low occurrence with 8.3% each found in age groups 11–20 and 21–30 years, respectively. The studied gonadal lesions were most frequent at the left testis and were predominantly premalignant forms. **Conclusion:** This was an index study on patterns of GGCTs in males in UBTH, and it showed that GGCTs in males were predominantly premalignant with ITGN as the most common type of testicular germ cell tumors.

Key words: Gonadal, histopathology, male, premalignant, retrospective

Address for correspondence:

Dr. Odokuma Emmanuel Igho,
Department of Human Anatomy and
Cell Biology, Delta State University,
Abraka, Delta State, Nigeria.
E-mail: secretfiles1800@yahoo.com

INTRODUCTION

Germ cells have been described as cells that give rise to gametes.¹ Though it is generally accepted that germ cell tumors arise from germ cells, arguments regarding the specific stage of development of the various tumors are profound. The most accepted theory is that these tumors may have arisen at any stage of development.² Gonadal germ cell tumors (GGCTs) are commoner in the young and vary in behavior from benign to frankly malignant forms.³ In the testis, the existence of preinvasive carcinoma *in situ* and intratubular germ cell neoplasms (ITGN) have further supported the claim that testicular lesions may have arisen from the cells of the testis.³ Though the etiology of these lesions is

unknown, it has been postulated that the disease process starts in fetal life and consists of cells with abnormal differentiation.⁴ Similarly, cryptorchidism, low birth weight, renal transplant, HIV/AIDS, and male infertility are associated factors.⁵⁻⁷ The aim of this study was to determine the histopathological patterns of GGCTs in males. Currently, there is a dearth of germ cell tumors, especially in Nigeria, and some germ cell tumors, especially the malignant varieties have been known to display fatal consequences.^{8,9} This study will provide empirical data of these lesions, especially in health management and policy making.

This is an open access article distributed under the terms of the Creative Commons Attribution-NonCommercial-ShareAlike 3.0 License, which allows others to remix, tweak, and build upon the work non-commercially, as long as the author is credited and the new creations are licensed under the identical terms.

For reprints contact: reprints@medknow.com

How to cite this article: Igho OE. A 20-year retrospective study of histopathologic patterns of gonadal germ cell tumors in males in the University of Benin Teaching Hospital. Niger Med J 2015;56:385-9.

Access this article online

Quick Response Code:



Website:

www.nigeriamedj.com

DOI:

10.4103/0300-1652.171619

MATERIALS AND METHODS

This was a retrospective record of all patients seen in consultation by the Department of Morbid Anatomy, University of Benin Teaching Hospital (UBTH) during the 20 years period commencing January 1, 1991, and ending December 31, 2010, retrospectively. Information including age, location, and pattern of lesion were obtained from the pathology records of the institution.

Gonadal germ cell tumors (GGCTs) from all age ranges and involving male samples were used for this study. The study included both samples from inpatient, outpatients, and those from health facilities outside UBTH.

Records in which age were not specified were excluded from this study.

Patients and Methods

Formalin-fixed, paraffin-embedded tissue specimen sectioned at 3 µm and stained with hematoxylin, and eosin was used for this study. The lesion was individually reviewed and standardized in accordance with a standard classification system. For the purpose of analysis, the type of tumor, age of the patient, and the site of the tumor was recorded for each case. The Statistical Package for the Social Sciences (SPSS) version 16, IBM and Microsoft Excel (Version 2012) was used to analyze the data, and a digital compound microscope (Brunel SP35 Digital, model: DN-107T, No 000026 www.brunelmicroscopes.cp.uk. www.digital-microscopes.co.uk) was used to capture the slides. The results were presented in tables and slides.

Approval for this study was obtained from the UBTH Ethics Committee with protocol number ADM/E 22/A/VOL.VH/928.

RESULTS

Table 1 showed the distribution of GGCT in males according to age distribution and anatomical sites which majority occurred at the left testis with 58% (7) followed by that at unspecified regions (25%). About 8.3% of the lesion occurred at the right and bilateral sites each. From the table, 25% of the tumors occurred in the fifth decades of life, 25% at the 0–10 age interval, 8.3% at the second, fourth, sixth, and eight decades of life, respectively, about 17% of GGCT was recorded in the third decade in this study.

Benign cystic teratoma constituted 8% (1) of the entire GGCTs recorded in this study [Table 2]. Benign cystic teratomas (BCT) occurred in an unspecified site [Table 3]. All these tumors occurred at the first decade of life constituting 33% of the cases recorded at that age group [Table 2]. A section of one of the lesions showed a cystic lesion lined by stratified epithelium whose lumen was fluid and cell debris. In the wall, loose connective

tissues stromas in which were clusters of sebaceous glands as shown in Figure 1 (slide A).

A case of choriocarcinoma (CHOCA) was recorded during the study period [Tables 1-3]. It accounted for 8% of the GGCTs in this study [Table 3]. The single CHOCA was located in the left testis [Table 3]. This tumor was observed to occur in the second decade of life. The cellular components were arranged in varying pattern in an extensively hemorrhagic and necrotic background.

Embryonal carcinoma accounted for about 17% (2) of GGCT in males as shown in Table 3. The tumors were located in the left testis [Table 3]. Embryonal Carcinoma was found to occur in the first and eight decades of life. Section showed

Table 1: Distributions of gonadal germ cell tumor according to age and site

Age interval	Right	Left	Bilateral	Unspecific	Total	F (%)
0-10	1	1		1	3	25
11-20		1			1	8
21-30		2			2	17
31-40		1			1	8
41-50			1	2	3	25
51-60		1			1	8
61-70						
71-80		1			1	8
Total	1	7	1	3	12	100

Table 2: Distribution of types of gonadal germ cell tumor with anatomical site

Types	Right	Left	Bilateral	Unspecific	Total	F (%)
BCT				1	1	8
ITGCN		1	1	2	4	33
EC		2			2	17
YST	1	1			2	17
SEM		2			2	17
CHOCA		1			1	8
Total	1	7	1	3	12	100

BCT – Benign cystic teratoma; ITGCN – Intratubular germ cell neoplasm; EC – Embryonal carcinoma; YST – Yolk sac tumor; SEM – Seminoma; CHOCA – Choriocarcinoma

Table 3: Age distribution of the various types of gonadal germ cell tumors

Age interval	BCT	ITGCN	EC	YST	SEM	CHOCA
0-10	1			1		
11-20						1
21-30					2	
31-40				1		
41-50		3				
51-60		1				
61-70						
71-80			1			
Total	1	4	1	2	2	1

BCT – Benign cystic teratoma; ITGCN – Intratubular germ cell neoplasm; EC – Embryonal carcinoma; YST – Yolk sac tumor; SEM – Seminoma; CHOCA – Choriocarcinoma

a lesion composed of tubule-like structures; dispose in a fibromyxoid connective tissue stroma. The tubules were lined by stratified columnar epithelium with the cells displaying an overlapping basophilic nuclear appearance and indistinct cell boundaries as shown in Figure 1 (slide B).

Intratubular germ cell neoplasm (ITGN) were observed to constitute 33.3% of the GGCTs [Table 3], and it occurred in the fifth and sixth decades [Table 2]. A single lesion was observed in the left testes, another case recorded bilaterally and two cases in unspecified male gonadal sites (50%) [Table 3]. Sections of the test are showed a malignant neoplasm composed of seminiferous tubules of various size dispose within a loose connective tissue stroma in which were few sheaths of interstitial cell Leydig. The individual tubules were lined by germ cell with extensively vacuolated cytoplasm, and most tubules showed a single layer of these cells which had variable, small, and vesicular nuclei. Some of them have prominent nucleoli, with their lumens filled with cell debris and fluid as shown in Figure 1 (slide C).

Two cases of seminomas were recorded in this study [Tables 2 and 3] with the lesion accounting for 17% of GGCTs. Both cases were confined to the left testes and distributed between the second and the third age group intervals [Table 2]. Involved section of the test is showed a malignant neoplasm composed of variable sized seminiferous tubules disposed within the sheaths of interstitial cell of Leydig. Abundant areas of intratubular cell neoplasm were seen but on a focus, there was invasion of the basement membrane extending into the blood vessel as shown in Figure 1 (slide E).

Yolk sac tumor accounted for 17% of the entire GGCT in this study as shown in Tables 2 and 3. The tumors occurred at the right and left testis, respectively, were distributed in the first and fourth decade of life [Table 2]. Sections showed a tumor composed of the sheath of round blue cell, some of which were disposed in cysts and pseudorosette (Schiller-Duval bodies). There was palisading in some of the rosette. Individual cell had round to oval vesicular nuclei with some show is abnormal mitosis and scant amphophilic cytoplasm. The cells are invaded the surrounding connective tissue stroma and blood vessels, with foci of hemorrhage also seen as shown in Figure 1 (slide I).

DISCUSSION

This study recorded 12 cases of GGCTs over the 20 years period (1990–2010), in the Department of Morbid Anatomy/Histopathology, UBTH, Benin City with ITGN accounting for the majority of tumors recorded.

BCT was the only benign testicular tumor recorded in this study, and it constituted a small percentage of GGCTs. This finding was not different from previous reports in which

BCT was observed to constitute about 4% of the gonadal testicular germ cell tumors.^{2,10} An important finding also was that all the BCT tumors recorded in the index study were cystic which has been declared by several authors as rare, especially in children. The findings of this study, however, showed that the lesion was only present in children^{1,2,11} which could be explained by the elevation in early childhood of androgens and gonadotropins to the heightened levels peculiar to puberty.^{12,13}

ITGN have been described as the precursor lesion for all testicular germ cell neoplasms (except spermatocytic seminoma, yolk sac tumors, and teratomas of infancy).¹⁴⁻¹⁷ This could explain the predominance of this tumor over other germ cell tumor which would all likely have arisen from ITGCN¹⁷ that accounted for most cases of postpubertal germ cell tumors recorded in this study. This was similar to the observation of by Burke and Mostofi in which ITGCN's were recorded in approximately 82% of germ cell tumors of postpubertal patients. The reason for the observed age distribution was most likely infertility, a common reason for males with testicular complaints to present to a hospital.¹⁸ Males in their forties and fifties suspected to be infertile may present in the hospital, and the process of investigation may result in detection of this lesion. This could explain the age group distribution in this study.

Embryonal carcinoma has been described as a rare germ cell tumor and Mills further stated that it was uncommon among testicular tumors and accounted for approximately 10% of testicular germ cell tumors.¹⁹ Elsewhere, it was noted that it was the third most common testicular germ cell tumor in children²⁰ as was observed in this study. It can, therefore, be concluded that embryonal carcinoma was rare germ cell tumors.

Yolk sac tumors have been observed to constitute 65% of testicular germ cell tumor in children with median age of 1.5 years.²¹ It was earlier described in children before the age of two and observed to be extremely rare in adults.⁷ In the index study, though yolk sac tumor contributed a minor percentage to the entire germ cell tumors recorded, it was the most common germ cell tumor in male children.⁷

Prior studies have recorded seminomas as the most common testicular germ cell tumor,²¹⁻²⁴ this was not the case in this study where it was observed to constitute only about the fifth of the cases. Similarly, reports in the East Asia revealed that only 22% of germ cell tumors were found to be seminomas.²⁵ The reason for these observations could likely be a result of the small population studied. As was demonstrated in the index study, other reports have recorded that seminoma occurred between the third and fourth decades of life^{9,26,27} and rarely occurred before the age of five.²³

CHOCA has been described as a rare malignant neoplasm originating from anaplastic trophoblastic tissue.⁹ CHOCA

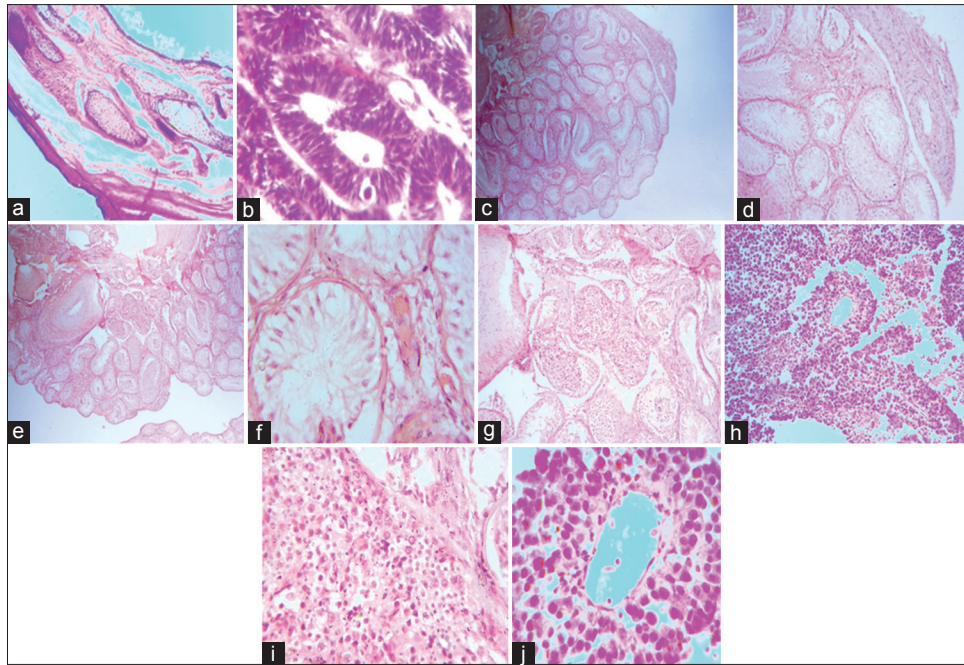


Figure 1: (a) Benign cystic teratoma (H and E, $\times 100$); (b) embryonal carcinoma (H and E, $\times 400$); (c) intratubular germ cell neoplasm ($\times 40$); (d) intratubular germ cell neoplasm ($\times 100$); (e) seminoma (H and E, $\times 40$); (f) intratubular germ cell neoplasm ($\times 400$); (g) seminoma (H and E, $\times 100$); (h) seminoma (H and E, $\times 400$); (i) yolk sac tumor (H and E, $\times 100$); (j) yolk sac tumor (H and E, $\times 400$)

has been reported to occur as a component of testicular tumors and presented almost exclusively in the second and third decades of life as was reported in this study though no specific reason for the occurrences of this tumor in this age interval has been identified.²⁸

CONCLUSION

This study has clearly demonstrated and described the pattern of GGCT in males in South Southern Nigeria. Individual descriptions of tumor types were explicitly outlined with reference to the site, age distribution, and frequency. The study clearly demonstrated that GGCTs in male were predominantly premalignant with ITGN constituting the most common type.

Financial support and sponsorship

Nil.

Conflicts of interest

There are no conflicts of interest.

REFERENCES

1. Albert B, Johnson A, Lewis J, Raff M, Roberts K, Water P. Molecular Biology of the Cell. Vol. 10. New York: Garland Science; 2002. p. 4072-9.
2. Raghavan D, Neville M. Biology of germ cell tumour. In: Raghavan D, editor. Germ Cell Tumors. London: BC Decker Inc.; 2003. p. 5-6.
3. Damjanov I. Pathology. In: Raghavan D, editor. Germ Cell Tumors. London: BC Decker Inc.; 2003. p. 4-37.
4. Bosl GJ, Motzer RJ. Testicular germ-cell cancer. N Engl J Med 1997;337:242-53.
5. Nichols CR, Heerema NA, Palmer C, Loehrer PJ Sr, Williams SD, Einhorn LH. Klinefelter's syndrome associated with mediastinal germ cell neoplasms. J Clin Oncol 1987;5:1290-4.
6. Timmerman JM, Northfelt DW, Small EJ. Malignant germ cell tumors in men infected with the human immunodeficiency virus: Natural history and results of therapy. J Clin Oncol 1995;13:1391-7.
7. Woodward PJ, Heidenreich A, Looijenga LH, Oosterhus JW, Mcleod DG, Moler H, *et al.* Tumour of the urinary system and male genital organ: Epidemiology, clinical features, histopathological typing and grading. In: Eble JN, Sauter G, Epstein JI, Sesterhem IA, editors. World Health Organization Classification of Tumour. Pathology and Genetic of Tumour of the Urinary System and Male Genital Organ. 6th ed. Lyon: IARC Press; 2004. p. 221.
8. Salako AA, Onakpoya UU, Osasan SA, Omoniyi-Esan GO. Testicular and para-testicular tumors in south western Nigeria. Afr Health Sci 2010;10:14-7.
9. Mohammed A, Aliyu HO. Childhood cancers in a referral hospital in Northern Nigeria. Indian J Med Paediatr Oncol 2009;30:95-8.
10. Ulbright TM. Germ cell tumors of the gonads: A selective review emphasizing problems in differential diagnosis, newly appreciated, and controversial issues. Mod Pathol 2005;18 Suppl 2:S61-79.
11. Walsh TJ, Grady RW, Porter MP, Lin DW, Weiss NS. Incidence of testicular germ cell cancers in U.S. children: SEER program experience 1973 to 2000. Urology 2006;68:402-5.
12. Forest M. Pituitary gonadotropin and sex steroid secretion during the first two years of life. In: Grunbach MM, Sizonenko PC, Aubert ML, editors. Control of the Onset of Puberty II. Baltimore: Lippincott, Williams and Wilkins; 1990. p. 451-770.
13. Mann DR, Fraser HM. The neonatal period: A critical interval in male primate development. J Endocrinol 1996;149:191-7.

14. Bettocchi C, Coker CB, Deacon J, Parkinson C, Pryor JP. A review of testicular intratubular germ cell neoplasia in infertile men. *J Androl* 1994;15 (14S-6S): 14S-6S.
15. Müller J, Skakkebaek NE, Parkinson MC. The spermatocytic seminoma: Views on pathogenesis. *Int J Androl* 1987;10:147-56.
16. Manivel JC, Simonton S, Wold LE, Dehner LP. Absence of intratubular germ cell neoplasia in testicular yolk sac tumors in children. A histochemical and immunohistochemical study. *Arch Pathol Lab Med* 1988;112:641-5.
17. Burke AP, Mostofi FK. Intratubular malignant germ cells in testicular biopsies: Clinical course and identification by staining for placental alkaline phosphatase. *Mod Pathol* 1988;1:475-9.
18. Burke AP, Mostofi FK. Placental alkaline phosphatase immunohistochemistry of intratubular malignant germ cells and associated testicular germ cell tumors. *Hum Pathol* 1988;19:663-70.
19. Mills S, editor. *Sternberg' Diagnostic Pathology*. 5th ed. Lippincott: Williams and Wilkins; 2010.
20. Sesterhenn IA, Davis CJ Jr. Pathology of germ cell tumors of the testis. *Cancer Control*. 2004;11:374-87.
21. Singer G, Kurman RJ, McMaster MT, Shih IeM. HLA-G immunoreactivity is specific for intermediate trophoblast in gestational trophoblastic disease and can serve as a useful marker in differential diagnosis. *Am J Surg Pathol* 2002;26:914-20.
22. Berney DM, Warren AY, Verma M, Kudahetti S, Robson JM, Williams MW, *et al*. Malignant germ cell tumours in the elderly: A histopathological review of 50 cases in men aged 60 years or over. *Mod Pathol* 2008;21:54-9.
23. Bahrami A, Ro JY, Ayala AG. An overview of testicular germ cell tumors. *Arch Pathol Lab Med* 2007;131:1267-80.
24. Zheng LW, Li FB, Liu RZ, Ji RG, Zhao ZW. Clinical analysis of 87 cases of testicular tumor. *Zhonghua Nan Ke Xue* 2005;11:445-7.
25. Tan GH, Azrif M, Shamsul AS, Ho CC, Praveen S, Goh EH, *et al*. Clinicopathological features and survival of testicular tumours in a Southeast Asian university hospital: A ten-year review. *Asian Pac J Cancer Prev* 2011;12:2727-30.
26. Park DS, Chung MK, Chung JI, Ahn HJ, Lee ES, Choi HY, *et al*. Histologic type, staging, and distribution of germ cell tumors in Korean adults. *Urol Oncol* 2008;26:590-4.
27. Purdue MP, Devesa SS, Sigurdson AJ, McGlynn KA. International patterns and trends in testis cancer incidence. *Int J Cancer* 2005;115:822-7.
28. Geraghty MJ, Lee FT Jr, Bernstein SA, Gilchrist K, Pozniak MA, Yandow DJ. Sonography of testicular tumors and tumor-like conditions: A radiologic-pathologic correlation. *Crit Rev Diagn Imaging* 1998;39:1-63.