



Detection of Incidental Prostate Cancer or Urothelial Carcinoma Extension in Urinary Bladder Cancer Patients by Using Multiparametric MRI: A Retrospective Study Using Prostate Imaging Reporting and Data System Version 2.0

방광암 환자의 다중 매개 자기공명영상에서 우연히 발견된 전립선암 또는 요로상피세포암종의 전립선 침범의 검출: 전립선 이미징 보고 및 데이터 시스템 버전 2.0을 사용한 후향적 연구

Sang Eun Yoon, MD¹ , Byung Chul Kang, MD^{1,2*†} ,
 Hyun-Hae Cho, MD^{1,2} , Sanghui Park, MD³ 

¹Department of Radiology, Ewha Womans University Mokdong Hospital, Seoul, Korea
 Departments of ²Radiology, ³Pathology, Ewha Womans University College of Medicine, Seoul, Korea

Purpose The study aimed to investigate the role of Prostate Imaging Reporting and Data System version 2 (PI-RADS v2) in predicting incidental prostate cancer (PCa) or urothelial carcinoma (UCa) extension in urinary bladder (UB) cancer patients.

Materials and Methods A total of 72 UB cancer patients who underwent radical cystoprostatectomy and 3 Tesla multiparametric MRI before surgery were enrolled. PI-RADS v2 ratings were assigned by two independent radiologists. All prostate specimens were examined by a single pathologist. We compared the multiparametric MRI findings rated using PI-RADS v2 with the pathologic data.

Results Of the 72 UB cancer patients, 29 had incidental PCa (40.3%) and 20 showed UCa exten-

Received June 8, 2019
 Revised August 19, 2019
 Accepted September 27, 2019

***Corresponding author**

Byung Chul Kang, MD
 Department of Radiology,
 Ewha Womans University
 Mokdong Hospital,
 Ewha Womans University
 College of Medicine,
 1071 Anyangcheon-ro,
 Yangcheon-gu, Seoul 07985,
 Korea.

Tel 82-2-2650-5092

Fax 82-2-2650-5302


E-mail kangchwangsj@yuhs.ac

This is an Open Access article distributed under the terms of the Creative Commons Attribution Non-Commercial License (<https://creativecommons.org/licenses/by-nc/4.0>) which permits unrestricted non-commercial use, distribution, and reproduction in any medium, provided the original work is properly cited.

ORCID iDs

Sang Eun Yoon 
<https://orcid.org/0000-0002-2472-8691>

Byung Chul Kang 
<https://orcid.org/0000-0002-5536-7796>

Hyun-Hae Cho 
<https://orcid.org/0000-0002-4865-2601>

Sanghui Park 
<https://orcid.org/0000-0003-3837-8677>

† Current address

Department of Radiology,
 Severance Hospital,
 Yonsei University
 College of Medicine, Seoul, Korea

sion (27.8%), with an overlap for 3 patients. With a score of 4 as the cut-off value for predicting incidental PCa, the diagnostic accuracy was 65.3%, specificity was 90.7%, and positive predictive value (PPV) was 66.7%. The diagnostic accuracy for incidental UCa extension was 47.2%, specificity was 92.3%, and PPV was 83.3%.

Conclusion Despite the low diagnostic accuracy, the PPV and specificity were relatively high. Therefore, PI-RADS v2 scores of 1, 2, or 3 may help exclude the probability of incidental PCa or UCa extension.

Index terms Cystectomy; Magnetic Resonance Imaging; Prostate Cancer; Urinary Bladder Cancer

INTRODUCTION

The gold standard treatment for localized high-grade muscle-invasive carcinoma of the bladder is radical cystoprostatectomy (CPT), and this includes the removal of the prostate, seminal vesicles, and vas deferens in male patients (1). Radical CPT can cause functional morbidities such as urinary incontinence or erectile dysfunction (2). It is known that the prevalence of incidental prostate cancer (PCa) far exceeds that of clinically detected disease (3). The prostate is involved in urothelial carcinoma (UCa) in up to 48% of patients undergoing radical CPT for urinary bladder (UB) cancer (4). In addition, PCa is detected incidentally in up to 40% of UB cancer patients, and up to 50% of incidental PCa cases are clinically significant (3).

The updated Prostate Imaging Reporting and Data System version 2 (PI-RADS v2) was established and standardized for the interpretation and systematic reporting of prostate MRI (5, 6). The main purpose of PI-RADS v2 is the efficient and reproducible detection of clinically significant PCa with multiparametric MRI (mpMRI) (5, 6). Several studies have demonstrated the use of PI-RADS v2 in the evaluation of PCa (7). However, no studies have reported the use of PI-RADS v2 for detecting incidental PCa or UCa extension of the prostate in UB cancer patients. To the best of our knowledge, our study is the first to compare the MRI rated by PI-RADS v2 with the pathologic data of UB cancer patients. We hypothesized that PI-RADS v2 could help identify the presence of incidental PCa or UCa extension by using it as a valid screening protocol for the risk stratification of occult prostatic malignancy (incidental PCa or UCa extension of the prostate) in UB cancer patients. We used PI-RADS v2 to retrospectively detect incidental PCa or UCa extension of the prostate in patients undergoing radical CPT for UB cancer and compared the results with histopathologic findings. Based on the results, we determined whether PI-RADS v2 could help predict incidental PCa or UCa extension of the prostate in UB cancer.

MATERIALS AND METHODS

STUDY SUBJECTS

The Institutional Review Board of our institution approved this retrospective study and waived the requirement for informed consent owing to the retrospective design of the study (EUMC 2019-05-018).

A total of 72 consecutive male UB cancer patients who were scheduled to undergo radical CPT and had no history of PCa, normal digital rectal exam before surgery were enrolled in this study between October 2016 and December 2017 at a single institution. Preoperatively, mpMRI and serum prostate-specific antigen (PSA) assay were performed for all enrolled UB cancer patients. In addition, radical CPT with bilateral pelvic lymphadenectomy was performed.

HISTOPATHOLOGIC EVALUATION

Radical CPT specimens were immersed intact in formalin solution. Complete transverse sections were taken from the apex to the base at 4 mm intervals. All prostates were examined by a single pathologist. The 2002 TNM classification system was used to determine the pathologic stage. The Gleason score (GS), presence of extracapsular extension, and evidence of seminal vesicle invasion were assessed. According to the Epstein criteria, clinically insignificant cancer is defined as $GS \leq 6$, organ-confined tumor (category $< T3$), and tumor volume < 0.5 cc based on the pathologic findings of the surgical specimen (8).

IMAGING ACQUISITION AND ANALYSIS

Preoperative mpMRI was performed with 3.0 Tesla MRI (Achieva; Philips Healthcare System, Gainesville, FL, USA) for UB cancer staging and incidental PCa detection. The patients were examined in the supine position using a 16-channel SENSE-XL-Torso coil (In Vivo; Philips Healthcare System). The MRI protocol was composed of routine T1-weighted imaging, T2-weighted imaging, diffusion-weighted imaging (DWI), and dynamic contrast-enhanced (DCE) imaging. After obtaining three-plane localizer images, T2-weighted images were obtained in the axial, sagittal, and coronal planes. The imaging parameters were as follows: repetition time (TR)/echo time (TE), 2900–3800/80–100 ms; slice thickness, 3 mm; interslice gap, 1 mm; matrix, 520×247 ; field of view (FOV), 240×240 mm; number of signals acquired (NSA), 3. Axial T1-weighted turbo spin-echo images (4 mm slice thickness) were acquired to assess the lymph nodes and the pelvic bone. Axial DWI was performed using the single-shot echo-planar imaging technique with the following parameters: TR/TE, 5000–5500/64–66 ms; slice thickness, 3–4 mm; interslice gap, 1 mm; matrix, 112×108 ; FOV, 220×220 mm; NSA, 4. Diffusion-encoding gradients were applied at b values of 0 and 1400 s/mm^2 along the three orthogonal directions of the motion-probing gradients. We also acquired DWI for UB cancer, which was obtained axial plane with free breathing, fast spin-echo echo-planar imaging. The imaging parameters were as follows: TR/TE, 5000–6000/76.39–63.96 ms; b values of 0, 100, and 1000 s/mm^2 ; matrix, 124×124 ; slice thickness, 4.0–5.0 mm; interslice gap, 0 mm; number of excitations, 8.0; FOV, 250×250 . The direction of the phase-encoding gradient was from the left to right to minimize motion artifacts. Apparent diffusion coefficient maps were automatically constructed on a pixel-by-pixel basis using the manufacturer's software.

For axial DCE-MRI, fat-saturated T1-weighted fast-field-echo images (echo-planar imaging) with a temporal resolution of 4–7 s were acquired before and after a bolus injection of gadolinium diethylenetriamine pentaacetic acid (Gadavist; Bayer Schering Pharma, Berlin, Germany) at a rate of 2–3 mL/s through a power injector at a dose of 0.1 mmol/kg body weight, followed by a 20 mL saline flush. The imaging parameters were as follows: TR/TE, 400–700/8–

10 ms; flip angle, 90°; matrix, 512 × 256; slice thickness, 4 mm; interslice gap, no; FOV, 240 × 240 mm; NSA, 1. DCE-MRI was performed from the apex to the base of the prostate. Before MRI, 20 mg of butylscopolamine (Buscopan; Boehringer Ingelheim, Ingelheim am Rhein, Germany) was injected intramuscularly to suppress bowel peristalsis.

All of the MR images were archived in a PACS (PathSpeed Workstation; GE Healthcare, Chicago, IL, USA) for image interpretation. All MR images were retrospectively reviewed by two experienced radiologists (19 and 3 years of experience in prostate MRI). They were blinded to pathologic results; however, the readers were aware that all patients had undergone radical CPT for UB cancer. They evaluated the PI-RADS v2 score (S) for the peripheral zone, transitional zone and the highest score of PI-RADS v2 was assigned for each patient (Figs. 1, 2).

Fig. 1. A 55-year-old man with pT2b urinary bladder cancer and clinically significant PCa, a Gleason score of 7 (4 + 3) based on the surgical specimen, and a baseline prostate-specific antigen level of 1.13 ng/mL.

A. Axial T2-weighted MR image shows a 1.3-cm lenticular-shaped lesion (arrow) with an indistinct margin and a moderately hypointense lesion in the right anterior transition zone at the base level (T2-weighted imaging score: 4).

B, C. High b-value ($b = 1400 \text{ s/mm}^2$) diffusion-weighted MR image (**B**) and ADC map (**C**) showing a markedly hyperintense lesion on DWI (arrow on **B**) and a markedly hypointense lesion on the ADC map (arrow on **C**) (DWI-ADC imaging score: 4). Since T2-weighted MR imaging is the primary method for assessing transition zone abnormalities, this focal lesion was assigned a PI-RADS v2 score of 4.

D. Pathologic specimen show clinically significant PCa (arrow).

ADC = apparent diffusion coefficient, DWI = diffusion-weighted imaging, MR = magnetic resonance, PCa = prostate cancer, PI-RADS v2 = Prostate Imaging Reporting and Data System version 2

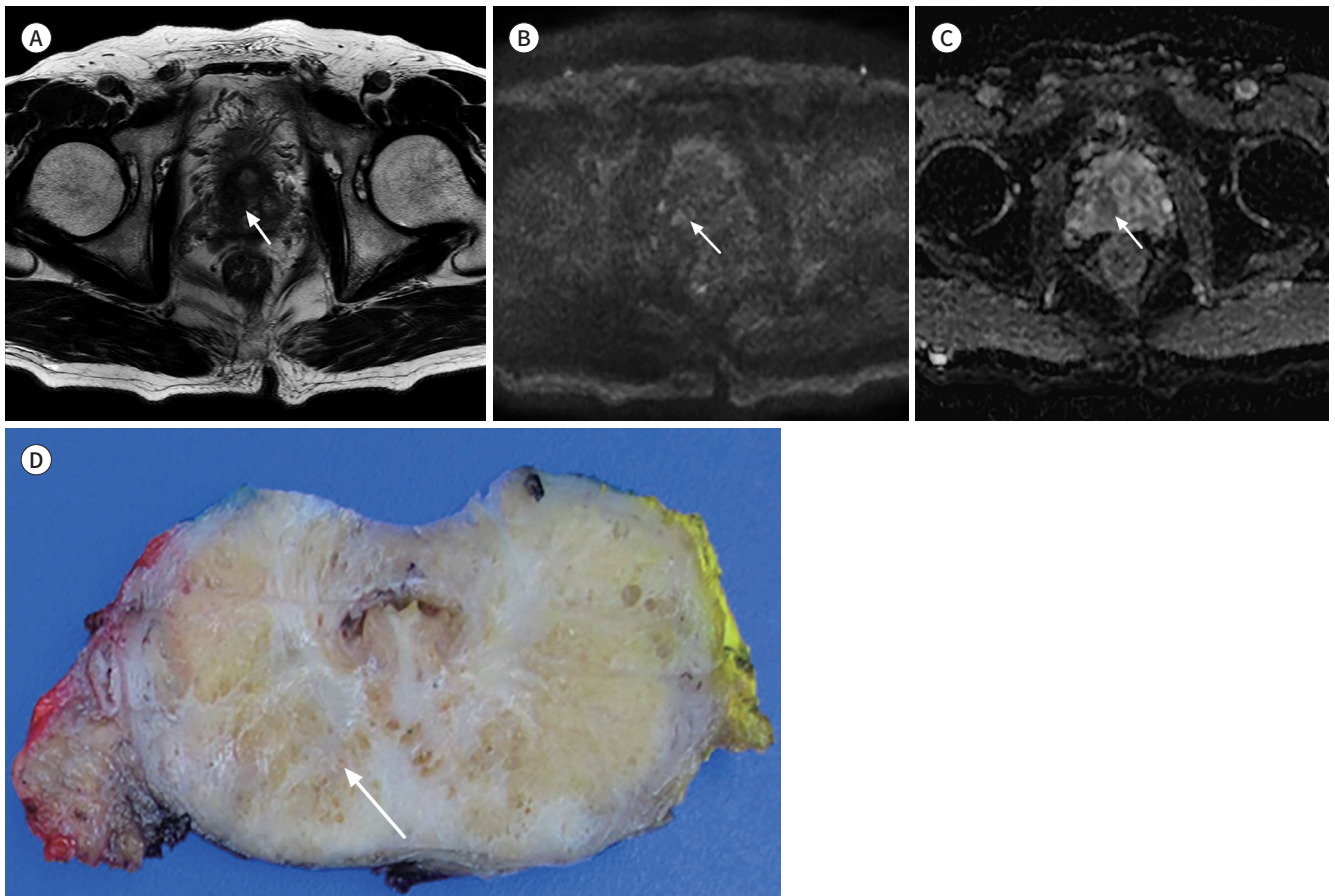


Fig. 2. A 72-year-old man with pT2b urinary bladder cancer and clinically insignificant PCa, a Gleason score of 6 (3 + 3) based on the surgical specimen, and a baseline prostate-specific antigen level of 3.82 ng/mL.

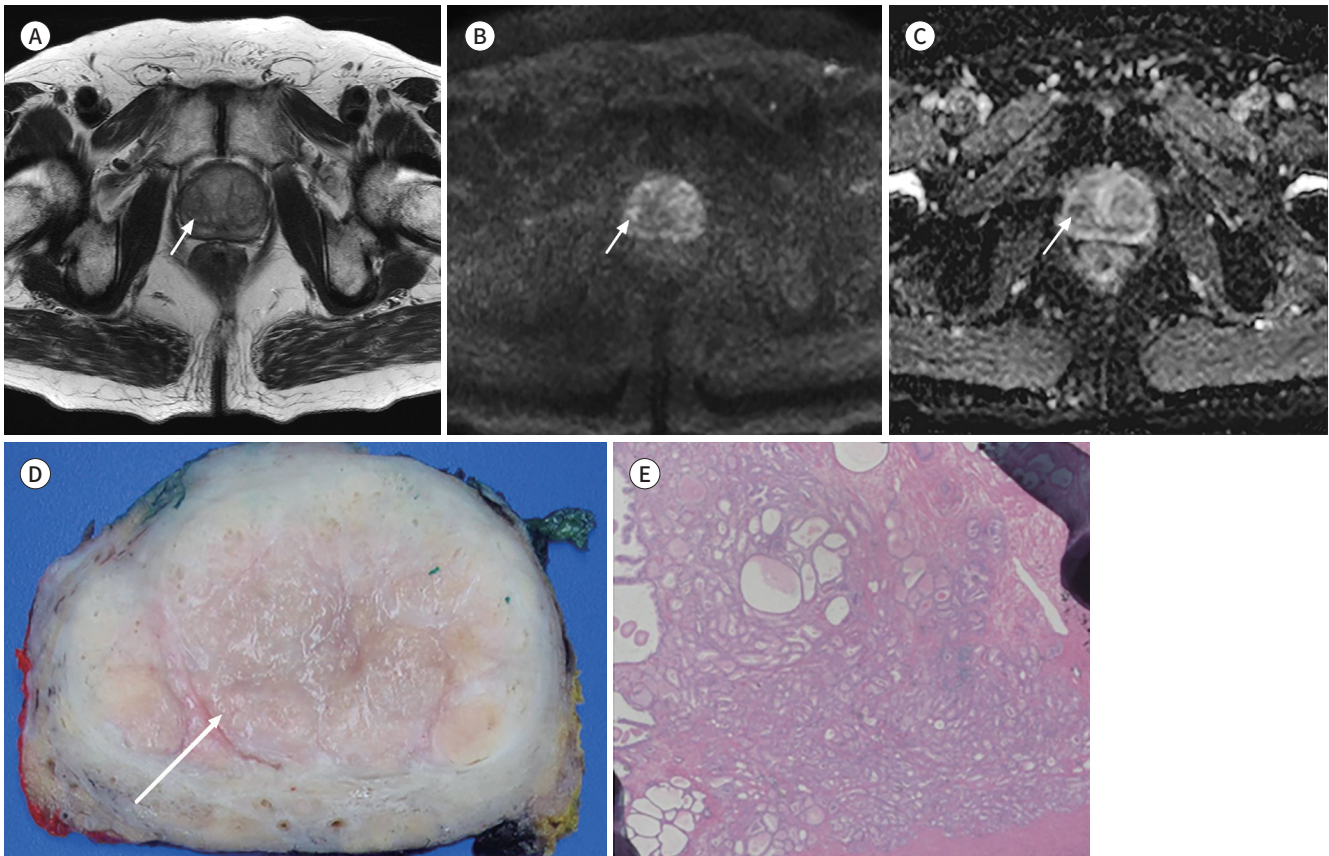
A. Axial T2-weighted MR image shows a focal heterogeneous signal intensity with an obscured margin (arrow) in the right anterior transition zone at the mid-gland (T2-weighted imaging score: 3).

B, C. High b-value ($b = 1400 \text{ s/mm}^2$) diffusion-weighted MR image (**B**) and ADC map (**C**) show a markedly hyperintense lesion on DWI (arrow on **B**) and hypointense lesion on the ADC map (arrow on **C**) (DWI-ADC imaging score: 4). Since T2-weighted MR imaging is the primary method for assessing transition zone abnormalities, this focal lesion was assigned a PI-RADS v2 score of 3.

D. Pathologic specimen shows clinically insignificant PCa (arrow).

E. Microscopic findings shows the crowded, relatively uniform glands of prostatic adenocarcinoma in a back-to-back arrangement (GS of 6) (hematoxylin-eosin stain, $\times 100$).

ADC = apparent diffusion coefficient, DWI = diffusion-weighted imaging, GS = Gleason score, MR = magnetic resonance, PCa = prostate cancer, PI-RADS v2 = Prostate Imaging Reporting and Data System version 2



STATISTICAL ANALYSIS

The prevalence of incidental PCa and UCa extension of the prostate in the radical CPT specimens was assessed, and the clinical significance of these cancers was determined. Then, the clinical characteristics of these patients were examined, and the relationship between clinical parameters including age, PSA, and pathologic information was determined. Differences were determined by chi-square test ($p < 0.01$).

The patients were grouped according to their pathologic results (normal prostate or hyperplastic prostate, prostatitis, incidental PCa, UCa extension of the prostate). Subsequently, the MRI rated by PI-RADS v2 was compared with the patient pathologic results, and the diagnostic accuracy, specificity, sensitivity, positive predictive value (PPV), and negative predictive value (NPV) were calculated using S3 or S4 as a cut-off value for cancer prediction. SPSS for Win-

dows version 12.0 (SPSS Inc., Chicago, IL, USA) was used for all statistical analyses, and $p < 0.05$ was considered significant.

RESULTS

PATIENT CHARACTERISTICS

The clinicopathological characteristics of the 72 patients are summarized in Table 1. Radical CPT with neobladder formation or ileal conduit formation was performed for all 72 patients. The mean age and preoperative PSA level of the patients were 65.1 ± 10.2 years and 2.42 ± 2.34 ng/mL, respectively. Of the 72 UB cancer patients, the overall incidence of incidental PCa or UCa extension of the prostate was 63.4% (46 patients). And 29 patients (40.3%) had incidental PCa, which was diagnosed after surgery. The mean age of patients with incidental PCa and without incidental PCa was 68.0 ± 9.3 years and 63.3 ± 10.4 years, respectively, and this difference was significant ($p = 0.017$). The mean serum PSA level of patients with incidental PCa was similar to that of patients without incidental PCa (2.50 ± 2.66 ng/mL and 2.36 ± 2.13 ng/mL, respectively) ($p = 0.036$). UCa extension of the prostate was identified

Table 1. Baseline Characteristics of the Patients with Urinary Bladder Cancer ($n = 72$)

Parameters	Total	Incidental PCa		<i>p</i> -Value
		No	Yes	
No. of patients (%)	72 (100)	43 (59.7)	29 (40.3)	
Age, years				
Median (SD)	68 (37–84)	64 (37–84)	70 (44–83)	
Mean (SD)	63.1 (10.2)	63.3 (10.4)	68.0 (9.3)	0.017
PSA, ng/mL				
Median (SD)	1.32 (<0.1–11.26)	1.21 (<0.1–9.29)	1.58 (0.25–11.26)	
Mean (SD)	2.42 (2.34)	2.36 (2.13)	2.50 (2.66)	0.036

PCa = prostate cancer, PSA = prostate-specific antigen, SD = standard deviation

Table 2. Baseline Characteristics of the Patients with Incidental PCa ($n = 29$)

Parameters	Total	Clinically significant PCa		<i>p</i> -Value
		No	Yes	
No. of patients (%)	29 (100)	16 (55.2)	13 (44.8)	
Age, years				
Median (SD)	70 (44–83)	69.5 (54–79)	73 (44–83)	
Mean (SD)	67.97 (9.25)	67.94 (7.22)	68.0 (11.6)	0.012
PSA, ng/mL				
Median (SD)	1.58 (<0.1–11.26)	2.27 (<0.1–9.29)	1.22 (0.25–11.26)	
Mean (SD)	2.50 (2.66)	2.87 (2.47)	2.14 (2.89)	0.140
Gleason score				
6	17	16	1	
7	11	0	11	
8–10	1	0	1	

PCa = prostate cancer, PSA = prostate-specific antigen, SD = standard deviation

in 20 patients (27.8%), with an overlap with incidental PCa for 3 of these patients.

And of these 29 patients with incidental PCa, clinically significant PCa was found in 13 patients (44.8%) (18.1% of all UB cancer patients; Table 2). The mean age of patients with clinically significant PCa was similar to that of clinically insignificant PCa patients (68.0 ± 11.6 years and 67.9 ± 7.2 , respectively) ($p = 0.012$). The mean serum PSA level of patients with clinically significant PCa (2.14 ± 2.89 ng/mL) was lower than that of clinically insignificant PCa patients (2.87 ± 2.47 ng/mL), but the result was statistically non-significant ($p = 0.140$).

PATHOLOGY-PI-RADS V2 CORRELATION

We compared PI-RADS v2 results with the pathologic findings of UB patients undergoing radical CPT. We used the S3 and S4 of PI-RAD v2 as the cut-off value according to the pathologic results, and the results are summarized in Table 3.

Of the 72 UB cancer cases, 46 cases (63.4%) involved underlying incidental PCa or UCa extension. In addition, based on PI-RADS v2, 25 cases (34.7%) were classified as over S3, and 10 cases (13.9%) were classified as over S4. With S4 as a cut-off value for predicting incidental PCa or UCa extension, the diagnostic accuracy was 47.2%, specificity was 92.3%, PPV was 83.3%, and NPV was 40.0%. With S3 as a cut-off value for predicting incidental PCa or UCa extension, the diagnostic accuracy was 63.9%, specificity was 80.8%, PPV was 83.3%, and NPV was 50.0%.

Of the 29 incidental PCa cases, 20 cases (69.0%) were classified as over S3 by PI-RAD v2

Table 3. Pathology-PI-RADS Correlations for All 72 Urinary Bladder Cancer Patients using PI-RADS v2 Scores of 3 and 4 as Cut-Off Values ($n = 72$)

Cut-Off: S3	Peripheral Zone or Transition Zone (Higher Score)		Peripheral Zone		Transition Zone	
	S1-2	S3-5	S1-2	S3-5	S1-2	S3-5
	Normal prostate or hyperplastic prostate	20	5	23	2	22
Prostatitis	1	0	1	0	1	0
Incidental PCa	9	17	14	12	17	9
UCa extension	11	5	11	5	15	1
Incidental PCa + UCa extension	0	3	0	3	3	0
UCa extension + prostatitis	1	0	1	0	1	0

Cut-Off: S4	Peripheral Zone or Transition Zone (Higher Score)		Peripheral Zone		Transition Zone	
	S1-3	S4-5	S1-3	S4-5	S1-3	S4-5
	Normal prostate or hyperplastic prostate	23	2	24	1	24
Prostatitis	1	0	1	0	1	0
Incidental PCa	19	7	19	7	26	0
UCa extension	14	2	14	2	15	1
Incidental PCa + UCa extension	2	1	2	1	3	0
UCa extension + prostatitis	1	0	1	0	1	0

PCa = prostate cancer, PI-RADS v2 = Prostate Imaging Reporting and Data System version 2, S = score, UCa = urothelial carcinoma

Table 4. Clinically Significant PCa vs. Clinically Insignificant PCa using PI-RADS v2 Scores of 3 and 4 as Cut-Off Values ($n = 29$)

	Clinically Significant PCa	Clinically Insignificant PCa
Cut-off: S3		
S3-5	10	10
S1-2	3	6
Total	13	16
Cut-off: S4		
S4-5	6	2
S1-3	7	14
Total	13	16

PCa = prostate cancer, PI-RADS v2 = Prostate Imaging Reporting and Data System version 2, S = score

with clinical significance for 10 cases (50%) (Table 4). In addition, 8 cases (27.6%) were classified as over S4 by PI-RADS v2 with clinical significance for 6 cases (75%). With S4 as a cut-off value for predicting incidental PCa, the diagnostic accuracy was 65.28%, specificity was 90.7%, PPV was 66.7%, and NPV was 65.0%. With S3 as a cut-off value for predicting incidental PCa, the diagnostic accuracy was 73.6%, specificity was 76.7%, PPV was 66.7%, and NPV was 78.6%.

And of the 26 non-malignant cases, 24 cases (92.3%) were classified as below PI-RADS v2 S3, and 21 cases (87.5%) were classified as below S2. Only 2 cases (7.7%) were over S4 of PI-RADS v2.

DISCUSSION

UB cancer is the 11th most frequent cancer worldwide, and it was the 2nd most common urologic cancer from 1999 to 2012 (9, 10). A previous study revealed that incidental PCa occurs in 30% of 50-year-old male and in 70% of 80-year-old male in the USA (11). In addition, a recent pathologic study reported that incidental PCa can be found in around 40% of UB cancer patients undergoing radical CPT in Korea (12). PI-RADS v2 has demonstrated good diagnostic performance in detecting clinically significant PCa (12, 13). However, no studies have reported the use of PI-RADS v2 in detecting incidental PCa or UCa extension of the prostate in UB cancer patients.

Our results showed a low diagnostic accuracy in detecting incidental PCa or UCa extension of the prostate in UB cancer patients. Despite the low diagnostic accuracy rate (65.3%) over S4 for predicting incidental PCa in UB cancer patients, the specificity was relatively high (90.7%). Moreover, despite the low diagnostic accuracy (47.2%) over S4 for predicting incidental PCa or UCa extension of the prostate in UB cancer patients, the PPV (83.3%) and specificity (92.3%) were relatively high for excluding the non-incidental PCa or UCa without extension. Therefore, MRI by PI-RADS v2 could help exclude the probability of incidental PCa or UCa extension if a score of 1, 2, or 3 was assigned by PI-RADS v2.

According to the Epstein criteria, clinically insignificant PCa is defined as $GS \leq 6$, organ-confined tumor (category < T3), and tumor volume < 0.5 cc based on the pathologic findings

of the surgical specimen (8). These characteristics may also be used to detect clinically significant PCa with PI-RADS v2. Our study showed 44.8% of clinically significant PCa detection rate, which was lower than that of a recent pathologic study of the incidental PCa in UB cancer patients undergoing radical CPT in Korea (57.1%) (5). Our study revealed that 65.3% of patients with S4 or S5 disease determined by PI-RADS v2 had incidental PCa, of which 69.0% had clinically significant PCa.

In a previous study, increasing patient age, especially over 60 years, was associated with the possibility of incidental PCa (3). In our study, the mean age of patients with incidental PCa was 68.0 ± 9.3 years, and the mean age of patients without incidental PCa was 63.3 ± 10.4 years; this difference was significant ($p = 0.017$). In addition, a previous study reported that the serum PSA level of patients with incidental PCa was significantly higher than that of patients without incidental PCa (3). However, in our study, the mean serum PSA level of patients with incidental PCa was similar to that of patients without incidental PCa (2.50 ± 2.66 ng/mL and 2.36 ± 2.13 ng/mL, respectively; $p = 0.036$).

A limitation of our study was the small number of patients, and there was no control group. In addition, we analyzed PCa at the per-patient level. Lesion-by-lesion and sector-by-sector analyses with a prospective design are needed. Therefore, further studies with a larger number of cases with lesion-by-lesion or sector-by-sector analyses should be conducted. Other limitations are retrospective study design and non-comparison between PCa and UCa extension.

In conclusion, our preliminary study showed that mpMRI with PI-RADS v2 may help predict or exclude incidental PCa or UCa extension of the prostate in UB cancer patients. Furthermore, it could be used for planning treatment.

Author Contributions

Conceptualization, K.B.C., Y.S.E.; data curation, all authors; formal analysis, K.B.C., Y.S.E., C.H.; investigation, K.B.C., Y.S.E., P.S.; methodology, K.B.C., Y.S.E., C.H.; project administration, K.B.C., Y.S.E.; resources, K.B.C., P.S.; software, K.B.C., Y.S.E.; supervision, K.B.C.; validation, K.B.C., Y.S.E.; visualization, K.B.C., Y.S.E., P.S.; writing—original draft, K.B.C., Y.S.E.; and writing—review & editing, all authors.

Conflicts of Interest

The authors have no potential conflicts of interest to disclose.

REFERENCES

- Stein JP, Skinner DG. Radical cystectomy for invasive bladder cancer: long-term results of a standard procedure. *World J Urol* 2006;24:296-304
- Sivalingam S, Drachenberg D. The incidence of prostate cancer and urothelial cancer in the prostate in cystoprostatectomy specimens in a tertiary care Canadian centre. *Can Urol Assoc J* 2013;7:35-38
- Cho IC, Kim JE, Kim SH, Joung JY, Seo HK, Chung J, et al. Oncologic aspects of long-term followed incidental prostate cancer detected by cystoprostatectomy in Korean patients. *Prostate Int* 2015;3:56-61
- Lerner SP, Shen S. Pathologic assessment and clinical significance of prostatic involvement by transitional cell carcinoma and prostate cancer. *Urol Oncol* 2008;26:481-485
- Barentsz JO, Richenberg J, Clements R, Choyke P, Verma S, Villeirs G, et al. ESUR prostate MR guidelines 2012. *Eur Radiol* 2012;22:746-757
- Weinreb JC, Barentsz JO, Choyke PL, Cornud F, Haider MA, Macura KJ, et al. PI-RADS prostate imaging - reporting and data system: 2015, version 2. *Eur Urol* 2016;69:16-40
- Seo JW, Shin SJ, Taik Oh Y, Jung DC, Cho NH, Choi YD, et al. PI-RADS version 2: detection of clinically signif-

- icant cancer in patients with biopsy gleason score 6 prostate cancer. *AJR Am J Roentgenol* 2017;209:W1-W9
8. Ploussard G, Epstein JI, Montironi R, Carroll PR, Wirth M, Grimm MO, et al. The contemporary concept of significant versus insignificant prostate cancer. *Eur Urol* 2011;60:291-303
 9. Chavan S, Bray F, Lortet-Tieulent J, Goodman M, Jemal A. International variations in bladder cancer incidence and mortality. *Eur Urol* 2014;66:59-73
 10. Joung JY, Lim J, Oh CM, Jung KW, Cho H, Kim SH, et al. Current trends in the incidence and survival rate of urological cancers in Korea. *Cancer Res Treat* 2017;49:607-615
 11. Scott R Jr, Mutchnik DL, Laskowski TZ, Schmalhorst WR. Carcinoma of the prostate in elderly men: incidence, growth characteristics and clinical significance. *J Urol* 1969;101:602-607
 12. Abdelhady M, Abusamra A, Pautler SE, Chin JL, Izawa JI. Clinically significant prostate cancer found incidentally in radical cystoprostatectomy specimens. *BJU Int* 2007;99:326-329
 13. Hassanzadeh E, Glazer DI, Dunne RM, Fennessy FM, Harisinghani MG, Tempany CM. Prostate imaging reporting and data system version 2 (PI-RADS v2): a pictorial review. *Abdom Radiol (NY)* 2017;42:278-289

방광암 환자의 다중 매개 자기공명영상에서 우연히 발견된 전립선암 또는 요로상피세포암종의 전립선 침범의 검출: 전립선 이미징 보고 및 데이터 시스템 버전 2.0을 사용한 후향적 연구

윤상은¹ · 강병철^{1,2*†} · 조현혜^{1,2} · 박상희³

목적 본 연구는 방광암 환자에서 전립선 Prostate Imaging Reporting and Data System version 2 (이하 PI-RADS v2)가, 우연히 발견된 전립선암 또는 요로상피세포암종의 전립선 침범을 예측하는데 도움이 되는지 분석하였다.

대상과 방법 3 Tesla 다중 매개 자기공명영상에서 수술 전 영상을 촬영한 후, 근치적 방광전립선절제술을 시행한 72명의 방광암 환자가 연구에 포함되었다. 수술 전 영상 소견은 두 명의 영상의학과 의사가 분석하였고, 수술 검체는 한 명의 병리과 의사가 평가하였다. 그 후, 전립선 PI-RADS v2의 결과와 병리 소견을 비교 분석하였다.

결과 72명의 방광암 환자 중 29명이 전립선암(40.3%)이 있었고, 20명이 요로상피세포암종(27.8%)이 있었다. 스코어 4를 기준으로 설정하였을 때, 전립선암을 예측하는 진단 정확도는 65.3%, 특이도는 90.7%, 양성 예측도는 66.7%였다. 또한 전립선암 또는 요로상피세포암종을 예측하는 진단 정확도는 47.2%, 특이도는 92.3%, 양성 예측도는 83.3%였다.

결론 정확도는 낮은 편이었지만, 양성 예측도와 특이도는 높은 편이었다. 따라서 전립선 PI-RADS v2에서 스코어 1, 2 또는 3에 해당되면 우연히 발견된 전립선암과 요로상피세포암종의 침범을 배제하는데 도움이 될 수 있다.

¹이화여자대학교 목동병원 영상의학과, 이화여자대학교 의과대학 ²영상의학교실, ³병리학교실
*연세대학교 의과대학 신촌세브란스병원 영상의학과