

Contemporary management of prostatic abscess: Our experience

Amrendra Pathak^{1,2}, Manish Kiran Shrestha³, Sudhir Khanna¹, Juhil Dipak Nanavati¹, Om Prakash Prasad², Arun Gupta³, Tejas Mistry¹

Departments of ¹Urology and ³Interventional Radiology, Sir Ganga Ram Hospital, ²Department of Urology, Hindu Rao Hospital, New Delhi, India

Abstract

Introduction: Prostatic abscess is a serious urological problem that needs immediate attention due to its high morbidity and mortality in absence of appropriate treatment. The objective of our study is to evaluate the efficacy and safety of various modalities of management of prostatic abscess: medical management (MM), transrectal ultrasound-guided aspiration (TRUS-GA), and transurethral derroofing (TU-DR).

Methods: This retrospective study was done in a tertiary care center after taking approval from the institutional review board. Conservative management was done by oral or parenteral medications. Transrectal ultrasound GAs were performed under local anesthesia with an 18-gauge two-part needle. Collapse of cavity was seen in “real time” on TRUS. TU-DR of the prostate was done by 26 French continuous irrigation monopolar resectoscopes. The aspirated pus was sent for microbiological investigation.

Results: TRUS-guided aspiration was performed in 20 patients, TU-DR in five patients, and conservative management in 15 patients. The mean volume of abscess aspirated by TRUS guidance was 13 cc (range 8–50 cc) with single-time aspiration in 85% of cases. Re-aspiration was done in 3 patients. The mean volume of abscess was 33.2 cc (range: 25–40 cc) in TU-DR group and 1.2 cc (range 0.5–2.0 cc) in the MM group. The predominant organism isolated was *Escherichia coli* (48%). Clinical improvement was seen in 97.5% of cases.

Conclusion: We suggest TRUS-GA for symptomatic patients with abscess size more than 2 cc and TU-DR if TRUS-GA fails or is contraindicated.

Keywords: Prostatic abscess, transrectal ultrasonography, transurethral derroofing

Address for correspondence: Dr. Amrendra Pathak, Department of Urology, Sir Ganga Ram Hospital, Room No. 24, Sir Ganga Ram Hospital Marg, Old Rajendra Nagar, New Delhi - 110 060, India.

E-mail: pathakamrendra64@gmail.com

Received: 14.10.2020, **Accepted:** 28.04.2021, **Published:** 15.02.2022.

INTRODUCTION

Prostatic abscess is a urological emergency. The diagnosis of prostatic abscess is often delayed due to overlap of symptoms with other urological conditions. Although prostatic abscess has a low incidence of 0.5% among all prostate-related diseases, it needs immediate attention

due to its high morbidity and mortality when appropriate treatment is not initiated promptly.^[1,2] Broadly, the two mechanisms postulated for the development of prostatic abscess are reflux of infected urine and hematogenous propagation from a primary infected focus elsewhere in the body.^[3] Culture of the prostatic abscess usually

Access this article online	
Quick Response Code:	Website: www.urologyannals.com
	DOI: 10.4103/UA.UA_161_20

This is an open access journal, and articles are distributed under the terms of the Creative Commons Attribution-NonCommercial-ShareAlike 4.0 License, which allows others to remix, tweak, and build upon the work non-commercially, as long as appropriate credit is given and the new creations are licensed under the identical terms.

For reprints contact: WKHLRPMedknow_reprints@wolterskluwer.com

How to cite this article: Pathak A, Shrestha MK, Khanna S, Nanavati JD, Prasad OP, Gupta A, *et al.* Contemporary management of prostatic abscess: Our experience. *Urol Ann* 2022;14:135-40.

reveals a host of organisms as the source of infection, including Gram-negative bacilli such as *Escherichia coli*, Gram-positive Staphylococci, as well as anaerobic, fungal, and mycobacterial organisms.^[4,5] Some of the common predisposing factors for the evolution of prostatic abscesses include diabetes mellitus (DM), immunocompromised status, renal failure, prolonged dialysis, and prolonged urinary bladder catheterization.^[6] High suspicion on clinical grounds, combined with digital rectal examination (DRE), transrectal ultrasonography (TRUS), per-abdominal ultrasonography (USG), computed tomography (CT), and magnetic resonance imaging (MRI) can help establish the diagnosis of prostatic abscess.

Several approaches have been recommended for the management of prostatic abscesses, which include medical management (MM), perineal drainage, transurethral de-roofing (TU-DR), transrectal ultrasound guided aspiration (TRUS GA), and transurethral Holmium laser resection.^[7] TRUS-GA is gaining popularity as it is more cost-effective, less invasive, and can be repeated in case of recurrence. It can be also performed in very morbid patients. Moreover, the morbidity and mortality associated with the procedure are less and can be done on a day-care basis.

The present study was undertaken to evaluate the efficacy and safety of MM, TRUS-GA, and TU-DR in prostatic abscess treatment.

METHODS

This retrospective study was done in a tertiary care center of Delhi, India, from January 2016 to May 2019, after obtaining approval from the institutional review board. Patients with prostatic abscess detected on per-abdominal USG, TRUS, CT, or MRI were included in the study. Patients who did not give their consent for the study or for follow-up were excluded. Baseline investigations were done prior to admission.

The criteria for MM were those patients in whom prostatic abscess was diagnosed incidentally on evaluation, with no evidence of sepsis, organized abscess on TRUS; size <2 cc, or prostatic abscess ruptured into the prostatic urethra while waiting for intervention. This group of patients was managed by appropriate antibiotics as per urine culture-sensitivity reports and followed up by TRUS.

All TRUS-GA was done by an experienced intervention radiologist after obtaining written and informed consent from the patients. All the patients received an aminoglycoside (injection amikacin 15 mg/kg– single

dose) just prior to the procedure, in addition to their ongoing antibiotics. Post procedure, antibiotics were continued for at least 5 days. TRUS-GA was done in the left lateral decubitus. A transrectal 7.5 MHz probe was used after adequate lubrication with an anesthetic jelly. No periprostatic anesthetic block was used. The volume of the abscess was measured and an 18-gauge two-part needle was used for TRUS-GA. Aspiration of pus was done manually and collapse of cavity seen on “real-time” TRUS imaging. The aspirated pus was sent for routine bacterial culture and sensitivity, fungal smear and culture, and acid-fast bacilli staining. Repeat aspiration was done for recollection of pus in the abscess cavity on follow-up, usually after 3 days. Success of the treatment was defined by resolution of symptoms, absence of sepsis, and no residual liquefied abscess.

In symptomatic patients with significant pus cavity size (>2 cc) and where TRUS-GA had failed or was contraindicated (hemorrhoids, anal fissure/fistula, post abdomino-perineal resection), TU-DR was done. TU-DR of the prostate was done under spinal anesthesia or general anesthesia by using 26 French continuous irrigation monopolar resectoscope. Glycine (1.5%) was used as irrigation fluid. In young patients, precaution was taken to preserve the bladder neck, sphincter, and healthy prostatic lobes. Resection was carried out deep enough to ensure adequate drainage of all abscess cavities. Foley’s catheter was placed for 5–10 days along with antibiotic with antipyretic coverage. Patients were discharged after the resolution of symptoms.

Patients were divided into three groups – Group 1 (MM), Group 2 (TRUS-GA), and Group 3 (TU-DR). Patients’ demographic data were collected. Details about abscess volume or aspirate volume, duration of stay in hospital, clinical improvement, mortality, etc., were collected and statistical analysis was performed using SPSS version 17 (IBM company).

RESULTS

Forty patients were included in the study. MM (Group 1) was done in 15 patients, TRUS-GA was performed in 20 patients (Group 2), and TU-DR was done in 5 patients (Group 3). The mean age of all patients was 49.92 years (range: 26–74 years) and the median age was 50.5 years.

Fever, lower urinary tract symptoms (LUTS), or acute urinary retention was seen in 34 cases. Patients presented with fever in 13, 17, and 4 cases; LUTS/retention was found in 12, 18, and 4 cases in Group 1, 2, and 3, respectively.

Three patients with prostatic abscess waiting for TU-DR presented with ruptured abscess into prostatic urethra leading to pericatheter and per-urethral pus discharge, hence were included in MM group. Twenty-six patients had comorbidities such as DM, hypertension (HTN), coronary artery disease, and chronic kidney disease (CKD), while 14 patients had no comorbidities [Table 1].

Clinical suspicion of prostatic abscess was made in 13 (32.5%) cases. A total of 17 patients underwent transabdominal or transrectal ultrasound. Ultrasound was able to pick up the lesion in 70.58% of cases. Smaller lesions were not easily picked up by these modalities. In the 34 cases who underwent CT or MRI, the diagnosis was established in all the cases. The number of days to intervention after the onset of initial symptoms ranged from 4 to 10 days, with the median being 6 days in all the groups.

For TRUS-GA, the mean volume of abscess aspirated was 13 cc (range 8–50 cc). Single-time aspiration was performed in 17 cases of 20 cases (85%), while 2 (10%) patients had to undergo re-aspiration twice and 1 (5%) patients underwent re-aspiration thrice on follow-up for recollected abscess. The mean volume of abscess in TU-DR was 33.2 cc (range: 25–40 cc). In the MM group, the mean volume of abscess was 1.2 cc (range: 0.5–2.0 cc).

The predominant organisms isolated from the aspirated pus were *Escherichia coli* followed by *Staphylococcus* and *Klebsiella*. Sterile aspirate was reported in 1 case [Table 2].

Mean hospital stay was 6.1 days (range: 0–9), 1.2 days (range: 1–2), and 6.6 days (range: 4–15) in Groups 1, 2, and 3, respectively. TRUS-GA was commonly performed as a day-care procedure, while some of the patients in the MM group received domiciliary treatment.

Clinical improvement was seen in 97.5% of cases, while one subject who had undergone TU-DR died as a result of hemorrhage with a large clot in the bladder and sepsis in postoperative period. Nine out of 15 patients in the MM group underwent formal transurethral resection of the prostate (TURP); 5 out of 20 patients required formal TURP in the TRUS-GA group; and 1 out of 5 patients required formal TURP in TU-DR group due to persistent LUTS within 3 years of follow-up.

DISCUSSION

Prostatic abscess mimics other urological problems due to which the diagnosis is often delayed. As it is associated with high morbidity and mortality due to lack of proper

Table 1: Comorbidities present in different groups

Comorbidities	MM	TRUS-GA	TU-DR
DM	3	8	2
DM and HTN	2	2	1
DM, HTN and CAD	2	2	1
HTN	0	2	0
None	8	5	1
CKD	0	1	0

DM: Diabetes mellitus, HTN: Hypertension, CAD: Coronary artery disease, CKD: Chronic kidney disease, MM: Medical management, TRUS-GA: Transrectal ultrasound-guided aspiration, TU-DR: Transurethral derroofing

Table 2: Organisms isolated in pus culture

Organism	TRUS-GA	TU-DR
<i>Escherichia coli</i>	10	2
<i>Staphylococcus</i>	5	1
<i>Klebsiella</i>	2	1
<i>Streptococcus</i>	1	1
<i>Mycobacterium</i>	1	0
None	1	0

TRUS-GA: Transrectal ultrasound-guided aspiration, TU-DR: Transurethral derroofing

management, especially in patients with comorbidities, prompt management is imperative. Various modalities have been put forth for the management of prostatic abscess including conservative management for smaller abscesses.^[7]

In a study done by Vyas *et al.* in 48 patients with TRUS-GA of prostatic abscess, the mean age was 54 ± 14.6 years. The comorbidities present were DM (41.66%), CKD (6.25%), and immunosuppression (4.1%) which was similar to our study.^[8] Selem *et al.* did a study in 32 patients comparing TRUS-GA and TU-DR with prostatic abscess. The mean age was 59 ± 11.46 years in TRUS-GA group and 60 ± 13.65 years in TU-DR group. The comorbidities present in TRUS-GA group and TU-DR group were DM (56.25% and 37.5% respectively); HTN (43.75% and 37.5% respectively), and cirrhosis (12.5% in each group).^[9] Similarly, Oshinomi *et al.* carried out a study in 18 patients comparing MM to drainage of prostatic abscess in which the mean age was 59 and 62 years, respectively. The common comorbidities were DM and cirrhosis.^[10] Increasing age and associated comorbidities have been shown to increase the vulnerability to develop prostatic abscesses.^[8]

The subjects in our study predominantly presented with fever and LUTS. The clinical presentations noted by Vyas *et al.* were fever (41.66%), obstructive LUTS (35.4%), irritative LUTS (58.3%), acute urinary retention (25%), and testicular pain (6.5%).^[8] Selem *et al.* in their comparison of TRUS-GA versus TU-DR recorded presentations as fever (75% and 93.75%), LUTS (75% and 81.75%), perineal discomfort (81.75% and 62.5%), retention (25%

and 12.5%), and sepsis (18.75% and 43.75%), respectively. They also suggested that the severity of the presenting symptoms depends on the immune status of the patient and virulence of the involved pathogen.^[9]

In our study, single TRUS-GA was performed in 17 cases of 20 cases (85% of cases), while 2 patients had to undergo re-aspiration twice and 1 patient underwent re-aspiration 3 times on follow-up. The mean volume of aspirate in a study done by Vyas *et al.* was 10.2 ml (2.5–30 ml). Complete resolution of abscess after the first attempt was observed in 20 cases (41.66%) with an average number of aspiration being 4.1 (1–7) for complete resolution. Complete resolution was seen in 41 subjects (85.42%), while 7 patients (14.58%) required deroofting.^[8] In the study by Selem *et al.*, the mean abscess size was 3.36 ± 0.86 cm and 3.04 ± 0.86 cm in TRUS-GA and TU-DR groups, respectively,^[9] while Oshinomi *et al.* noted the median size of abscess to be 25 mm and 36.9 mm in MM and drainage groups respectively. Five patients had undergone drainage, out of which 4 underwent TRUS-GA (size range: 23.5–60 mm) and one underwent TURP (size 21 mm).^[10]

The predominant organisms isolated in our observation on TRUS-GA and TU-DR were *E. Coli* (48%) followed by *Staphylococcus aureus* (24%) and *Klebsiella* (12%). Two cases (8%) showed *Streptococcus*, one case (4%) showed ycobacterial growth, and one (4%) culture was sterile. Studies similar to ours have shown positive cultures comprising of *E. coli* (37.5–50%), *Klebsiella* (12.5–33.3%), *Pseudomonas* (11.1–18.75%), Mycobacterium tuberculosis (5.5%), *Staphylococcus* (25%), and sterile cultures.^[8,9] Hashimura *et al.* have also reported a case of prostatic abscess following intravesical bacille Calmette-Guerin (BCG) instillation.^[11] Bansal *et al.* reported *S. aureus* as the most common organism in pus cultures, *E. coli* was the second most common organism to be isolated, and sterile cultures were seen in 3 cases.^[12] Elwagdy *et al.* reported *E. coli* to be the most common organism isolated accounting for 78% of the pus culture in a study of 18 patients.^[13]

In our study, 3 patients (15%) had to undergo re-aspiration, while no recurrence was noted in TU-DR group. Selem *et al.* noted the recurrence of abscess in the TRUS-GA group to be 31.2% and TU-DR to be 6.25% ($P = 0.08$).^[9] Jang *et al.* in their study of 18 patients with prostatic abscess reported a recurrence of 22.0% within 1 month of TRUS-GA with a mean abscess size of 4.04 ± 0.95 mm. There was no recurrence after TU-DR with an abscess size of 3.87 ± 0.38 mm.^[14] In a study by Elshal *et al.*, recurrence after TU-DR was 7% with a median size of abscess of 4.5 (2–23) ml, while no recurrence was seen after

TRUS-GA with a median size of abscess of 2.7 (1.5–7.1) ml. Multiple abscesses in were seen in 50% of the subjects. High recurrence rates were seen in patients who underwent TU-DR as these were not detected intraoperatively.^[15] Collado *et al.* reported successful drainage in 75% of cases out of 24 patients. Twenty-three patients had undergone TRUS-GA, out of which re-aspiration was done in two patients, and three patients underwent TU-DR after failure of aspiration. Vyas *et al.* reported complete resolution of prostatic abscess in 85.42% after 1–7 procedures, while 7 subjects had to undergo TU-DR to reach a complete resolution.^[8]

The duration of hospital stay reported by Selem *et al.* in TRUS-GA and TU-DR was 12.9 ± 4.05 days versus 7.25 ± 2.40 days, respectively.^[9] Elshal *et al.* reported hospital stay of 2 (1–11) days and 1 (1–19) days after aspiration and deroofting, respectively.^[15] Jang *et al.* reported a shorter duration of hospital stay in the TU-DR group (10.2 ± 2.8 days) compared to the TRUS-GA group (23.5 ± 5.3 days). As TRUS-GA was performed on a day-care basis, the duration of hospital stay was shorter in our study, with a mean of 1.2 days. The mean duration of hospital stay in MM (6.07 days) and TU-DR (6.60 days) was longer as these patients needed closer observation.^[14]

A study by Jang *et al.* showed shorter hospital stay in the TU-DR group (mean 10.2 days) compared to TRUS-GA (mean: 23.25 days), which contradicts the results of our study.^[14] Our study showed significantly less hospital stay in TRUS-GA group. This might be due to more advanced imaging and aspiration techniques as well as real-time ultrasonographic visualization of collapsing abscess cavity.

We observed one case of mortality due to hemorrhage, large bladder clots, and sepsis post TU-DR, while there were no significant complications following TRUS-GA. TU-DR is a more invasive procedure with a risk of hemorrhage, retrograde ejaculation, and sepsis usually due to irrigation fluid induced-bacteremia. Vyas *et al.* also reported that none of the 7 patients in his study who required aspiration developed sepsis. They reported a success rate of 85.42% in patients treated with aspiration. They also recommended TRUS-GA, as it can be done in real time, can be repeated if necessary, doesn't involve radiations, and can be diagnostic as well as therapeutic at the same time. Furthermore, the risk of urinary bladder catheterization, urethral strictures, retrograde ejaculation, bleeding, and incontinence is less with TRUS-GA and can be performed on an outpatient basis, thus reducing the duration of hospital stay.^[8]

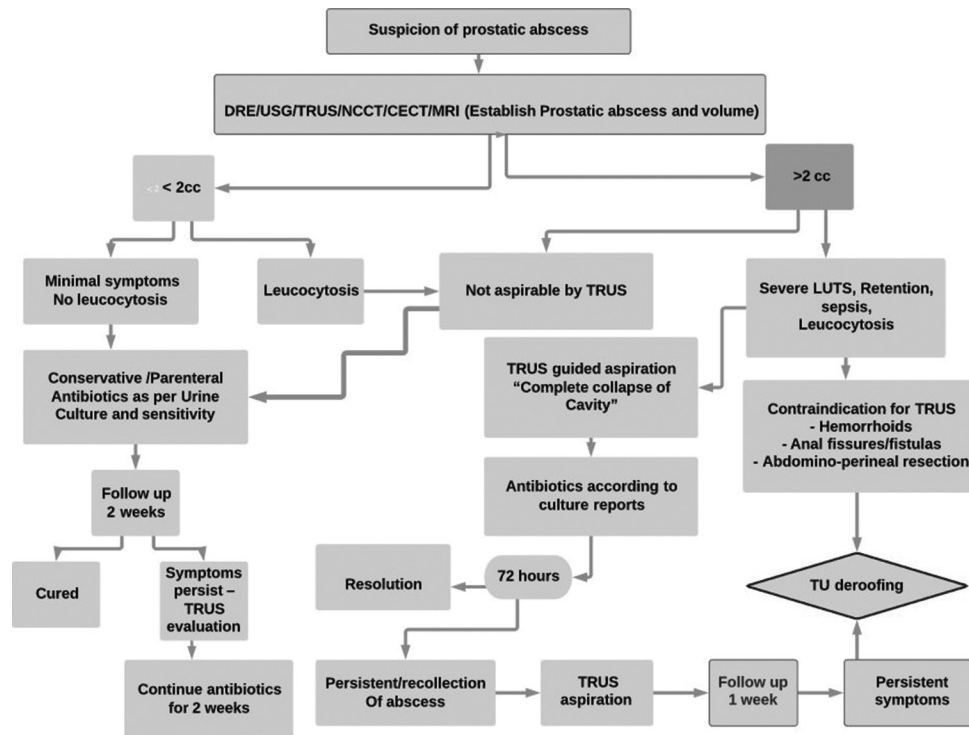


Figure 1: Algorithm for management of prostatic abscess

It was observed that further advantages of TRUS-GA are that it is more affordable and can be performed in severely morbid patients in which general anesthesia is precarious. Moreover, instant improvement in symptoms can be monitored, and even peripherally located abscess can be drained easily, which is difficult in TU-DR. During TRUS-GA, actual pus is aspirated thus preserving the quality of the specimen for culture and sensitivity. During TU-DR, the pus is contaminated with glycine. The pus thus aspirated by TRUS-GA can be sent for Gram stain which gives prompt results and timely intervention. However, it was also noted that apart from other previously mentioned contraindications, one of the major limitations of TRUS-GA is the presence of thick pus that cannot be aspirated and usually requires MM or TU-DR.

Vyas *et al.* suggested that TRUS-GA was beneficial for prostatic abscess of >20 mm volume associated with severe LUTS and/or leukocytosis and that TU-DR can be recommended for failed aspirations.^[8] No single consensus is available for the management of prostatic abscess. However, Vyas *et al.* have proposed an algorithm based on their experiences on the management of prostatic abscess. They have suggested that once the diagnosis of prostatic abscess is established clinically and on TRUS, investigations such as prothrombin time and total leukocyte count are carried out. In case of small abscess (<2 cm), multiple small abscesses with minimal symptoms, and no leukocytosis, antibiotics should be given for 2 weeks as per urine

culture sensitivity. If abscess persists on follow-up, then TRUS-GA should be carried out. If abscess is more than 2 cm in size, associated with severe LUTS, urinary retention, sepsis, or leukocytosis, then TRUS-GA with per-urethral/suprapubic catheterization should be done and reassessed after 72 h. After 72 h if there is resolution, treatment with antibiotics is continued for 2 weeks. If abscess persists, then TRUS-guided re-aspiration is recommended. They have also advised TU-DR if two efforts of TRUS-GA fail.^[8] There is no consensus regarding the size criteria for which aspiration has to be done, but our opinion is that if aspiration is feasible, then TRUS-GA should be offered to the patients as it leads to faster resolution of symptoms and sepsis. Based on our experiences on the treatment of prostatic abscess, we have proposed an algorithm for the management of prostatic abscess [Figure 1].

The limitation of our study was a retrospective study design with a small sample size. Due to the lack of interventional radiologists at most of the institutions, the study is difficult to reproduce. However, where interventional radiology facilities are not available for TRUS-GA, the patient should be referred to a higher center for TRUS-GA, which can then be done as an outpatient procedure, after which the patient can be followed up conveniently at the primary center. There is potential for further study in future where prospective and randomized studies can be carried out with a larger sample size.

CONCLUSION

TRUS-GA is a reliable, less invasive procedure with a high success rate, and has less economic burden on the patients. Thus, all clinically significant prostatic abscesses should be treated preferably with TRUS-GA. Transurethral deroofing should be reserved for those patients in whom TRUS-GA fails or in those where TRUS-GA is contraindicated.

Financial support and sponsorship

Nil.

Conflicts of interest

There are no conflicts of interest.

REFERENCES

- Granados EA, Riley G, Salvador J, Vincente J. Prostatic abscess: Diagnosis and treatment. *J Urol* 1992;148:80-2.
- Ludwig M, Schroeder-Printzen I, Schiefer HG, Weidner W. Diagnosis and therapeutic management of 18 patients with prostatic abscess. *Urology* 1999;53:340-5.
- Collado A, Palou J, García-Penit J, Salvador J, de la Torre P, Vicente J. Ultrasound-guided needle aspiration in prostatic abscess. *Urology* 1999;53:548-52.
- Kadmon D, Ling D, Lee JK. Percutaneous drainage of prostatic abscesses. *J Urol* 1986;135:1259-60.
- Zigelboim J, Goldfarb RA, Mody D, Williams TW, Bradshaw MW, Harris RL. Prostatic abscess due to *Histoplasma capsulatum* in a patient with the acquired immunodeficiency syndrome. *J Urol* 1992;147:166-8.
- Mariani AJ, Jacobs LD, Clapp PR, Hariharan A, Stams UK, Hodges CV. Emphysematous prostatic abscess: Diagnosis and treatment. *J Urol* 1983;129:385-6.
- Shah H. Transurethral holmium laser deroofing of prostatic abscess: Description of technique and early results. *J Urol* 2010;183:e128.
- Vyas JB, Ganpule SA, Ganpule AP, Sabnis RB, Desai MR. Transrectal ultrasound-guided aspiration in the management of prostatic abscess: A single-center experience. *Indian J Radiol Imaging* 2013;23:253-7.
- Selem M, Desoky E, Eliwa A, Fawzi A, Elkady E, Ali MM, *et al.* Transrectal ultrasound-guided aspiration versus transurethral deroofing of prostatic abscess: A prospective randomized study. *Urol Ann* 2018;10:291-5.
- Oshinomi K, Matsui Y, Unoki T, Shimoyama H, Nakasato T, Morita J, *et al.* Treatment strategy for prostatic abscess: Eighteen cases' report and review of literature. *Urol Sci* 2018;29:206-9.
- Hashimura M, Momose H, Takenaga M, Hoshiyama H, Fujimoto K, Ono T, *et al.* Tubercular prostatic abscess following intravesical *Bacillus Calmette-Guerin* therapy. *Hinyokika Kyo* 2012;58:169-72.
- Bansal P, Gupta A, Mongha R, Bera M, Ranjit K, Kundu AK. Minimally-invasive management of prostatic abscess: The role of transrectal ultrasound. *Urol Ann* 2009;1:56-60.
- Elwagdy S, Abdelkhalik M, El-Kheshen A, Aun AA, Mostafa A. Role of transrectal sectional sonography (TRSS) in management of prostatic abscesses. *Urol Ann* 2015;7:334-8.
- Jang K, Lee DH, Lee SH, Chung BH. Treatment of prostatic abscess: Case collection and comparison of treatment methods. *Korean J Urol* 2012;53:860-4.
- Elshal AM, Abdelhalim A, Barakat TS, Shaaban AA, Nabeeh A, Ibrahim el-H. Prostatic abscess: Objective assessment of the treatment approach in the absence of guidelines. *Arab J Urol* 2014;12:262-8.