

Available online at [www.sciencedirect.com](http://www.sciencedirect.com)

ScienceDirect

journal homepage: [www.elsevier.com/locate/ihj](http://www.elsevier.com/locate/ihj)

## Case Report

# Adenosine induced coronary spasm – A rare presentation

P. Arora<sup>a,\*</sup>, V. Bhatia<sup>a</sup>, M. Arora<sup>b</sup>, U. Kaul<sup>c</sup><sup>a</sup> Senior Consultant Cardiology, Fortis Hospital, Noida, India<sup>b</sup> Clinical Associate Cardiology, Fortis Hospital, Noida, India<sup>c</sup> Executive Director and Dean Cardiology, Escorts Heart Institute, New Delhi, India

## ARTICLE INFO

## Article history:

Received 30 April 2013

Accepted 12 December 2013

Available online 3 January 2014

## Keywords:

Adenosine

Coronary spasm

Supraventricular tachycardia

## ABSTRACT

Adenosine is commonly used as a pharmacological agent in myocardial perfusion imaging, as an antiarrhythmic agent, and in Cath Lab. during PCI for treating no reflow phenomenon. Coronary spasm has been reported following adenosine injection during stress imaging. We report a rare complication with ST segment elevation, following adenosine injection, given for treatment of supraventricular tachycardia.

Copyright © 2013, Cardiological Society of India. All rights reserved.

## 1. Introduction

Adenosine is widely used as a pharmacological agent for stress myocardial perfusion imaging as it is a potent coronary vasodilator<sup>1</sup> as well as treatment of supraventricular tachycardia.<sup>2</sup> It is also used for treatment of no reflow phenomenon during PCI.<sup>3</sup> Coronary vasospasm leading to ST elevation during MPI has been reported rarely<sup>4,5</sup> which resolved spontaneously on discontinuation of infusion. Isolated case reports of transient ST elevation following adenosine injection, given for treatment of SVT are there,<sup>6</sup> but to our knowledge no cases have been reported from the Indian subcontinent.

## 2. Case report

A 39-year-old female presented to emergency with complaint of sudden onset palpitation, 2 h prior to admission. There was

no history of chest discomfort or syncope accompanying palpitations. She did not have any history of previous such episodes. On examination pulse rate was rapid with a systemic blood pressure of 100/80 mmHg. Rest of clinical examination was unremarkable. ECG was done and it revealed SVT with heart rate of 200 BPM (Fig. 1A). Vagal maneuvers were unsuccessful in terminating the tachycardia. Intravenous adenosine bolus of 6.0 mg was planned and given through large bore cubital vein. The tachycardia terminated following adenosine injection, however upon cessation of tachycardia, patient started developing ST segment elevation noted on monitor. ECG done revealed ST elevation in inferior leads, consistent with inferior wall myocardial infarction (Fig. 1B). Patient developed hypotension and started gasping. She was immediately intubated. Echocardiography revealed regional wall motion abnormality in inferior wall. ST segment started settling after 4–5 min. Patient was started on inotropes and taken to Cath Lab with intent to perform primary PTCA.

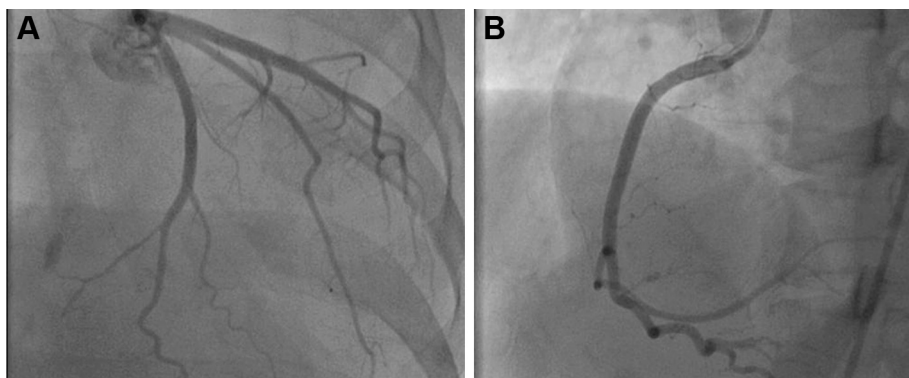
\* Corresponding author.

E-mail addresses: [arora\\_pameesh@rediffmail.com](mailto:arora_pameesh@rediffmail.com), [pameesharora@gmail.com](mailto:pameesharora@gmail.com) (P. Arora).

0019-4832/\$ – see front matter Copyright © 2013, Cardiological Society of India. All rights reserved.

<http://dx.doi.org/10.1016/j.ihj.2013.12.043>





**Fig. 2 – (A): Normal left coronary system. (B): Normal right coronary system.**

Coronary angiography was done and it revealed patent coronary arteries (Fig. 2A and B) without any evidence of thrombus with TIMI III flow. Subsequent ECG done showed complete normalization of ST segment without any Q wave (Fig. 1C). There was no rise in cardiac enzymes and troponin I did not show any rise. Blood pressure gradually improved on inotropes and fluid and patient was extubated successfully after 6 h. Inotropes were weaned off and subsequent recovery was uncomplicated. PredischARGE echocardiography did not reveal any regional wall motion abnormality. She was discharged on the 4th day.

### 3. Discussion

Most of side effects reported with adenosine injection such as flushing, headache, nausea, chest discomfort, shortness of breath are benign, mild and transient in nature.<sup>2</sup> Coronary spasm following injection of adenosine is rare but not an unknown entity.<sup>6</sup> Since the patient developed ST elevation after injection of adenosine which reverted to normal within a few minutes, cause and effect relationship seems highly likely. This is further reinforced by the fact that coronaries were normal without any evidence of thrombus, ruling out coronary atherosclerotic disease, or dissection as the likely etiology. Hence coronary spasm looks like the most logical possibility. Cardiac enzymes were not elevated because of short duration of spasm.

Adenosine is a potassium channel opener and acts on adenosine receptors in sinoatrial, atrioventricular node and ventricular myocytes. It has a negative chronotropic action and at same time causes coronary vasodilation. Coronary vasospasm due to adenosine is rare, but has been reported most often during stress MPI.<sup>4,5</sup> Rare case reports following administration for treatment of SVT have now started appearing.<sup>6</sup>

The mechanism resulting in such a phenomenon may be abrupt withdrawal of short lasting vasodilator effect of adenosine.<sup>7</sup> Coronary hypersensitivity in patients prone to develop spasm, like patients with Prinzmetal's angina may be an added mechanism. However the exact mechanism is still unclear.<sup>8,9</sup> Autonomic nervous system may have a role to play.<sup>10</sup> Sympathetic nervous system activation, secondary to

baroreceptor stimulation caused by hypotensive and vasodilator effect, may cause coronary spasm by triggering catecholamine release. Molecular abnormalities in K ATP channel may in part explain paradoxical spasm.<sup>11</sup>

### 4. Conclusion

The above case demonstrates a potentially life threatening and hazardous complication of adenosine. Fortunately it is a rare phenomenon. However caution should be exercised especially in patients with previous history suggestive of vasospastic angina. Sudden onset of chest pain following adenosine injection, should alert the clinician of this rare possibility. Most cases resolve spontaneously, but one should be prepared for occasional adverse outcome.

### Conflicts of interest

All authors have none to declare.

### REFERENCES

1. Anagnostopoulos C, Harbinson M, Kelion K. Procedure guideline for radionuclide myocardial perfusion. *Heart*. 2004;90:1–10.
2. Camm AJ, Garratt CJ. Adenosine and supraventricular tachycardia. *N Engl J Med*. 1991;325:1621–1629.
3. Marzilli M, Orsini E, Marraccini P, Testa R. Beneficial effects of intracoronary adenosine as an adjunct to primary angioplasty in acute myocardial infarction. *Circulation*. 2000;101:2154–2159.
4. Golzar J, Mustafa SJ, Movahed A. Chest pain and ST segment elevation 3 minutes after completion of adenosine pharmacological stress testing. *J Nucl Cardiol*. 2004;11:744–746.
5. Weissman G, Scandrett RM, Howes CJ, Russel 3rd RR. Coronary vasospasm during an adenosine stress test. *J Nucl Cardiol*. 2004;11:747–750.
6. Ismail M, Assad N, Suwaidi JA. Adenosine – induced coronary artery spasm: a case report. *Med Princ Pract*. 2012;21:82–85.

7. Rosenberg T, Perdrisot R. Coronary spasm after adenosine stress test: an adverse effect of a vasodilator. *Acta Cardiol.* 2008;63:401–404.
8. Lagerqvist B, Sylven C, Waldenström A. Lower threshold for adenosine induced chest pain in patients with angina and normal coronary angiograms. *Br Heart J.* 1992;68:282–285.
9. Inobe Y, Kugiyama K, Morita E, et al. Role of adenosine in pathogenesis of syndrome X: assessment with coronary hemodynamic measurements and thallium 201 myocardial single-photon emission computed tomography. *J Am Coll Cardiol.* 1996;28:890–896.
10. Biaggioni I, Killian TJ, Mosqueda Garcia R, Robertson RM, Robertson D. Adenosine increases sympathetic nerve traffic in humans. *Circulation.* 1991;83:1668–1675.
11. Marban E. The surprising role of vascular KATP channels in vasospastic angina. *J Clin Invest.* 2002;110:153–154.