

Case report

Open Access

Secretory carcinoma of breast in a 17-year-old male

Alfie J Kavalakat*¹, Ramani K Covilakam² and Terence B Culas¹

Address: ¹Department of Surgery, Medical College Hospital, Thrissur, Kerala, India and ²Department of Pathology, Medical College Hospital, Thrissur, Kerala, India

Email: Alfie J Kavalakat* - alfiejose@sanchamnet.in; Ramani K Covilakam - dr_ramanikc@yahoo.co.in; Terence B Culas - culas@vsnl.com

* Corresponding author

Published: 02 June 2004

Received: 13 July 2003

World Journal of Surgical Oncology 2004, **2**:17

Accepted: 02 June 2004

This article is available from: <http://www.wjso.com/content/2/1/17>

© 2004 Kavalakat et al; licensee BioMed Central Ltd. This is an Open Access article: verbatim copying and redistribution of this article are permitted in all media for any purpose, provided this notice is preserved along with the article's original URL.

Abstract

Background: Secretory carcinoma of the male breast (juvenile carcinoma) is a rare neoplasm. Only a few cases have been reported in the literature.

Case report: We report here a case in a 17-year old male presenting with recurrent breast swelling.

Conclusions: Though considered an indolent neoplasm, secretory carcinoma does metastasise to lymph nodes and recur after local excision. Surgery in form of mastectomy with axillary clearance is the treatment of choice.

Introduction

Male breast carcinoma is a relatively rare neoplasm accounting for less than 1% of all breast cancers [1]. It is a disease of the elderly, with a peak incidence around 60 years of age [2]. Majority of the cases are infiltrating duct carcinomas (70%–95%) [2]. It is extremely rare in boys and young adults. At our centre, 5 cases of carcinoma of the male breast were treated out of a total of 594 breast cancers, during the period 1997 – 2002. One of these was a rare form of breast carcinoma in a 17-year-old boy, which forms the basis of this report.

Secretory carcinoma is a rare variant of breast carcinoma with a relatively good prognosis. Most of the patients are females and it is very rare in males [4]. A review of literature revealed only 15 cases of secretory breast carcinoma in males and this is the first reported case from India [3–18].

Case presentation

A 17-Year-old male presented with a swelling over the right breast. He had underwent excision of a lump at a peripheral hospital two years ago for a swelling in the sub-areolar region of the right breast with a fine needle aspiration cytology (FNAC) report of benign epithelial proliferative lesion. Histopathological report of the lumpectomy specimen was invasive lobular carcinoma following which he was referred to an oncologist and mastectomy was advised. Instead, he took herbal medicines. He developed recurrence on the same site within six months. He reported to the oncologist and chemotherapy using cyclophosphamide, methotrexate and 5 fluorouracil (CMF-regimen) was initiated. He was irregular and discontinued the treatment in between.

On examination there was a 5 × 4-cm tumour in the sub areolar region with skin infiltration and multiple satellite nodules around the main lesion (figure 1) and multiple mobile ipsilateral axillary lymph nodes. There was no

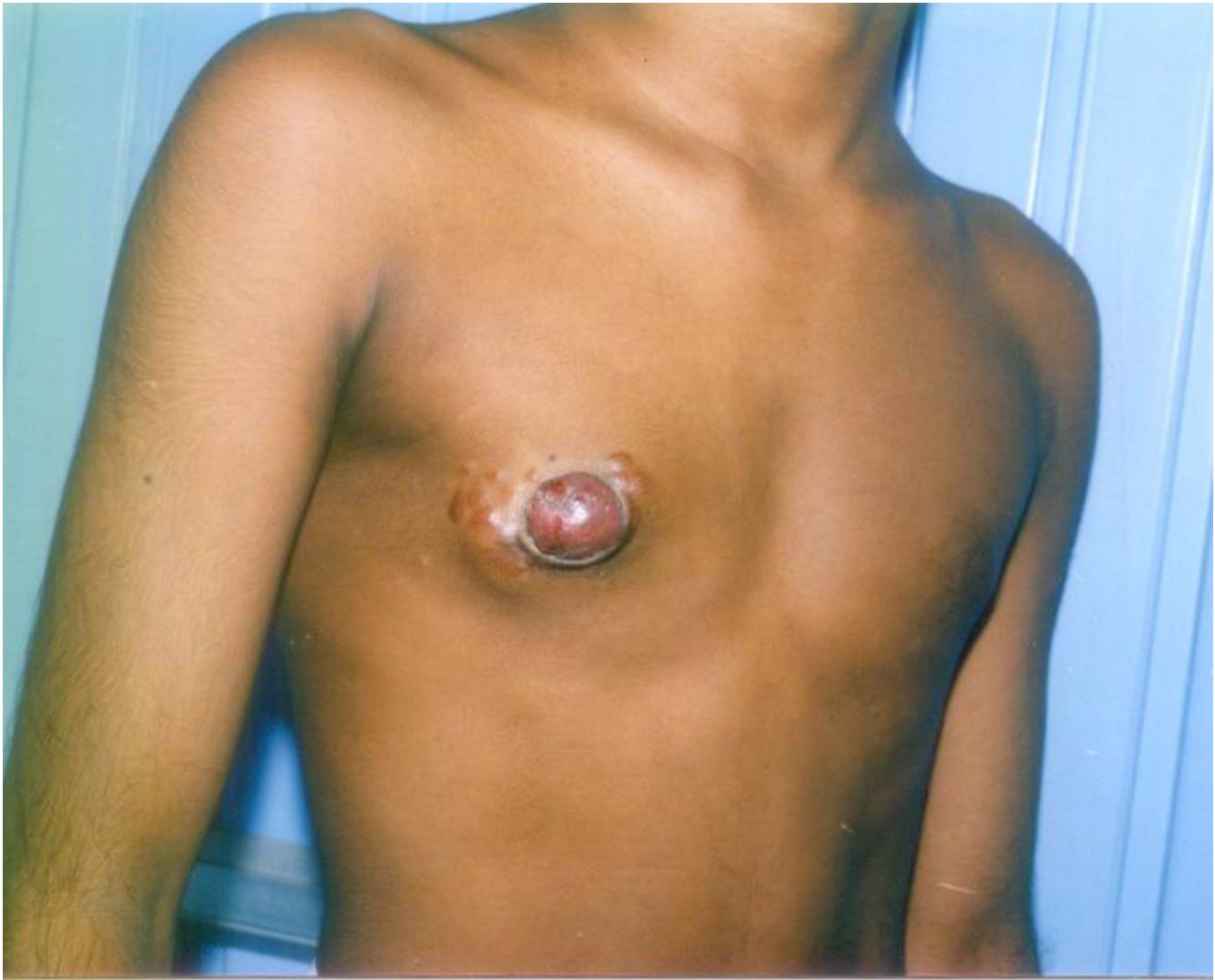

Figure 1
Clinical photograph showing the breast mass with involvement of the skin.

evidence of distant spread. A modified radical mastectomy was performed. Postoperative period was uneventful.

Examination of the mastectomy specimen showed a circumscribed neoplasm measuring 6 × 3.5 cm, involving the overlying nipple. Cut section of the growth showed whitish appearance. The axillary pad of fat showed twelve lymph nodes largest measuring 2 cm. Cut section of most of the lymph nodes showed whitish appearance.

Microscopic examination showed a neoplasm composed of cells arranged in glandular patterns with eosinophilic secretion within the lumen (figure 2). The tumour cells

showed intra cytoplasmic lumen-formation with secretion (figure 3). The secretion was Periodic acid- Schiff (PAS) positive and diastase resistant material (figure 4). The cells showed only mild nuclear pleomorphism and no mitotic activity; however areas of necrosis were seen. The neoplasm was seen invading the overlying nipple and the posterior resected margin was free. A diagnosis of secretory carcinoma of the breast was made.

Of the twelve axillary lymph nodes dissected, ten showed metastatic deposits. The tumour was oestrogen receptor negative and the progesterone receptor status was not studied. As the specimen blocks of first surgery could not

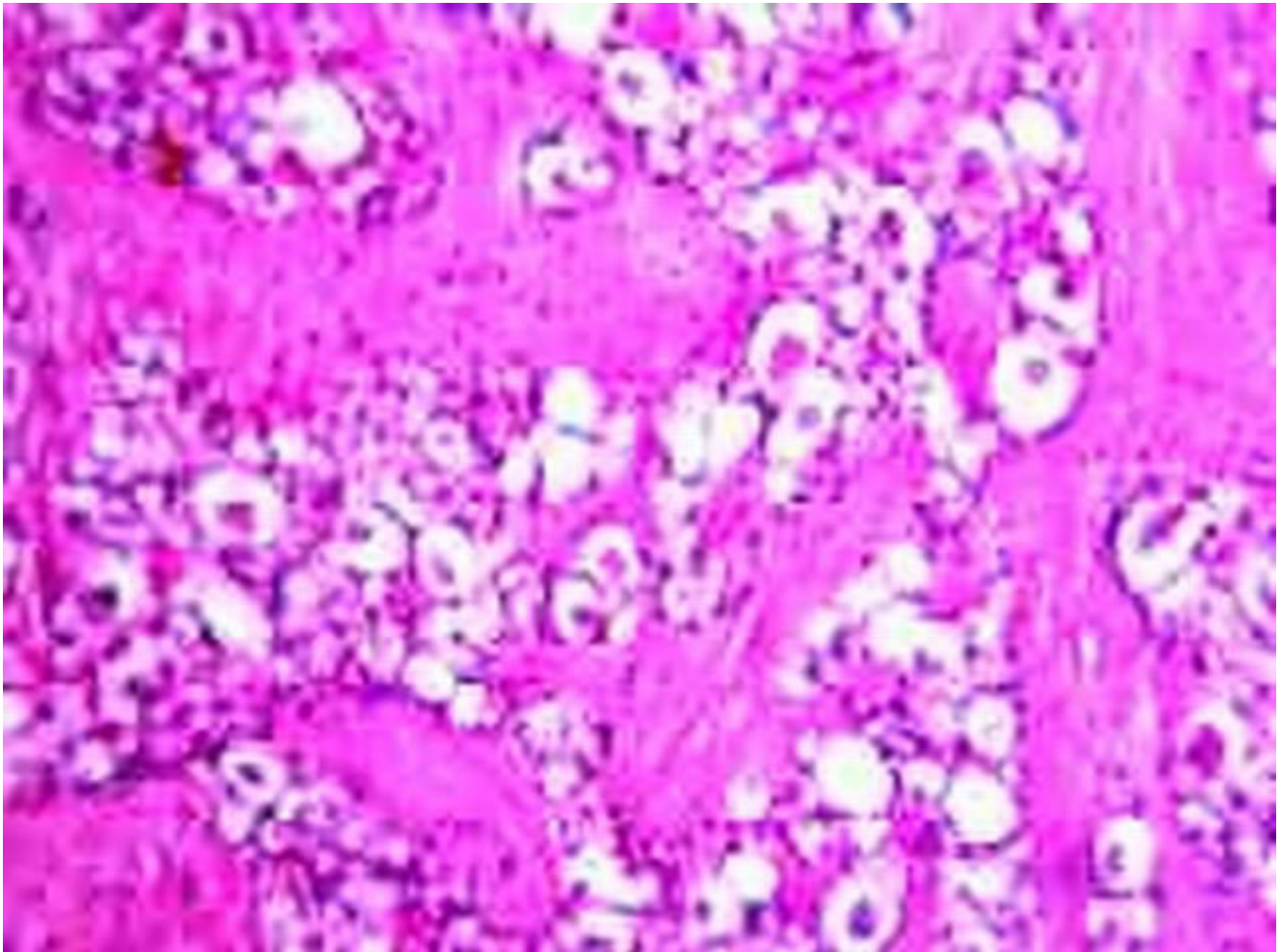


Figure 2

Photomicrograph showing cells arranged in glandular pattern with eosinophilic secretion within lumen (Haematoxylin and Eosin \times 100)

be retrieved no comments regarding the status of margins of first surgery could be made.

He received postoperative radiotherapy and was started on 10 mg twice daily tamoxifen. He is asymptomatic with no evidence of recurrence or metastasis 13 months after mastectomy.

Discussion

Secretory carcinoma of the breast is a rare entity, most commonly seen in females and its occurrence in male is even rarer with only 15 cases reported in the world literature [3-18]. Secretory carcinoma though known previously as juvenile breast carcinoma [19] has been reported in all age groups. In the mix series of Tavassoli and Norris the median age at diagnosis was 25 years [4]. In the recent

review of data of 15 male patients by de Bree et al, the median age was 17 years [18]. Secretory carcinoma seems to occur at a younger age in males than females [18].

Characteristically the tumour presents as a circumscribed and mobile mass in the subareolar location. Most characteristic histological feature is the presence of abundant intra and extra cellular secretory material and tumour cells with vacuolated or granular eosinophilic cytoplasm [4]. Intracytoplasmic lumen is seen frequently (figure 3). The secretory material is PAS positive and diastase resistant.

Fine needle aspiration cytology (FNAC) shows presence of prominent intracytoplasmic vacuolisation [9]. Vesoulis and Kashkari reported that cytological features of secretory breast carcinoma resemble that of benign epithelial

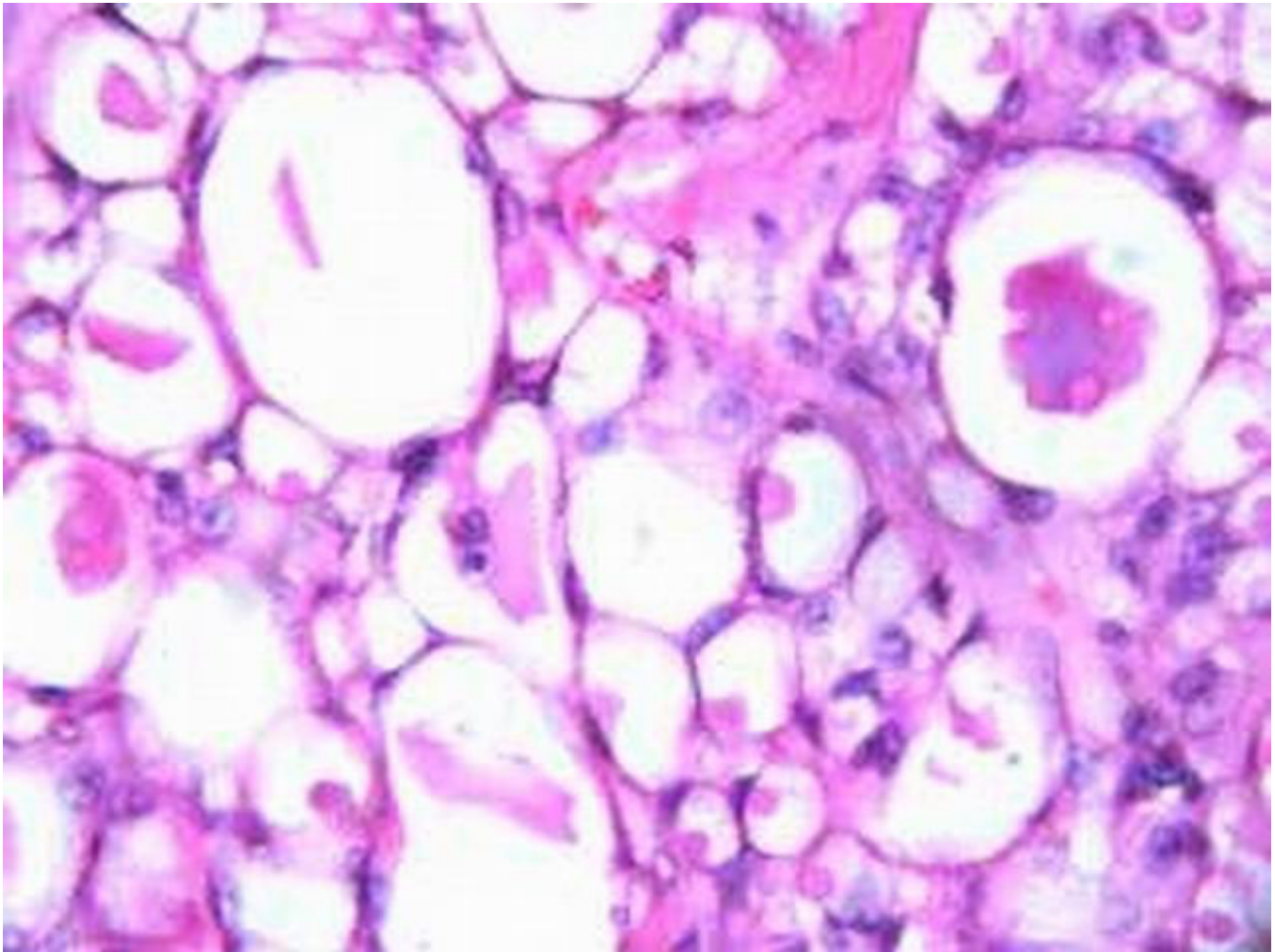


Figure 3
Tumour cells showing intracytoplasmic lumen formation with secretion (Haematoxylin and Eosin \times 400).

proliferative lesions; particularly lactational changes or lactating adenoma [11] and this could be the reason for missing the diagnosis on FNAC in the present case.

The prognosis for secretory carcinoma is favourable when compared with ductal carcinoma. Tavassoli and Norris suggested three features of secretory carcinoma that indicate a favourable prognosis: (1) tumour size less than 2 cm, (2) age of less than 20 years at diagnosis and (3) tumour with circumscribed margins [4].

Case reports of local recurrence following local excision suggest that local excision alone may not be adequate and many have advocated mastectomy [4,5,7,19]. Lymph node metastasis is observed in approximately 20–30% of the recorded cases [4,20]. It is rare in females with tumour

<2 cm [4]. It has been suggested by de Bree *et al*, that in males nodal metastasis might occur more frequently in smaller tumours [18]. Therefore mastectomy with axillary lymph node dissection or sentinel lymph node biopsy is recommended in males [18].

Distant metastases from secretory carcinoma are extremely rare with only four cases reported [7,21]. Metastasis has been reported even after 20 years of surgery. In males, recurrence has been reported in only one case [18]. Herz *et al*, has reported non-responsiveness of the tumour to chemotherapy [21]. Even though adjuvant therapy has been administered in many cases there is no evidence to support any form of therapy [18]. In our case, tumour size of 6 cm and presence of metastasis in 10 axillary nodes suggests a relatively poor prognosis. However secretory

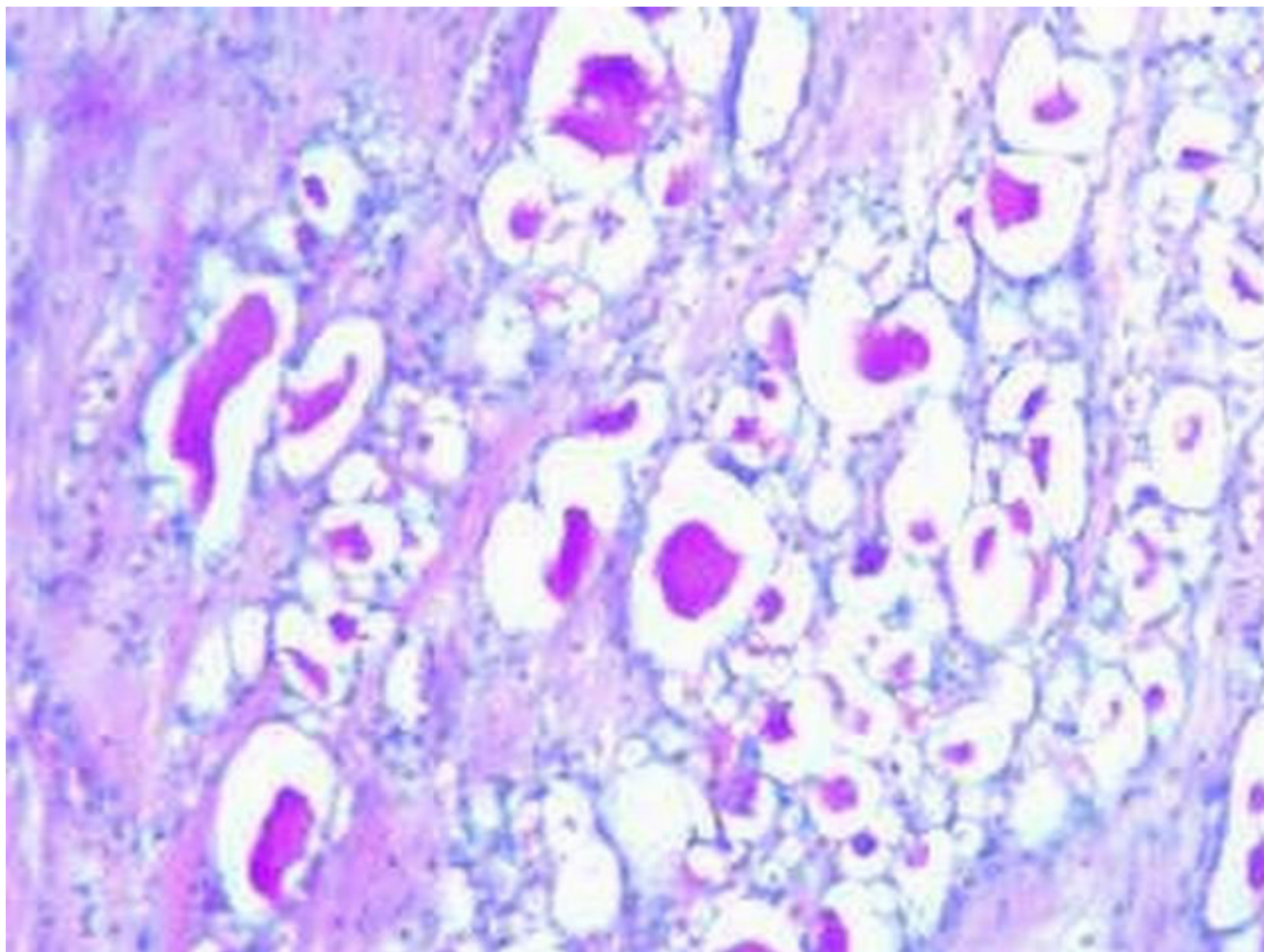


Figure 4
PAS positive and diastase resistant secretion (PAS × 400).

carcinoma being an indolent tumour, a long-term follow-up is required to derive definite conclusions.

Competing interests

None declared.

Authors' contributions

All authors equally contributed in management of the patient and preparation of the manuscript for publication.

Acknowledgement

Written consent was obtained from the patient for publication of the patient's details.

References

1. Schottenfeld D, Lilienfeld AM, Diamond H: **Some observations on the epidemiology of breast cancer among males.** *Am J Public Health* 1963, **53**:890-897.
2. Meguerditchian AN, Falardeau M, Martin G: **Male breast carcinoma.** *Can J Surg* 2002, **45**:296-302.
3. Simpson JS, Barson AJ: **Breast tumours in infants and children: a 40-year review of cases at a children's hospital.** *Can Med Assoc J* 1969, **101**:100-102.
4. Tavassoli FA, Norris HJ: **Secretory carcinoma of the breast.** *Cancer* 1980, **45**:2404-13.
5. Karl SR, Ballantine TVN, Zaino R: **Juvenile secretory carcinoma of the breast.** *J Pediatr Surg* 1985, **20**:368-371.
6. Roth JA, Discafani C, O'Malley M: **Secretory breast carcinoma in a man.** *Am J Surg Pathol* 1988, **12**:150-154.
7. Krausz T, Jenkins D, Grontoft O, Pollock DJ, Azzopardi JG: **Secretory carcinoma of the Breast in adults: emphasis on late recurrence and metastasis.** *Histopathology* 1989, **14**:25-36.
8. Serour F, Gilad A, Kopolovic J, Krispin M: **Secretory breast cancer in childhood and adolescence: report of a case and review of the world literature.** *Med Pediatr Oncol* 1992, **20**:341-344.

9. Pohar-Marinsek Z, Golouh R: **Secretory breast carcinoma in a man diagnosed by fine needle aspiration biopsy. A case report.** *Acta Cytol* 1994, **38**:446-450.
10. Lamovec J, Bracko M: **Secretory carcinoma of the breast: Light microscopical, immunohistochemical flow cytometric study.** *Mod Pathol* 1994, **7**:475-479.
11. Vesoulis Z, Kashkari S: **Fine needle aspiration of Secretory breast carcinoma resembling lactational changes. A case report.** *Acta Cytol* 1998, **42**:1032-1036.
12. Kuwabara H, Yamane M, Okada S: **Secretory breast carcinoma in a 66-year-old man.** *J Clin Pathol* 1998, **51**:545-547.
13. Kameyama K, Mukai M, Iri H, Kuramochi S, Yamazaki K, Ikeda Y, Hata J: **Secretory carcinoma of the breast in a 51-year-old male.** *Pathol Int* 1998, **48**:994-997.
14. Bhagwandeem BS, Fenton L: **Secretory carcinoma of the breast in a nine-year-old boy.** *Pathology* 1999, **31**:166-168.
15. Chevallier A, Boissy C, Rampal A, Soller C, Ture-Carel C, Thyss A, Michiels JF: **Secretory carcinoma of the breast. Report of a case in a 9-year-old boy.** *Clin Exp Pathol* 1999, **47**:88-91.
16. Yildirim E, Turban N, Pak I, Berberoglu U: **Secretory breast carcinoma in a boy.** *Eur J Surg Oncol* 1999, **25**:98-99.
17. Titus J, Sillar RW, Fenton LE: **Secretory breast carcinoma in a 9-year old boy.** *Aust N Z J Surg* 2000, **70**:144-146.
18. de Bree E, Askoxylakis J, Giannikaki E, Chroniaris N, Sanidas E, Tsiftsis DD: **Secretory carcinoma of the male breast.** *Ann Surg Oncol* 2002, **9**:663-667.
19. McDivitt RW, Stewart FW: **Breast carcinoma in children.** *JAMA* 1966, **195**:388-390.
20. Yamashita T, Yoh T, Tanaka I, Nakagawa S: **A case of secretory carcinoma of the breast in an adult.** *Gan No Rinsho* 1988, **34**:342-346.
21. Herz H, Cooke B, Goldstein D: **Metastatic secretory breast cancer. Non-responsiveness to chemotherapy: Case report and review of literature.** *Ann Oncol* 2000, **11**:1343-1347.

Publish with **BioMed Central** and every scientist can read your work free of charge

"BioMed Central will be the most significant development for disseminating the results of biomedical research in our lifetime."

Sir Paul Nurse, Cancer Research UK

Your research papers will be:

- available free of charge to the entire biomedical community
- peer reviewed and published immediately upon acceptance
- cited in PubMed and archived on PubMed Central
- yours — you keep the copyright

Submit your manuscript here:
http://www.biomedcentral.com/info/publishing_adv.asp

