

CASE REPORT

Superficial temporal artery access for carotid artery stenting: A case report

Ádám Csavajda¹  | Sándor Nardai²  | Olivier F. Bertrand³ | Zoltán Ruzsa^{2,4}

¹Invasive Cardiology, Bács-Kiskun County Hospital, Teaching Hospital of the Albert Szent-Györgyi Medical School, University of Szeged, Kecskemét, Hungary

²Semmelweis University Heart and Vascular Centre, Budapest, Hungary

³Quebec Heart-Lung Institute, Laval University, Quebec, Quebec, Canada

⁴Department of Internal Medicine, Invasive Cardiology, Albert Szent-Györgyi Medical School, University of Szeged, Szeged, Hungary

Correspondence

Ádám Csavajda, Invasive Cardiology, Bács-Kiskun County Hospital, Teaching Hospital of the Albert Szent-Györgyi Medical School, University of Szeged, Nyíri Street 38, Kecskemét 6000, Hungary.
Email: csavajda92@gmail.com

Abstract

Percutaneous intervention of patients who suffer from generalized vascular disease is often a great challenge due to the limited accessibility of the access gates. We discuss the case of a 66-year-old man who presented with critical right internal carotid artery (ICA) stenosis after previous hospitalization due to stroke. In addition to arteria lusoria, the patient had known bilateral femoral amputation, occlusion of the left ICA and significant three-vessel coronary artery disease. After unsuccessful common carotid artery (CCA) cannulation from the right distal radial artery access, we successfully performed the diagnostic angiography and the planned right ICA-CCA intervention using superficial temporal artery (STA) puncture. We showed that STA access can be used as an alternative and additional access site for diagnostic carotid artery angiography and intervention when standard access sites alone are insufficient.

KEYWORDS

carotid artery intervention, case report, distal radial artery access, superficial temporal artery access

1 | INTRODUCTION

Percutaneous intervention of patients who suffer from generalized vascular disease is often a great challenge even for an experienced interventionist. The limited number of entry gates can significantly complicate even a relatively simple intervention. On the other hand, in the case of these complex patients, the diagnostic algorithms and patient pathways are also more complex due to existing serious comorbidities. Moreover, if an anatomical variation of the vascular system is also an aggravating circumstance, coronary or peripheral angiography and interventions might be extremely complicated or impossible from standard femoral or radial access sites. In these rare cases, direct aortic puncture has already been described,

but due to the high complication rate and low success rate, its use was not widespread.

The common femoral artery is one of the most commonly used vascular approach during endovascular interventions (primarily due to its size and location). However, possible complications resulting from the puncture can be very serious. In order to prevent these vascular complications and minimize their occurrence, the use of alternative penetration gates has recently gained ground. An example of such an entry gate is the transradial puncture, which nowadays is a generally accepted and recommended vascular approach for cardiac catheterization according to current European and American guidelines.^{1,2} Furthermore, the distal radial artery (DRA) access represents an alternative transradial access. It has been

This is an open access article under the terms of the [Creative Commons Attribution-NonCommercial-NoDerivs](https://creativecommons.org/licenses/by-nc-nd/4.0/) License, which permits use and distribution in any medium, provided the original work is properly cited, the use is non-commercial and no modifications or adaptations are made.

© 2023 The Authors. *Clinical Case Reports* published by John Wiley & Sons Ltd.

described many years ago, however it exploded in popularity only recently. DRA can take the role of access to any extracardiac interventions that are classically performed by femoral approach, such as lower limb or carotid artery procedures.^{3,4}

Superficial temporal artery can be used as an alternate access site for percutaneous carotid artery interventions in the case of iatrogenic carotid artery dissection or for diagnostic coronary angiography and intervention if the accessibility of standard entry points is limited.^{5–7} DRA access with combination of the STA access has not been published in the literature for carotid artery stenting.

2 | CASE PRESENTATION

We discuss the case of a 66-year-old man who presented with critical right ICA stenosis (which was confirmed by CT angiography performed in connection with the patient's recent stroke). The patient was transported by ambulance from the sending institution (where he underwent a cardiology examination on the recommendation of an anesthesiologist) in order to perform the planned right ICA percutaneous intervention. It should also be noted from the antecedents that the diagnostic coronary angiography confirmed significant three-vessel coronary artery disease. Approached from a different direction, the patient came for carotid artery stenting before solving the confirmed three-vessel coronary artery disease with coronary artery bypass graft surgery or percutaneous coronary artery intervention (PCI).

The patient was known to have arteria lusoria, bilateral femoral amputation and occlusion of the left ICA. He had several comorbidities including hypertension, hyperlipidemia, diabetes treated with oral medication, chronic kidney failure, and paroxysmal atrial fibrillation. Chronic medication consisted of clopidogrel (75 mg once daily), aspirin (100 mg once daily), acenocoumarol (2–2.5 mg in daily shift – it was abandoned 3 days before the intervention), ramipril-amlodipine (10/10 mg once daily), indapamide (1.5 mg once daily), bisoprolol (5 mg twice daily), metformin (500 mg twice daily – it was abandoned 3 days before the intervention), spironolactone (25 mg once daily), pantoprazole (40 mg twice daily) and atorvastatin (40 mg once daily). Considering the atrial fibrillation, recent neurologic event, and left ventricular thrombus, the patient was on antithrombotic therapy level three (aspirin + clopidogrel + acenocoumarol) since neurologic observation.⁸

Upon physical examination, radial arteries were palpable. The patient was hemodynamically stable and his vital parameters were found to be fine.

In laboratories moderately reduced renal function (serum creatinine level – 152 μ mol/L) had been seen with

normal level of electrolyte, blood count, and inflammatory parameters. Cardiac biomarkers were also in the normal range. The National Institutes of Health Stroke Scale (NIHSS) score was 0.

Echocardiography demonstrated decreased left ventricular function (EF: 35%; LVOT VTI: 17.5 cm), inferior and lateral wall akinesis with an echogenic, organized thrombus attached to the inferior wall. The echocardiographic image suggested a dilated cardiomyopathy formed on the ground of chronic coronary syndrome.

Initial access through the right DRA (punctured by ultrasonography guidance) was successful, but selective cannulation of the CCA from here was unsuccessful despite our repeated attempts. Angiography revealed a critical right CCA and ICA stenosis (Figure 1A). In addition to antiplatelet treatment, 5000 IU heparin sodium was administered directly to the DRA through the sheath. Additional Na-Heparin was given until reaching 100 IU/kg. Routine activated clotting time was not measured during the intervention. Given the difficulty of selective cannulation due to the anatomical variation of the vascular system (arteria lusoria), we decided to puncture the STA, taking into account the provision of adequate support.

First of all, the right temporal scalp was shaved, sterile prepped and draped. Then the right STA was punctured under ultrasonography guidance, and a 5F 7.5 cm radial sheath (Radiofocus, Terumo) was advanced into the CCA. Then we have externalized the guidewire (after another diagnostic angiography – Figure 1B,C) in a 6.5F Sheathless guiding catheter through the DRA access (Figure 1D,E). After that, positioning the catheter in the CCA, we implanted a 7 \times 30 mm Roadsaver stent in the ICA under filter wire protection (Figure 1F,G). Then we changed the initial guiding catheter for a 7.5F Sheathless guiding, and a 9 \times 40 mm CGuard stent was deployed in the CCA; however, it jumped higher (Figure 2A,B).

Since we could not go back with the guiding catheter from the DRA access, so we finally covered the ostium with a 9 \times 28 mm balloon-expandable stent (Omnalink) from the temporal direction (the initial temporal sheath was previously replaced with a 7F 16 cm Glidesheath Slender [Terumo]; Figure 2C). Post-procedural angiographic result showed adequate flow and no residual stenosis (Figure 2D). The sheaths were pulled out immediately from both puncture points and a StatSeal hemostatic patch (Biolife) was used followed by a local compression and gaze covering. The temporal artery patency was checked using echosonography, which showed normal flow values without any vascular complications.

During his inpatient stay, hemodynamically, he was stable and without complaints throughout, we did not detect any manifest cardiac decompensation symptoms or organic neurological abnormality. Based on the heart-team

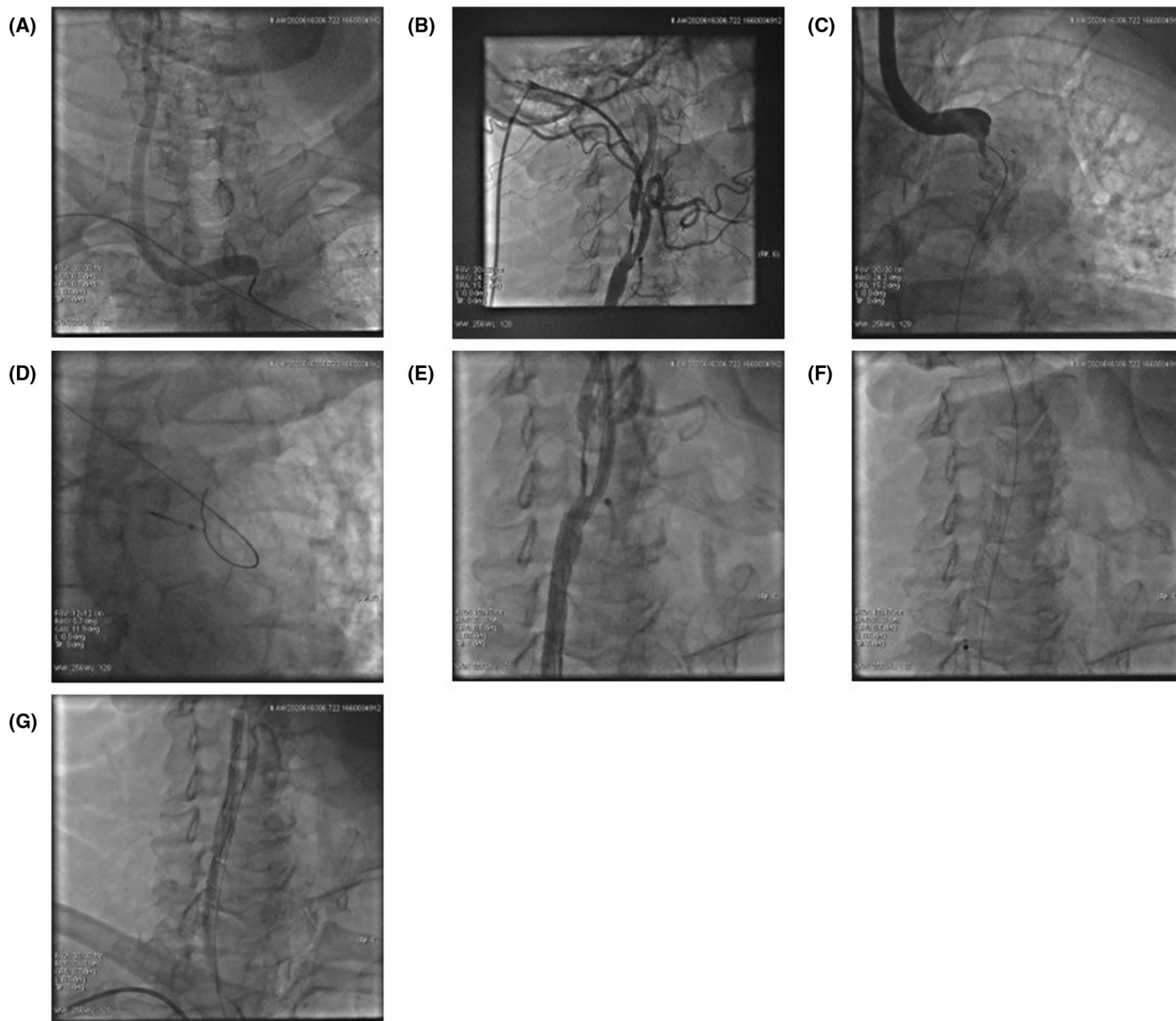


FIGURE 1 Selective diagnostic angiography from DRA access (A) and from STA access (B, C). Guidewire externalization in a 6.5F Sheathless guiding catheter through the DRA access and another diagnostic angiography (D, E). Stent implantation in the ICA (Roadsaver 7×30 mm) under filter wire protection (F) and control angiography after balloon dilatation (G). DRA, distal radial artery; STA, superficial temporal artery.

consultation due to gravis three-vessel coronary artery disease, a decision was made to perform PCI at an elective appointment. Following the intervention, dual antiplatelet therapy was continued with aspirin and clopidogrel. Due to paroxysmal atrial fibrillation and left ventricular thrombus, taking into account his kidney failure, long-term oral anticoagulation was essential. It was recommended to take aspirin and clopidogrel together for 1 month, with the intention of stopping one drug and then the other after 1 year.² No further complication occurred and the patient was discharged to the sending institution on day 4th.

Based on the experience of the 1-month follow-up visit, the patient was compensated, but we took him back to our department due to complaints of angina at rest. Based on

the patient's complaints and the already known coronary status, a decision was made in favor of immediate PCI. After adequate preparation, with the presence of circumflex artery (CX) and right coronary artery (RCA) chronic total occlusion, left main PCI was performed from left DRA access with good angiographic result. To assess the myocardial viability of the RCA and CX territories, further tests are planned.

3 | DISCUSSION

We showed that STA can be used as an additional access site for carotid angiography and intervention when

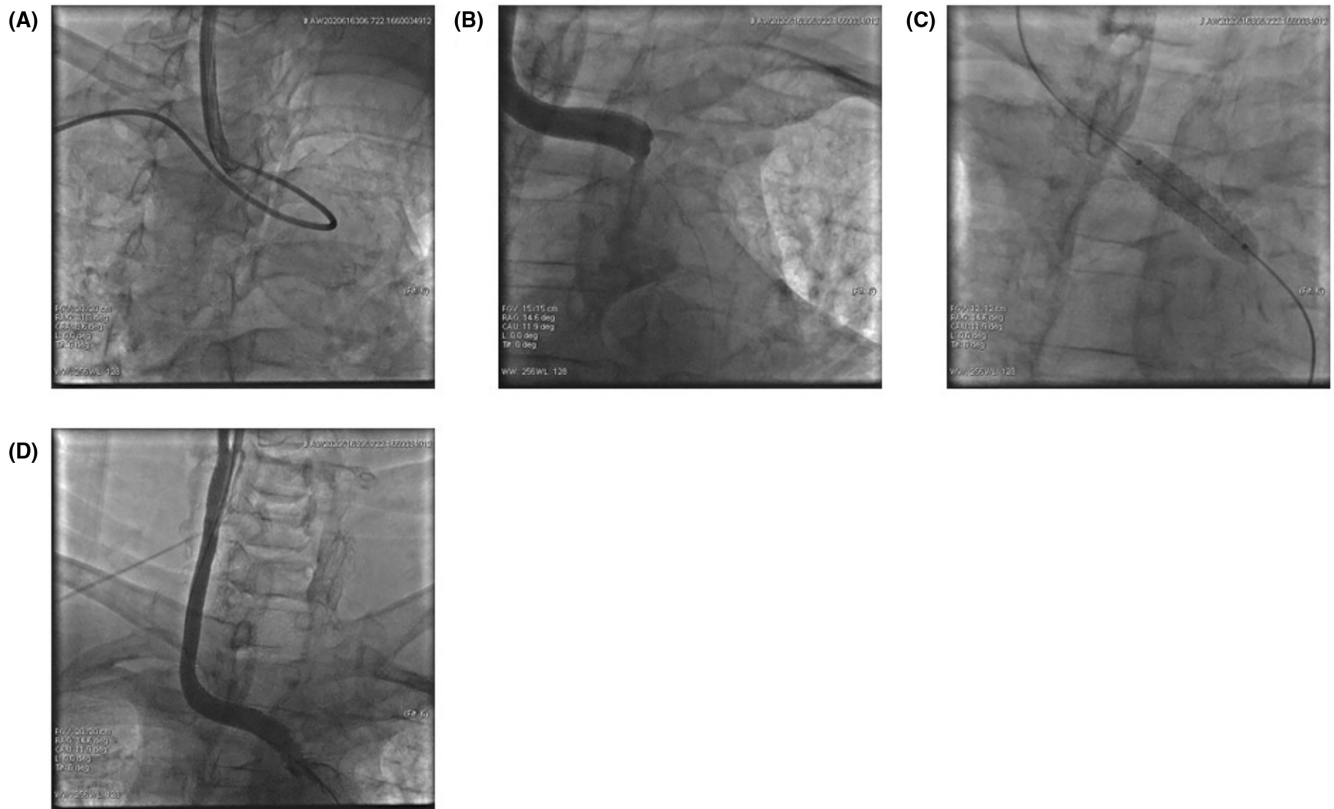


FIGURE 2 Diagnostic angiography after sheath replacement from DRA access (7.5F Sheathless Guiding) (A). Stent pop-up (geometrical miss) (B). Stenting from the temporal access through a 7F Glidesheath Slender (Omnilink 9 × 28 mm) (C). Post-procedural angiographic result – adequate flow and no residual stenosis (D). DRA, distal radial artery.

standard access sites are not enough to achieve adequate support or due to the anatomical variation of the vascular system, a different entry point is required.⁹ DRA access combining with STA access can be an alternative and successful method for CCA stenting or in cases when the cannulation of the CCA is very difficult, or the artery is dissected. The technique might be useful in acute stroke cases also. Using the advantages of the two modalities, a safe and effective interventional technique can be achieved. The STA arises from the external carotid artery (ECA), it is 1 of the 2 terminal branches of the ECA. It gives off many branches that supply the scalp and muscles, it has got a very important role in neurovascular diseases, and it might serve as bypass for intracranial ischemic vascular disease¹⁰ (Figure 3). STA is not really used as a puncture point; however, it is similar to those used in other small vessels like the radial artery or for the snuffbox approach.¹¹ Both arteries have similar diameter, are superficial and well visualized with ultrasound. STA access has several advantages and disadvantages, however. Contrary to popular belief, the biggest advantage of this puncture point, is its ease of access. On the other hand, since this vessel runs close to the bony surface, it can be easily compressed.

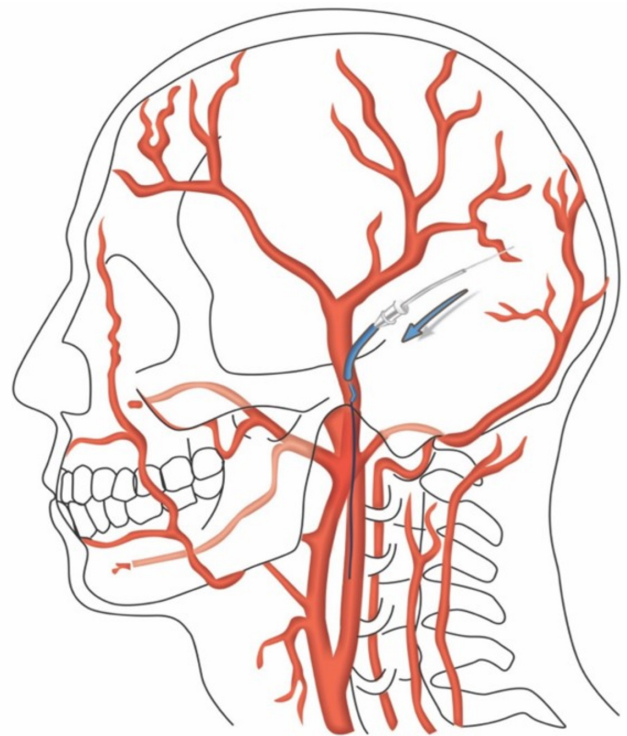


FIGURE 3 Schematic picture of the STA anatomy and sheath insertion. STA, superficial temporal artery.

In some selected cases, due to the small caliber of the vessel, it is much more prone to vasospasm.^{6,7} During the puncture facial nerve must be avoided, especially in case of an inferior approach. Unfortunately, in the case of interventions performed from this injection point, there is also the risk of retrograde embolization from the ECA into the ICA.¹²

Distal radial artery access is associated with low rate of radial artery occlusion; and in the case of occlusion the hand circulation is more stable than during conventional radial artery occlusion.¹¹ It can be asymptomatic because the main branch of the vessel is patent and intact.

On the other hand, DRA access is more comfortable for the patients due to the different puncture position. Due to its many advantages, it can be used for both coronary and non-coronary interventions alone or in combination with other modalities.^{13,14}

4 | CONCLUSION

A percutaneous ultrasound-guided STA access can help facilitate transradial carotid artery stenting in cases, where anatomical variations of the aortic arch make this extremely difficult.

AUTHOR CONTRIBUTIONS

Ádám Csavajda: Conceptualization; data curation; formal analysis; methodology; writing – original draft. **Sándor Nardai:** Conceptualization; supervision; writing – review and editing. **Olivier F. Bertrand:** Conceptualization; supervision; writing – review and editing. **Zoltan Ruzsa:** Conceptualization; supervision; writing – review and editing.

ACKNOWLEDGEMENTS

None.

CONFLICT OF INTEREST STATEMENT

The authors have no conflict of interest.

DATA AVAILABILITY STATEMENT

Data sharing not applicable to this article as no datasets were generated or analysed during the current study.

CONSENT

Written informed consent was obtained from the patient to publish this report in accordance with the journal's patient consent policy.

ORCID

Ádám Csavajda  <https://orcid.org/0000-0002-7184-7853>
Sándor Nardai  <https://orcid.org/0000-0001-9282-4477>

REFERENCES

1. Kolkailah AA, Alreshq RS, Muhammed AM, Zahran ME, Anas El-Wegoud M, Nabhan AF. Transradial versus transfemoral approach for diagnostic coronary angiography and percutaneous coronary intervention in people with coronary artery disease. *Cochrane Database Syst Rev.* 2018;2018(4):CD012318.
2. Neumann F-J, Sousa-Uva M, Ahlsson A, et al. 2018 ESC/EACTS guidelines on myocardial revascularization. *EurHeart J.* 2019;40:87-165.
3. Ruzsa Z, Csavajda Á, Nemes B, et al. Distal radial artery access for superficial femoral artery interventions. *J Endovasc Ther.* 2020;28(2):255-261.
4. Kühn AL, Singh J, Moholkar VM, et al. Distal radial artery (snuffbox) access for carotid artery stenting – technical pearls and procedural set-up. *Interv Neuroradiol.* 2020;27(2):241-248.
5. Ewig S, Torres A. Community-acquired pneumonia as an emergency: time for an aggressive intervention to lower mortality. *Eur Respir J.* 2011;38:253-260.
6. Ivancev K, Resch T, Malina M. Novel access technique facilitating carotid artery stenting. *Vascular.* 2006;14(4):219-222.
7. Syed MI, Sinnathamby S, Shaikh A, Tyrrell R, Neravetla S, Morar K. Percutaneous superficial temporal artery access for carotid artery stenting in patients with a hostile aortic arch. *J Endovasc Ther.* 2011;18(5):729-733.
8. Levine GN, McEvoy JW, Fang JC, et al. Management of patients at risk for and with left ventricular thrombus: a scientific statement from the American Heart Association. *Circulation.* 2022;146(15):e205-e223.
9. Csavajda Á, Bertrand OF, Merkely B, Ruzsa Z. Superficial temporal artery access for percutaneous coronary artery stenting during the COVID-19 pandemic: a case report. *Eur Heart J.* 2020;5(2):ytaa520.
10. Pinar YA, Govsa F. Anatomy of the superficial temporal artery and its branches: its importance for surgery. *Surg Radiol Anat.* 2006;28(3):248-253.
11. Nardai S, Végh E, Óriás V, et al. Feasibility of distal radial access for carotid interventions: the RADCAR-DISTAL pilot study. *EuroIntervention.* 2020;15(14):1288-1290.
12. Hou K, Guo Y, Xu K, Yu J. Clinical importance of the superficial temporal artery in neurovascular diseases: a PRISMA-compliant systematic review. *Int J Med Sci.* 2019;16(10):1377-1385.
13. Kiemeneij F. Left distal transradial access in the anatomical snuffbox for coronary angiography (IdTRA) and interventions (IdTRI). *EuroIntervention.* 2017;13:851-857.
14. Kumar AJ, Jones LE, Kollmeyer KR, et al. Radial artery access for peripheral endovascular procedures. *J Vasc Surg.* 2017;66:820-825.

How to cite this article: Csavajda Á, Nardai S, Bertrand OF, Ruzsa Z. Superficial temporal artery access for carotid artery stenting: A case report. *Clin Case Rep.* 2023;11:e6947. doi:[10.1002/ccr3.6947](https://doi.org/10.1002/ccr3.6947)