

# Clinical and Radiological Outcome of Vancouver B2 Fracture Treated With Open Reduction and Internal Fixation. A Multicenter Cohort Analysis

Peter Biberthaler, MD, PhD,<sup>a</sup> Patrick Pflüger, MD,<sup>a</sup> Markus Wurm, MD,<sup>a</sup> Marc Hanschen, MD, PhD,<sup>a</sup> Chlodwig Kirchhoff, MD, PhD,<sup>a</sup> Joseph Aderinto, MD,<sup>b,c</sup> George Whitwell, MD,<sup>b,c</sup> Peter V. Giannoudis, MD, PhD,<sup>b,c</sup> and Nikolaos Kanakaris, MD, PhD<sup>b,c</sup>

**Objectives:** To determine whether open reduction and internal fixation (ORIF) of periprosthetic Vancouver B2 fractures can lead to successful fracture healing in selected patients, when attention is given to the surgical exposure and the creation of a balanced extramedullary construct.

**Design:** Retrospective.

**Setting:** Two Level-1 trauma centers in Germany and United Kingdom.

**Methods:** Patients with a B2 fracture receiving solely ORIF using a polyaxial locking plate were included for analysis. Patients with other fracture types, or treated with other methods, or with follow-up less than 12 months were excluded. Clinical characteristics, including the Charlson index, the American Society for Anesthesiologists score, and their preinjury functional levels, were recorded. Main outcome measures were 1-year mortality, revision rate, and radiological healing according to the Beals–Tower criteria.

**Results:** A total of 32 patients (mean age  $79 \pm 12$  years) were enrolled. Six patients died within the first year (1-year mortality: 19%), and 5 were unavailable for follow-up studies. The remaining 21 patients had a mean follow-up of 30 months. Of 21, 20 had an excellent/good result using the criteria of Beals–Tower. One patient required revision surgery due to loosening and secondary subsidence of the stem.

**Conclusion:** ORIF can be offered to selected patients suffering from B2 fractures, especially if their functional demand is limited, and perioperative risk high for revision arthroplasty. In this challenging cohort of patients, ORIF was a safe and effective therapeutic option.

**Key Words:** periprosthetic fracture, femoral fracture, hip arthroplasty, open reduction internal fixation, polyaxial locking plate

**Level of Evidence:** Therapeutic Level IV. See Instructions for Authors for a complete description of levels of evidence.

(*J Orthop Trauma* 2022;36:e306–e311)

## BACKGROUND

The number of total hip arthroplasties (THA) has been increasing continuously over the past decades.<sup>1</sup> Consequently, the number of periprosthetic fractures (PPFx) is increasing and constitute the second most frequent reason for revision surgery at 4 years after a primary THA.<sup>2</sup> Due to aging and the growing incidence of comorbidities in this population, mortality rates are increasing and are reported to be almost similar to those suffering hip fractures.<sup>3</sup> Moreover, the functional demand in this advanced aged group is also reduced as compared with primary hip replacement, and only a small proportion of patients return directly to their homes postoperatively.<sup>4</sup>

PPFx relevant to a THA, affect either the acetabular or the femoral components. Several studies have demonstrated that the frequency of periacetabular fractures is much less when compared with femoral PPFx.<sup>5</sup> In general, the therapeutic strategy of PPFx is based on the following critical factors: (1) location of the fracture, (2) stability of the prosthesis, (3) bone stock quality, (4) patient clinical characteristics, comorbidities, and perioperative risk, and (5) available resources and surgical expertise. When the femoral stem is loose (Vancouver B2 and B3 PPFx) a revision to a longer stem either alone or combined with plate fixation or strut grafts can achieve acceptable results.<sup>6,7</sup> The revision stem system

Accepted for publication January 28, 2022.

From the <sup>a</sup>Department of Trauma Surgery, Klinikum Rechts der Isar, Technical University of Munich, Munich, Germany; <sup>b</sup>Trauma Related Services, Leeds Teaching Hospitals NHS Trust, Leeds, United Kingdom; and <sup>c</sup>NIHR Leeds Biomedical Research Center, Chapel Alerton Hospital, Leeds, United Kingdom.

P. Biberthaler and P. Pflüger contributed equally.

P. Biberthaler, N. Kanakaris, and P. V. Giannoudis are instructors in instructional courses for Zimmer Biomet. C. Kirchhoff receives sponsorship from Zimmer Biomet for instructional courses. The remaining authors report no conflict of interest.

Supplemental digital content is available for this article. Direct URL citations appear in the printed text and are provided in the HTML and PDF versions of this article on the journal's Web site ([www.jorthotrauma.com](http://www.jorthotrauma.com)).

This study was performed in line with the principles of the Declaration of Helsinki. Approval was granted by the Ethics Committee of Technical University of Munich, Germany (No: 313/18s) and Leeds UK (No: 2019/TRS81).

Reprints: Patrick Pflüger, MD, Department of Trauma Surgery, Klinikum Rechts der Isar, Technical University of Munich, Ismaninger Street 22, 81675 Munich, Germany (e-mail: [Patrick.pflueger@tum.de](mailto:Patrick.pflueger@tum.de)).

Copyright © 2022 The Author(s). Published by Wolters Kluwer Health, Inc. This is an open access article distributed under the terms of the Creative Commons Attribution-Non Commercial-No Derivatives License 4.0 (CCBY-NC-ND), where it is permissible to download and share the work provided it is properly cited. The work cannot be changed in any way or used commercially without permission from the journal.

DOI: 10.1097/BOT.0000000000002354

should anchor well to the remaining femoral shaft below the level of the fracture to allow immediate mobilization of the patients and reduce the risk of bone healing complications.

Undoubtedly, revision arthroplasty, even as an elective procedure, is a highly invasive surgical procedure with associated increased perioperative morbidity and mortality.<sup>8</sup> We have hypothesized that open reduction and internal fixation (ORIF) of Vancouver B2 PPFx can lead to successful fracture healing in a specific geriatric patient group, when attention is given to the surgical exposure and the creation of a balanced extramedullary construct, using modern polyaxial locking periprosthetic plating systems. Therefore, the aim of this study was to analyze the short-to-midterm outcome of patients treated with this method.

## PATIENTS AND METHODS

Two level-1 trauma centers in Munich, Germany, and Leeds, United Kingdom, participated in the study. The study was approved by local regulatory committees (No: 313/18s, Technical University of Munich, Germany and No: 2019/TRS81 Leeds UK) as a retrospective cohort study. The study period was from 2009 until 2019.

Inclusion criteria were all patients with a femoral PPFx after hip arthroplasty classified as Vancouver B2 and treated using solely ORIF. Exclusion criteria included patients with other types of PPFx, evidence of septic loosening of their stem, or B2 fractures treated with revision arthroplasty or other combined methods. Primary study end points were 1-year mortality, revision rate, and radiological bone healing characteristics. Collected and analyzed data complied with the recent recommendations of Khan et al.<sup>6</sup>

## RADIOLOGICAL EVALUATION

In all cases, the instability of the femoral component was apparent and documented, after careful evaluation of the preoperative imaging (x-rays and CT scan with metal artifact reduction). Thereafter, no further exposure of the hip joint and surgical dislocation was required or performed to document the stem instability. All patients were treated with ORIF alone, as described below. At follow-up, only patients with adequate radiological data sets and a minimum follow-up time of 12 months were included for further analysis. Plain radiographs, and when available postoperative computed tomography scans, were analyzed. The fracture was deemed healed when bridging callus was seen across the fracture on both the anteroposterior and lateral planes.<sup>9</sup>

Implant fixation of the femoral stem was evaluated according to Engh et al<sup>10</sup> (bone-ingrowth fixation, stable fibrous fixation, unstable fixation). The vertical subsidence of the femoral hip stem was measured as distance between the apex of greater trochanter to the shoulder of stem in immediate postoperative and 1-year or final follow-up radiograph. A subsidence up to 3 mm was graded acceptable and more than 5 mm as poor.<sup>11</sup>

The results were graded following the criteria proposed by Beals and Tower.<sup>12</sup> An excellent outcome was a stable arthroplasty and healed fracture with minimal deformity and no

shortening. A stable subsidence of the prosthesis or moderate deformity/shortening was graded good. A poor result was defined as loose prosthesis, nonunion, or severe shortening.<sup>12</sup>

Secondary end points were epidemiological and demographic data, such as age, gender, preoperative assessment, the mode of injury, time to index fracture, primary implants, Vancouver classification, type of ORIF implants, the surgical approach and technique, and overall follow-up time.<sup>6</sup>

## CLINICAL PROCEDURE

All patients were investigated preoperatively for loosening symptoms such as pain during walking before their injury. The preoperative Parker Mobility Score and Charlson Index score was then calculated.<sup>13,14</sup> To quantify perioperative risk, the American Society for Anesthesiologists (ASA) score was recorded. Patient and THA history, biochemical markers, as well as pre- and intraoperative clinical findings indicating the presence of infection were assessed. If positive, they were excluded from the study group.

The decision to treat with ORIF alone without revision was made by the senior surgeon on the basis of perioperative risks, physiologic reserve, the severity of their comorbidities, and the patient's preinjury functional state/demands. Based on these data, it was determined that the patient would not be able to withstand a larger surgical procedure such as a formal ORIF combined with revision of the prosthesis. All procedures were discussed at the multidisciplinary meetings of each department and performed with the full informed consent of the patients and their family members as to the risks and benefits of this alternative approach.

## Surgical Technique

All surgical procedures were performed using a specific plating system, which allows noncontact bridging (NCB Periprosthetic Proximal Femur System, Zimmer Biomet, Warsaw, Indiana). The screws allow a polyaxial placement for bypassing even bulky stems and become locking with the insertion of specific end cups.

One of the most important objectives in all these patients was the anatomic reduction around the loose stem preserving vascularity as much as possible, with careful elevation of the vastus lateralis and minimizing the extend of injury to the perforating nutrient arteries. The reduction of the fractured femur around the stem, often using 1 or 2 onlay cerclages and a reduction clamp was always the initial stage. Subsequently, a long precontoured NCB periprosthetic plate was inserted usually using the targeting jig. During insertion of the plate, the vascularity of the bone was respected, as much as possible but not on the cost of femoral reduction or optimal plate positioning. Then, the plate was temporarily anchored with 2.0 mm K-wires proximally and distally, and the overall axis, and length and rotational alignment were assessed using fluoroscopy. Fixation around the THA stem was achieved using polyaxial cortical screws (4.0 or 5.0 mm) aiming to achieve bicortical fixation as often as possible, with at least 4 anchoring points equally distributed along the stem. Unicortical screw fixation was used when no bicortical screw could be inserted. Around cemented stems, slightly oversized

drill bits were used to minimize the risk of further compromise of the cement mantle. Furthermore, attention was given into the avoidance of linear perforation of the cement mantle but rather spreading the fixation points at both sides of the stem. The main goal was to create a balanced construct around an accurately restored proximal femoral anatomy with the least possible surgical insult (Figs. 1, 2).

Aftercare consisted of early mobilization out of bed into a chair, weight bearing as tolerated, and increased walking distance and mobility as tolerated over the first 8 weeks, under physical therapy supervision. This approach was considered more practical in this patients' group due to their relevant inability to follow different instructions.<sup>15,16</sup>

### Statistical Analysis

Data are presented as mean  $\pm$  SD. RStudio (Version 1.2.5033, 2009–2019 RStudio, Inc.) was used for data processing.

## RESULTS

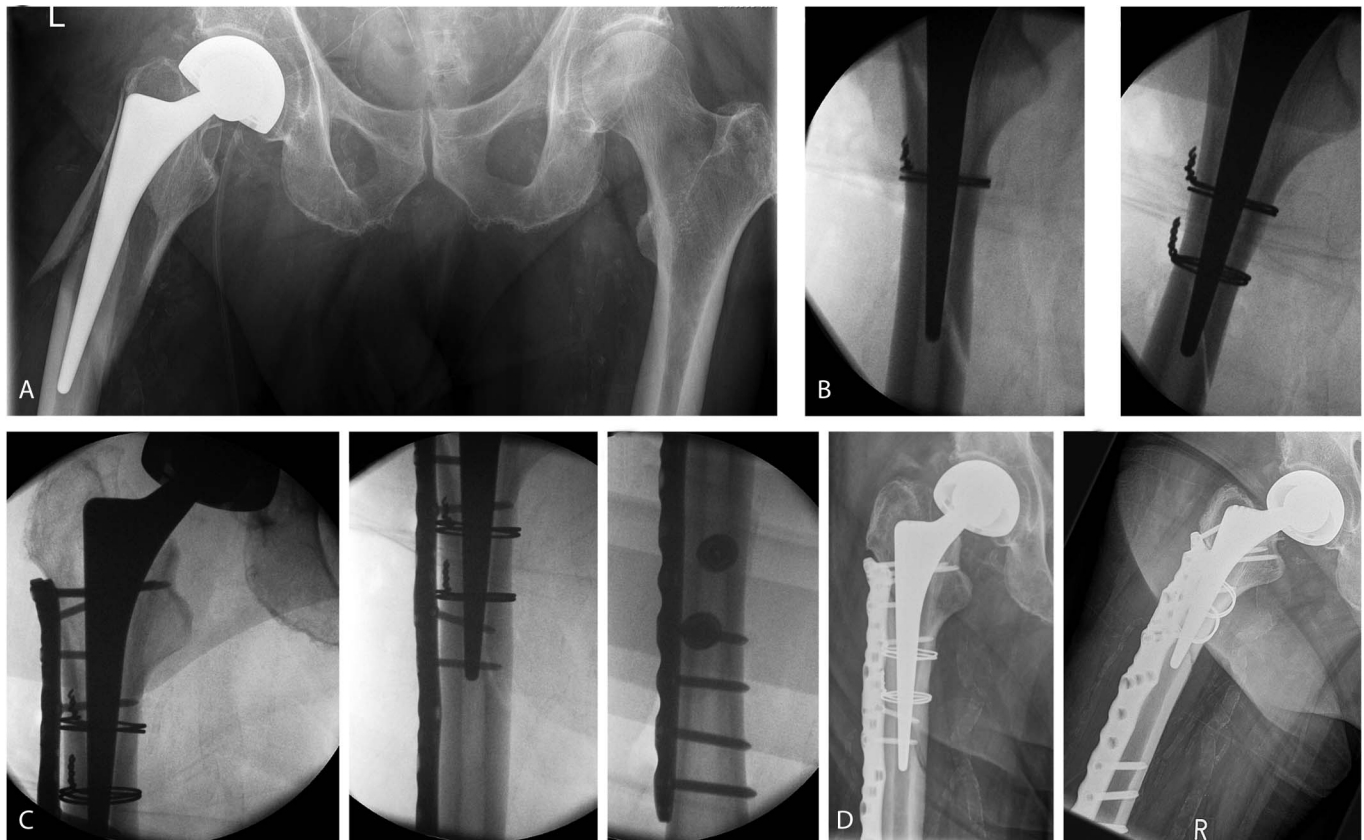
### General Parameters

During the study period, 108 patients with a Vancouver B2/3 were surgically treated in the study hospitals. In total, 32

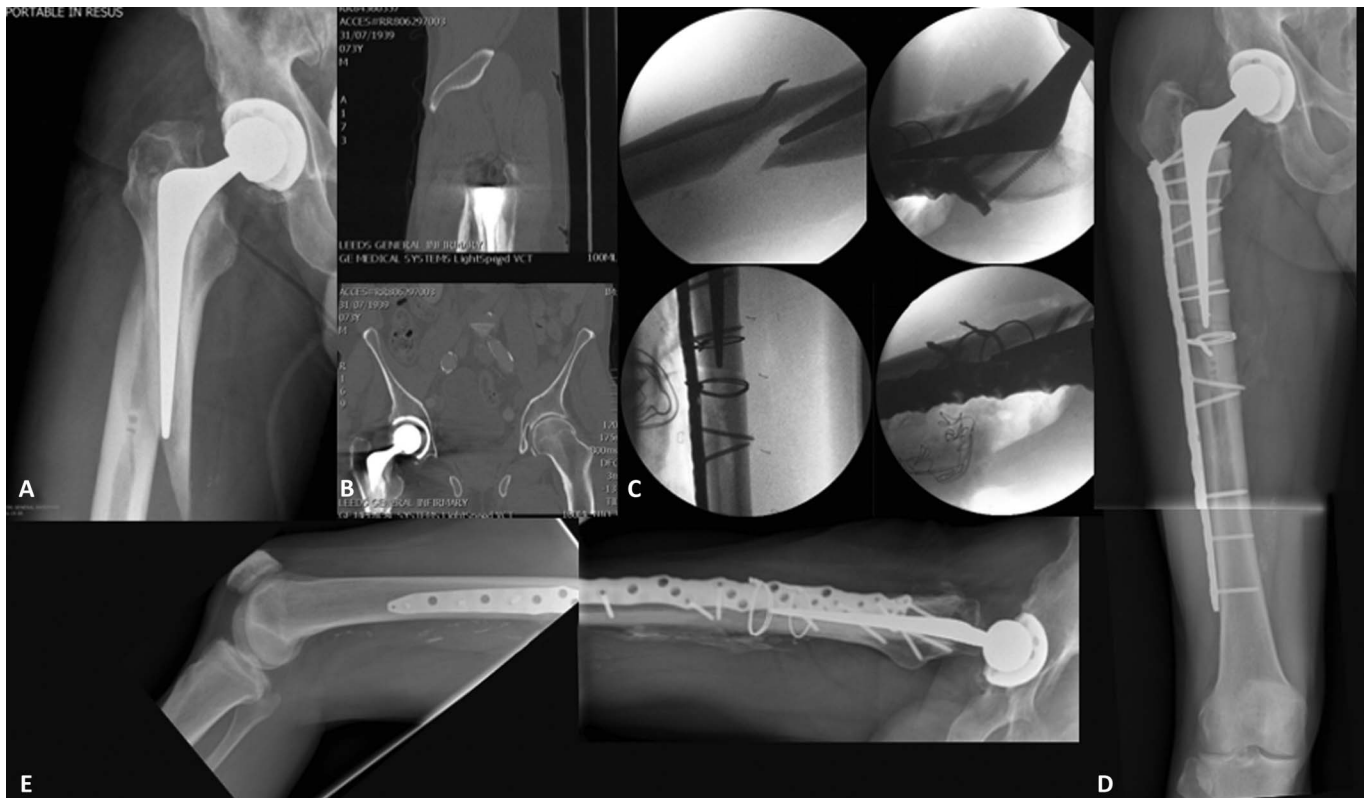
patients were identified as B2 fractures treated solely with ORIF. The mean age was  $79 \pm 12.2$  years, including 17 female and 15 male patients. Due to early death or incomplete radiological data, 21 patients remained for the radiological and functional analysis component of the study.

### Implants and Surgical Technique

Twenty-three patients had a primarily cemented hip stem, all polished taper slip designs. The other 9 patients had a uncemented collarless or collared hip stem. Four patients had their PPFx around a cemented hemiarthroplasty stem. During fixation of the PPFx, 29 of 32 cases required at least 1 or more cerclage wires/cables in addition to a polyaxial locking plate for fracture reduction and fixation. Overall, the mean was 2 cerclage wires/cables with a maximum of 6 besides the plate fixation. Thirty-one patients were treated with an antegrade polyaxial locking plate (NCB Periprosthetic Proximal Femur System, Zimmer Biomet). Only 1 patient received a retrograde polyaxial locking plate (NCB Periprosthetic Proximal Femur System, Zimmer Biomet). The targeting jig was used in 24 cases (75%). Most frequently a 12-hole, followed by a 15 hole, polyaxial locking plate was used for internal fixation (see **Table, Supplemental Digital Content 1**, <http://links.lww.com/JOT/B683>).



**FIGURE 1.** Radiographs of Vancouver B2 fracture treated with ORIF. A, X-ray (pelvic anteroposterior view) of an 80-year-old man with a Vancouver B2 fracture. B, Intraoperative x-ray showing ORIF with the help of 2 cerclages. C, Intraoperative x-ray with polyaxial locking plate osteosynthesis (NCB Periprosthetic Proximal Femur System, Zimmer Biomet). D, Postoperative radiographs 2 months after ORIF.



**FIGURE 2.** Long-term radiological result after ORIF of a Vancouver B2 fracture. A, X-ray of a B2 femoral fracture of a 73-year-old man following a high-energy accident (associated injuries of spleen rupture, subarachnoid and multiple rib fractures). B, CT scan captures that demonstrates the expansion of fracture lines all the way up to the calcar region of his cemented tapered THA, making the tapered stem fully unstable. The CT scan also does not show any cement–bone separation. C, Intraoperative fluoroscopy views demonstrating the long spiral nature of the fracture, and following the lateral surgical approach did show clear exposure of the stem at all its length remaining attachment index 0. Onlay cerclage wires were used for reduction and as well as a balanced plate bone construct with bicortical screw fixation around the stem and appropriate plate span width and plate screw density. D and E, latest follow-up x-rays (anteroposterior and lateral relatively) at 7 years postoperatively with full union and minimal subsidence of the tapered stem of 3 mm.

## Primary End points

### One-Year Mortality

From 32 enrolled patients, 26 (81%) survived the first year and 6 died (19%). Five of the 6 patients died within the first 2 months after surgery. Another 5 patients were excluded from radiological analysis due to missing x-ray data or inadequate follow-up.

### Revision Rate and Radiological Bone Healing Characteristics

Twenty-one patients remained for radiological analysis with a minimum x-ray follow-up of 12 months (mean, 30 months; range 12–67 months, SD  $\pm$  17.7). All 21 fractures progressed to union. One healed with a varus deformity and 1 showed evidence of secondary subsidence and loosening of the stem. Revision arthroplasty was performed in the patient with the loose stem 1 year after the ORIF. The mean vertical subsidence in the final x-ray was 1.5 mm  $\pm$  2.5 (without the 1 patient with revision arthroplasty: 1.2 mm  $\pm$  2.5). Sixteen patients had an excellent, 4 a good, and 1 a poor result according to the classification of Beals–Tower (Table 1).

## Secondary End points

The majority of the patients had an ASA score of 3, and a mean preoperative Parker Mobility Score of  $6 \pm 1.7$ . Regarding the Charlson Index score, more than half of the patients had a score of  $\geq 3$  (mean:  $2.7 \pm 0.9$ ). Preoperative assessment of hip function revealed that 6 patients were unhappy with their hip arthroplasty, whereas 26 patients reported no symptoms. A simple fall occurred in 28 of 32 patients as the cause of injury, only 2 fell down the stairs, and another 2 were involved in a road traffic accident. The interval between primary hip replacement and periprosthetic fracture was 5 years (range, 1–11 years). Twenty-nine patients had a Vancouver B2 fracture, 3 an interprosthetic B2 (see **Table, Supplemental Digital Content 1**, <http://links.lww.com/JOT/B683>). From the 32 patients, we retrieved their preinjury social status in 27, with 12 living previously at a nursing home, 10 at home with caregiver support, and only 5 at home independently. At their latest follow-up, only 16 of 27 patients have returned to their preinjury social status. The rest either have died earlier or have become new residents of nursing houses.

**TABLE 1.** Outcome of Patients According to Beals–Tower Scoring at Latest Follow-up (Mean, 30 Months; Range, 12–67 Months)

Beals–Tower Score	N (%)
Excellent (healed fractures, stable stem, minimal deformity, and no shortening)	16 (76%)
Good (healed fracture and subsidence <3 mm, moderate deformity/shortening)	4 (19%)
Poor (subsidence >5 m, loose prosthesis)	1 (5%)

N, number of patients.

## DISCUSSION

In our study, we investigated the outcome of 32 patients suffering from Vancouver B2 fractures treated with ORIF. This number of patients is comparable to those of previous studies reporting on 8 to a maximum of 52 patients.<sup>17–21</sup> Patients with periprosthetic femur fractures are usually elderly and thus often suffer from several comorbidities.<sup>6</sup> Our cohort had a mean age of 79 years, high ASA score ( $\geq 3$ ), and had on average ( $\geq 3$ ) serious comorbidities, while at the same time was perceived by a senior clinician as of high risk to be subjected to a revision arthroplasty. This subgroup of patients represents a similar cohort to other studies.<sup>6</sup>

In our series, 6 patients died in the first year, resulting in an overall 1-year mortality of 19%. One-year mortality after femoral PPFx is similar to that following hip fracture, ranging from 11% to 15.1%.<sup>3,21–24</sup> The elevated 1-year mortality in this cohort can be attributed to the comorbidities of this cohort of patients. High ASA score and low Parker Mobility Score, as in this group, correlates with increased mortality.<sup>13,23</sup> In general, studies found comparable results regarding the 1-year mortality of Vancouver B2 fractures treated with ORIF or revision arthroplasty.<sup>18,20,21</sup>

Quite recently, Karam et al<sup>25</sup> introduced 4 subtypes of B2 fractures with different configuration and fracture line extensions, which appear to be quite relevant mostly to local femoral bone quality and the type of the femoral stem. These authors advocate in favor of ORIF for the spiral types of B2 around a cemented stem or those with an intact bone–cement interface and/or where anatomic reduction around a cemented or uncemented stem can be achieved. In our cohort, this approach was not followed because our series represent patients operated before this publication. However, interestingly, in all our cemented stems, the preoperative CT scan demonstrated intact bone–cement interfaces of the main fragments, and anatomic reduction around the stem was one of our main goals. Our approach to proceed to an ORIF was mostly individualized and influenced from the patient's overall profile rather than the fracture characteristics.

Within the follow-up period of this study (mean of 30 months), only 1 patient needed a reoperation due to loosening of the hip stem following the ORIF. In contrast to other studies with overall reoperation rates from 11% to 17%, our reoperation rate is considerably lower,<sup>6,19,24</sup> which can be

attributed to the low demands of this group of patients, as well as to our limited follow-up. A systematic review analyzed 22 studies with a total number of 343 Vancouver B2 fractures and found comparable revision rates for hip arthroplasty of 12.4% and internal fixation of 13.3%.<sup>6,24</sup> Baum et al treated Vancouver B2 fractures with a monoaxial locking compression plate, and 4 patients (17%) needed revision surgery. In 2 cases, a wound revision was performed, and in another 2, a revision with LCP.<sup>17</sup> Spina and Scalvi<sup>20</sup> reported of 3 patients (15%) with hip stem loosening in their ORIF cohort of 20 patients. Smitham et al<sup>19</sup> reported about 5 reoperations (11%) in their cohort, from which 3 patients needed reoperation due to revision of the fixation and 2 following a new fracture below the fixation.

Assessing the radiological outcome in our study cohort, 20 patients (95%) had “excellent/good” results according to the Beals–Tower criteria. Only 1 patient, the one that needed revision arthroplasty, was scored as “poor” result (Table 1). That is in line with other studies, who reported “excellent/good” radiographic results of 80% in Vancouver B2 patients treated with ORIF and an uneventfully healing without stem migration or other complications.<sup>17,18,20,26</sup> A current study of 52 Vancouver B2 periprosthetic fractures treated with ORIF reported only minimal stem subsidence with union in all patients.<sup>19</sup>

## Secondary End points

The mean ASA score of 3 is in line with previous published studies reporting also a median ASA score of 3.<sup>20,21</sup> Patients were limited in their mobility, represented by a mean preoperative Parker Mobility Score of 6. Thus, it is not surprising that the mode of injury was a simple fall in 28 of the 32 patients. Other studies also report a limited mobility and similar mode of injury in their cohort.<sup>18</sup> Assessing the patients risk factors is essential for choosing the right treatment. Studies revealed an increased mortality with increasing age and higher ASA score.<sup>23,27</sup> Since the patients' general medical condition is not part of the Vancouver classification, recent studies suggest an individualized treatment especially for B2 fractures depending on patients' comorbidities, mobility, and the surgeon's experience.<sup>28–30</sup>

## Implants and Surgical Technique

ORIF in comparison to revision arthroplasty is a less invasive procedure for patients with a Vancouver B2 fracture.<sup>17,18,26</sup> The primary biomechanical target of our less invasive surgery technique was to restore the femoral anatomy around the stem, achieve adequate fixation stability with a balanced plate/bone construct, and, at the same time, minimize the compromise of the local biology. The vascularity of the bone was respected as much as possible but not at the expense of reduction or optimal plate position. The careful surgical technique of exposure and reduction, as well as the noncontact design of this specific plating system to the lateral femoral cortex,<sup>31</sup> contribute to the preservation of periosteal blood supply versus a totally open technique.<sup>16,32,33</sup>

Limitations of the study are its retrospective design and the relatively small number of patients, as well as the absence of a control group. Randomization between revision

arthroplasty and ORIF in patients with high perioperative risk is problematic, as well as the completion of large prospective series of surgical patients of this age group as previously described.<sup>16</sup> Long-term clinical and radiological results were not part of our study, and radiographs were taken for clinical follow-up and not for research purposes in a strict standardized manner. The surgical procedures evaluated in this study were performed between a period of 10 years in both centers, which share the same principles of fixation and rationale of indications. The decision for ORIF or revision arthroplasty was made by senior clinicians based on the overall patient profile (functional demands, perioperative risk and physiological reserves, and comorbidities) rather than the fracture characteristics. Hence, there was a clear selection bias, which is another shortcomings of this retrospective study; however, it represents the clinical reality in many centers and seems to be supported by the overall outcome of this group of patients.

## CONCLUSIONS

In this multicentered cohort study, we recorded successful healing in the majority of these selected B2 PPFx treated solely with ORIF using modern polyaxial implant systems and biological surgical techniques in low demand geriatric patients, confirming our hypothesis. This alternative approach could be encouraged when the strategy of a revision arthroplasty is considered too much of a surgical insult for a specific patient with a B2 periprosthetic fracture.

## REFERENCES

- Kurtz S, Ong K, Lau E, et al. Projections of primary and revision hip and knee arthroplasty in the United States from 2005 to 2030. *J Bone Joint Surg Am.* 2007;89:780–785.
- Lindahl H. Epidemiology of periprosthetic femur fracture around a total hip arthroplasty. *Injury.* 2007;38:651–654.
- Bhattacharyya T, Chang D, Meigs JB, et al. Mortality after periprosthetic fracture of the femur. *J Bone Joint Surg Am.* 2007;89:2658–2662.
- Moreta J, Aguirre U, de Ugarte OS, et al. Functional and radiological outcome of periprosthetic femoral fractures after hip arthroplasty. *Injury.* 2015;46:292–298.
- Capone A, Congia S, Civinini R, et al. Periprosthetic fractures: epidemiology and current treatment. *Clin Cases Miner Bone Metab.* 2017;14:189–196.
- Khan T, Grindlay D, Ollivier BJ, et al. A systematic review of Vancouver B2 and B3 periprosthetic femoral fractures. *Bone Joint J.* 2017;99-B:17–25.
- Dehghan N, McKee MD, Nauth A, et al. Surgical fixation of Vancouver type B1 periprosthetic femur fractures: a systematic review. *J Orthop Trauma.* 2014;28:721–727.
- Belmont PJ, Jr, Goodman GP, Hamilton W, et al. Morbidity and mortality in the thirty-day period following total hip arthroplasty: risk factors and incidence. *J Arthroplasty.* 2014;29:2025–2030.
- Fink B, Oremek D. Hip revision arthroplasty for failed osteosynthesis in periprosthetic Vancouver type B1 fractures using a cementless, modular, tapered revision stem. *Bone Joint J.* 2017;99-B:11–16.
- Engh CA, Massin P, Suthers KE. Roentgenographic assessment of the biologic fixation of porous-surfaced femoral components. *Clin Orthop Relat Res.* 1990;257:107–128.
- Clair AJ, Gabor JA, Patel KS, et al. Subsidence following revision total hip arthroplasty using modular and monolithic components. *J Arthroplasty.* 2020;35:S299–S303.
- Beals RK, Tower SS. Periprosthetic fractures of the femur. An analysis of 93 fractures. *Clin Orthop Relat Res.* 1996;327:238–246.
- Parker MJ, Palmer CR. A new mobility score for predicting mortality after hip fracture. *J Bone Joint Surg Br.* 1993;75:797–798.
- Charlson M, Szatrowski TP, Peterson J, et al. Validation of a combined comorbidity index. *J Clin Epidemiol.* 1994;47:1245–1251.
- Trompeter A. A call to arms: it's time to bear weight! *Bone Joint J.* 2020;102-B:403–406.
- Kanakaris NK, Obakponovwe O, Krkovic M, et al. Fixation of periprosthetic or osteoporotic distal femoral fractures with locking plates: a pilot randomised controlled trial. *Int Orthop.* 2019;43:1193–1204.
- Baum C, Leimbacher M, Kriechling P, et al. Treatment of periprosthetic femoral fractures vancouver type B2: revision arthroplasty versus open reduction and internal fixation with locking compression plate. *Geriatr Orthop Surg Rehabil.* 2019;10:2151459319876859.
- Joestl J, Hofbauer M, Lang N, et al. Locking compression plate versus revision-prosthesis for Vancouver type B2 periprosthetic femoral fractures after total hip arthroplasty. *Injury.* 2016;47:939–943.
- Smitham PJ, Carbone TA, Bolam SM, et al. Vancouver B2 periprosthetic fractures in cemented femoral implants can be treated with open reduction and internal fixation alone without revision. *J Arthroplasty.* 2019;34:1430–1434.
- Spina M, Scalvi A. Vancouver B2 periprosthetic femoral fractures: a comparative study of stem revision versus internal fixation with plate. *Eur J Orthop Surg Traumatol.* 2018;28:1133–1142.
- Gitajn IL, Heng M, Weaver MJ, et al. Mortality following surgical management of vancouver B periprosthetic fractures. *J Orthop Trauma.* 2017;31:9–14.
- Heyes GJ, Tucker A, Marley D, et al. Predictors for 1-year mortality following hip fracture: a retrospective review of 465 consecutive patients. *Eur J Trauma Emerg Surg.* 2017;43:113–119.
- Finlayson G, Tucker A, Black ND, et al. Outcomes and predictors of mortality following periprosthetic proximal femoral fractures. *Injury.* 2019;50:438–443.
- Drew JM, Griffin WL, Odum SM, et al. Survivorship after periprosthetic femur fracture: factors affecting outcome. *J Arthroplasty.* 2016;31:1283–1288.
- Karam J, Campbell P, Desai S, et al. Periprosthetic proximal femoral fractures in cemented and uncemented stems according to Vancouver classification: observation of a new fracture pattern. *J Orthop Surg Res.* 2020;15:100.
- Solomon LB, Hussenbocus SM, Carbone TA, et al. Is internal fixation alone advantageous in selected B2 periprosthetic fractures? *ANZ J Surg.* 2015;85:169–173.
- Fuchtmeyer B, Galler M, Muller F. Mid-term results of 121 periprosthetic femoral fractures: increased failure and mortality within but not after one postoperative year. *J Arthroplasty.* 2015;30:669–674.
- Niikura T, Lee SY, Sakai Y, et al. Treatment results of a periprosthetic femoral fracture case series: treatment method for Vancouver type b2 fractures can be customized. *Clin Orthop Surg.* 2014;6:138–145.
- Park SK, Kim YG, Kim SY. Treatment of periprosthetic femoral fractures in hip arthroplasty. *Clin Orthop Surg.* 2011;3:101–106.
- Pavone V, de Cristo C, Di Stefano A, et al. Periprosthetic femoral fractures after total hip arthroplasty: an algorithm of treatment. *Injury.* 2019;50(suppl 2):S45–S51.
- El-Zayat BF, Zettl R, Efe T, et al. Minimally invasive treatment of geriatric and osteoporotic femur fractures with polyaxial locking implants (NCB-DF(R)) [in German]. *Unfallchirurg.* 2012;115:134–144.
- Link BC, Apiwatthakakul T, Hill BW, et al. Minimally invasive plate osteosynthesis (MIPO) of periprosthetic femoral fractures with percutaneous cerclage wiring for fracture reduction: tips and technique. *JBJS Essent Surg Tech.* 2014;4:e13.
- Min BW, Cho CH, Son ES, et al. Minimally invasive plate osteosynthesis with locking compression plate in patients with Vancouver type B1 periprosthetic femoral fractures. *Injury.* 2018;49:1336–1340.