



The Retrospective Study of Closed Reduction of Nasal Bone Fracture

Han-Kyul Park, Jae-Yeol Lee, Jae-Min Song, Tae-Seup Kim, Sang-Hun Shin

Department of Oral and Maxillofacial Surgery, School of Dentistry, Pusan National University

Abstract

Purpose: This study was conducted in order to investigate the therapeutic effect of closed reduction according to a classification in patients with nasal bone fracture.

Methods: The study was conducted retrospectively on 186 patients with a mean age of 38 years (range: 7 to 80 years). All patients were diagnosed by clinical and radiologic examination, and then classified according to Hwang's classification by computed tomography. The patients were further classified by their age, gender, causes of fracture, operation timing after fracture, concurrent facial bone fracture, and complications. All patients underwent the same reduction and treatment protocol and were then followed up regularly for at least three months.

Results: The cause of the fracture was slip down, and the highest prevalence was shown in the 20s. The mean operation timing after fracture was 4.1 days (range: 1 to 14 days), and it tended to be longer in the case of defected septal bone or more severe fracture. The most common concurrent facial bone fracture was orbital blow-out fracture, and zygomaticomaxillary complex and maxillary fracture occurred frequently. The largest number of complications occurred in class III and IIBs patients, and the main complication was postoperative pain.

Conclusion: Results of nasal bone closed reduction on the 186 patients showed that serious complications rarely occurred. Closed reduction is generally an effective treatment for nasal bone fracture. However, in the case of severe concurrent septal bone fracture or comminuted fracture with depression, open reduction should be considered. Further study with a larger number of patients and further classification is required.

Key words: Facial bones, Nasal bone, Manipulation, Orthopedic

Introduction

The nose is positioned on the center of the face and is significantly anteriorly protruded compared to the other facial structures. Nasal bone fracture is the most common facial fracture, accounting for approximately 40% of all facial fractures[1]. If proper treatment is not provided at

an appropriate time, nasal bone fracture may cause not only a change in facial contouring but also complications in the upper airway[2], and septoplasty or augmentation rhinoplasty could be required due to the patients' low functional and aesthetic satisfaction. For nasal bone reduction, general or local anesthesia, open or closed reduction, and the time elapsed until operation after fracture should be

RECEIVED September 25, 2014, REVISED October 8, 2014, ACCEPTED November 10, 2014

Correspondence to Sang-Hun Shin

Department of Oral and Maxillofacial Surgery, Pusan National University Dental Hospital
20 Geumo-ro, Mulgeum-eup, Yangsan 626-787, Korea
Tel: 82-55-360-5100, Fax: 82-55-360-5104, E-mail: ssh8080@pusan.ac.kr

Copyright © 2014 by The Korean Association of Maxillofacial Plastic and Reconstructive Surgeons. All rights reserved.

© This is an open access article distributed under the terms of the Creative Commons Attribution Non-Commercial License (<http://creativecommons.org/licenses/by-nc/3.0>) which permits unrestricted non-commercial use, distribution, and reproduction in any medium, provided the original work is properly cited.

considered. These factors may affect patient satisfaction or complications. In the case of non-complex nasal bone fracture, closed reduction under systemic anesthesia is conventionally known to be effective[3]. Accordingly, the authors reviewed the fracture classification, type of anesthesia, reduction type, and time elapsed until operation after fracture in patients who had visited the Department of Oral and Maxillofacial Surgery in Pusan National University Dental Hospital and Pusan National University Hospital due to nasal bone fracture during a period of three years, from 2010 to 2012. The patients, who were classified according to their age, gender, and cause of fracture according to a specific classification, received the same treatment. The authors conducted a clinical assessment and an analysis of the results for the effective diagnosis and treatment of nasal bone fracture.

Materials and Methods

Of the outpatients and emergency patients who had visited the Department of Oral and Maxillofacial Surgery in Pusan National University Dental Hospital and Pusan

National University Hospital during a period of three years, from January 1, 2010 to December 31, 2012, 186 patients who had been diagnosed with nasal bone fracture via physical examination, plain radiograph, and computed tomography were studied retrospectively. Patients' age, gender, cause of fracture, fracture severity, concurrent fracture, clinical finding, time elapsed until operation after fracture, and postoperative complications were reviewed. In particular, in the case of postoperative complications, a comparison was performed between nasal bone fracture without and with concurrent facial fracture.

Patient information including complications was collected via the patients' medical records, phone interview, interview, physical examination, and radiograph examination. Those with a previous history of nasal bone fracture or who had undergone septoplasty, augmentation rhinoplasty, or corrective rhinoplasty were excluded from the study. After computed tomography, Hwang *et al.*'s classification method (2006)[4] was used to evaluate the fracture severity based on the deviation or depression degree and the concurrent fracture of the septal bone. Accordingly, the patients were classified according to the following six

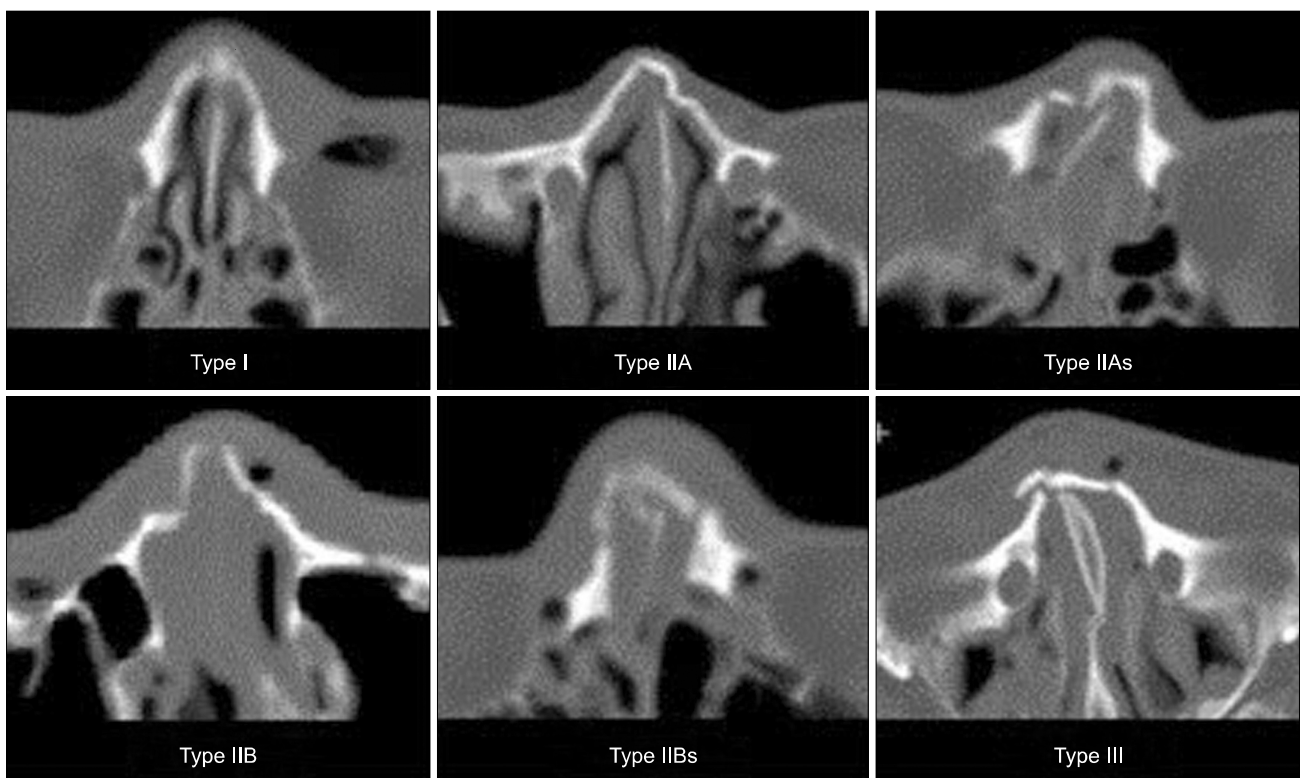


Fig. 1. Classification of nasal bone fracture. Each types classification according to the standard of Hwang *et al.*'s classification[4].

groups: type I – simple, without displacement; type II – simple, with displacement/without telescoping (IIA – unilateral, IIAs – unilateral with septal fracture, IIB – bilateral, IIBs – bilateral with septal fracture); and type III – comminuted with telescoping or depression (Fig. 1). All patients except for the type I group underwent closed reduction with external nasal splinting under systemic anesthesia. Pre- and post-operative plain films were obtained from all patients. After surgery, gauze packing and external nasal splinting were maintained for four and seven days, respectively. The patients were followed-up for at least three months to assess the complications, such as fracture recurrence and functional abnormality.

The Institutional Review Board of the Ethics Committee of the Pusan National University Hospital approved this study (2-2014023).

Results

1. Age and gender

Regarding the age distribution, patients in their 20s accounted for the highest proportion, and those in their 40s to 50s accounted for the second highest proportion. However, the number of pediatric patients aged 9 years

or below and elderly patients aged 70 years or higher was small. Regarding the gender distribution, most were male in all types (Table 1).

2. Cause of fracture

Regarding the causes of fracture, 61 patients suffered a slip down, which accounted for the highest proportion, followed by collision and fist trauma, in that order. The proportions of fall down and traffic accident (TA) were relatively low. Sports trauma, motorcycle TA and unknown cause were also included in the causes of fracture (Table 2).

The number of type IIA cases (lateral fracture without septal fracture) accounted for the highest proportion. The number of type I cases, which are non-indicative for surgery, followed type IIA, while the number of cases of nasal bone fracture with septal fracture was relatively low, and the number of type III cases (with depression and comminuted fracture) was also low (Table 2).

3. Timing of surgery after the trauma

The mean time elapsed until operation after diagnosis was 4.1 days, indicating that surgery was performed promptly. In addition, in the case of the defected septal bone or higher classification type, the number of patients who required more than one week until surgery tended

Table 1. Age distribution

	Age (yr)								Sex		Total
	≤9	10~19	20~29	30~39	40~49	50~59	60~69	≥70	Male	Female	
Type I	0	8	10	8	5	8	5	1	34	10	44
Type IIA	1	9	19	6	18	11	7	1	60	11	71
Type IIAs	0	1	4	2	2	3	2	0	11	3	14
Type IIB	0	4	8	4	6	3	2	1	26	1	27
Type IIBs	0	0	5	0	5	4	3	1	17	0	17
Type III	1	3	2	1	0	6	0	0	10	3	13
Total	2	25	48	21	36	35	15	4	158	28	186

Values are presented as number. Each types classification according to the standard of Hwang *et al.*'s classification[4].

Table 2. Cause of trauma

	Slip down	Fall down	Fist trauma	Collision	TA	Etc.	Total
Type I	16	2	5	14	6	1	44 (23.7)
Type IIA	22	2	19	7	15	6	71 (38.2)
Type IIAs	5	4	2	1	1	1	14 (7.5)
Type IIB	8	2	5	7	2	3	27 (14.5)
Type IIBs	7	2	2	4	2	0	17 (9.1)
Type III	3	0	3	4	1	2	13 (7.0)
Total	61 (32.80)	12 (6.45)	36 (19.35)	37 (19.89)	27 (14.52)	13 (6.99)	186 (100.0)

Values are presented as number or number (%). Each types classification according to the standard of Hwang *et al.*'s classification[4]. TA, traffic accident.

to increase, although the number was small. However, no surgery was delayed for more than two weeks.

4. Accompanied fracture

Regarding adjacent fractures that occurred together with nasal bone fracture, 32 patients had orbital blow-out fracture (BOF), which accounted for the highest proportion. Zygomaticomaxillary complex (ZMC) fracture and mandible fracture accounted for the second and third highest proportions, respectively. Regarding the frequency of accompanying fracture by nasal bone fracture type, accompanying fracture occurred most frequently in type I. Regarding the rate of accompanying fracture, the highest rate was 63% in type IIB. Similarly high rates were also shown in type III and type IIBs. However, the overall rate of accompanying fracture was 38.7%, which was relatively low (Table 3, Fig. 2).

Table 3. Accompanying fracture

	BOF	ZMC	Mandible	Le Fort	NOE	Total
Type I	9	10	1	3		23/44 (52.3)
Type IIA	3	7	3			13/71 (18.3)
Type IIAs	1					1/14 (7.1)
Type IIB	8	7	2			17/27 (63.0)
Type IIBs	7	3				10/17 (58.8)
Type III	4	2	1		1	8/13 (61.5)
Total	32	29	7	3	1	72/186 (38.7)

Values are presented as number or number/total number (%). BOF, blow-out fracture; ZMC, zygomaticomaxillary complex; NOE, naso-orbito-ethmoid. Each types classification according to the standard of Hwang *et al.*'s classification[4].

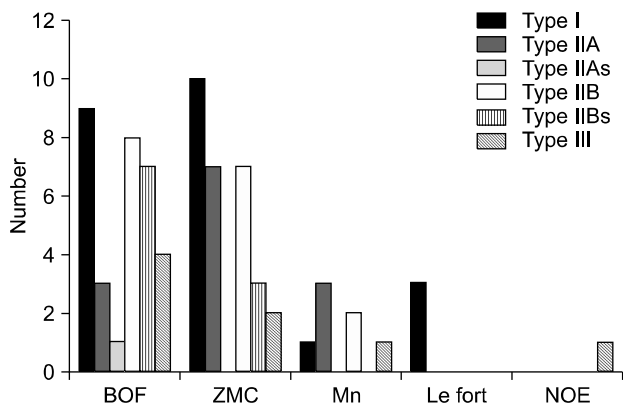


Fig. 2. Accompanying fracture. BOF, blow-out fracture; ZMC, zygomaticomaxillary complex; Mn, mandible; NOE, naso-orbito-ethmoid. Each types classification according to the standard of Hwang *et al.*'s classification[4].

5. Complications

The complication types were classified according to esthetic deformity, hyposmia, and hypoesthesia following Yang *et al.*[5], in addition to obstruction and pain, but rhinorrhea was excluded because there were no appropriate patients. The esthetic deformity type included depression, deviation as well as ecchymosis, bruise, swelling, and scar formation. The hypoesthesia type included hypoesthesia and paresthesia on the nasal area. The pain type included nasal pain and tenderness. The patients' complications were subcategorized according to the 'early' type, which occurred between one week after surgery and one month after surgery, and the 'late' type, which occurred since one month after surgery and then followed-up regularly for at least three months after surgery. Of the patients,

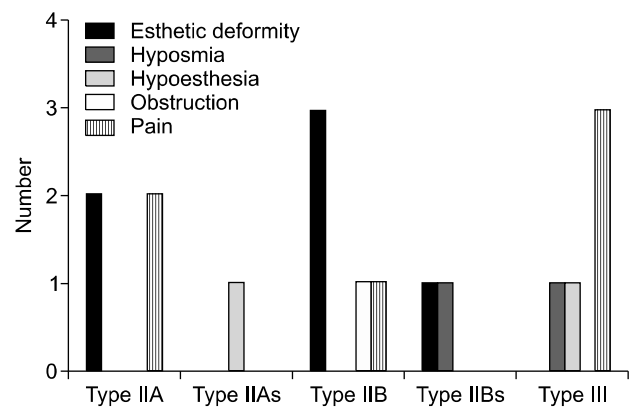


Fig. 3. Early complications after closed reduction. Each types classification according to the standard of Hwang *et al.*'s classification[4].

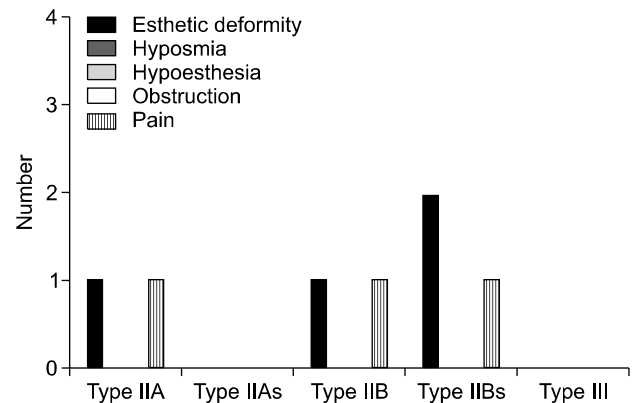


Fig. 4. Late complications after closed reduction. Each types classification according to the standard of Hwang *et al.*'s classification[4].

except for those who refused surgery and type I patients who were non-indicative for surgery, the esthetic deformity type of complications included six early cases and four late cases. Regarding deformity, among type IIA or IIAs patients, no one complained of deviation or depression, while three of six early cases and two of four late cases were observed in type IIB and IIBs patients. Two of four late complications had a symptom of scar formation only, and other acute complications were ecchymosis or bruise. Regarding pain, six early cases and three late cases were observed, which accounted for the highest proportion of all complications. Pain was evenly observed by type, but its frequency tended to be slightly higher in type III patients. Regarding hypoesthesia, an early case was observed in type IIAs and III patients, respectively. Regarding obstruction, one early case was observed in type IIB patients only. Regarding hyposmia, an early case was observed in type IIBs and III patients, respectively (Fig. 3, 4).

Discussion

Regarding age distribution, patients in their 20s, particularly male patients, accounted for the highest proportion. This result was similar to that of a study conducted by Small[6], which reported a male-to-female ratio of 4:1. Turvey[7] reported that TA accounted for the highest proportion of causes of fracture. In this study, however, slip down, fist trauma, and collision were the main causes of fracture. These results are likely to be attributable to the fact that Pusan National University Hospital was easy to reach and that the nearby workers and males in their 20s were involved in many social activities. In addition, the low occurrence rate of nasal bone fracture due to TA is likely to be attributable to the fact that the rate of TA is lower than that of other causes of injury and that nasal bone fracture is easily ignored due to the other concurrent fractures that frequently occur. Regarding the fracture type, type IIA, which is a unilaterally simple fracture according to Hwang *et al.*'s classification[4], accounted for the highest proportion, while the occurrence rate of type IIAs or IIBs, which has septal fracture without depression, was low. This is likely to be attributable to the fact that due to the structural feature of the nose, the patients visited the hospital mainly due to mild fracture caused by slip down,

The mean time elapsed until operation after fracture was 4.1 days. All patients underwent primary reduction within two weeks[8,9]; however, the operation tended to be delayed as the fracture type became more severe. This is likely to be attributable to the fact that due to the feature of closed reduction, surgery was performed once the patient's edema and other symptoms were somewhat relieved after the fracture, and that the time for surgery was delayed as the recovery time was delayed in severe cases.

Regarding the classification of nasal bone fracture, Stranc and Robertson's classification[10] based on the direction of force and clinical assessment, Harrison's classification[11] based on associating bones and with/without displacement, Haug and Prather's classification[12] based on the degree of fracture of the nasal and adjacent bones, and Murray *et al.*'s classification[13] based on the pathologic criteria and others are used. In this study, Hwang's classification[4] based on fracture severity, bone segment displacement, and the presence of septal fracture, which was presented in 2006, was used in conduct of the study by focusing on the fracture severity and range.

Open reduction for nasal bone fracture is performed to secure a vision field or to fix using a metal plate in treatment of compound and comminuted fracture. However, open reduction has the disadvantages of infection risk and difficulty of controlling the amount of bone segment absorption. Closed reduction has the advantages of relatively easy manipulation and short operation time but has the disadvantage of difficulty of accurate bone segment reduction. Thus, a proper surgical method should be selected considering the fracture severity and degree of nasal deformity[8,11]. In the case of reduction, a satisfactory outcome was reported to have been clinically achieved in many cases[14], and a successful prognosis in terms of patient satisfaction and postoperative status was achieved in children[15]. In this study, statistical analysis was performed on patients who underwent closed reduction to achieve the reliability of postoperative assessment. In the case of type III, the patient number was small, but the complication rate was the highest. In cases of types IIB and IIBs, the complication rate was high. However, early complications were observed in most type IIB cases, and late complications were observed in type IIBs patients, who showed the most deformity complication. In the case

of type III, many patients particularly suffered from pain. This is likely to be attributable to the fact that the more severe septal bone fracture, depression, and deviation in type III increased the preoperative and postoperative pain, and that the number of patients who suffered from deformity as a late complication was different as the patients recognized the deformity by themselves. However, this result means that patient satisfaction after closed reduction is relatively lower in type IIBs or III patients than in the other groups. Thus, for type IIBs or III patients, open reduction should be considered or the patients should be informed of the possibility of postoperative septorhinoplasty.

General or local anesthesia may be selected for closed reduction. Wild *et al.*[16] reported that a satisfactory result was obtained in terms of stability or complication in reduction under sedation. Khwaja *et al.*[17] conducted a study on the effectiveness of reduction under sedation, but Cook *et al.*[18] reported that a successful closed reduction could be achieved under general anesthesia. In this study, however, closed reduction under systemic anesthesia was performed for pain reduction during surgery, and for more accurate nasal bone reduction. In addition, nasal plain films were taken from all patients for effective preoperative and postoperative evaluations[19,20], and 4-day gauze packing with antibiotic treatment and 7-day external nasal splinting were applied to the patients according to the conventional treatment protocol[9].

In examination of other fractures near the nasal bone via computed tomography, the frequency of concurrent fracture increased the more adjacent the site is to the nasal bone, such as BOF, ZMC fracture, and mandible fracture. In particular, in the case of BOF, concurrent fracture was observed in 32 of 72 cases. The rate of concurrent fracture was high in severe cases, such as types IIB, IIBs, and III. In the case of type I, the rate of concurrent fracture was 52.3%, which was relatively high. This is likely to be attributable to the fact that the direction impact on the nasal bone was lower and the impact on the adjacent bone was higher according to the direction of force application, as shown in Stranc and Robertson's classification[10].

Complications observed during the 3-month follow-up after surgery included esthetic deformity, hyposmia, hyposmia, rhinorrhea, obstruction, and pain. However, infection, re-fracture, or epiphora did not occur. According

to Chung *et al.*[21], long-term follow-up should be required after surgery on nasal bone fracture, for the following reasons. First, because the nose is covered with thin soft tissues without muscles for reconstruction of the bone, fibrosis, scar formation, and contracture frequently occur during treatment[2]. Second, it is difficult to set the standard of satisfaction evaluation. Third, the treatment goal is not always clear. Fourth, due to the complex anatomical structure, the clinical manifestations and surgical method vary depending on the adjacent anatomical structures[22].

Conclusion

Nasal bone fracture frequently occurs in the face. If proper treatment is not provided, nasal bone fracture may cause functional and aesthetic abnormalities. This study was conducted on outpatients and emergency patients who visited the Department of Oral and Maxillofacial Surgery in Pusan National University Dental Hospital and Pusan National University Hospital due to nasal bone fracture for the past three years, to investigate the types and causes of nasal bone fracture and to evaluate the efficacy and prognosis of closed reduction according to the fracture classification.

The same treatment protocol was applied to all patients, followed by follow-up of at least three months. As a result, the complication occurrence rate was insignificant in most cases, and in such cases, mild complications were observed. However, postoperative pain, deformity, and hyposmia of the nasal bone were observed in type IIBs and III patients. Therefore, closed reduction should be considered, or postoperative septorhinoplasty should be required, for type IIBs and III patients. Further study with a larger number of patients and further classification is required.

Acknowledgements

This study was supported by a Clinical Research Grant from the Pusan National University Dental Hospital (2013).

References

1. Kucik CJ, Glenney T, Phelan J. Management of acute nasal fractures. *Am Fam Physician* 2004;70:1315-20.

2. Murray JA, Maran AG. The treatment of nasal injuries by manipulation. *J Laryngol Otol* 1980;94:1405-10.
3. Kelley BP, Downey CR, Stal S. Evaluation and reduction of nasal trauma. *Semin Plast Surg* 2010;24:339-47.
4. Hwang K, You SH, Kim SG, Lee SI. Analysis of nasal bone fractures; a six-year study of 503 patients. *J Craniofac Surg* 2006;17:261-4.
5. Yang IS, Yeo HH, Kim YK, Byun WR. A clinical study of the nasal bone fractures. *J Korean Plast Reconstr Surg* 1994;16:419-27.
6. Small EW. Survey of maxillofacial fractures. *J Oral Surg* 1976;34:27-8.
7. Turvey TA. Midfacial fractures: a retrospective analysis of 593 cases. *J Oral Surg* 1977;35:887-91.
8. Fonseca RJ, Walker RV, editors. *Oral and maxillofacial trauma*, 2nd ed, Philadelphia: W.B. Saunders; 1997. p.543-72.
9. Park CH. The current knowledge of the treatment of nasal bone fractures. *J Rhinol* 2011;18:94-101.
10. Stranc MF, Robertson GA. A classification of injuries of the nasal skeleton. *Ann Plast Surg* 1979;2:468-74.
11. Harrison DH. Nasal injuries: their pathogenesis and treatment. *Br J Plast Surg* 1979;32:57-64.
12. Haug RH, Prather JL. The closed reduction of nasal fractures: An evaluation of two techniques. *J Oral and Maxillofac Surg* 1991;49:1288-92.
13. Murray JA, Maran AG, Busuttill A, Vaughan G. A pathological classification of nasal fractures. *Injury* 1986;17:338-44.
14. Staffel JG. Optimizing treatment of nasal fractures. *Laryngoscope* 2002;112:1709-19.
15. Yabe T, Tsuda T, Hirose S, Ozawa T. Comparison of pediatric and adult nasal fractures. *J Craniofac Surg* 2012;23:1364-6.
16. Wild DC, El Alami MA, Conboy PJ. Reduction of nasal fractures under local anaesthesia: an acceptable practice? *Surgeon* 2003;1:45-7.
17. Khwaja S, Pahade AV, Luff D, Green MW, Green KM. Nasal fracture reduction: local versus general anaesthesia. *Rhinology* 2007;45:83-8.
18. Cook JA, McRae RD, Irving RM, Dowie LN. A randomized comparison of manipulation of the fractured nose under local and general anaesthesia. *Clin Otolaryngol Allied Sci* 1990;15:343-6.
19. Han DG, Kim TS, Park DD, Shim JS, Lee YJ. The accuracy rate in comprehension of aspects of nasal bone fracture based on simple X-ray and 2D CT compared with 3D image. *Arch Craniofac Surg* 2012;13:111-8.
20. Park SY, Choi JH, Lee KH, Moon IS, Yang HS. Analysis on effectiveness of three dimensional facial computed tomography in diagnosis of nasal fractures. *J Rhinol* 2009;16:134-8.
21. Chung SH, Park JI, Choe J, Baek SM. Clinical analysis of satisfaction of nasal bone reduction. *Arch Plast Surg* 1994;21:984-90.
22. Verwoerd CD. Present day treatment of nasal fractures: closed versus open reduction. *Facial Plast Surg* 1992;8:220-3.